

Case Report

Bony tumour in an unusual location on the mandible

Aashish Sasidharan, Amish Gohil, Santosh Koshy¹, Ashish Kumar Gupta

Departments of Plastic and Reconstructive Surgery and ¹Oral and Maxillofacial Surgery, Christian Medical College and Hospital, Vellore, Tamil Nadu, India

Address for correspondence: Dr. Aashish Sasidharan, Department of Plastic Surgery, Christian Medical College and Hospital, Vellore - 632 004, Tamil Nadu, India. E-mail: draashish27@gmail.com

ABSTRACT

Osteomas are benign osteogenic tumors that are seen in the facial bones, but uncommonly in the mandible. In the facial bones, both central and peripheral osteomas have been described. Peripheral osteomas have been described to occur in the frontal, ethmoid, and maxillary sinuses but are not common in jawbones. When in the mandible, they are usually found over the angle and inferior border of the mandible. We report on a solitary peripheral osteoma located unusually in the sigmoid notch of the left mandible causing facial asymmetry.

KEY WORDS

Mandible; mandibular notch; osteoma; sigmoid notch; tumor

INTRODUCTION

Osteomas are slow growing, innocuous, benign osteogenic tumours composed of compact and/or cancellous bone. The three variants described are peripheral, central and extraskeletal types.^[2] The central osteoma arises from the endosteum, the peripheral osteoma from the periosteum, and the extraskeletal osteoma usually develops within a muscle. Generally, osteoma is seen as a solitary lesion though multiple osteomas are found in Gardner's syndrome. They are mostly restricted to the craniofacial skeleton involving the paranasal sinuses and mandible and rarely involve the maxilla. It is usually found over the angle and inferior border of the mandible; an osteoma developing in the sigmoid notch of the mandible is extremely rare.^[5]

We report a case of a solitary periosteal osteoma arising from the sigmoid notch of the mandible in a 52-year-old woman.

CASE REPORT

A 52-year-old female presented with a gradually enlarging painless swelling on the left cheek in the preauricular region for the past 5 years. There was no other significant medical history and no history of any trauma. On examination, there was facial asymmetry but no trismus, deviation of the jaw on mouth opening, difficulty with mastication or neurological deficits.

This is an open access article distributed under the terms of the Creative Commons Attribution-NonCommercial-ShareAlike 3.0 License, which allows others to remix, tweak, and build upon the work non-commercially, as long as the author is credited and the new creations are licensed under the identical terms.

For reprints contact: reprints@medknow.com

How to cite this article: Sasidharan A, Gohil A, Koshy S, Gupta AK. Bony tumour in an unusual location on the mandible. Indian J Plast Surg 2015;48:200-3.

Access this article online	
Quick Response Code:	Website: www.ijps.org
	DOI: 10.4103/0970-0358.163062

On extra-oral examination, a swelling was observed in the left preauricular region which became more prominent on opening the mouth. Palpation revealed a single, hard, non-tender, fixed swelling 3.0 cm × 2.5 cm × 2.0 cm large that appeared to be arising from the mandible [Figure 1]. The overlying skin was free. A non-contrast computed tomography (CT) scan showed a well-circumscribed, bone-like hyper dense, sclerotic image with a broad base and lobulated surface on the left mandibular notch [Figure 2].

A provisional diagnosis of osteoma was made. Under general anesthesia, the lesion was approached intraorally, vestibular incision taken on left side mandible ramus. The lateral surface of ascending ramus was exposed up to the coronoid process. As the medial placement of the coronoid prevented access to the base of the tumor, a coronoidectomy was performed,. The lesion was then excised using an oscillating saw blade. Figure 3 shows the excised specimen. Primary closure of the wound was

achieved with 3-0 vicryl. The postoperative period was uneventful. Histopathology findings showed the tumor to be composed of trabeculae of dense, sclerotic, mature lamellar and woven bone with a pauci-cellular fibro collagenous stroma [Figure 4]. There was no evidence of malignancy. Based upon the clinical, radiological and histological findings, a definitive diagnosis of peripheral osteoma was established. The patient has presently been followed up regularly over the past 4 months and there has been no recurrence of the swelling [Figures 5 and 6].

DISCUSSION

Osteoma is a benign, slow growing bone tumor that presents as a protruding mass, frequently arising from the craniomaxillofacial bones and characterised by proliferation of compact, lamellar cortical bone. It arises from the paranasal sinuses, most commonly the frontal sinus. Peripheral osteomas have been reported to occur

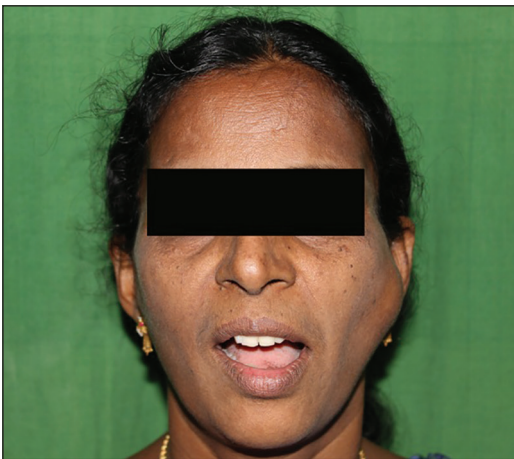

Figure 1: Swelling over left preauricular region, prominent on opening mouth

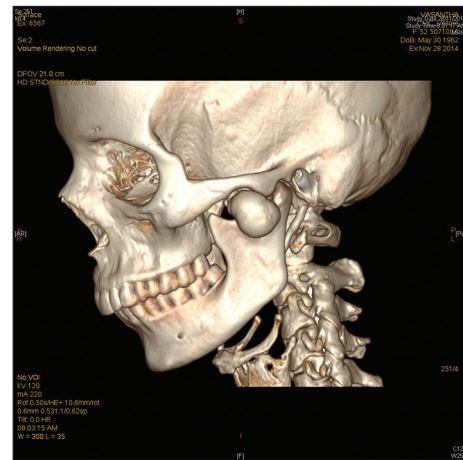


Figure 2: Three-dimensional computed tomography face showing a radio-opaque well defined swelling 3.0 cm × 2.5 cm × 2.0 cm at left mandible notch

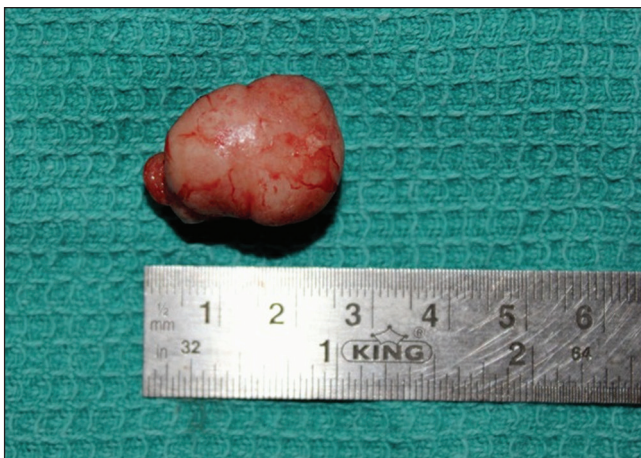

Figure 3: Excised specimen measuring 3.0 cm × 2.5 cm × 2.0 cm

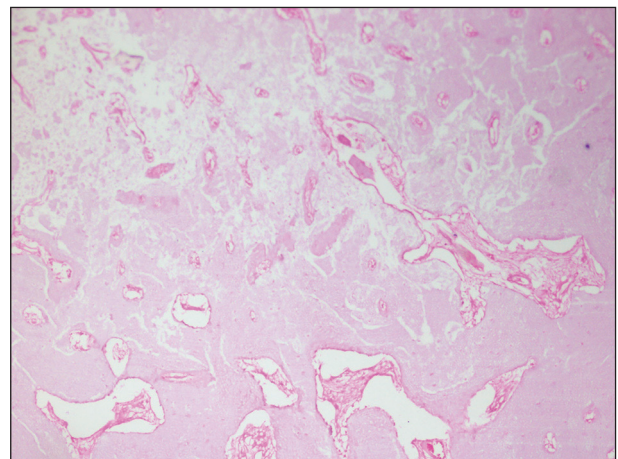


Figure 4: Interwoven trabeculae of mature lamellar bone with intervening loose stroma (H and E ×50)

Table 1: Comparison between the reported cases of the osteoma of the sigmoid notch

Reference	Age (years)	Sex	Side	Location	Size (in cm)	Symptoms	Treatment
Bessho <i>et al.</i>	26	Male	Right	Lateral	3.4×2.9×1.7	Swelling	Excision
Schulze	73	Female	Left	Medial	3.0×3.0×2.7	Pain	Not available
Sekerci <i>et al.</i>	59	Male	Right	Middle	Not available	No	Conservative
Iwai <i>et al.</i>	78	Female	Right	Medial	3.6×3.5×3.0	No	Conservative
Rao <i>et al.</i>	16	Female	Right	Lateral	3.0×3.0	Swelling	Excision (intraoral)
Our case	52	Female	Left	Lateral	3.0×2.5×2.0	Swelling	Excision (intraoral)

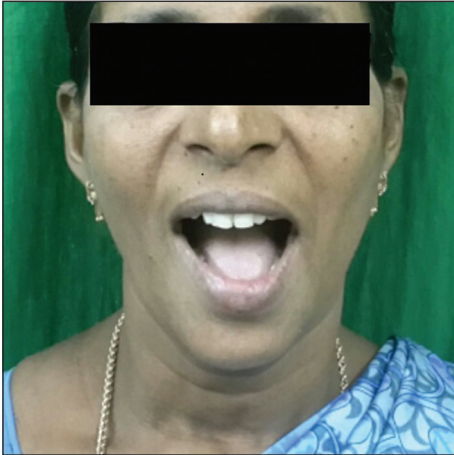

Figure 5: Post-operative photo, absence of swelling over left pre-auricular region

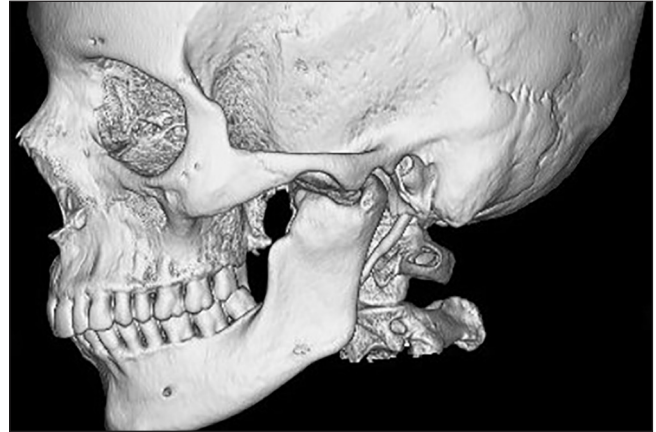

Figure 6: Three-dimensional computed tomography face postoperative at 4 months, with absence of residual tumour/recurrence

in the mandible, maxilla, external auditory meatus, temporal bones and pterygoid plates. The mandible is more frequently involved than the maxilla with reports of incidence ranging from 64%^[1] to 81.3%, respectively.^[4] Lesions are usually located in the angle and margin of the mandible. Osteoma is most frequently observed in the second and fifth decades of life. Osteomas are usually solitary; if multiple, the patient should be evaluated for Gardner's syndrome.

The etiology of osteomas is still unknown. While some investigators consider it a true neoplasm; others classify it as a developmental anomaly. Osteomas are often asymptomatic and detected incidentally. However, secondary to the location of the tumor, problems with occlusion, asymmetry of the face, headaches, facial pain, and impaired mandibular movements may occur.

CT is the best imaging modality for determining the location, attachment, extension and anatomical relationships of the lesion.^[5] Peripheral osteomas are easy to recognise by their radiographic findings. They appear as round or oval radiopaque masses with a broad base and distinct borders.^[5] If a peripheral osteoma is pedunculated, a narrow contact area can be seen between the lesion and the compact bone. In this case, the lesion

consisted of dense, uniformly opaque compact bone with a broad base.

Histological classification differentiates among compact (dense, compact bone), cancellous (soft, spongy bone), and mixed-type osteomas. The compact osteoma consists of mature lamellar bone with few marrow spaces. The cancellous/trabecular osteoma is characterised by bony trabeculae and fibro-fatty marrow enclosing osteoblasts, surrounded by a cortical bone margin. Although the compact type is the most common type seen in the mandible, in this case, the osteoma was a mixed variant.

Treatment includes observation with periodic clinical and radiological examination^[4] for small, non-progressing, asymptomatic, solitary lesions. Surgery should be considered for large, deforming osteomas. In this case, excision was considered as the lesion was progressive and causing facial asymmetry. We employed an intraoral approach for aesthetic purposes, which also allowed easy access to this unusually placed osteoma. Recurrence of peripheral osteoma after surgical excision is extremely rare. Malignant transformation of peripheral osteoma has not been reported in the literature.

Sigmoid notch osteomas are rare and to the best of our knowledge, this is only the sixth such case reported in

English literature.^[1,3-6] Among the previously reported cases [Table 1], the mean age of presentation was 51 years. In contrast to the lateral location of the osteoma in our case and that reported by Bessho *et al.*^[1] and Rao *et al.*,^[6] the others were in the middle^[4] or the medial aspect of the sigmoid notch.^[3,5] Conservative management was adopted in cases where the lesion was asymptomatic; in this case progressive enlargement of the lesion and facial asymmetry warranted surgical excision.

Financial support and sponsorship

Nil.

Conflicts of interest

There are no conflicts of interest.

REFERENCES

1. Bessho K, Murakami KI, Iizuka T, Ono T. Osteoma in mandibular condyle. *Int J Oral Maxillofac Surg.* 1987;16:372-375.
2. Kaplan I, Calderon S, and Buchner A. "Peripheral osteoma of the mandible: A study of 10 new cases and analysis of the literature," *Journal of Oral and Maxillofacial Surgery*, vol. 52, no. 5, pp. 467-470, 1994.
3. Shulze D. Radiographic diagnostic: Osteoma of the left mandibular notch. *Quintessence Int*, 2008; 39:702-703.
4. Sekerci AE, Sahman H, Ertas ET, Sisman Y. An unusual peripheral osteoma of the mandibular notch: A case report with computed tomography evaluation. *Oral Radiology*. 2011; 27:78-82.
5. Iwai T, Izumi T, Baba J, Maegawa J, Mitsuda K, Tohnai I. Peripheral osteoma of the mandibular notch: Report of a case. *Iran J Radiol.* 2013;10:74-6.
6. Rao S, Rao S, Pramod DSR. Transoral removal of peripheral osteoma at sigmoid notch of the mandible. *J Maxillofac Oral Surg.* 2015 Mar;14:255-7.