

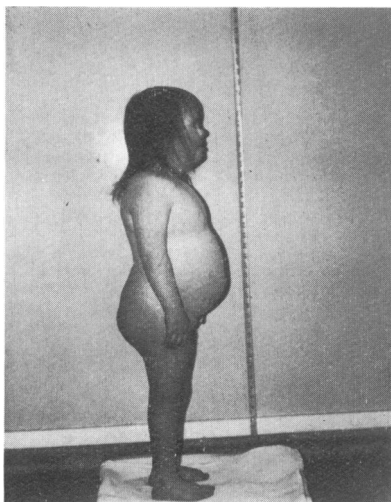FIG.—Patient at time of presentation, showing ascites.

normal serum bilirubin and no evidence of hepatocellular dysfunction or biliary obstruction. Total serum proteins normal at 8.2 g/100 ml, lipoprotein electrophoresis showed a raised  $\beta$  fraction, serum cholesterol was high at 345 mg/100 ml, and serum triglycerides increased at 310 mg/100 ml. These abnormally high values persisted, as did the ascites, after the child's diabetes was brought under control; and at this stage her thyroid function was investigated.

Her height at 96 cm was well below the 3rd centile, though bone age was only marginally less than chronological age. Serum protein-bound iodine was 3  $\mu$ g/100 ml (normal 4–7  $\mu$ g/100 ml) and serum thyroxine 3.6  $\mu$ g/100 ml (normal 4.5–13  $\mu$ g/100 ml). The 4-hour uptake after  $^{132}\text{I}$  (5  $\mu$ Ci) was 13% (normal range 10–30%), but when repeated after administration of 20 units thyroid-stimulating hormone, 4-hour uptake was only 9.5%. The absence of any extra response to thyroid-stimulating hormone indicates an absence of thyroid reserve in the patient. No thyroid antibodies were shown in either the patient or her mother.

After a diagnosis of hypothyroidism, her progress on a small dose of thyroxine (0.025 mg daily) has been encouraging. She has grown 3 cm in 6 months, ascites and abdominal distension are no longer evident, and her skin and hair are less dry and coarse. Her mother reports she is generally more lively and interested.

### Discussion

This case is presented not only because the combination of Down's syndrome with diabetes mellitus and hypothyroidism is rare, but also because of the unusual presentation of this child's disturbance of thyroid function.

Thyroid function in Down's syndrome is usually normal (Marks and Hamlin, 1967), but both hyperthyroidism (Kurland *et al.*, 1957) and

hypothyroidism have been described. The latter is less common, and until 1965 only 5 cases had been reported (Hayles, Hinrichs, and Tauxe, 1965).

The triple combination of hypothyroidism, Down's syndrome, and diabetes mellitus is even more rare and there are only two previously described cases (Daniels and Simon, 1968; Litman, 1968), who were aged 13 months and 17 years at the time the full picture became evident.

Investigations in this child have shown that she was hypothyroid rather than totally deficient in thyroid function. The presenting symptom of ascites is unusual in children, but fluid accumulation in the peritoneum and elsewhere is a well-recognized clinical feature of adult myxoedema. On admission the provisional diagnosis in this case was Mauriac syndrome (Guest, 1953), but it is doubtful if this condition of hepatomegaly, stunting of growth, and poorly controlled diabetes mellitus is an entity. Rather, this patient shows a rare cause of that unusual condition.

### Summary

A child with Down's syndrome who subsequently developed diabetes mellitus and hypothyroidism before the age of 6 years is described. The principal presenting feature of her disturbed thyroid function was ascites.

### REFERENCES

- Daniels, D. M., and Simon, J. L. (1968). Down's syndrome, hypothyroidism, and diabetes mellitus. *Journal of Pediatrics*, **72**, 697.
- Guest, G. M. (1953). The Mauriac syndrome. *Diabetes*, **2**, 415.
- Hayles, A. B., Hinrichs, W. L., and Tauxe, W. N. (1965). Thyroid disease among children with Down's syndrome (mongolism). *Pediatrics*, **36**, 608.
- Kurland, G. S., Fishman, J., Hamolsky, M. W., and Freedberg, A. S. (1957). Radioisotope study of thyroid function in 21 mongoloid subjects, including observations in 7 parents. *Journal of Clinical Endocrinology*, **17**, 552.
- Litman, N. N. (1968). Down's syndrome, hypothyroidism, and diabetes mellitus. *Journal of Pediatrics*, **73**, 798.
- Marks, J. F., and Hamlin, M. (1967). Free thyroxine levels in children with mongolism. *Journal of Pediatrics*, **70**, 435.

W. ABDEL SHAHEED and L. ROSENBLUM\*  
*Royal Liverpool Children's Hospital, Liverpool.*

\*Correspondence to Dr. L. Rosenbloom, Alder Hey Children's Hospital, Eaton Road, Liverpool L12 2AP.

## Cartilage hair hypoplasia

Cartilage hair hypoplasia was first described by McKusick in 1964. While studying the old Amish sect he noticed an association between short-limbed dwarfism and sparseness of hair, and later reported

77 cases (McKusick *et al.*, 1965). Since then several cases with no Amish ancestry have been published. However, though two variants of this rare condition were shown in Britain recently (Savage, 1972), no other cases have been published in Britain.

#### Case report

A male was the product of the third pregnancy of a young mother. There was no history of consanguinity in the parents and, apart from hydramnios, the pregnancy had been normal.

He weighed 2.77 kg (10th centile) at birth, and crown to heel length was 43 cm (below the 3rd centile). An oesophageal tube was passed without difficulty into the stomach. Both upper and lower limbs were short in relation to the trunk, but there was no clinical or radiological evidence of achondroplasia.

At 3 weeks of age he was admitted to the Radcliffe Infirmary with large intestinal obstruction, which was relieved by sigmoid colostomy. A biopsy showed Hirschsprung's disease and at 9 months of age the aganglionic segment was resected and the colostomy closed (Mr. Malcolm Gough).

At 2½ years of age he was readmitted for assessment of his short stature and particularly for investigations appropriate to the cartilage hair hypoplasia syndrome, which seemed a likely diagnosis. His height remained below the third centile and his weight had fallen below this level, falling away from the centile lines.

On examination he was strikingly short, height 76 cm and weight 12.8 kg. He had very fine and sparse fair hair, and the lower limbs appeared disproportionately shorter than the upper limbs (Fig. 1). His hands were

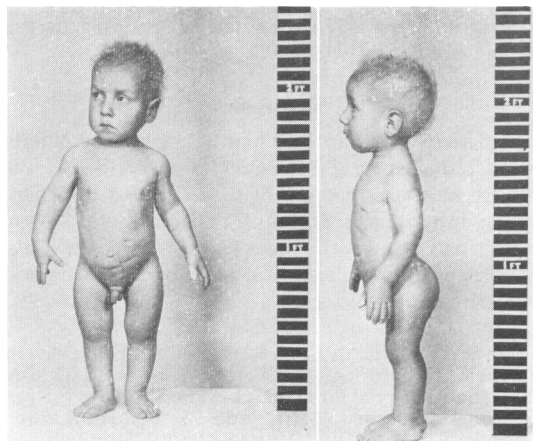


FIG. 1.—The patient aged 2½ years. Note increased lumbar lordosis and fine sparse hair.

short and broad, and it was not possible to extend fully either elbow. The sternum was abnormally prominent, and there was marked bowing of the legs. No hyperextensibility of the joints could be shown. His

intellectual development was considered to be within normal limits for his age.

#### Investigations.

**X-rays.** The skeleton showed generalized changes of typical metaphyseal dysostosis, i.e. widening, cupping, and defective mineralization in the metaphyses of the tubular bones (Fig. 2).

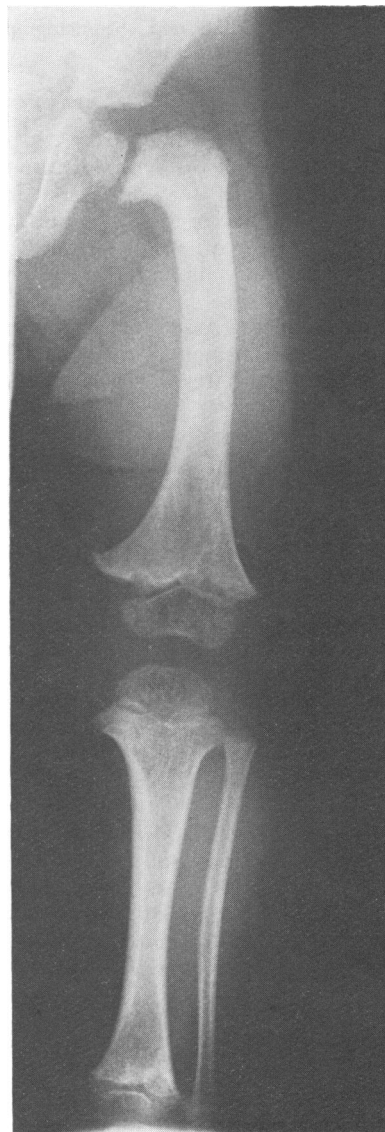

FIG. 2.—X-ray of left lower limb of patient showing widening, cupping, and defective mineralization of the metaphyses.

**Hair.** Amino acid analysis of the scalp hair (Dr. R. J. Pollitt) gave normal results. Electron microscopical examination (Dr. R. P. R. Dawber) showed that the majority of the hairs had a diameter approximately  $\frac{1}{4}$  of normal, but the cuticular scale pattern was within normal limits.

**Biochemical.** The following were performed with normal results: lipid tolerance test, microscopical examination for fat globules in stools, blood urea and electrolytes, urinary amino acid chromatography, and mucopolysaccharide screening test.

### Discussion

The main features of the syndrome are (i) short limbed dwarfism with bow legs and increased lumbar lordosis; (ii) minor skeletal abnormalities of anterior protrusion of the sternum, hyper-extendibility of joints, limitation of extension of elbows; (iii) fine sparse hair; and (iv) autosomal recessive inheritance. Associated features in some patients are Hirschsprung's disease, malabsorption syndrome, and poor resistance to some virus infections.

**Skeletal disorder.** Cartilage hair hypoplasia is one of several disorders in which the abnormality of the growth plate known as metaphyseal dysostosis leads to short stature (Irwin, 1966). The other 3 main disorders are (1) Jansen type; rare; associated with mental and motor retardation; pattern of inheritance unknown. (2) Schmidt type; dwarfism mild; skeletal deformities slight; intelligence average; an autosomal dominant. (3) Spahr type; similar to Schmidt type but an autosomal recessive. Thus cartilage hair hypoplasia differs from these disorders in the markedly short stature, and differs from the Jansen type in the absence of severe intellectual deficit.

The localized skeletal abnormalities present in cartilage hair hypoplasia (Smith, 1970), i.e. short broad hands, lack of full extension of elbow joints, prominence of the sternum with flaring of the bony rib cage, bow legs, and increased lumbar lordosis, may be present in the other varieties.

**Hair.** The other striking feature which distinguishes this from the other types of metaphyseal dysostosis is the very short, fine, sparse scalp hair. Coupe and Lowry (1970) have analysed hair from typical cases and found a normal amino acid content, but a thin structure with lower tensile strength and the lack of a central pigment core, which is present in normal hair. The hair from our patient shows the first two features.

**Associated alimentary tract disorders.** In the report of McKusick *et al.* (1965) one of the 77 patients died of coeliac disease and in 5 others malabsorption was suspected. There was no evidence of malabsorption in our patient, though full investigation to exclude this was not carried out. Two of McKusick's patients had Hirschsprung's disease, which was the presenting feature in our case.

**Associated severe viral infections.** 2 of McKusick's patients died of chickenpox and 3 others were so severely affected that a diagnosis of smallpox was seriously considered. Lux *et al.* (1970) extensively investigated 2 children with cartilage hair hypoplasia who had severe varicella and found them to have chronic neutropenia and disordered cellular immunity. Burke *et al.* (1967) mentioned 2 patients with exocrine pancreatic insufficiency and neutropenia who had metaphyseal dysostosis (Cases 5 and 11) and one who had Hirschsprung's disease. No mention was made of the state of the hair.

Our patient has so far had no clinical evidence of a poor response to infection.

This is another of the many rare genetic disorders in which correct diagnosis is advantageous to the patient and his family even though the condition itself is untreatable, as the parents can be informed of the poor prognosis for linear growth but the fairly good prognosis for intellectual development, and the genetic implications for further sibs can be explained. The physician will be aware of the possibility of malabsorption, Hirschsprung's disease, and severe illness with viral infection.

### Summary

A patient with cartilage hair hypoplasia associated with Hirschsprung's disease is described. The syndrome is a rare cause of short-limbed dwarfism, and is inherited as an autosomal recessive. Apart from small stature, the main features are fine, sparse scalp hair and characteristic radiological changes of metaphyseal dysostosis.

We are grateful to Drs. R. J. Pollitt (University of Sheffield, Department of Psychiatry), R. P. R. Dawber (St. John's Hospital for Diseases of the Skin), T. J. Ryan, Consultant Dermatologist, and J. C. McLarnon, Consultant Radiologist (United Oxford Hospitals) for their help; and thank Mr. Malcolm Gough, Consultant Surgeon (United Oxford Hospitals) for information on the surgical aspects of this patient.

### REFERENCES

- Burke, V., Colebatch, J. H., Anderson, C. M., and Simons, M. J. (1967). Association of pancreatic insufficiency and chronic neutropenia in childhood. *Archives of Disease in Childhood*, **42**, 147.

- Coupe, R. L., and Lowry, R. B. (1970). Abnormality of the hair in cartilage-hair hypoplasia. *Dermatologica*, **141**, 329.
- Irwin, G. A. L. (1966). Cartilage-hair hypoplasia (CHH) variant of familial metaphyseal dysostosis. *Radiology*, **86**, 926.
- Lux, S. E., Johnston, R. B., August, C. S., Say, B., Penchaszadeh, V. B., Rosen, F. S., and McKusick, V. A. (1970). Chronic neutropenia and abnormal cellular immunity in cartilage-hair hypoplasia. *New England Journal of Medicine*, **282**, 231.
- McKusick, V. A. (1964). Metaphyseal dysostosis and thin hair; a 'new' recessively inherited syndrome? *Lancet*, **1**, 832.
- McKusick, V. A., Eldridge, R., Hostetler, J. A., Ruangwit, U., and Egeland, J. A. (1965). Dwarfism in the Amish. II. Cartilage-hair hypoplasia. *Bulletin of the Johns Hopkins Hospital*, **116**, 285.
- Savage, M. O. (1972). Metaphyseal dysplasia in siblings: a variant of cartilage-hair hypoplasia. *Proceedings of the Royal Society of Medicine*, **65**, 727.
- Smith, D. W. (1970). *Recognizable Patterns of Human Malformation*, p. 204. Saunders, Philadelphia and London.

C. B. BOOTHBY\* and B. D. BOWER  
*Department of Paediatrics, Radcliffe Infirmary, Oxford.*

\*Correspondence to Dr. C. B. Boothby, West Suffolk General Hospital, Bury St. Edmunds, Suffolk IP33 3JX.

---

*The following articles will appear in future issues of this journal:*

- Looking back:* Bray's discovery of pathogenic *Esch. coli* as a cause of infantile gastroenteritis. *J. Bray.*
- Personal comment:* Paediatrics and child psychiatry: the case for collaboration. *P. Pinkerton.*
- Assessment of techniques for measurement of blood pressure in infants and children. *A. M. Elseed, E. A. Shinebourne, and M. C. Joseph.*
- Exercise-induced bronchial lability and atopic status of families of infants with wheezy bronchitis. *P. König and S. Godfrey.*
- Sex chromosome aberrations and speech development. *M. Garvey and D. E. Mutton.*
- Serum protein and transferrin determinations to distinguish kwashiorkor from iron deficiency anaemia. *A. E. J. Masawe and J. Rwabwogo-Atenyi.*
- Diaphragmatic paralysis in the newborn. *D. Anagnostakis, E. Economou-Mavrou, A. Moschos, P. Vlachos, and D. Liakakos.*
- Treatment with new synthetic analogue of vasopressin in diabetes insipidus. *H. Nash.*