

gramme. This is in keeping with the tremor of other body parts, for example the wing-beating arm tremor of Wilson's disease and task-specific tremors such as writing and other occupational tremors.³

We have examined clinically, three other patients with clear dystonic head tremor in whom head tremor was altered by the position of the head in the anterior-posterior plane. In none of the others could we demonstrate a vestibular (otolith) mechanism. Despite these negative observations for a clear otolith influence upon head tremor electrophysiological measurements have shown that otolith spinal reflexes may be modulated by both head and body position.⁶ Thus there still remains the possibility that a change in head or body position may in itself modify vestibular influences upon body movement.

S MOSSMAN
L CLEEVES
L FINDLEY
MRC Human Movement and Balance Unit,
Section of Neuro-otology,
National Hospital for Neurology and Neurosurgery,
London, UK

Correspondence to: Dr Mossman, Department of Neurology, Wellington Hospital, Private Bag, Wellington South, Wellington, New Zealand.

- 1 Denny-Brown D. Clinical symptomatology of diseases of the basal ganglia. In: Vinken P, Bruyn G, eds. *Handbook of clinical neurology*, vol 6. Amsterdam: North Holland Publishing Co, 1968:133-9.
- 2 Bronstein A, Rudge P, Beechey A. Spasmodic torticollis following unilateral VIII nerve lesions: neck EMG modulation in response to vestibular stimuli. *J Neurol Neurosurg Psychiatry* 1987;50:580-6.
- 3 Cleeves L, Findley L, Marsden D. Odd tremors. In: Marsden D, Fahn S, eds. *Movement disorders 3*. Butterworths (In Press).
- 4 Podivinsky F. Torticollis. In: Vinken P, Bruyn G, eds. *Handbook of clinical neurology*, vol 6. Amsterdam: North Holland. 1968:567-603.
- 5 Gresty M, Barratt H, Page N, Rudge P. Analysis of downbeat nystagmus. Otolith vs semicircular canal influences. *Arch Neurol* 1986;43:52-55.
- 6 Dieterich M, Brandt T, Fries W. Otolith function in man. *Brain* 1989;112:1377-92.

Probable cases of Mast syndrome in a non-Amish family

Complicated forms of hereditary spastic paraplegia are rare. A 58 year old Flemish woman was admitted with a clinical picture of slowly progressive spastic paraplegia, dysarthria, presenile dementia and mild athetosis.

At the age of 16 her gait became shuffling. Before the age of 30 she used a walking stick, since the age of 35 years she has needed a walking frame and from the age of 40 she has become more wheelchair bound. During the third decade (maybe earlier) dysarthria, apathy and negativism appeared. Towards her 45th year, urinary incontinence began. On admission, aged 48, significant bradyphrenia and comprehension difficulties were noted and during the following years she presented a further mental deterioration. She is now bedridden and her speech restricted to rare, usually inappropriate, single syllable answers, which are sometimes repeated. She has difficulty swallowing fluids. She often shows spontaneous repeated slow turning of the head to the right and left and mild tortuous movements of the shoulders. Except for a divergent strabismus there are neither oculomotor abnormalities, nor fundoscopic anomalies. There is a slight bilateral facial weakness. The fine motor hand skills are lost

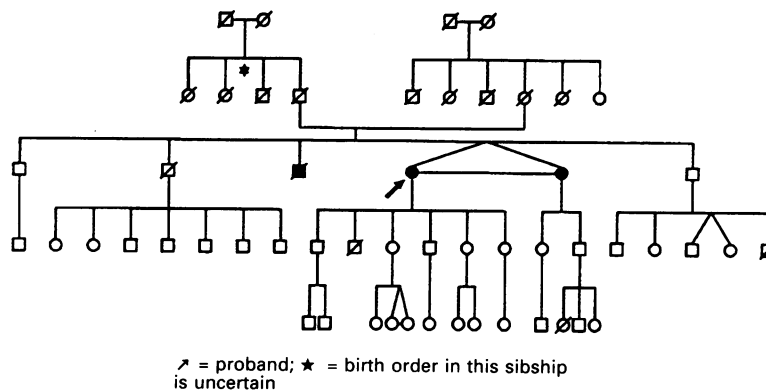


Figure Pedigree

without clear paresis of the upper limbs. The strength of leg muscles measures about 1 to 2/5. There were neither sensory deficits nor cerebellar signs. Deep tendon reflexes in the upper limbs were increased slightly. Knee jerks were unusually brisk and without clonus; ankle jerks were decreased. Plantar responses were extensor. Snout reflex and bilateral palmomental reflexes were present whilst corneomandibular reflexes were absent.

The following laboratory investigations showed no significant abnormalities: routine blood examination (except for intermittent elevation of glucose with normal haemoglobin A1C), creatine kinase, copper, lipids, very long chain fatty acids ratios C24/C22 and C26/C22, vitamin E, vitamin B12, folate, cortisol, adrenocorticotrophic hormone, thyroid hormones, arylsulfatase A and hexosaminidase A + B; the CSF protein was 590 mg/l with normal electrophoretic pattern.

The EEG showed mild general slowing. Nerve conduction studies and needle electromyography showed a mild axonal polyneuropathy. The somato-sensory evoked potentials demonstrated a slightly prolonged central conduction time. An electrocardiogram was normal. MRI of the brain showed diffuse cortico-subcortical atrophy, periventricular hyperintensities, thin corpus callosum and less marked atrophy of the brainstem and cerebellum. Light microscopic and electron microscopic examination of conjunctiva and skin showed some membranous cytoplasmic body-like inclusions (Professor J J Martin, Dr C Ceuterick-de Groote, University Hospital Antwerp).

The family history revealed two similar cases (figure). There was no known consanguinity.

The monozygotic twin has an almost identical medical history and clinical picture. She is able to stammer a few simple words. Her answers are sometimes slightly more appropriate, particularly for old memories. Her knee jerks and ankle jerks are both unusually brisk, and the plantar responses are extensor. One brother died at the age of 53. The medical records and relatives described difficulties with walking from the age of 20 (maybe earlier). During the following decades he presented a progressive spastic paraparesis, dysarthria, mental deterioration and urinary and faecal incontinence; no deficits of sensation or coordination were demonstrated. There was dysphagia in his last years. Death was due to pneumonia.

The pedigree suggests an autosomal recessive inheritance. The neurodegenerative syndrome in this family seems fully comparable

to the Mast syndrome, described in 1967 in an Ohio Amish isolate by Cross and McKusick.¹⁻³ There appears to be no similar cases that have been described outside the Amish population.

MARC D'HOOGE
Department of Neurology,
Algemeen Ziekenhuis St Jan,
Ruddershove 10,
8000 Brugge, Belgium

- 1 Cross HE, McKusick VA. The mast syndrome: a recessively inherited form of presenile dementia with motor disturbances. *Arch Neurol (Chic)* 1967;16:1-13.
- 2 Harding AE. Classification of hereditary ataxias and paraplegias. *Lancet* 1983;i:1151-55.
- 3 McKusick VA. Mendelian inheritance in man. Baltimore: The Johns Hopkins University Press, 1990:1095.

Ultrasensitive TSH assay and anti-Parkinsonian treatment with levodopa

We have recently reported the association of Parkinson's disease and hyperthyroidism in a group of 10 patients.¹ In that report, symptoms of Parkinson's disease were always significantly exacerbated by the development of hyperthyroidism and improved by its successful treatment.¹ We proposed that hyperthyroidism should be suspected in all Parkinsonian patients when their condition deteriorates.¹ Since clinical diagnosis of thyrotoxicosis is difficult in Parkinsonian patients, they should have a comprehensive thyroid examination and, if there is the slightest suspicion of hyperthyroidism, a hormonal evaluation of thyroid function (free T₄, ultrasensitive TSH).

Thyroid hormone levels (T₃ and T₄) have been found to be normal in Parkinsonian patients untreated or treated with levodopa.² However, a decreased response of thyrotropin (TSH) after stimulation by TRH (thyrotropin releasing hormone) has been reported in Parkinsonian patients treated with levodopa.³ Such a decreased TSH response after TRH stimulation is observed during hyperthyroidism, and is sometimes the only hormonal abnormality, especially in elderly patients with autonomous thyroid nodules. Thus the decreased TSH response after TRH-stimulation in patients treated with levodopa could be responsible for a false diagnosis of hyperthyroidism. These results, however, were obtained before the ultrasensitive TSH determination with a monoclonal antibody assay was available. A low ultrasensitive TSH level has the same significance as a decreased TSH response to TRH, indicating an increased negative feed-

Table Ultrasensitive TSH assay and anti-Parkinsonian treatment with levodopa. Means (SD).

	Normal ranges	Levodopa treated patients (n = 32)	Controls (n = 30)	p
Age (years)		73.1 (9)	76.0 (9)	0.27
Free T ₃ (pMol/l)	3.3-8.3	3.80 (1.29)	3.34 (1.16)	0.20
Free T ₄ (pMol/l)	8-26	13.40 (3.24)	12.75 (2.9)	0.47
Ultrasensitive TSH (mU/l)	0.17-3.5	1.71 (1.05)	1.45 (1.02)	0.38

Free T₃, free T₄ and ultrasensitive TSH levels in levodopa treated Parkinsonian patients compared with age-matched controls, mean (SD). NS: not significant by Student's *t* test.

back of thyroid hormones on pituitary TSH secretion. Thus basal ultrasensitive TSH level has become an important tool to detect hyperthyroidism, replacing the TRH-stimulation test.

The aim of our study was to determine whether chronic treatment with levodopa was able to lower the basal TSH levels, measured by an ultrasensitive assay, in Parkinsonian patients and thus be responsible for a false diagnosis of hyperthyroidism in such patients.

Thirty two Parkinsonian patients, mean (SD) age 73.12 (9.32) years; range: 50-88 treated with levodopa (187.5 mg/day to 700 mg/day) for one to 108 months were studied. These patients were clinically euthyroid, had a normal clinical thyroid examination and normal levels of free T₄. Blood samples were drawn at 8:00 am in fasting patients, from 8 to 12 hours after the last levodopa dose, for determination of free T₃, free T₄ and ultrasensitive TSH. These patients were not receiving any other drugs known to modify thyroid function. Thirty age matched controls were also studied, for comparison [mean (SD) 76.05 (9.31) years; range: 53-91]. Each patient and each control had titres of antithyroglobulin and antimicrosomal autoantibodies less than 1/320 and 1/800 respectively (haemagglutination assay). Free T₃ and free T₄ were measured using radioimmunoassay (RIA Amersham). Ultrasensitive TSH was measured by radioimmunoassay, using a monoclonal antibody (RIA Behring). The sensitivity of this TSH assay is 0.02 mU/l, the intra-assay and inter-assay coefficient of variations are 3.5% and 5% respectively. Comparisons of means were made with Student's unpaired *t* test after verification of a normal distribution for the data.

Free T₃ [mean (SD) 3.8 (1.29) pMol/l; range: 1.3-5.7] and free T₄ [mean (SD) 13.4 (3.24) pMol/l; range: 8.5-21] levels were not significantly different in Parkinsonian patients treated with levodopa than controls (table). The ultrasensitive TSH level was not significantly different in levodopa treated Parkinsonian patients [mean (SD) 1.71 (1.05) mU/l; range: 0.51-4] from controls [mean (SD) 1.45 (1.02) mU/l; range: 0.44-3.87] (table). Among the 32 patients, none had an ultrasensitive TSH level below the normal range. Ultrasensitive TSH level was not shown to be influenced by levodopa doses since no difference was noted between patients treated with less than 200 mg/day (n = 17) and those treated with more than 200 mg/day (n = 15) [1.64 (0.64) vs 1.97 (1.17) mU/l; not significant]. Furthermore, duration of levodopa therapy did not appear to modify ultrasensitive TSH level since no difference was observed between patients treated for less than 12 months (n = 12) and those treated for more than 12 months (n = 20) [1.53 (1.20) vs 1.82 (1.08) mU/l; not significant].

Clinical diagnosis of hyperthyroidism is often difficult in patients with Parkinson's disease because symptoms such as tremor, weight loss and sweating are common to both diseases, because thyrotoxicosis only produces few symptoms in elderly patients,⁴ and because the Parkinson's syndrome predominates in most cases.^{1,5,6} Thus hormonal evaluation of thyroid function appears to be very helpful, for diagnosis of hyperthyroidism, in Parkinsonian patients. Ultrasensitive TSH assay had been a great improvement in hormonal thyroid function evaluation, leading to easier detection of hyperthyroidism. A low ultrasensitive TSH level, with normal thyroid hormones, is frequently seen in elderly patients with autonomous thyroid nodules. Such patients require a thyroid scintigraphy to detect hyperfunctioning nodules, allowing the diagnosis of hyperthyroidism.^{7,8} Before the ultrasensitive TSH assay was available, an absence of TSH response after TRH stimulation was the only method of detecting such hyperthyroid patients. As a decreased response of TSH after TRH had been reported in Parkinsonian patients treated with levodopa,³ it remains to be determined whether basal TSH levels, measured by ultrasensitive assay were modified by levodopa treatment. In our study, basal TSH levels, measured by an ultrasensitive assay, in Parkinsonian patients treated with levodopa, were not found to be lower than in age matched controls. No patient treated with levodopa had an ultrasensitive TSH level below the normal range. Furthermore, in patients treated with levodopa, ultrasensitive TSH level was influenced neither by the levodopa dose nor by the duration of levodopa treatment.

In conclusion, chronic anti-Parkinsonian therapy with levodopa does not modify basal TSH levels measured by an ultrasensitive-assay. Thus ultrasensitive TSH evaluation is as efficient a method to detect hyperthyroidism in patients treated with levodopa as in the general population.

B VERGÈS,
M GIROUD,
G VAILLANT,
B VERGES-PATOIS,
JM BRUN,
R PUTELET
University hospital
(hôpital du bocage)
Dijon, France

Correspondence: Dr Vergès, Service de médecine 2, Hôpital du Bocage, B.P. 1542 Dijon Cedex, France

- Vergès B, Giroud M, Richard A, Giroud-Baleyrier F, Vaillant G, Lorcerie B, Brun JM, Putelat R. Parkinson's disease after antithyroid treatment. *Lancet* 1988;ii:564.
- Johannessen AC, Boye A, Parkenbergh H. Thyroid function in patients with Parkinson's disease. *Acta Neurol Scand* 1987;75:364-5.
- Spaulding SW, Burrow GN, Donabedian R, Van Woert M. L-Dopa suppression of thyrotropin releasing hormone response in man. *J Clin Endocrinol Metab* 1972;35:182-5.
- Davis PJ, Davis FB. Hyperthyroidism in

patients over the age of 60 years. *Medicine* 1974;53:161.

- Caradoc-Davies TH. Resolution of dyskinesia and the "on-off" phenomenon in thyrotoxic patients with Parkinson's disease after antithyroid treatment. *BMJ* 1986;293:38-9.
- Lavy S, Marks ES, Abramsky O. Parkinsonism and hyperthyroidism. *Europ Neurol* 1974; 12:20-27.
- Cadwell G, Gow SM, Sweeting UM, et al. A new strategy for thyroid function testing. *Lancet* 1985;i:1117-8.
- Bruce S, Rangedara DC, Lewis RR, Cordless D. Hyperthyroidism in elderly patients with atrial fibrillation and normal thyroid hormone measurements. *J Royal Soc Med* 1987; 80:74-76.

Vestibular and ventilatory dysfunction in sensory and autonomic neuropathy associated with primary Sjögren's syndrome

Subacute sensory neuropathy was described by Denny-Brown in association with carcinoma¹ and has recently been described in association with primary Sjögren's syndrome (SS).² The primary pathology is in the dorsal root ganglia and consists of lymphocytic infiltration and neuronal cell destruction. We describe a patient with primary SS with sensory and autonomic neuropathy and the previously undescribed clinical features of vestibular and ventilatory dysfunction.

A 38 year old man presented with difficulty with walking for one month. He also complained of pain and tingling in the feet and hands, patchy areas of abnormal sensation on the trunk and perioral paraesthesiae. He had experienced grittiness and dryness of the eyes and a dry mouth for 6 months and had keratoconjunctivitis sicca on ophthalmological examination about 4 months before his neurological presentation. His pupils reacted sluggishly to light but the visual fields and optic fundi were normal. There was reduced sensation in all divisions of the fifth cranial nerve bilaterally, although there was some sparing of the perioral region, and the corneal reflexes and corneal sensation were reduced. In the limbs the power was normal. The deep tendon reflexes were absent. In the upper limbs there was reduction of pinprick and light touch sensation in a distal distribution and loss of vibration sense and proprioception up to and including the wrists. In the lower limbs, pinprick sensation was reduced in the toes, light touch was absent up to the thighs and vibration sensation was absent below the iliac crests. There was severe impairment of proprioception up to and including the knees. Romberg's sign was positive and the gait was severely ataxic. There was bilateral punctate keratitis in the interpalpebral distribution and the Schirmer's test was 14 mm on the right and 4 mm on the left (normal > 5). On later examination, the Schirmer's test revealed no lacrimation from either eye.

The significant results of investigations were that the RA latex test was negative, anticardiolipin antibody level was 8 (normal < 20) and smooth muscle antibody titre was 1:40. Screening for other autoantibodies, including extractable nuclear antigens, was negative. CSF protein was initially 660 mg/L (normal < 400), CSF IgG was 55 mg/L (normal 10-60) and CSF IgG/albumin was 0.14 (normal < 0.11). On a later occasion the CSF protein level was 1,100 mg/L. CSF electrophoresis did not reveal oligoclonal bands. Motor nerve conduction velocity was normal but sensory action potentials were absent in the right median, ulnar and sural