



Update on the Genetics of Congenital Myopathies

Katarina Pelin, PhD,^{*,†} and Carina Wallgren-Pettersson, MD, PhD[†]

The congenital myopathies form a large clinically and genetically heterogeneous group of disorders. Currently mutations in at least 27 different genes have been reported to cause a congenital myopathy, but the number is expected to increase due to the accelerated use of next-generation sequencing methods. There is substantial overlap between the causative genes and the clinical and histopathologic features of the congenital myopathies. The mode of inheritance can be autosomal recessive, autosomal dominant or X-linked. Both dominant and recessive mutations in the same gene can cause a similar disease phenotype, and the same clinical phenotype can also be caused by mutations in different genes. Clear genotype-phenotype correlations are few and far between.

Semin Pediatr Neurol 29:12-22 © 2019 Elsevier Inc. All rights reserved.

Introduction

The application of next-generation sequencing methods, such as whole-exome sequencing, targeted gene panels, and whole-genome sequencing has resulted in an accelerated discovery of novel disease genes and disease-causing variants underlying the various types of congenital myopathies. Furthermore, the use of custom high-density oligonucleotide arrays for comparative genomic hybridization has enabled the discovery of large copy number variations (CNVs) causing, for example, nemaline myopathy and centronuclear myopathy.¹⁻³

The inheritance of congenital myopathies can be autosomal dominant, autosomal recessive or X-linked. De novo dominant disease-causing variants are common in some genes, for example, *ACTA1* and *TPM2*.^{4,5} Both dominant and recessive variants have been described in several genes, for example, *ACTA1*, *TPM2*, *TPM3*, *RYR1*, *MYH2*, and *TTN*.⁴⁻⁸ Interestingly, epigenetic silencing of a wild-type allele can result in

monoallelic expression of a mutant allele causing a congenital myopathy. This has been described for *RYR1* and core myopathies.⁹ Furthermore, it has been suggested that a common pathophysiological pathway caused by epigenetic changes is activated in some forms of congenital myopathies.¹⁰

Mutations in the same gene can result in more than 1 clinical phenotype, and the same clinical phenotype can result from mutations in several different genes.¹¹ There is also substantial variation in the severity of the clinical phenotype, even within 1 genetic entity, seldom with any discernible genotype-phenotype correlations.¹²

Nemaline Myopathies Including Cap Myopathy and Fiber-Type Disproportion

The clinical spectrum of nemaline myopathies (NM) is wide, ranging from severe congenital forms, sometimes already detectable in utero, through the typical form to milder childhood-onset and even adult-onset forms. Nemaline rods, derived from sarcomeric Z discs, and often type 1 fiber predominance, are characteristic pathological features of NM. Cap myopathy is pathologically characterised by cap-like structures of disorganised myofibrils and thickened Z discs, but usually no large rods.¹¹ Following the description of families and patients with variable presence of nemaline rods and/or caps,^{13,14} NM and cap myopathy are considered to be overlapping entities. Fiber-type disproportion (FTD), that is, type 1 hypotrophy in the

From the *Molecular and Integrative Biosciences Research Programme, Faculty of Biological and Environmental Sciences, University of Helsinki, Helsinki, Finland.

[†]The Folkhälsan Institute of Genetics, Folkhälsan Research Center, and Department of Medical and Clinical Genetics, University of Helsinki, Helsinki, Finland.

Supported in part by the Sigrid Jusélius Foundation, the Association Française contre les Myopathies grant no. 18761, the Finska Läkaresällskapet, Muscular Dystrophy UK grant no. 16NEM-PG36-0094, and the Medicinska understödsföreningen Liv och Hälsa.

Address reprint requests to Katarina Pelin, PhD, Faculty of Biological and Environmental Sciences, University of Helsinki, P.O.Box 56 (Viikinkaari 9), FI-00014 Helsinki, Finland. E-mail: Katarina.Pelin@helsinki.fi

presence of larger type 2 fibers, but in the absence of specific pathological features, may be caused by the same genes as NM and cap myopathy.¹¹ FTD and type 1 fiber predominance are common features in the other congenital myopathies also, caused by mutations in other genes.

Eleven NM-causing genes have been described to date^{15–25} (Fig., Table). Seven of these genes, that is, *ACTA1*, *NEB*, *TPM2*, *TPM3*, *TNNT1*, *LMOD3*, and *MYPN*, encode structural proteins of the skeletal muscle sarcomere, *CFL2* regulates actin filament dynamics and is essential for muscle maintenance, whereas three of the genes, that is, *KBTBD13*, *KLHL40*, and *KLHL41*, encode proteins involved in the maintenance of sarcomeric integrity by regulating turnover of sarcomeric proteins.

The Nebulin Gene (*NEB*)

Disease-causing variants in the nebulin gene (*NEB*) are the most common cause of autosomal recessive NM, accounting for approximately 50% of all NM cases, and the most common cause of the typical form. The majority of the patients are compound heterozygous for 2 different *NEB* mutations. Point mutations causing aberrant splicing, small indels causing frameshifts, and nonsense mutations are the most common mutation types in *NEB*.¹² A custom high-density oligonucleotide array, the NM-CGH array, has revealed several large, 1–143 kb, CNVs in *NEB*, including recurrent CNVs in the triplicate region spanning exons 82–105.^{1,26} Eight exons are repeated 3 times in the 32-kb triplicate (TRI) region of *NEB*, and the normal copy number is 6 (3 copies in each allele). Deletion or duplication of one TRI copy is non-pathogenic, but gains of 2 or more TRI copies segregate with NM in 4% of the families studied, and are, thus, interpreted to be pathogenic. The CNVs in the TRI region of *NEB* can currently be detected only using the NM-CGH-array.²⁶ We have estimated that a large pathogenic CNV in *NEB* is present in 10%–15% of NM patients.

Missense variants are very common in *NEB*. In the current release of the ExAC Browser (<http://exac.broadinstitute.org>), 63% of the variants in the coding region (including splice sites and UTRs) of *NEB* are missense, 24% are synonymous changes, and 4% are apparent pathogenic variants (nonsense, splice site, frameshift, indels). Most of the missense variants are rare, 76% of the variants being present in only 1–3 heterozygous carriers (allele frequencies well below 0.01). This makes the interpretation of the pathogenicity of missense variants extremely difficult. Our current recommendation is that only variants affecting conserved actin- and tropomyosin-binding sites in *NEB* can readily be considered as pathogenic, but all the others require functional studies for assessment of their pathogenicity. Actin- and tropomyosin-binding experiments may be used for this purpose.²⁷

In addition to the “classical” forms of NM, recessive disease-causing variants in *NEB* may cause distal nebulin myopathy without nemaline rods,²⁸ core-rod myopathy,²⁹ distal forms of NM,³⁰ and lethal multiple pterygium syndrome.³¹

To date, only 1 clearly dominant *NEB* variant has been found. It is a ~100 kb in-frame deletion spanning *NEB* exons 14–89 resulting in the expression of substantially smaller nebulin proteins, expected to have a dominant-negative effect. This variant segregates with a distal form of NM in a 3-generation Finnish family.

The Skeletal Muscle Alpha-Actin Gene (*ACTA1*)

According to our estimate, 23% of NM cases are caused by mutations in *ACTA1*. Most of the pathogenic variants in *ACTA1* are dominant (90%) missense variants, most often causing severe NM. Of the sporadic cases with *ACTA1* variants, approximately 85% have been shown to be caused by de novo missense variants. Autosomal recessive variants are rarer (10%), and result in null alleles (splice site, nonsense, frameshift, and some missense variants).³² Dominant variants inherited across

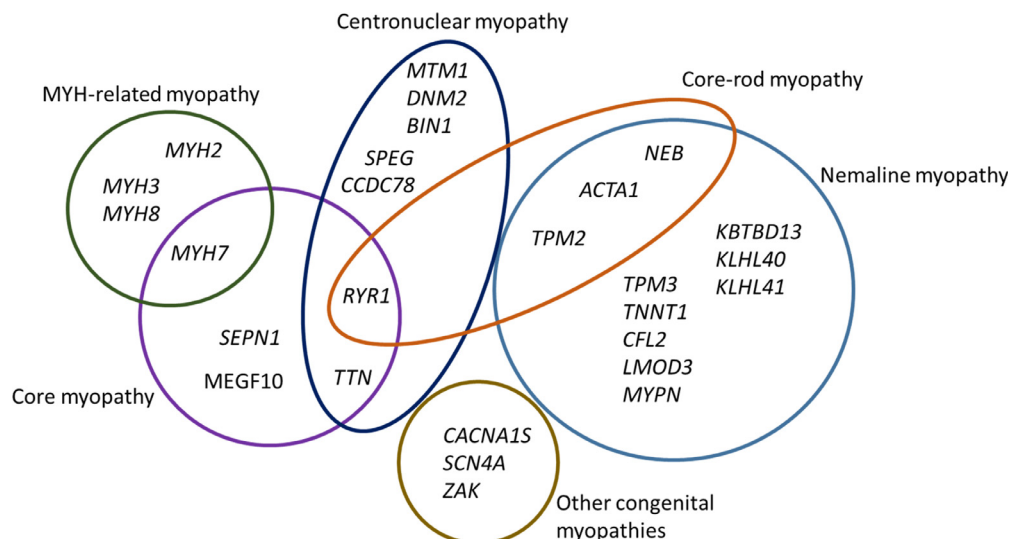


Figure Congenital myopathy-causing genes. The diagram shows 27 genes implicated in various forms of the congenital myopathies, and the overlap between different entities. Core-rod myopathy was included to illustrate the overlap between nemaline myopathy and core myopathy.

Table Genes Causing Congenital Myopathies

Disorder	Gene	Inheritance	Other Entities Caused by Mutations in the Gene
Nemaline myopathy	<i>NEB</i>	AR, AD*	Distal nemaline myopathy, distal nemaline myopathy, core-rod myopathy, lethal multiple pterygium syndrome
	<i>ACTA1</i>	de novo, AD, AR	Actin-accumulation myopathy, core-rod myopathy, intranuclear rod myopathy, zebra body myopathy, CFTD, progressive scapuloperoneal myopathy, distal nemaline myopathy
	<i>TPM3</i>	AD, de novo, AR	CFTD
	<i>TPM2</i>	AD, de novo, AR†	CFTD, core-rod myopathy, distal arthrogryposis, Escobar syndrome (AR)
	<i>TNNT1</i>	AR	
	<i>CFL2</i>	AR	
	<i>LMOD3</i>	AR	
	<i>MYPN</i>	AR	Cardiomyopathy
	<i>KBTD13</i>	AD	
	<i>KLHL40</i>	AR	
Core myopathy	<i>KLHL41</i>	AR	
	<i>RYR1</i>	AD, AR	Core-rod myopathy, CFTD, malignant hyperthermia, multi-minicore disease with ophthalmoplegia, arthrogryposis multiplex congenita
	<i>SEPN1</i>	AR	Rigid spine muscular dystrophy, CFTD, desmin-related myopathy with Mallory body-like inclusions, myofibrillar myopathy
	<i>TTN</i>	AR	TMD, LGMD2J, HMERF, adult-onset recessive proximal muscular dystrophy, Emery-Dreifuss-like phenotype without cardiomyopathy, cardiomyopathy
	<i>MYH7</i>	AD	Laing distal myopathy, CFTD, myosin storage myopathy (hyaline body myopathy), cardiomyopathy
	<i>MEGF10</i>	AR	
	<i>MTM1</i>	X-linked	
Centronuclear myopathy	<i>DNM2</i>	AD	CMTDIB, CMT2M
	<i>RYR1</i>	AR	See above
	<i>BIN1</i>	AR, AD	
	<i>TTN</i>	AR	See above
	<i>SPEG</i>	AR	
	<i>CCDC78</i>	AD	
MYH-related myopathy	<i>MYH2</i>	AD, AR	
	<i>MYH7</i>	AD	See above
	<i>MYH3</i>	AD	Distal arthrogryposis
	<i>MYH8</i>	AD	Distal arthrogryposis
Other congenital myopathies	<i>CACNA1S</i>	AD, AR	Hypokalemic periodic paralysis type 1, malignant hyperthermia
	<i>SCN4A</i>	AR	Hypokalemic periodic paralysis type 2, congenital myasthenic syndrome 16, myotonia congenita, paramyotonia congenita
	<i>ZAK</i>	AR	Split-foot malformation with mesoaxial polydactyly

AD, autosomal dominant; AR, autosomal recessive; CFTD, congenital fiber type disproportion; CMT, Charcot-Marie-Tooth neuropathy; HMERF, hereditary myopathy with early respiratory failure; LGMD, limb-girdle muscular dystrophy; TMD, tibial muscular dystrophy.

*Only 1 dominant *NEB* mutation has been identified to date.

†Only 1 recessive *TPM2* mutation has been identified to date.

2 or more generations have been identified in less than 5% of *ACTA1* families, while mosaicism has been observed in a few families.³²⁻³⁴ We have recently described a dominant *ACTA1* missense variant segregating in a 3-generation family with clinically variable NM, illustrating the clinical and histological variability of NM between patients sharing the same mutation.

In addition to NM, dominant, mostly de novo, disease-causing variants in *ACTA1* can cause actin-accumulation myopathy,³⁵ cap myopathy,³⁶ congenital fiber type disproportion,³⁷ core-rod myopathy,³⁸ intranuclear rod myopathy,^{39,40} zebra

body myopathy,⁴¹ progressive scapuloperoneal myopathy,⁴² and distal myopathy with nemaline rods.⁴³

The Alpha- and Beta-Tropomyosin Genes (*TPM3* and *TPM2*)

Mutations in *TPM3* and *TPM2* are relatively rare causes of NM, accounting for less than 10% of the cases. In addition to NM, mutations in *TPM3* and *TPM2* can cause cap myopathy, core-rod myopathy, congenital fiber type disproportion, distal

arthrogryposes, and Escobar syndrome.⁵ The majority of the mutations in both *TPM3* and *TPM2* are dominant missense variants or in-frame deletions removing one amino acid. A few recurrent mutations have been described in both genes; p.Lys7del and p.Glu139del in *TPM2*, and p.Arg168His, p.Arg168Cys, and p.Arg168Gly in *TPM3*. The mutations alter the conserved coiled-coil structure of the tropomyosins, resulting in aberrant tropomyosin-actin-binding.^{5,44}

Recessive mutations are more common in *TPM3* than in *TPM2*. In *TPM2* only 1 recessive homozygous nonsense mutation has been described, causing Escobar syndrome associated with NM.⁴⁵ In *TPM3*, a few recessive mutations, including nonsense, frameshift, and stop-lost mutations have been described.^{46–49} NMs caused by mutations in *TPM2* usually have milder presentations than NMs caused by mutations in *TPM3*.⁵ Recessive disease caused by mutations in these genes appears mostly to be severe. No clear correlation was found between the type of mutation and the clinical phenotype. Cap formation in the muscle biopsy may be seen in disorders caused by mutations in either gene, and type 1 fiber hypotrophy and predominance is common in both groups.⁵ Furthermore, we have identified a large, 17–21 kb homozygous deletion that removes the promoter and the first 2 exons of *TPM3*, causing a severe form of NM.²

The Troponin T1 Gene (*TNNT1*)

The first mutation in *TNNT1*, a recessive nonsense mutation causing a severe form of NM with tremor in the first months of life and contractures in the Old Order Amish, was described almost 20 years ago.¹⁸ Not until recently have a few other NM-causing mutations in *TNNT1* been identified, all showing recessive inheritance. Compound heterozygosity for a splice site mutation resulting in skipping of *TNNT1* exon 8, and an exon 14 deletion was identified in a Dutch patient with a similar clinical phenotype as in Amish NM.⁵⁰ A clinical phenotype similar to Amish NM was also observed in a Hispanic patient homozygous for a nonsense mutation (different from the Amish one) in *TNNT1*.⁵¹ Homozygosity for a complex indel mutation in *TNNT1* causing premature truncation of the protein has been described in 9 unrelated Palestinian patients with a severe form of NM.⁵²

The Cofilin-2 Gene (*CFL2*)

Recessive mutations in the *CFL2* gene are rare causes of NM. The first *CFL2* mutation was described in 2007. The homozygous missense mutation, p.Ala35Thr, was found to cause NM with some minicores in a large consanguineous family of Middle Eastern origin showing congenital onset, delayed milestones and no facial weakness or foot drop.²⁰ The second *CFL2* mutation was published in 2012. Again a homozygous missense mutation, in this case p.Val7Met, was found in 2 sisters of Iraqi Kurdish origin with axial and limb girdle weakness who were born to consanguineous parents. The sisters had NM with features of myofibrillar myopathy.⁵³ A third mutation described in *CFL2* is a homozygous 4 base pair deletion causing a frameshift, p.Lys34Glnfs*6. The mutation had caused a severe form of NM in a Saudi Arabian consanguineous family.⁵⁴

The Leiomodlin-3 Gene (*LMOD3*)

Recessive mutations in *LMOD3* have hitherto been described in 15 families with severe, often lethal forms of NM, which in some cases were associated with perinatal fractures.^{24,55} Most of the mutations are nonsense or frameshift variants causing loss of leiomodlin-3 protein expression. The patients were homozygous or compound heterozygous for the mutations.²⁴

The Myopalladin Gene (*MYPN*)

Recessive mutations in *MYPN* have been described in four families with childhood or adult-onset mild NM, and in 2 families with congenital slowly progressive cap myopathy.^{25,56} All *MYPN* mutations described to date are loss-of-function variants, either nonsense, frameshift or splice site variants, leading to no or very low expression of myopalladin in skeletal muscle. The patients are either homozygous or compound heterozygous for the mutations. Intranuclear rods, previously only associated with *ACTA1* mutations, were observed in the muscle biopsies of 2 of the patients with mild NM.²⁵ Interestingly, dominant *MYPN* mutations have been reported to cause dilated, familial hypertrophic or familial restrictive cardiomyopathy.^{57–59} Contrary to the NM- and cap myopathy-causing mutations, the cardiomyopathy-causing *MYPN* mutations lead to the expression of mutant proteins with dominant-negative effects in cardiomyocytes.⁵⁸

The Kelch Repeat- and BTB/POZ Domain-Containing Protein 13, the Kelch-Like 40 and the Kelch-Like 41 Genes (*KBTBD13*, *KLHL40*, and *KLHL41*)

KBTBD13, *KLHL40*, and *KLHL41* encode proteins of the Kelch superfamily including altogether 66 genes and 63 protein members.⁶⁰ *KBTBD13* interacts with Cullin 3 ubiquitin ligase, and this interaction is required for the formation of a functional Cul3 RING ubiquitin ligase complex, which is involved in the ubiquitination of proteins destined for degradation.⁶¹ Three different missense variants, p.Arg248Ser, p.Lys390Asn, and p.Arg408Cys in *KBTBD13* have been found to cause autosomal dominant NM with cores, and unusual clinical presentations including a characteristic slowness of movement.²¹

KLHL40 has been shown to bind and stabilize nebulin and *LMOD3* in the sarcomere, as well as prevent ubiquitination of *LMOD3*.⁶² Recessive mutations in *KLHL40* are a fairly common cause of severe NM, often with fetal akinesia or hypokinesia and contractures, fractures, respiratory failure, and swallowing difficulties at birth. Mutations in *KLHL40* account for up to 28% of severe cases of NM in the Japanese population due to a founder mutation, p.Glu528Lys.²² One patient with a mild form of NM has been reported to be homozygous for a missense mutation, p.Arg500Cys, in *KLHL40*.⁶³ This mutation has not been found in the severe cases published to date.^{22,64,65} Furthermore, one patient with severe NM due to compound heterozygous mutations in *KLHL40* showed prolonged beneficial response to treatment with high-dose acetylcholinesterase inhibitors (pyridostigmine).⁶⁶ Such a response

has also been observed in other congenital myopathies, for example, myotubular/centronuclear myopathy.⁶⁷

KLHL41 shows high homology to KLHL40, but KLHL41 preferentially stabilizes nebulin rather than LMOD3.⁶⁸ Five families with clinically different forms of NM have been found to have recessive mutations in *KLHL41*. Frameshift mutations correlated with severe phenotypes with neonatal death, whereas missense variants resulted in impaired motor function with survival into late childhood and/or early adulthood compatible with mild, typical or intermediate NM.²³

Core Myopathies

Central core disease, minicore myopathy, and multimicore disease are historical definitions of congenital myopathies with cores, that is, areas devoid of mitochondria and, thus, lack of oxidative enzyme activity in muscle biopsies. There is pathologic, clinical and genetic overlap in congenital myopathies with cores, and thus the term “core myopathy” is nowadays preferentially used.¹¹ Five genes have been reported to cause core myopathies. The ryanodine receptor 1 encoding gene, *RYR1*, was the first one to be discovered,^{69,70} and is now known as the major core myopathy-causing gene.⁷¹ The second most common core myopathy-causing gene, *SEPN1* encodes selenoprotein N.⁷² Occasional mutations causing core myopathies have also been described in the satellite cell gene *MEGF10*,⁷³ the titin gene *TTN*,⁷⁴ and the myosin heavy chain encoding gene *MYH7*⁷⁵ (Fig., Table).

The Ryanodine Receptor 1 Gene (*RYR1*)

RYR1 encodes the skeletal muscle specific ryanodine receptor RYR1, which is a calcium release channel involved in excitation-contraction coupling activating muscle contraction. Both dominant and recessive mutations in *RYR1* have been found to cause core myopathies, but also related disorders such as core-rod myopathy, congenital FTD and centronuclear myopathy, as well as malignant hyperthermia susceptibility.^{6,76}

RYR1 is a large gene with 106 exons encoding a polypeptide of 5037 amino acids, which forms the subunits of the tetramer calcium release channel. More than 200 *RYR1* mutations have been reported.^{77,78} Most mutations causing core myopathies and malignant hyperthermia are dominant missense variants changing conserved amino acids, many of them clustered in specific hotspot regions in the N-terminus, central region and in the C-terminal transmembrane region of RYR1.^{71,76} De novo dominant *RYR1* variants have been reported to cause core-rod myopathy.⁷⁹⁻⁸¹

Recessive *RYR1* mutations are widespread throughout the gene and patients with such mutations are generally more severely affected than those with a dominant mutation.^{82,83}

The recessive mutations include null mutations, but also combinations of missense variants. Among the recessive variants, one recurrent allele carrying 3 different missense variants (p.Ile1571Val, p.Arg3366His, and p.Tyr3933Cys) has been reported in the Dutch population, but it is unclear whether one of the variants is causative, or if a combination of 2 or all

3 variants cause disease. Furthermore, this 3 missense variant-carrying allele, as well as some other missense variants are associated with the malignant hyperthermia trait in heterozygous individuals, but cause recessive *RYR1*-related myopathies in homozygous or compound heterozygous individuals.⁸³

In addition to variants affecting a single or a few base pairs, 2 recessive large-scale *RYR1* deletions associated with myopathies have been published.^{84,85} The first one, an in-frame deletion of 54 out of 106 *RYR1* exons, was identified in a child with a congenital myopathy with lethal neonatal weakness and atypical histopathologic features. The child was compound heterozygous for the deletion and a single amino acid duplication.⁸⁴ The second large deletion starts in *RYR1* exon 91 and ends within exon 98, causing a frameshift. The deletion was detected in a family with recessive late-onset core myopathy, the patients being compound heterozygous for the deletion and a missense variant.⁸⁵ In addition, a recessive deletion of *RYR1* exons 70-71 has been described in a family with severe arthrogyrosis multiplex congenita.⁸⁶

Tissue-specific epigenetic silencing of the maternal *RYR1* allele has been documented in a cohort of patients with recessive core myopathies. Silencing of the maternal allele in skeletal muscle tissue unmasked the recessive paternal allele causing the disease.⁹

The Selenoprotein N Gene (*SEPN1*)

SEPN1 encodes selenoprotein N, which is an integral membrane glycoprotein of the endoplasmic reticulum. *SEPN1* is expressed at high levels in several human fetal tissues, and is thought to have a role in early muscle development.⁸⁷ *SEPN1* is physically associated with ryanodine receptors and modifies RYR channel activity.⁸⁸ Furthermore, it has recently been shown that *SEPN1* is a key component of redox-regulated calcium metabolism in the endoplasmic reticulum, through its interaction with the SERCA2 calcium pump.⁸⁹

Recessive loss-of-function mutations in *SEPN1* have caused entities termed rigid spine muscular dystrophy, core myopathy, congenital fiber type disproportion, and desmin-related myopathy with Mallory body-like inclusions.^{72,90,91} Due to the overlap of clinical and histopathologic features these disorders are now collectively referred to as *SEPN1*-related myopathies. All types of mutations have been identified in *SEPN1*, many being truncating nonsense or frameshift variants, but missense variants affecting conserved amino acids are also common. Homozygous mutations seem to be surprisingly prevalent, also in affected children born to non-consanguineous parents.^{92,93}

The Multiple EGF-Like Domain 10 Gene (*MEGF10*)

A recessive congenital myopathy with minicores has been described, caused by missense variants in *MEGF10*. Three siblings were compound heterozygous for 2 different missense variants, p.Cys326Arg and p.Cys774Arg in *MEGF10*.⁷³ *MEGF10* regulates myoblast function via the NOTCH signalling pathway,

and the interaction between MEGF10 and NOTCH1 is impaired by the p.Cys774Arg variant.⁹⁴

The Titin Gene (*TTN*)

The huge *TTN* gene with 363 exons encodes titin, the largest polypeptide in nature. One titin molecule reaches from the Z disc to the M line in the skeletal and cardiac muscle sarcomeres.^{95,96} Given the size of titin, it is not surprising that several clinically distinct disorders affecting skeletal and/or cardiac muscle are caused by dominant or recessive mutations in *TTN*.⁸ Most of these disorders have adult onset. However, five patients from 2 families with congenital muscle weakness, minicore-like lesions and abundant centrally located nuclei, and severe childhood-onset dilated cardiomyopathy were found to be homozygous for truncating mutations in the C-terminus of *TTN*. The parents were consanguineous in both families.⁹⁷ Furthermore, in a cohort of 31 patients with congenital core myopathy combined with primary heart disease, 7 pathogenic *TTN* variants were identified in 5 patients from 4 families. The variants included missense and truncating mutations. The patients were homozygous or compound heterozygous for the mutations.⁷⁴

The Myosin Heavy Chain 7 Gene (*MYH7*)

The majority of the more than 500 missense mutations identified in the slow skeletal muscle fiber myosin heavy chain encoding gene *MYH7* cause cardiomyopathy.⁹⁸ A subset of the mutations cause skeletal muscle disease, including Laing distal myopathy and myosin storage myopathy.⁹⁹ More recently mutations in *MYH7* have been reported in dominant core myopathies.^{75,100} Cullup et al. described 4 patients from 2 families affected by multimicore disease caused by novel dominant missense mutations in *MYH7*.⁷⁵ Romero et al described four patients in a 3-generation family with autosomal dominant central core disease. They identified a novel missense mutation in *MYH7* that segregated with the disease in the family.¹⁰⁰ The mutations identified in these families are located in the *MYH7* tail region, close to previously described mutations causing Laing distal myopathy.

Centronuclear Myopathies

Centrally located nuclei in the muscle fibers are hallmarks of centronuclear (myotubular) myopathies (CNM), but some muscle biopsies may also show additional pathological features such as type 1 fiber predominance, type 1 fiber hypotrophy, and cores. The most common genes causing centronuclear myopathies are *MTM1*, *DNM2*, *RYR1*, and *TTN*. Minor causative genes are *BINI*, *CCDC78*, and *SPEG*¹¹ (Fig., Table). *RYR1* and *TTN* variants identified in CNM will be discussed briefly below. The other CNM genes will be the focus of separate paragraphs.

Mutations in *RYR1* have turned out to be a fairly common cause of autosomal recessive CNM (ARCNM). The patients are usually compound heterozygous for 2 mutations, often

one truncating mutation on one allele and a missense one on the other allele. The mutations are spread all across the *RYR1* gene. Some of the *RYR1* mutations found in ARCNM patients have previously been reported in core myopathy or malignant hyperthermia susceptibility.^{101–104}

Compound heterozygous truncating mutations causing ARCNM have also been identified in the *TTN* gene. To date, 7 unrelated patients with ARCNM due to mutations in *TTN* have been described.^{103,105,106} The CNM-causing mutations are spread all along the *TTN* gene. One of the mutations has previously been reported to cause tibial muscular dystrophy, and another caused adult-onset cardiomyopathy in the heterozygous state.¹⁰⁵

The Myotubularin Gene (*MTM1*)

Mutations in *MTM1*, encoding myotubularin, a ubiquitously expressed lipid phosphatase, cause X-linked myotubular myopathy (XLMTM).¹⁰⁷ Myotubularin colocalizes with *RYR1* at the junctional sarcoplasmic reticulum in skeletal muscle, and it is a key regulator of sarcoplasmic reticulum remodelling together with its lipid substrate phosphatidylinositol 3-monophosphate (PtdIns3P). Lack of *MTM1* activity leads to disorganisation of the sarcoplasmic reticulum, which is considered to be the primary cause of most of the organelle positioning defects observed in muscles biopsies from XLMTM patients.¹⁰⁸

The XLMTM-causing mutations in *MTM1* are loss-of-function mutations spread across the 15 exons of the gene. The majority of the patients are neonatally severely affected boys. Most mutations are truncating, but missense variants affecting conserved amino acids essential for *MTM1* activity are common also.^{109,110} A few large deletions removing one or more *MTM1* exons, as well as whole-gene deletions of *MTM1* including neighbouring genes have been reported. The latter causes contiguous gene syndromes.^{3,109} Several different types of *MTM1* pre-mRNA splicing affecting mutations have also been described.^{109,111,112} Germ line mosaicism for de novo *MTM1* mutations has been documented in a few families, in some cases manifesting as paternal transmission of the X-linked pathogenic variant.^{109,113}

Evidence is accumulating that there is a higher number of females manifesting XLMTM than previously anticipated.^{3,114} Females with XLMTM are usually less severely affected than males, but the clinical phenotype is highly variable in age of onset and severity. The most severely affected females can show a similar clinical course as a severely affected XLMTM male. In general, those *MTM1* mutations that cause a severe phenotype in males, cause a milder phenotype in females, probably due to the normal pattern of approximately 50-50 X-chromosome inactivation in females. However, there is an increased prevalence of highly skewed X-chromosome inactivation in females affected by XLMTM, although it has not been possible to determine which of the X chromosomes is preferentially inactivated.¹¹⁴ Not all manifesting females show any skew, even in muscle tissue.

Interestingly, dynamin 2 (*DNM2*) expression levels are increased in the muscles of XLMTM patients, as well as in *MTM1* knock-out mice, indicating that *MTM1* may be a

negative regulator of DNM2 expression.¹¹⁵ This finding has led to the development of a potential therapeutic approach aiming towards reducing DNM2 levels in the muscles of XLMTM patients. Proof-of-principle has been achieved with antisense oligonucleotide-mediated *DNM2* knockdown in a mouse model for XLMTM.¹¹⁶

The Dynamin 2 Gene (*DNM2*)

DNM2 encodes dynamin 2, a large GTPase involved in diverse cellular processes, among others endocytosis, cytokinesis, phagocytosis, and cell migration. Mutations in *DNM2* cause autosomal dominant ADCNM with onset usually in adolescence or early childhood, with ptosis, distal weakness and contractures, and often radial strands in muscle fibers on biopsy, and Charcot-Marie-Tooth (CMT) peripheral neuropathy (CMTDIB and CMT2M).^{117–119} However, cases with earlier onset have been reported due to de novo mutations in the pleckstrin homology domain of *DNM2*.¹²⁰ The ADCNM-causing mutations in *DNM2* are gain-of-function mutations, predominantly missense variants. One in-frame deletion of one amino acid, as well as one splice site mutation causing an in-frame deletion of three amino acids in addition to an in-frame insertion of 23 new amino acids have been identified. Many of the missense variants are recurrent and present in several unrelated families. The mutations causing ADCNM are distinct from the ones causing CMT.¹¹⁹

Functional studies of common ADCNM *DNM2* mutations show abnormal self-assembly of mutant *DNM2* resulting in abnormally high GTPase activity of the protein, which in turn leads to T-tubule fragmentation.¹²¹ The hyperactive mutant *DNM2* protein is a potential therapeutic target in ADCNM, that is, downregulation of *DNM2* activity should have a similar beneficial effect in ADCNM muscle as in XLMTM muscle.^{116,121}

The Bridging Integrator 1 Gene (*BIN1*)

BIN1 encodes for amphiphysin 2, a protein involved in membrane tubulation. The membrane tubulation activity of *BIN1* is enhanced by its interaction with MTM1.¹²² Nicot et al described the first disease-causing variants in *BIN1* 10 years ago. Two missense variants and 1 nonsense variant were shown to cause ARCNM with congenital or childhood onset in 3 consanguineous families. The patients were homozygous for the mutations.¹²³ Subsequently, 1 novel homozygous missense mutation and 1 novel homozygous nonsense mutation have been published as causative for ARCNM.^{124,125} Furthermore, a homozygous acceptor splice site mutation in intron 10 causing abnormal splicing of the skeletal muscle-specific *BIN1* exon 11 was identified in patients with rapidly progressive ARCNM in 1 consanguineous family. The corresponding splice site was found to be mutated in canine Inherited Myopathy of Great Danes, which, thus, represents a mammalian model for *BIN1*-related CNM.¹²⁶

Dominant mutations in *BIN1* have been reported to cause mild and adult-onset forms of CNM.^{127,128} Three of the mutations are single base pair deletions in the stop codon of

BIN1, causing read-through and extension of the protein with 52 novel amino acids. Two other dominant mutations were 1 in-frame deletion of 1 amino acid, and 1 missense mutation, located in the N-terminus of *BIN1*.¹²⁷ A second dominant missense mutation, also in the N-terminus, was recently published.¹²⁸ The dominant *BIN1* mutations are distinct from the recessive ones, with different impacts on protein function, suggesting different pathomechanisms for dominant and recessive *BIN1*-related CNM.¹²⁷

The SPEG Complex Locus Gene (*SPEG*)

SPEG interacts with myotubularin at the junctional sarcoplasmic reticulum in skeletal muscle. *SPEG* is also expressed in cardiac muscle. The first *SPEG* mutations were described in 6 CNM patients from 3 families. In addition to CNM, 2 unrelated patients had dilated cardiomyopathy. The mutations were recessive loss-of-function mutations (nonsense or frameshifts), and the patients were compound heterozygous or homozygous for the mutations.¹²⁹ Two novel *SPEG* mutations were recently reported in 2 unrelated CNM patients. One of the patients had dilated cardiomyopathy also. The patient with CNM and cardiomyopathy was homozygous for a nonsense mutation, and the patient with CNM without cardiac involvement was homozygous for a frameshift mutation in *SPEG*.¹³⁰

The Coiled-Coil Domain-Containing Protein 78 Gene (*CCDC78*)

Only 1 dominant mutation in *CCDC78* causing CNM with atypical cores has been described in 1 family with patients in 3 generations. The mutation changes the acceptor splice site of intron 1 in *CCDC78*, causing retention of the intron, which is in-frame with the coding sequence. This is predicted to result in the addition of 74 amino acids to the protein.¹³¹

Myosin-Related Myopathies

Myosin heavy-chain genes, especially *MYH7*, *MYH2*, *MYH3*, and *MYH8* are implicated in various myopathies affecting skeletal and/or cardiac muscle (Fig., Table). Some of these myopathies are congenital. *MYH7* was already discussed in the context of the core myopathies, but dominant mutations in *MYH7* can also cause, for example, congenital fiber type disproportion without any other specific histological features. One such case was recently reported to be due to a de novo heterozygous splice site mutation causing skipping of *MYH7* exon 38.¹³² A few cases of *MYH7*-related congenital myopathy were also found in a cohort of Italian patients. These patients had dominant missense mutations in *MYH7*.¹³³

Both dominant and recessive mutations in *MYH2* can cause a usually mild congenital myopathy with external ophthalmoplegia. The dominant cases are caused by missense mutations, and the recessive ones usually by truncating mutations in *MYH2*.⁷ A homozygous splice site mutation causing skipping of *MYH2* exon 12, leading to a frameshift,

was recently reported in a consanguineous family where 4 patients had a congenital myopathy with ophthalmoplegia.¹³⁴ A novel homozygous frameshift mutation in *MYH2* has also recently been described to cause a congenital myopathy with chronic aspiration pneumonia in infancy.¹³⁵

MYH3 and *MYH8* encode embryonic and fetal myosin heavy-chain isoforms. Dominant missense mutations in *MYH3* and *MYH8* cause distal arthrogryposis syndromes, probably as the result of a severe muscle weakness already during fetal development.^{7,136,137}

Other Genes Causing Congenital Myopathies

Two genes, *CACNA1S* and *SCN4A*, previously known channelopathy-causing genes, have now been implicated in congenital myopathies as well.^{138–141} A third gene, *ZAK*, has also recently been identified as a novel congenital myopathy-causing gene¹⁴² (Fig., Table).

A dihydropyridine receptor (DHPR) congenital myopathy caused by dominant or recessive mutations in the *CACNA1S* gene was recently described in 11 patients from 7 families. The muscle biopsies showed features of centralised nuclei, focal zones of sarcomeric disorganisation, and cores. DHPR directly regulates the RYR1 calcium release channel. Both the dominant and recessive mutations identified in *CACNA1S* are hypothesised to cause a decrease in overall DHPR function in skeletal muscle.¹³⁸

Recessive loss-of-function mutations in the *SCN4A* gene encoding the alpha-subunit of the skeletal muscle voltage-gated sodium channel (Na_v1.4) have been identified in patients from 8 families with a congenital myopathy of variable severity, severe or “classical.” Histological features were unspecific; abnormal fiber size variability, in some with type I predominance, and no pathognomic findings.^{139–141} Partial loss-of-function mutations were associated with a milder disease phenotype.¹⁴⁰

A congenital myopathy with fiber type disproportion caused by recessive loss-of-function mutations in the mitogen-activated protein triple kinase encoding gene, *ZAK*, was recently reported in six patients from three families. The patients were homozygous for frameshift or nonsense mutations in *ZAK*. The parents were consanguineous in all families. All mutations are located in the kinase domain of *ZAK*.¹⁴² Interestingly, in 2 families recessive mutations in the SAM domain of *ZAK* have been associated with split-foot malformation with mesoaxial polydactyly.¹⁴³

Conclusions

Here we have described 27 different genes implicated in various forms of the congenital myopathies. It is clear that the number of genes will increase due to the accelerated use of next-generation sequencing methods. Moreover, large CNVs and rearrangements are likely to be discovered as causative mutation types in many more disorders than those currently known.

References

- Kiiski K, Laari L, Lehtokari VL, et al: Targeted array comparative genomic hybridization—A new diagnostic tool for the detection of large copy number variations in nemaline myopathy-causing genes. *Neuromuscul Disord* 23:56-65, 2013
- Kiiski K, Lehtokari VL, Manzur AY, et al: A large deletion affecting TPM3, causing severe nemaline myopathy. *J Neuromuscul Dis* 2:433-438, 2015
- Savarese M, Musumeci O, Giugliano T, et al: Novel findings associated with MTM1 suggest a higher number of female symptomatic carriers. *Neuromuscul Disord* 26:292-299, 2016
- Nowak KJ, Ravenscroft G, Laing NG: Skeletal muscle alpha-actin diseases (actinopathies): Pathology and mechanisms. *Acta Neuropathol* 125:19-32, 2013
- Marttila M, Lehtokari VL, Marston S, et al: Mutation update and genotype-phenotype correlations of novel and previously described mutations in TPM2 and TPM3 causing congenital myopathies. *Hum Mutat* 35:779-790, 2014
- Hwang JH, Zorzato F, Clarke NF, et al: Mapping domains and mutations on the skeletal muscle ryanodine receptor channel. *Trends Mol Med* 18:644-657, 2012
- Tajsharghi H, Oldfors A: Myosinopathies: Pathology and mechanisms. *Acta Neuropathol* 125:3-18, 2013
- Savarese M, Sarparanta J, Vihola A, et al: Increasing role of titin mutations in neuromuscular disorders. *J Neuromuscul Dis* 3:293-308, 2016
- Zhou H, Brockington M, Jungbluth H, et al: Epigenetic allele silencing unveils recessive RYR1 mutations in core myopathies. *Am J Hum Genet* 79:859-868, 2006
- Rokach O, Sekulic-Jablanovic M, Voermans N, et al: Epigenetic changes as a common trigger of muscle weakness in congenital myopathies. *Hum Mol Genet* 24:4636-4647, 2015
- Sewry CA, Wallgren-Pettersson C: Myopathology in congenital myopathies. *Neuropathol Appl Neurobiol* 43:5-23, 2017
- Lehtokari VL, Kiiski K, Sandaradura SA, et al: Mutation update: The spectra of nebulin variants and associated myopathies. *Hum Mutat* 35:1418-1426, 2014
- Lehtokari VL, Ceuterick-de Groote C, de Jonghe P, et al: Cap disease caused by heterozygous deletion of the beta-tropomyosin gene TPM2. *Neuromuscul Disord* 17:433-442, 2007
- Tajsharghi H, Ohlsson M, Lindberg C, et al: Congenital myopathy with nemaline rods and cap structures caused by a mutation in the beta-tropomyosin gene (TPM2). *Arch Neurol* 64:1334-1338, 2007
- Laing NG, Wilton SD, Akkari PA, et al: A mutation in the alpha tropomyosin gene TPM3 associated with autosomal dominant nemaline myopathy NEM1. *Nat Genet* 24:75-79, 1995
- Nowak KJ, Wattanasirichaigoon D, Goebel HH, et al: Mutations in the skeletal muscle alpha-actin gene in patients with actin myopathy and nemaline myopathy. *Nat Genet* 23:208-212, 1999
- Pelin K, Hilpela P, Donner K, et al: Mutations in the nebulin gene associated with autosomal recessive nemaline myopathy. *Proc Natl Acad Sci U S A* 96:2305-2310, 1999
- Johnston JJ, Kelley RI, Crawford TO, et al: A novel nemaline myopathy in the Amish caused by a mutation in troponin T1. *Am J Hum Genet* 67:814-821, 2000
- Donner K, Ollikainen M, Ridanpaa M, et al: Mutations in the beta-tropomyosin (TPM2) gene—A rare cause of nemaline myopathy. *Neuromuscul Disord* 12:151-158, 2002
- Agrawal PB, Greenleaf RS, Tomczak KK, et al: Nemaline myopathy with minicores caused by mutation of the CFL2 gene encoding the skeletal muscle actin-binding protein, cofilin-2. *Am J Hum Genet* 80:162-167, 2007
- Sambuughin N, Yau KS, Olive M, et al: Dominant mutations in KBTBD13, a member of the BTB/Kelch family, cause nemaline myopathy with cores. *Am J Hum Genet* 87:842-847, 2010
- Ravenscroft G, Miyatake S, Lehtokari VL, et al: Mutations in KLHL40 are a frequent cause of severe autosomal-recessive nemaline myopathy. *Am J Hum Genet* 93:6-18, 2013
- Gupta VA, Ravenscroft G, Shaheen R, et al: Identification of KLHL41 mutations implicates BTB-Kelch-mediated ubiquitination as an

- alternate pathway to myofibrillar disruption in nemaline myopathy. *Am J Hum Genet* 93:1108-1117, 2013
24. Yuen M, Sandaradura SA, Dowling JJ, et al: Leiomodlin-3 dysfunction results in thin filament disorganization and nemaline myopathy. *J Clin Invest* 124:4693-4708, 2014
 25. Miyatake S, Mitsuhashi S, Hayashi YK, et al: Biallelic mutations in MYPN, encoding myopalladin, are associated with childhood-onset, slowly progressive nemaline myopathy. *Am J Hum Genet* 100:169-178, 2017
 26. Kiiski K, Lehtokari VL, Loytynoja A, et al: A recurrent copy number variation of the NEB triplicate region: Only revealed by the targeted nemaline myopathy CGH array. *Eur J Hum Genet* 24:574-580, 2016
 27. Marttila M, Hanif M, Lemola E, et al: Nebulin interactions with actin and tropomyosin are altered by disease-causing mutations. *Skelet Muscle* 4, 2014. 15-5040-4-15. eCollection 2014
 28. Wallgren-Pettersson C, Lehtokari VL, Kalimo H, et al: Distal myopathy caused by homozygous missense mutations in the nebulin gene. *Brain* 130:1465-1476, 2007
 29. Romero NB, Lehtokari VL, Quijano-Roy S, et al: Core-rod myopathy caused by mutations in the nebulin gene. *Neurology* 73:1159-1161, 2009
 30. Lehtokari VL, Pelin K, Herczegfalvi A, et al: Nemaline myopathy caused by mutations in the nebulin gene may present as a distal myopathy. *Neuromuscul Disord* 21:556-562, 2011
 31. Abdalla E, Ravenscroft G, Zayed L, et al: Lethal multiple pterygium syndrome: A severe phenotype associated with a novel mutation in the nebulin gene. *Neuromuscul Disord* 27:537-541, 2017
 32. Laing NG, Dye DE, Wallgren-Pettersson C, et al: Mutations and polymorphisms of the skeletal muscle alpha-actin gene (ACTA1). *Hum Mutat* 30:1267-1277, 2009
 33. Witting N, Werlauff U, Duno M, et al: Prevalence and phenotypes of congenital myopathy due to alpha-actin 1 gene mutations. *Muscle Nerve* 53:388-393, 2016
 34. Seidahmed MZ, Salih MA, Abdelbasit OB, et al: Gonadal mosaicism for ACTA1 gene masquerading as autosomal recessive nemaline myopathy. *Am J Med Genet A* 170:2219-2221, 2016
 35. Sparrow JC, Nowak KJ, Durling HJ, et al: Muscle disease caused by mutations in the skeletal muscle alpha-actin gene (ACTA1). *Neuromuscul Disord* 13:519-531, 2003
 36. Hung RM, Yoon G, Hawkins CE, et al: Cap myopathy caused by a mutation of the skeletal alpha-actin gene ACTA1. *Neuromuscul Disord* 20:238-240, 2010
 37. Laing NG, Clarke NF, Dye DE, et al: Actin mutations are one cause of congenital fibre type disproportion. *Ann Neurol* 56:689-694, 2004
 38. Kaïndl AM, Ruschendorf F, Krause S, et al: Missense mutations of ACTA1 cause dominant congenital myopathy with cores. *J Med Genet* 41:842-848, 2004
 39. Goebel HH, Warlo I: Nemaline myopathy with intranuclear rods—Intranuclear rod myopathy. *Neuromuscul Disord* 7:13-19, 1997
 40. Domazetovska A, Ilkovski B, Kumar V, et al: Intranuclear rod myopathy: Molecular pathogenesis and mechanisms of weakness. *Ann Neurol* 62:597-608, 2007
 41. Sewry CA, Holton JL, Dick DJ, et al: Zebra body myopathy is caused by a mutation in the skeletal muscle actin gene (ACTA1). *Neuromuscul Disord* 25:388-391, 2015
 42. Zukosky K, Meilleur K, Traynor BJ, et al: Association of a novel ACTA1 mutation with a dominant progressive scapulooperoneal myopathy in an extended family. *JAMA Neurol* 72:689-698, 2015
 43. Liewluck T, Sorenson EJ, Walkiewicz MA, et al: Autosomal dominant distal myopathy due to a novel ACTA1 mutation. *Neuromuscul Disord* 27:742-746, 2017
 44. Marttila M, Lemola E, Wallefeld W, et al: Abnormal actin binding of aberrant beta-tropomyosins is a molecular cause of muscle weakness in TPM2-related nemaline and cap myopathy. *Biochem J* 442:231-239, 2012
 45. Monnier N, Lunardi J, Marty I, et al: Absence of beta-tropomyosin is a new cause of Escobar syndrome associated with nemaline myopathy. *Neuromuscul Disord* 19:118-123, 2009
 46. Tan P, Briner J, Boltshauser E, et al: Homozygosity for a nonsense mutation in the alpha-tropomyosin slow gene TPM3 in a patient with severe infantile nemaline myopathy. *Neuromuscul Disord* 9:573-579, 1999
 47. Wattanasirichaigoon D, Swoboda KJ, Takada F, et al: Mutations of the slow muscle alpha-tropomyosin gene, TPM3, are a rare cause of nemaline myopathy. *Neurology* 59:613-617, 2002
 48. Lawlor MW, Dechene ET, Roumm E, et al: Mutations of tropomyosin 3 (TPM3) are common and associated with type 1 myofiber hypotrophy in congenital fiber type disproportion. *Hum Mutat* 31:176-183, 2010
 49. Lehtokari VL, Pelin K, Donner K, et al: Identification of a founder mutation in TPM3 in nemaline myopathy patients of Turkish origin. *Eur J Hum Genet* 16:1055-1061, 2008
 50. van der Pol WL, Leijenaar JF, Spliet WG, et al: Nemaline myopathy caused by TNNT1 mutations in a Dutch pedigree. *Mol Genet Genomic Med* 2:134-137, 2014
 51. Marra JD, Engelstad KE, Ankala A, et al: Identification of a novel nemaline myopathy-causing mutation in the troponin T1 (TNNT1) gene: A case outside of the old order Amish. *Muscle Nerve* 51:767-772, 2015
 52. Abdulhaq UN, Daana M, Dor T, et al: Nemaline body myopathy caused by a novel mutation in troponin T1 (TNNT1). *Muscle Nerve* 53:564-569, 2016
 53. Ockeloen CW, Gilhuis HJ, Pfundt R, et al: Congenital myopathy caused by a novel missense mutation in the CFL2 gene. *Neuromuscul Disord* 22:632-639, 2012
 54. Ong RW, ALSaman A, Selcen D, et al: Novel cofilin-2 (CFL2) four base pair deletion causing nemaline myopathy. *J Neurol Neurosurg Psychiatry* 85:1058-1060, 2014
 55. Abbott M, Jain M, Pferdehirt R, et al: Neonatal fractures as a presenting feature of LMOD3-associated congenital myopathy. *Am J Med Genet* 173A:2789-2794, 2017
 56. Lomage X, Malfatti E, Cheraud C, et al: Recessive MYPN mutations cause cap myopathy with occasional nemaline rods. *Ann Neurol* 81:467-473, 2017
 57. Duboscq-Bidot L, Xu P, Charron P, et al: Mutations in the Z-band protein myopalladin gene and idiopathic dilated cardiomyopathy. *Cardiovasc Res* 77:118-125, 2008
 58. Purevjav E, Arimura T, Augustin S, et al: Molecular basis for clinical heterogeneity in inherited cardiomyopathies due to myopalladin mutations. *Hum Mol Genet* 21:2039-2053, 2012
 59. Meyer T, Ruppert V, Ackermann S, et al: Novel mutations in the sarcomeric protein myopalladin in patients with dilated cardiomyopathy. *Eur J Hum Genet* 21:294-300, 2013
 60. Gupta VA, Beggs AH: Kelch proteins: Emerging roles in skeletal muscle development and diseases. *Skelet Muscle* 4, 2014. 11-5040-4-11. eCollection 2014
 61. Sambuughin N, Swietnicki W, Techtman S, et al: KBTBD13 interacts with Cullin 3 to form a functional ubiquitin ligase. *Biochem Biophys Res Commun* 421:743-749, 2012
 62. Garg A, O'Rourke J, Long C, et al: KLHL40 deficiency destabilizes thin filament proteins and promotes nemaline myopathy. *J Clin Invest* 124:3529-3539, 2014
 63. Seferian AM, Malfatti E, Bosson C, et al: Mild clinical presentation in KLHL40-related nemaline myopathy (NEM 8). *Neuromuscul Disord* 26:712-716, 2016
 64. Chen TH, Tian X, Kuo PL, et al: Identification of KLHL40 mutations by targeted next-generation sequencing facilitated a prenatal diagnosis in a family with three consecutive affected fetuses with fetal akinesia deformation sequence. *Prenat Diagn* 36:1135-1138, 2016
 65. Todd EJ, Yau KS, Ong R, et al: Next generation sequencing in a large cohort of patients presenting with neuromuscular disease before or at birth. *Orphanet J Rare Dis* 10, 2015. 148-015-0364-0
 66. Natera-de Benito D, Nascimento A, Abicht A, et al: KLHL40-related nemaline myopathy with a sustained, positive response to treatment with acetylcholinesterase inhibitors. *J Neurol* 263:517-523, 2016
 67. Robb SA, Sewry CA, Dowling JJ, et al: Impaired neuromuscular transmission and response to acetylcholinesterase inhibitors in centronuclear myopathies. *Neuromuscul Disord* 21:379-386, 2011
 68. Ramirez-Martinez A, Cenik BK, Bezprozvannaya S, et al: KLHL41 stabilizes skeletal muscle sarcomeres by nonproteolytic ubiquitination. *Elife* 6. <https://doi.org/10.7554/eLife.26439>, 2017
 69. Quane KA, Healy JM, Keating KE, et al: Mutations in the ryanodine receptor gene in central core disease and malignant hyperthermia. *Nat Genet* 5:51-55, 1993

70. Zhang Y, Chen HS, Khanna VK, et al: A mutation in the human ryanodine receptor gene associated with central core disease. *Nat Genet* 5:46-50, 1993
71. McCarthy TV, Quane KA, Lynch PJ: Ryanodine receptor mutations in malignant hyperthermia and central core disease. *Hum Mutat* 15: 410-417, 2000
72. Ferreiro A, Quijano-Roy S, Pichereau C, et al: Mutations of the selenoprotein N gene, which is implicated in rigid spine muscular dystrophy, cause the classical phenotype of multimimicore disease: Reassessing the nosology of early-onset myopathies. *Am J Hum Genet* 71:739-749, 2002
73. Boyden SE, Mahoney LJ, Kawahara G, et al: Mutations in the satellite cell gene MEGF10 cause a recessive congenital myopathy with mimicores. *Neurogenetics* 13:115-124, 2012
74. Chauveau C, Bonnemann CG, Julien C, et al: Recessive TTN truncating mutations define novel forms of core myopathy with heart disease. *Hum Mol Genet* 23:980-991, 2014
75. Cullup T, Lamont PJ, Cirak S, et al: Mutations in MYH7 cause Multimimicore Disease (MmD) with variable cardiac involvement. *Neuromuscul Disord* 22:1096-1104, 2012
76. Davis MR, Haan E, Jungbluth H, et al: Principal mutation hotspot for central core disease and related myopathies in the C-terminal transmembrane region of the RYR1 gene. *Neuromuscul Disord* 13:151-157, 2003
77. Jungbluth H, Sewry CA, Muntoni F: Core myopathies. *Semin Pediatr Neurol* 18:239-249, 2011
78. Lillis S, Abbs S, Mueller CR, et al: Clinical utility gene card for: Central core disease. *Eur J Hum Genet* 20. <https://doi.org/10.1038/ejhg.2011.179>, 2012. Epub 2011 Oct 12
79. Scacheri PC, Hoffman EP, Fratkin JD, et al: A novel ryanodine receptor gene mutation causing both cores and rods in congenital myopathy. *Neurology* 55:1689-1696, 2000
80. von der Hagen M, Kress W, Hahn G, et al: Novel RYR1 missense mutation causes core rod myopathy. *Eur J Neurol* 15:e31-e32, 2008
81. Hernandez-Lain A, Husson I, Monnier N, et al: De novo RYR1 heterozygous mutation (I4898T) causing lethal core-rod myopathy in twins. *Eur J Med Genet* 54:29-33, 2011
82. Zhou H, Jungbluth H, Sewry CA, et al: Molecular mechanisms and phenotypic variation in RYR1-related congenital myopathies. *Brain* 130:2024-2036, 2007
83. Snoeck M, van Engelen BG, Kusters B, et al: RYR1-related myopathies: A wide spectrum of phenotypes throughout life. *Eur J Neurol* 22: 1094-1112, 2015
84. Monnier N, Laquerriere A, Marret S, et al: First genomic rearrangement of the RYR1 gene associated with an atypical presentation of lethal neonatal hypotonia. *Neuromuscul Disord* 19:680-684, 2009
85. Remiche G, Kadhim H, Abramowicz M, et al: A novel large deletion in the RYR1 gene in a Belgian family with late-onset and recessive core myopathy. *Neuromuscul Disord* 25:397-402, 2015
86. Laquerriere A, Maluenda J, Camus A, et al: Mutations in CNTNAP1 and ADCY6 are responsible for severe arthrogyriposis multiplex congenita with axoglial defects. *Hum Mol Genet* 23:2279-2289, 2014
87. Petit N, Lescure A, Rederstorff M, et al: Selenoprotein N: An endoplasmic reticulum glycoprotein with an early developmental expression pattern. *Hum Mol Genet* 12:1045-1053, 2003
88. Juryneec MJ, Xia R, Mackrill JJ, et al: Selenoprotein N is required for ryanodine receptor calcium release channel activity in human and zebrafish muscle. *Proc Natl Acad Sci U S A* 105:12485-12490, 2008
89. Marino M, Stoilova T, Giorgi C, et al: SEPNI, an endoplasmic reticulum-localized selenoprotein linked to skeletal muscle pathology, counteracts hyperoxidation by means of redox-regulating SERCA2 pump activity. *Hum Mol Genet* 24:1843-1855, 2015
90. Ferreiro A, Ceuterick-de Groote C, Marks JJ, et al: Desmin-related myopathy with Mallory body-like inclusions is caused by mutations of the selenoprotein N gene. *Ann Neurol* 55:676-686, 2004
91. Clarke NF, Kidson W, Quijano-Roy S, et al: SEPNI: Associated with congenital fiber-type disproportion and insulin resistance. *Ann Neurol* 59:546-552, 2006
92. Scoto M, Cirak S, Mein R, et al: SEPNI-related myopathies: Clinical course in a large cohort of patients. *Neurology* 76:2073-2078, 2011
93. Ardisson A, Bragato C, Blasevich F, et al: SEPNI-related myopathy in three patients: Novel mutations and diagnostic clues. *Eur J Pediatr* 175:1113-1118, 2016
94. Saha M, Mitsuhashi S, Jones MD, et al: Consequences of MEGF10 deficiency on myoblast function and Notch1 interactions. *Hum Mol Genet* 26:2984-3000, 2017
95. Kolmerer B, Witt CC, Freiburg A, et al: The titin cDNA sequence and partial genomic sequences: Insights into the molecular genetics, cell biology and physiology of the titin filament system. *Rev Physiol Biochem Pharmacol* 138:19-55, 1999
96. Bang ML, Centner T, Fornoff F, et al: The complete gene sequence of titin, expression of an unusual approximately 700-kDa titin isoform, and its interaction with obscurin identify a novel Z-line to I-band linking system. *Circ Res* 89:1065-1072, 2001
97. Carmignac V, Salih MA, Quijano-Roy S, et al: C-terminal titin deletions cause a novel early-onset myopathy with fatal cardiomyopathy. *Ann Neurol* 61:340-351, 2007
98. Colegrave M, Peckham M: Structural implications of beta-cardiac myosin heavy chain mutations in human disease. *Anat Rec (Hoboken)* 297:1670-1680, 2014
99. Lamont PJ, Udd B, Mastaglia FL, et al: Laing early onset distal myopathy: Slow myosin defect with variable abnormalities on muscle biopsy. *J Neurol Neurosurg Psychiatry* 77:208-215, 2006
100. Romero NB, Xie T, Malfatti E, et al: Autosomal dominant eccentric core disease caused by a heterozygous mutation in the MYH7 gene. *J Neurol Neurosurg Psychiatry* 85:1149-1152, 2014
101. Wilmshurst JM, Lillis S, Zhou H, et al: RYR1 mutations are a common cause of congenital myopathies with central nuclei. *Ann Neurol* 68:717-726, 2010
102. Bevilacqua JA, Monnier N, Bitoun M, et al: Recessive RYR1 mutations cause unusual congenital myopathy with prominent nuclear internalization and large areas of myofibrillar disorganization. *Neuropathol Appl Neurobiol* 37:271-284, 2011
103. Fattori F, Maggi L, Bruno C, et al: Centronuclear myopathies: Genotype-phenotype correlation and frequency of defined genetic forms in an Italian cohort. *J Neurol* 262:1728-1740, 2015
104. Abath Neto O, Moreno CAM, Malfatti E, et al: Common and variable clinical, histological, and imaging findings of recessive RYR1-related centronuclear myopathy patients. *Neuromuscul Disord* 27:975-985, 2017
105. Ceyhan-Birsoy O, Agrawal PB, Hidalgo C, et al: Recessive truncating titin gene, TTN, mutations presenting as centronuclear myopathy. *Neurology* 81:1205-1214, 2013
106. Witting N, Werlauff U, Duno M, et al: Phenotypes, genotypes, and prevalence of congenital myopathies older than 5 years in Denmark. *Neurol Genet* 3:e140, 2017
107. Laporte J, Hu LJ, Kretz C, et al: A gene mutated in X-linked myotubular myopathy defines a new putative tyrosine phosphatase family conserved in yeast. *Nat Genet* 13:175-182, 1996
108. Amoasii L, Hnia K, Chicanne G, et al: Myotubularin and PtdIns3P remodel the sarcoplasmic reticulum in muscle in vivo. *J Cell Sci* 126:1806-1819, 2013
109. Laporte J, Biancalana V, Tanner SM, et al: MTM1 mutations in X-linked myotubular myopathy. *Hum Mutat* 15:393-409, 2000
110. Longo G, Russo S, Novelli G, et al: Mutation spectrum of the MTM1 gene in XLMTM patients: 10 years of experience in prenatal and postnatal diagnosis. *Clin Genet* 89:93-98, 2016
111. Tanner SM, Schneider V, Thomas NS, et al: Characterization of 34 novel and six known MTM1 gene mutations in 47 unrelated X-linked myotubular myopathy patients. *Neuromuscul Disord* 9:41-49, 1999
112. Al-Hashim A, Gonorazky HD, Amburgey K, et al: A novel intronic mutation in MTM1 detected by RNA analysis in a case of X-linked myotubular myopathy. *Neurol Genet* 3:e182, 2017
113. Hedberg-Oldfors C, Visuttijai K, Topa A, et al: Grand paternal inheritance of X-linked myotubular myopathy due to mosaicism, and identification of necklace fibers in an asymptomatic male. *Neuromuscul Disord* 27:843-847, 2017
114. Biancalana V, Scheidecker S, Miguet M, et al: Affected female carriers of MTM1 mutations display a wide spectrum of clinical and

- pathological involvement: Delineating diagnostic clues. *Acta Neuropathol* 2017. in press
115. Cowling BS, Chevremont T, Prokic I, et al: Reducing dynamin 2 expression rescues X-linked centronuclear myopathy. *J Clin Invest* 124:1350-1363, 2014
 116. Tasfaout H, Buono S, Guo S, et al: Antisense oligonucleotide-mediated Dnm2 knockdown prevents and reverts myotubular myopathy in mice. *Nat Commun* 8:15661, 2017
 117. Bitoun M, Maugendre S, Jeannot PY, et al: Mutations in dynamin 2 cause dominant centronuclear myopathy. *Nat Genet* 37:1207-1209, 2005
 118. Zuchner S, Noureddine M, Kennerson M, et al: Mutations in the pleckstrin homology domain of dynamin 2 cause dominant intermediate Charcot-Marie-Tooth disease. *Nat Genet* 37:289-294, 2005
 119. Bohm J, Biancalana V, Dechene ET, et al: Mutation spectrum in the large GTPase dynamin 2, and genotype-phenotype correlation in autosomal dominant centronuclear myopathy. *Hum Mutat* 33:949-959, 2012
 120. Bitoun M, Bevilacqua JA, Prudhon B, et al: Dynamin 2 mutations cause sporadic centronuclear myopathy with neonatal onset. *Ann Neurol* 62:666-670, 2007
 121. Chin YH, Lee A, Kan HW, et al: Dynamin-2 mutations associated with centronuclear myopathy are hypermorphic and lead to T-tubule fragmentation. *Hum Mol Genet* 24:5542-5554, 2015
 122. Royer B, Hnia K, Gavrilidis C, et al: The myotubularin-amphiphysin 2 complex in membrane tubulation and centronuclear myopathies. *EMBO Rep* 14:907-915, 2013
 123. Nicot AS, Toussaint A, Tosch V, et al: Mutations in amphiphysin 2 (BIN1) disrupt interaction with dynamin 2 and cause autosomal recessive centronuclear myopathy. *Nat Genet* 39:1134-1139, 2007
 124. Claeys KG, Maisonobe T, Bohm J, et al: Phenotype of a patient with recessive centronuclear myopathy and a novel BIN1 mutation. *Neurology* 74:519-521, 2010
 125. Bohm J, Yis U, Ortac R, et al: Case report of intrafamilial variability in autosomal recessive centronuclear myopathy associated to a novel BIN1 stop mutation. *Orphanet J Rare Dis* 5, 2010. 35-1172-5-35
 126. Bohm J, Vasli N, Maurer M, et al: Altered splicing of the BIN1 muscle-specific exon in humans and dogs with highly progressive centronuclear myopathy. *PLoS Genet* 9:e1003430, 2013
 127. Bohm J, Biancalana V, Malfatti E, et al: Adult-onset autosomal dominant centronuclear myopathy due to BIN1 mutations. *Brain* 137:3160-3170, 2014
 128. Garibaldi M, Bohm J, Fattori F, et al: Novel dominant mutation in BIN1 gene causing mild centronuclear myopathy revealed by myalgias and CK elevation. *J Neuromuscul Dis* 3:111-114, 2016
 129. Agrawal PB, Pierson CR, Joshi M, et al: SPEG interacts with myotubularin, and its deficiency causes centronuclear myopathy with dilated cardiomyopathy. *Am J Hum Genet* 95:218-226, 2014
 130. Wang H, Castiglioni C, Kacar Bayram A, et al: Insights from genotype-phenotype correlations by novel SPEG mutations causing centronuclear myopathy. *Neuromuscul Disord* 27:836-842, 2017
 131. Majcenko K, Davidson AE, Camelo-Piragua S, et al: Dominant mutation of CCDC78 in a unique congenital myopathy with prominent internal nuclei and atypical cores. *Am J Hum Genet* 91:365-371, 2012
 132. Pajusalu S, Talvik I, Noormets K, et al: De novo exonic mutation in MYH7 gene leading to exon skipping in a patient with early onset muscular weakness and fiber-type disproportion. *Neuromuscul Disord* 26:236-239, 2016
 133. Fiorillo C, Astrea G, Savarese M, et al: Italian network on congenital myopathies: MYH7-related myopathies: Clinical, histopathological and imaging findings in a cohort of Italian patients. *Orphanet J Rare Dis* 11, 2016. 91-016-0476-1
 134. Willis T, Hedberg-Oldfors C, Alhaswani Z, et al: A novel MYH2 mutation in family members presenting with congenital myopathy, ophthalmoplegia and facial weakness. *J Neurol* 263:1427-1433, 2016
 135. Tsabari R, Daum H, Kerem E, et al: Congenital myopathy due to myosin heavy chain 2 mutation presenting as chronic aspiration pneumonia in infancy. *Neuromuscul Disord* 27:947-950, 2017
 136. Pokrzywa M, Norum M, Lenggqvist J, et al: Developmental MYH3 myopathy associated with expression of mutant protein and reduced expression levels of embryonic MyHC. *PLoS One* 10:e0142094, 2015
 137. Chong JX, Burrage LC, Beck AE, et al: Autosomal-dominant multiple pterygium syndrome is caused by mutations in MYH3. *Am J Hum Genet* 96:841-849, 2015
 138. Schartner V, Romero NB, Donkervoort S, et al: Dihydropyridine receptor (DHPR, CACNA1S) congenital myopathy. *Acta Neuropathol* 133:517-533, 2017
 139. Zaharieva IT, Thor MG, Oates EC, et al: Loss-of-function mutations in SCN4A cause severe foetal hypokinesia or 'classical' congenital myopathy. *Brain* 139:674-691, 2016
 140. Gonorazky HD, Marshall CR, Al-Murshed M, et al: Congenital myopathy with "corona" fibres, selective muscle atrophy, and craniosynostosis associated with novel recessive mutations in SCN4A. *Neuromuscul Disord* 27:574-580, 2017
 141. Mercier S, Lornage X, Malfatti E, et al: Expanding the spectrum of congenital myopathy linked to recessive mutations in SCN4A. *Neurology* 88:414-416, 2017
 142. Vasli N, Harris E, Karamchandani J, et al: Recessive mutations in the kinase ZAK cause a congenital myopathy with fibre type disproportion. *Brain* 140:37-48, 2017
 143. Spielmann M, Kakar N, Tayebi N, et al: Exome sequencing and CRISPR/Cas genome editing identify mutations of ZAK as a cause of limb defects in humans and mice. *Genome Res* 26:183-191, 2016