

Case reports

Journal of Medical Genetics, 1983, 20, 64-75

A new alopecia/mental retardation syndrome

SUMMARY Three cousins are reported in an inbred family with a mental retardation/alopecia syndrome.

The occurrence of mental retardation with other easily recognisable features is of importance for the identification of rare recessive syndromes. Total alopecia is a useful marker as there have been only a few conditions in which its association with mental retardation has been noted. Moynahan¹ reported a family in which members had epilepsy, oligophrenia, and scalp alopecia, and Shokeir² reported a separate condition with universal alopecia, mental retardation, and pyorrhoea. The present family differs from those previously described and the purpose of this paper is to draw to the attention of geneticists a hitherto undescribed recessive syndrome.

Case report

The patient is a 3-year-old male from the Middle East. He was delivered after a normal birth at 37 weeks and weighed 2043 g. At birth a mild talipes of the left foot was noted. He was given oxygen but intubation was not necessary and he was home within a week. No seizures have occurred at any stage, but developmental milestones have all been markedly delayed. He is now walking but has very little speech. Head circumference and weight are below the 2nd centile. No dysmorphic facial features were noted (fig 1) but there was a striking absence of hair on the scalp and neither eyebrows nor eyelashes were present. Some hair was noted at birth but after the ritual shaving of the head at 21 days the hair did not regrow. Occasionally a single hair appeared on the scalp but soon fell out. The only hair that could be sampled (a single strand) was submitted for histological examination and found to be normal. The rest of the examination was negative.

It can be seen (fig 2) that the patient himself has one normal male sib but his mother's sister's child (III·1) is similarly affected (bald from birth and

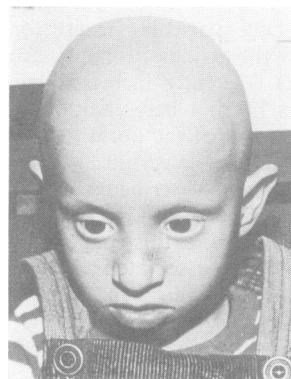


FIG 1 *The proband.*

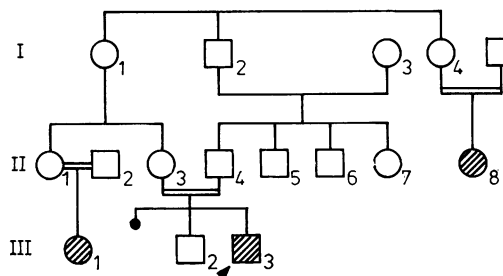


FIG 2 *Pedigree of family.*

mentally retarded) as is his father's aunt's daughter (II·8). III·1, although not seen personally, is said to wear a wig to cover her complete baldness.

Discussion

Shokeir² reported a family with dominant inheritance of mental retardation and alopecia. Twelve persons were affected over four generations but not all were retarded (eight out of the 12). Seven of the 12 had epilepsy but the onset was late (18 years in the proband). The alopecia was universal, involving the eyelashes and pubic hair, but was not total. The hair was thin and brittle and histologically showed thinning, uneven growth, and occasional beading.

Received for publication 30 January 1982.

Case reports

Inheritance was dominant and therefore unlike the present family.

Moynahan¹ reported male sibs with mental subnormality, epilepsy (onset at 2 to 3 years), and alopecia which involved the scalp only. The hair later regrew. The mode of inheritance in this family is difficult to ascertain as the boy's father only grew hair at the age of 2 years and the boy's mother's sister was bald until the age of 4 years. The regrowth of the hair, the restriction of the baldness to the scalp, and the epilepsy differentiate Moynahan syndrome from the one described here. A similar condition in two sibs whose parents were consanguineous was reported by Perniola *et al.*³ Deafness occurred in both. There are at least three other syndromes in which hair loss is associated with mental retardation. Menkes disease can be excluded as the hair is kinky and not totally absent. Prognosis for life is poor and seizures are frequent. Inheritance is X linked recessive. In Monilethrix the hair is normal at birth but is then lost within the first few months. Red pustular lesions on the scalp may be present. Alopecia is seldom total and through the pustules brittle hairs which break easily emerge. The nails and teeth are abnormal and mental retardation is only occasionally a feature. In the Hair-Brain syndrome (Amish brittle hair syndrome) those affected had short stature and relatively mild mental retardation. All the affected had hair but it was brittle and broke easily. Total alopecia was not a feature and inheritance was recessive.

In the condition described in this paper, the alopecia was total and involved all areas of normal hair growth. It probably represents a distinct entity.

M BARAITSER, C O CARTER, AND E M BRETT*

*Clinical Genetics Unit and *Department of Neurology, The Hospital for Sick Children, Great Ormond Street, London WC1N 3JH.*

References

- 1 Moynahan EJ. Familial congenital alopecia, mental retardation with unusual electroencephalograms. *Proc R Soc Med* 1962;**55**:411-2.
- 2 Shokeir MHK. Universal permanent alopecia, psychomotor epilepsy, pyorrhoea and mental subnormality. *Clin Genet* 1977;**11**:13-17.
- 3 Perniola T, Krajewska G, Carnevale F, Lospalluti M. Congenital alopecia, psychomotor retardation, convulsions in two sibs of a consanguineous marriage. *J Inher Met Dis* 1980;**3**:49-53.

Requests for reprints to Dr M Baraitser, Clinical Genetics Unit, The Hospital for Sick Children, Great Ormond Street, London WC1N 3JH.

A female infant with features of Mohr and Majewski syndromes: variable expression, a genetic compound, or a distinct entity?

SUMMARY A female child, the offspring of a consanguineous mating, had a cleft palate, tongue tumours, hypoplastic tibiae, and polysyndactyly. The relationship to the Mohr and Majewski syndromes is discussed.

Variable expression is a common problem encountered by those who seek to define syndromes. The best method to determine the extent of the phenotypic expression of a gene defect is to study the variability within sibships, but in rare disorders this is not always possible. It is then necessary to depend on somewhat arbitrary definitions. The Mohr and Majewski syndromes each behave as a probable autosomal recessive disorder^{1,2} with a relatively distinct phenotype. Temtamy and McKusick³ reported two subjects whose clinical features fulfilled the definition of both syndromes. We report a female infant, the second child of consanguineous parents, in whom combined features of both syndromes were seen.

Case report

The patient was born on 9.9.81 at 33 weeks' gestation weighing 1520 g. She was the second child of first cousin Pakistani Moslem parents. The mother and father were 19 and 21 years old, respectively. A sib was normal and there was no relevant family history.

The child (fig 1) was noted to have low set ears, micrognathia, and shallow orbits causing mild proptosis. There was a high arched palate with a posterior cleft and fleshy tumours were present on the underside of the tongue. Bilateral postaxial polysyndactyly was noted in the hands with polysyndactyly, severe talipes equinovarus, and distal shortening of both lower limbs.

At 6 months her weight of 4.2 kg was well below the 3rd centile. She fed poorly and had frequent chest infections. Her development was slightly delayed. Radiological examination revealed severe bilateral tibial dysplasia (fig 2), whereas the chest x-ray did not show significant rib shortening. There was a normal 46,XX karyotype.

Received for publication 23 July 1982.