

# Endoscopic Photography

## Digital or 35 mm?

Patrick C. Melder, MD; Eric A. Mair, MD

**Objective:** To compare off-the-shelf digital imaging equipment with a standard single lens reflex 35-mm endoscopic camera in a busy pediatric ears, nose, and throat setting.

**Design:** Two digital cameras with an endoscope adapter and a step-down ring were evaluated to obtain optimal settings for digital endoscopic photography. The equipment was used in various clinical and surgical settings to include otoscopy, sinonasal endoscopy, laryngoscopy, and bronchoscopy. The overall quality, color, brightness, and diagnostic quality of the endoscopic digital photographs were compared with those of the single-lens reflex 35-mm flash-generated photographs by experienced endoscopists. Cost analysis and ease of use were also compared.

**Subjects:** Initial digital endoscopic settings were formulated from cadaveric tests. These settings were then studied in multiple patients during endoscopy.

**Results:** Endoscopic digital photography resulted in high-quality images in all settings. Digital images were comparable to 35-mm images. The digital system was easier to use and less expensive than the 35-mm system.

**Conclusions:** We introduce a simple, inexpensive, and easily available endoscopic digital photography system. Digital photography offers numerous advantages over analog photography in a clinical practice. Digital imaging and archiving is more durable and easier to incorporate into patient records and clinical presentations. As the demand for high-quality digital imaging increases, easy-to-use inexpensive digital endoscopic photography will soon replace 35-mm camera technology.

*Arch Otolaryngol Head Neck Surg.* 2003;129:570-575

**T**HE PRINTING PRESS opened the door for the religious and secular revolutions that occurred during the Reformation in northern Europe and the Renaissance in southern Europe in the 15th century, respectively. Likewise, the digital age has opened the door for new ideas and expressions of ideas not possible or before imaginable. Like the printing press, digital information allows users to distribute their ideas to the masses, but on a magnitude of order far greater than can be experienced with hard copy.

At the core of a human's being is the ability to communicate thoughts, feelings, and experiences. Medicine is no island in this sea of expression, and often words cannot describe what the human eye can see. For centuries, visual documentation has been a cornerstone of medical education and experience. Physicians/surgeons could only communicate as well as they could visually describe their experiences. Fortunately, for the surgeon who is not an anatomist or artist, the 20th

century ushered in technologies to enhance our ability to communicate our visual experience.<sup>1</sup> But even though this new technology ushered in a new era of communication as in the 15th century, the photograph in hard copy format is limited in that it is an analog. Today, the means to organize and collate this information is many times digital (databases); however, the commodity, the image itself, is an analog and is difficult to distribute in or interface with the digital age.

The surgeon has the means to take digital photographs. This, combined with the use of digital organizational and distribution techniques or enhancement programs, allows the endoscopist the means to fully interface with the digital age. This new avenue to describe our visual experience has been tremendous. But for decades past, the tried and true 35-mm system has sat on a pedestal that has yet to be toppled, but knocks at the base can be heard.

Endoscopists face unique challenges in documenting their visual expe-

*From the Department of Otolaryngology–Head and Neck Surgery, Walter Reed Army Medical Center, Washington, DC. The authors have no relevant financial interest in this article.*

rience. Their extended eye, the endoscope, has required special adaptation to interface with the 35-mm single-lens reflex (SLR) camera. These adaptations can be expensive, and time-tested experience is required to master the art of endoscopic photography.<sup>2</sup> With the introduction of digital cameras, camera makers (some never before camera makers) introduced devices that did not and do not look like the time-tested 35-mm camera—a psychological barrier to its acceptance. None of this was useful for endoscopists as they waited on the sideline to see how they could interact with this new technology. Fortunately, inexpensive digital cameras combined with inexpensive modifications afford the endoscopist the ability to participate in the digital age and the great exchange of ideas that is so much a part of this new age.

One of us (E.A.M.) has used the standard 35-mm SLR camera for endoscopic pictures for more than 15 years. This has continued to be standard practice in the Department of Otolaryngology–Head and Neck Surgery at Walter Reed Army Medical Center. However, with the advent of affordable digital cameras, another one of us (P.C.M.) has attempted to use digital cameras in endoscopy for less than 18 months. We report herein our experience in obtaining the necessary equipment and skill to take diagnostic-quality, digital, endoscopic images. We then compared images taken with the 35-mm camera and those taken with the digital camera in various clinical/operative settings.

## METHODS

First, the initial purchase of a digital camera required researching the means to attach endoscopes to digital cameras. Many digital cameras are marketed toward the point-and-shoot consumer market and do not offer the ability to attach differing lenses and filters. Second, the image quality of the digital photograph had to be of sufficient resolution (pixels) to result in diagnostic-quality photographs. Third, the external flash attachment (hot shoe) was researched as a requirement. Also, a mode for manual operation of the camera was a necessity. Last, types of storage media were evaluated. Because of the universal appeal and cost of compact flash cards, this storage medium was chosen.

One camera (Epson PhotoPC 3000Z 3.3 Megapixel camera; Epson USA, Long Beach, Calif) met the initial criteria for purchase. A lens adapter is shipped with the camera, which allows the endoscopist to use Epson USA or third-party lenses and filters to modify images. If lenses or filters are attached directly to the camera housing, the lens mechanism will not fully extend. Most midrange digital cameras with a zooming capability have a retractable lens that retracts into the camera body when the unit is off. During normal operation, the lens is fully extended, hence the need for the lens adapter that fits like a sleeve over the extended lens (**Figure 1**). The lens adapter shipped with the camera has a 46-mm step-up to a 49-mm thread. Initially, a borescope adapter (item STI10213; Scope Technology, Pomfret, Conn) was purchased. The endoscopic adapter can be purchased in a 46- or 37-mm thread. Because the 46-mm thread more closely approximated the 49-mm thread, it was purchased. To accommodate for the change from 46 to 49 mm, a 49- to 46-mm step-down ring was purchased at a local camera store (widely available). The final adaptation in linear form was as follows (final thread in millimeters): camera (Epson PhotoPC 3000Z 3.3 Megapixel camera) (46 mm) → lens adapter (49 mm) → step-down ring (46 mm)



**Figure 1.** Digital endoscopic equipment (from left to right): CompactFlash card, camera (Canon Power Shot G2 4 Megapixel camera; Canon USA, Lake Success, NY) with lens fully extended (normal operation), lens adapter, step-down ring, endoscopic adapter, and endoscope. A fiberoptic light cord is running along the top of the photograph.

→borescope or endoscopic adapter (46 mm). The endoscope is then placed into the adapter, and a screw is used to tighten the adapter around the endoscope.

The initial fittings with the borescope adapter were poor. The borescope adapter is an industrial-grade product and not a medical-grade product. The endoscope would move about during photography, and 2 hands were required to center and stabilize it. Later, an endoscopic adapter (item 35mmCA; Precision Optics, Gardner, Mass) was chosen; this adapter has a spring release like many adapters commonly used in our practice. This adapter had matching 49-mm threads so it attached directly to the lens adapter (Epson USA) without step-up or step-down ring modifications.

After obtaining the proper equipment, a black box experiment was conducted. A cadaveric temporal bone was placed into a box and closed. On one side, a small valve was made in which to introduce the endoscope. Tape was applied to the endoscope with millimeter markings to determine the distance from the temporal bone. A 0° 4-mm endoscope (Storz Hopkins Rod II; Karl Storz, Culver City, Calif) was coupled to the camera, and a light source (Storz Xenon 175 model 20132020; Karl Storz) with a standard light cable was used to take pictures of the object, which was 11 cm from the valve. All modes of the camera were tested: fully automatic, program, and manual (automatic or manual exposure and aperture priority). Various flash modes were used: forced flash, flash off, and automatic flash. In addition, metering was adjusted. Likewise, the light intensity from the light source was adjusted.

After the initial work in the black box, the camera was used in various clinical settings to include airway and nasal endoscopy and otoscopy. Cadaveric airway photographs were taken as well. Images were also taken with other cameras (Canon Power Shot G1 3.34 Megapixel and Canon Power Shot G2 4 Megapixel cameras; Canon USA, Lake Success, NY) with similar attachments.

Photographs (35 mm) were then taken, of the same patients, using another camera (Olympus OM88 35mm SLR camera) using a special zoom lens (Karl Storz) with an endoscopic adapter (Karl Storz 560 QC; Karl Storz Endoscopy, Culver City), a synchronization cable, a fluid light cable, a light source, and a flash generator. Because techniques with the 35-mm camera are well established by one of us (E.A.M.), photography was limited to clinical or cadaveric work. There was no need to obtain initial settings in the black box.

The following endoscopes (Karl Storz) were used during the evaluation period: 4 mm, 0° (model 7208AA); 4 mm, 0°

(model 27005AA); 4 mm, 70° (model 7208CA); 10 mm, 0° (model 26033AP); and 4 mm, 120° (model 8700E).

To obtain images large enough to view, the camera had to be in full optical ( $\times 3$ ) and digital ( $\times 2$ ) zoom. The camera (Canon Power Shot G2 4 Megapixel camera) allows greater than  $\times 6$  zooming, but this is sufficient to fill the viewfinder of the camera. Zooming much past  $\times 6$  to  $\times 8$  will decrease picture quality. The best digital images were obtained using an International Standards Organization setting of 50 to 100.

Two different light cables were used. The one offering the most consistent results was the standard fiberoptic light cord. The fluid-filled light cord (used for 35-mm photography) often flooded the image with light and washed out the image, even with the light source on its lowest setting.

For these low-light situations, alterations of the previously mentioned variables are needed, as is adjustment of the International Standards Organization setting. The lowest International Standards Organization setting possible for the camera should be chosen for this environment. In addition, using the lowest possible International Standards Organization setting will minimize noise in the photograph.<sup>3</sup>

After digital or 35-mm photography, the images were processed in the standard fashion: images from the digital camera were downloaded to the computer immediately after shooting for review and analysis, and the 35-mm slide film was developed through our photography department.

A total of 29 images were obtained with the digital camera and compared with the 35-mm slides. Each image was then assessed by experienced endoscopists as to (1) overall image quality, (2) brightness, (3) color, and (4) diagnostic quality (ie, can healthy structures or abnormalities be identified?). Overall image quality was assessed on a scale from 1 to 5 (1 indicates excellent; and 5, poor). Brightness was evaluated on a scale from 1 to 3 (1 indicates adequate; 2, too bright; and 3, too dark). Overall color was evaluated as either 1 (good) or 2 (poor). Last, depending on the anatomic sight being photographed, the image was judged according to its ability to convey healthy anatomic structures and/or pathologic conditions. For nasal images, the image was evaluated to determine if (a) turbinates, (b) the uncinate process, (c) the eustachian tube orifice, and (d) the nasopharynx could be identified. Laryngeal images were evaluated for the presence of (a) the epiglottis, (b) a false vocal fold, (c) the ventricle, and (d) true vocal folds. Otolaryngologic images were evaluated for normal tympanic membrane landmarks: (a) the short process of malleus, (b) the umbo, (c) the pars flaccida, and (d) the light reflex. Any structure altered by abnormalities was noted. If healthy anatomic and/or pathologic conditions could be assessed, the image was assigned a score of 1; and if the diagnostic quality was poor, a score of 2 was applied. This scoring was done for digital and 35-mm slides. With the grading scale, the photograph with the lowest score was the better image. Accordingly, the best score available for each individual photograph is a 4, and the poorest is a 12. A side-by-side comparison of these images was not performed. Given the unique nature and mode of viewing these images (computer screen or carousel projection), viewing images in the same setting would unduly bias the observer. Therefore, in 2 separate settings with the same observers, either digital or analog images were viewed.

## RESULTS

The initial results with the digital camera were disappointing. The images were often blurred. This improved with manipulating the various shutter sizes and speeds. Images taken in a program or an automatic mode were uniformly poor in quality. In adapting fittings with

step-up and step-down rings, the distance from the endoscope to the camera lens will increase, thereby affecting final image quality.

The cadaveric temporal bone work was a good start; however, transferring what was learned to a clinical setting was difficult. The bare white temporal bone in the black box evaluation produced different images than those obtained in situ. Manual camera operation using manual exposure with aperture priority offered the greatest control over the camera. The flash was placed on automatic and the light source was variously adjusted, but a low light output of 10% offered the best results (for the black box). Differing light adjustments in situ were needed for differing image scenarios. Metering changes had no significant impact on image quality in this setting. The best shutter setting (F number) was F2, which gives the widest available aperture of the lens. Shutter speeds of 1/50 to 1/225 second produced the best images.

The total score for each photograph from 3 observers was added, and the added score was the final score of the photograph. Hence, with the combined scores of each photograph, the best possible score is a 12 and the poorest is a 36. After each photograph was graded and assigned a numerical score, the individual scores for all of the photographs in a given clinical scenario were summed and divided by the total to give an average score for the digital and 35-mm analog images.

Of the 35-mm images reviewed ( $n=29$ ), the lowest score (best quality) was a 12 and the highest score (poorest quality) was a 29. The total score for all 35-mm images was 521. The final average score for the 35-mm images was 18. The lowest score of the digital images was a 12; and the highest score, a 22. The final average score for the digital images was 17 (**Table 1**).

Although not graded, a uniform comment made by the panel was that the 35-mm slides offered greater depth of field.

## COMMENT

Taking endoscopic photographs with the digital camera involves completely different optics than those of an SLR camera. The pupil sizes of the endoscopes and camera must be considered, as must the distance of the endoscope from the camera lens. The exit pupil of the endoscope must closely approximate, if not match, the entry pupil of the camera lens to produce quality photographs. Also, the lens of the endoscope must be as close to the lens of the camera as possible to increase clarity and depth of field of the image.

D'Agostino et al<sup>4</sup> noted that photographic documentation of the larynx (practically speaking, photographic endoscopy) should fulfill 6 criteria: (1) The system should be easy to use in the operating room and the clinic. (2) It should be user friendly. (3) It should require only 1 operator. (4) When used in the operating room, it should involve minimal disruption of the procedure. (5) The cost of the equipment should be reasonable. (6) It should allow use of a commonly available film type. Benjamin<sup>2(p271)</sup> adds that, "the more expensive the equipment, the more reliable it is and the better the image." However, he did add that the photographic technique

should not be so cumbersome that a novice could not use the system.

Digital photography is an exciting and emerging technology for use in otolaryngology. There are many advantages in using digital imaging over 35-mm analog slides. First, images can be assessed intraoperatively for quality. The initial fear was that the review image on the liquid crystal display on the camera may look deceptively better on the smaller screen than on a computer or in a presentation; however, in a short time, we developed an appreciation for the quality of the final digital photograph by judging the appearance of the photograph on a liquid crystal display. On the other hand, the total time for a 35-mm image to make it from the surgeon's camera to processing and developing may take hours or days, and the end result may not be the desired result, with the opportunity for capturing the image lost at the expense of surgeon teaching or training.

Second, images can be shared or manipulated via a wide platform of programs and formats. Having the ability to directly import images into presentation software or publish directly onto the Web affords surgeons the ability to instantly share their visual experience. Furthermore, time-saving software is available for filing and organizing digital images that enhance surgeon education.<sup>5</sup> In addition, any flaws in technique or unwanted noise in the photograph can be eliminated with inexpensive, popular, off-the-shelf image-editing software. The concern and prohibition, though, in altering the true image and, thus, the true experience is always a factor in dealing with digital images. In fact, this concern extends to all digital data. Watermark technologies are being developed to counter this concern.<sup>6</sup> In an attempt to allay this concern, it may be appropriate in public forums or before acceptance in peer-reviewed journals that the author or presenter be required to sign a full disclosure statement. Appropriate disclosure may include information about the original source of the image, method of enhancement (if any), and denial of intent to alter photographic or surgical outcome.

Third, images may be archived indefinitely on magnetic or optical media. With the exception of Kodachrome (Eastman Kodak Co, Rochester, NY) slides, photographic slide film loses quality with time.<sup>7</sup> Digital images may be stored on a wide variety of magnetic and optical media at minimal cost, indefinitely. Also, images can be shared across a wide platform from the camera itself to laptop/desktop, handheld device, Internet, and even high-quality photographic paper suitable for framing. Yet another advantage in digital archiving is the organizational and retrieval methods available for the image. Images can be sorted, stored, and retrieved by key word with inexpensive (even free) popular image archival software.

Also, digital cameras and technologies to develop digital data are inexpensive (**Table 2**). The cost savings in using or starting to use digital technology are widely known.<sup>7</sup> In particular, the initial costs for an endoscopist to purchase special 35-mm equipment can be substantial. The cost of our digital endoscopic system was less than \$1000 (less the light source). The camera at the initial time of purchase was \$777, and the endoscopic

**Table 1. Scores for Images Produced Using 2 Methods\***

Image No.	35-mm Camera	Digital Camera
1	15	17
2	16	16
3	12	13
4	13	12
5	16	15
6	16	15
7	16	15
8	15	16
9	20	22
10	13	18
11	13	15
12	21	17
13	15	19
14	14	16
15	14	20
16	18	20
17	15	16
18	15	15
19	17	21
20	19	19
21	14	17
22	24	16
23	22	13
24	22	15
25	26	13
26	29	16
27	28	20
28	23	18
29	20	17
<b>Total</b>	<b>521</b>	<b>482</b>
Final averaged score	18	17

\*The best possible score is 12; and the poorest, 36.

**Table 2. Characteristics of the 2 Endoscopic Methods\***

Characteristic	35-mm Single Lens Reflex Endoscopy	Digital Endoscopy
Equipment costs	+	++++
Ease of use	+	++++
Universal utility†	+	++++
Image quality	++++	++++
Portability‡	+	++++
Image-processing costs	+	++++
Image storage costs§	++	++++
Image storage life	+++	++++

\*Abbreviations: +, poor; ++, fair; +++, good; +++, excellent.

†Compared with ease of use in word processing, presentation software, image enhancement software, and Internet applications.

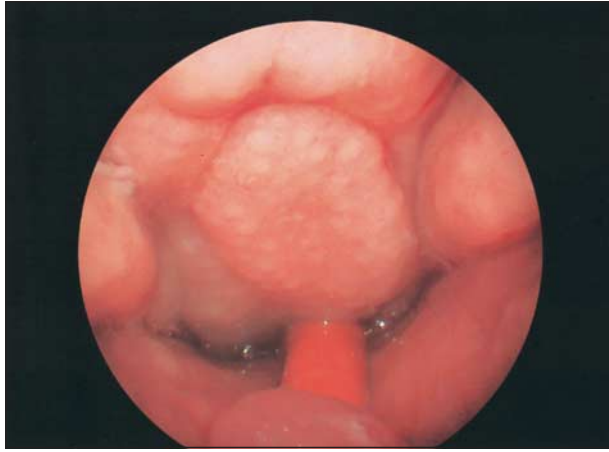
‡All equipment associated with 35-mm endoscopy is usually in a tower, which limits its transport outside of the clinic or operating room.

§The differential here will only favor digital endoscopy as storage costs continue to decrease (see the "Comment" section).

||Unless Kodachrome (Eastman Kodak Co, Rochester, NY) slides, 35-mm slides lose quality with time.

adapter can be purchased for \$200. The additional step-up or step-down rings are nominal in cost. The software needed for image enhancement is often bundled with most of the digital cameras on the market. With time, many of these cameras decrease dramatically in cost as newer models replace them. Gordon Moore, cofounder of Intel, initially predicted in 1965 that data density would





**Figure 2.** A digital photograph, with a 120° endoscope, of the nasopharynx and adenoidal tissues. A catheter used for retracting the palate is seen in the midline.

double every 12 months.<sup>8</sup> It has doubled approximately every 18 months. With this doubling of data density is the concomitant decrease in cost. This rule dictates that with an increase in data density, price moves inversely. Hence, it is inevitable that digital cameras will become more and more powerful and less and less expensive.

Furthering the decrease in cost of digital photography are the digital memory cards that replace the film and developing cost, not to mention the wait in developing 35-mm slides. This digital film comes in a wide variety of formats, some of which are proprietary and some of which are used industry-wide: (a) CompactFlash Types I & II, (b) SmartMedia Cards, (c) Memory Sticks (Sony Corp USA, New York, NY), (d) compact discs, and (e) Secure Digital Cards. What really makes using this digital film intriguing is being able to take photographs in one instant and taking the digital film out of the camera and inserting it into another camera, a personal digital assistant, a handheld computer, a laptop, or a desktop personal computer for review and manipulation.

The application of the Moore law<sup>8</sup> holds for this digital film as well. In addition, the compression format used in storing digital data affects storage capacity, which further enhances the cost advantage of digital imaging. Most cameras allow the user to capture the maximum amount of resolution in an image with little or no compression in a tagged image file format or an equivalent format. This greatly reduces the ability of the digital film to hold many photographs. To improve storage capacity and enhance cost savings, cameras can store data in a compressed format, commonly in the joint photographic experts group format. To further increase storage capacity, the resolution of images can be reduced when saving them on the camera. Saving images in a tagged image file format is “lossless,” ie, as much data as can be captured from the original digital image are preserved in this format vs storage in a joint photographic experts group format (which is “lossy”). This has implications in saving, editing, and re-saving images because it will affect final image quality.

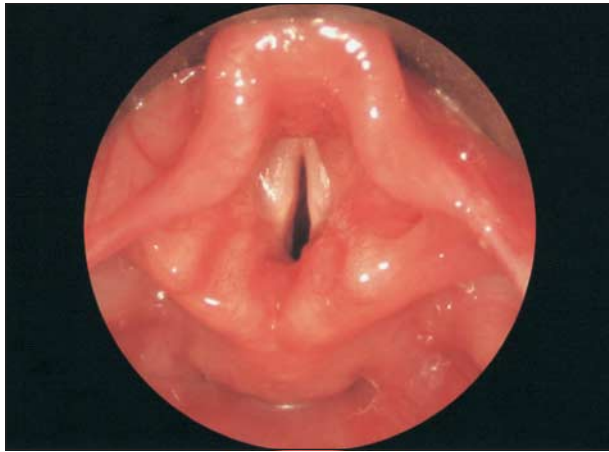The cost analysis would not be complete without an evaluation of the use and sharing of 35-mm slide technology. The unique components needed for 35-mm en-

doscopic photography are as follows: (1) a 35-mm camera with metering, motor wind, and a plain and clear focusing screen; (2) a special zoom lens with variable focal length from 70 to 140 mm; and (3) a synchronization cable with a flash generator and a fluid light cable (Figure 1).<sup>5</sup> The cost of the SLR camera with the endoscopic adapter and lens is about \$5300. The total cost of the flash generator, light source, and synchronization cable is about \$9100. The fluid light cable is \$900, for a total cost of around \$15 300. After the initial cost of the camera and setup, the endoscopist must contend with years of film and developing costs. Also, realizing that storing and retrieving these slides take time and space will affect the final cost of a 35-mm system. Also, for the endoscopists to input their 35-mm images into presentation software would require the expense, and time, of using a scanner. Alas, if the SLR camera is a dinosaur that will not die, some camera makers offer digital SLR camera bodies that allow the use of the lenses and endoscopic adapter of the previously mentioned system. This comes at a price, though. One digital SLR camera body (without lenses and adapter) is around \$2000. And the technique and knowledge of taking endoscopic photographs for these cameras is far from being resolved.

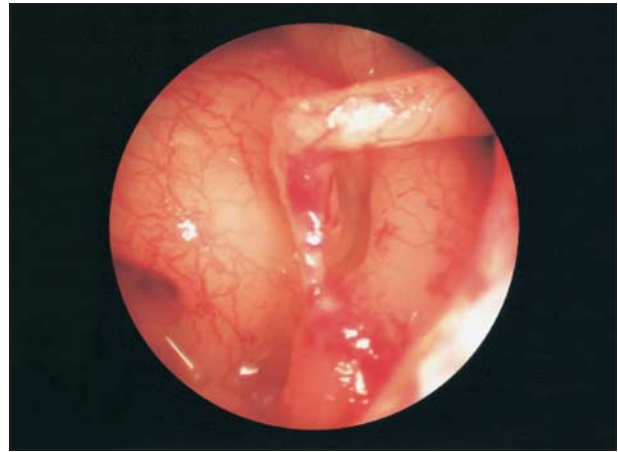In addition, digital photography is completely portable. The digital system we use is a system that can be easily used in the operating room, in the clinic, or at the bedside. Contrary, the 35-mm technology requires so much more in the way of setup and equipment (flash generator and special cable). It is difficult to transplant its use from the fixed setting of the operating room or clinic to the hospital ward.

Finally, image quality for diagnostic purposes is comparable to 35-mm slides, as demonstrated by our results. This is the last knock at the base of the pedestal of 35-mm analog photography. Although the resolution of digital photographs is not at the level of analog photographs, the question must be asked, “How much do you need?” The goal of any mode of visual presentation, whether it be on photographic paper, a slide photograph, on a computer screen, or a videotape projection, should be to render a photograph that is “photorealistic.” It should have the ability to convey and store the visual experience, as seen with the endoscope.

For our camera, the pixel resolution is 3.3 megapixels, or more than 3 million pixels. This means that the camera can capture an image with 2048 × 1536 pixels (actual and advertised pixels do not match) in an uncompressed format. In this format, the images can be printed out on 28 × 36-cm (11 × 14-in) photographic paper for a photorealistic appearance. To view images on an upscale computer screen would require input of anywhere from 1280 × 1024 to 800 × 600 pixels. Computer projection devices require 1024 × 768 pixels of resolution for projection. No matter the means of visual presentation, a 3-megapixel camera or higher is more than adequate for capturing the visual data. In fact, our results demonstrate that overall image quality with the digital photographs is comparable to the 35-mm slides (**Figure 2** and **Figure 3**). There was a noticeable difference in the quality of the otologic pictures between the 35-mm and the digital cameras. Images 22 through



**Figure 3.** A digital photograph, with a 10-mm 0° endoscope, of a healthy pediatric larynx.



**Figure 4.** A digital photograph, using a 4-mm sinus endoscope, of the middle ear in preparation for a stapedectomy. The stapes, oval window, stapedial tendon, fallopian canal, and Jacobson nerve are well visualized.

28 (Table 1) were all otologic pictures (**Figure 4**). The picture quality of the 35-mm images was uniformly poorer than that of the digital photographs. Even though the digital photographs matched or exceeded the 35-mm images, all of the digital images lacked significant depth of field. This may explain the excellent picture quality in the middle ear, where depth of field is limited by anatomic features. The lack of depth of field in the other photographs can be explained by the shutter size needed for clear images and the distance of the camera from the endoscope.

However, with a little serendipitous ingenuity, the endoscopist can obtain much information from this simple system. This is best illustrated by the inexpensive and simplistic means by which we found that digital cameras (or camcorders) allow an endoscopist to perform videoendoscopy at a fraction of the cost of a tower system. Most digital cameras come with packaged audio/visual cables that connect the camera directly to a television for the viewing of images in a slide show format. In doing this, a live image is routed from the digital camera to a standard television. Attaching a videocassette recorder then allows the endoscopist to have videotape documentation for around \$1200.

Before photography, it was the pen and paper (or its equivalent). Certainly, these were adequate to convey medical images over millennia. What needs to be decided is, what advantage does digital photography offer over 35-mm technology?<sup>9</sup> Given a similar paradigm shift, the answer was obvious for surgeons who first took pho-

tographs in the late 19th and the early 20th centuries to record their visual experiences. The answer should be as obvious now as well.

Accepted for publication October 4, 2002.

This study was presented at the annual meeting of the American Society of Pediatric Otolaryngology, Boca Raton, Fla, May 13, 2002.

Corresponding author and reprints: Patrick C. Melder, MD, Department of Otolaryngology–Head and Neck Surgery, Walter Reed Army Medical Center, 6900 Georgia Ave NW, Washington, DC 20307-5001 (e-mail: pmelder@pol.net).

## REFERENCES

1. Benjamin B. Indirect laryngeal photography using rigid telescopes. *Laryngoscope*. 1998;108:158-161.
2. Benjamin B. Art and science of laryngeal photography. *Ann Otol Rhinol Laryngol*. 1993;102:271-282.
3. Indman PD. Documentation in endoscopy. *Obstet Gynecol Clin North Am*. 1995; 22:605-616.
4. D'Agostino M, Jiang J, Hanson D. Endoscopic photography: solving the difficulties of practical application. *Laryngoscope*. 1994;104:1045-1047.
5. Mendelsohn MS. Using a computer to organize digital photographs. *Arch Facial Plast Surg*. 2001;3:133-135.
6. Teuffel W, Stettin J. Electronic documentation in endoscopy: present status and future perspectives from a company standpoint. *Endoscopy*. 2001;33:276-279.
7. Galdino GM, Swier P, Manson PN, Vander Kolk CA. Converting to digital photography: a model for a large group or academic practice. *Plast Reconstr Surg*. 2000;106:119-124.
8. Moore's law. Available at: [http://www.webopedia.com/TERM/M/Moores\\_Law.html](http://www.webopedia.com/TERM/M/Moores_Law.html). Accessed March 12, 2002.
9. Benjamin B. Photography of severe laryngeal obstruction. *Ann Otol Rhinol Laryngol*. 2000;109:829-831.