

UC Irvine

UC Irvine Previously Published Works

Title

Combined benzoporphyrin derivative monoacid ring photodynamic therapy and pulsed dye laser for port wine stain birthmarks.

Permalink

<https://escholarship.org/uc/item/1p49t236>

Journal

Photodiagnosis and photodynamic therapy, 6(3-4)

ISSN

1572-1000

Authors

Tournas, Joshua A
Lai, Jennifer
Truitt, Anne
[et al.](#)

Publication Date

2009-09-01

DOI

10.1016/j.pdpdt.2009.10.002

License

<https://creativecommons.org/licenses/by/4.0/> 4.0

Peer reviewed



Published in final edited form as:

Photodiagnosis Photodyn Ther. 2009 ; 6(3-4): 195–199. doi:10.1016/j.pdpdt.2009.10.002.

Combined Benzoporphyrin Derivative Monoacid Ring A Photodynamic Therapy and Pulsed Dye Laser for Port Wine Stain Birthmarks

Joshua A. Tournas, M.D.^{1,2}, Jennifer Lai, M.D.^{1,3}, Anne Truitt, M.D.^{1,2}, Y.C. Huang, Ph.D.¹,
Kathryn E. Osann, Ph.D.⁶, Bernard Choi, Ph.D.^{1,4,5}, and Kristen M. Kelly, M.D.^{1,2,4}

¹Beckman Laser Institute, University of California, Irvine, CA

²Department of Dermatology, University of California, Irvine, CA

³Keck School of Medicine, University of Southern California, Los Angeles, CA

⁴Department of Surgery, University of California, Irvine, CA

⁵Department of Biomedical Engineering, University of California, Irvine, CA

⁶Department of Medicine, University of California, Irvine, CA

Abstract

Background—Pulsed dye laser (PDL) is a commonly utilized treatment for port wine stain birthmarks (PWS) in the United States; however, results are variable and few patients achieve complete removal. Photodynamic therapy (PDT) is commonly used in China, but treatment associated photosensitivity lasts several weeks and scarring may occur. We propose an alternative treatment option, combined PDT+PDL and performed a proof-of-concept preliminary clinical trial.

Methods—Subjects with non-facial PWS were studied. Each subject had four test sites: control, PDL alone, PDT alone (benzoporphyrin derivative monoacid ring A photosensitizer with 576 nm light), and PDT+PDL. Radiant exposure time for PDT was increased in increments of 15 J/cm². Authors evaluated photographs and chromametric measurements before and 12 weeks post-treatment.

Results—No serious adverse events were reported; epidermal changes were mild and self-limited. No clinical blanching was noted in control or PDT-alone sites. At PDT radiant exposures of 15 and 30 J/cm², equivalent purpura and blanching was observed at PDL and PDT+PDL sites. At PDT radiant exposures over 30 J/cm², greater purpura was noted at PDT+PDL sites as compared to PDL alone. Starting at 75 J/cm², improved blanching was noted at PDT+PDL sites.

Conclusions—Preliminary results indicate that PDT+PDL is safe and may offer improved PWS treatment efficacy. Additional studies are warranted.

© 2009 Elsevier B.V. All rights reserved.

Corresponding Author: Kristen M. Kelly, M.D., 1002 Health Sciences Road East, Irvine, CA 92612, Telephone: (949) 824-7997, Fax: (949) 824-2726, KMKelly@uci.edu.

Publisher's Disclaimer: This is a PDF file of an unedited manuscript that has been accepted for publication. As a service to our customers we are providing this early version of the manuscript. The manuscript will undergo copyediting, typesetting, and review of the resulting proof before it is published in its final citable form. Please note that during the production process errors may be discovered which could affect the content, and all legal disclaimers that apply to the journal pertain.

Keywords

Port wine stain birthmarks; pulsed dye laser; photodynamic therapy; vascular birthmarks

INTRODUCTION

Port wine stain birthmarks (PWS) are congenital, progressive vascular malformations of the skin which are present at birth in 0.3% of infants, are commonly found on the face and in many cases disfigure the bearer. The pulsed dye laser (PDL) is the current standard of care for treatment of such cutaneous vascular lesions. The PDL enables lesion lightening by causing selective photothermal injury to tissue vasculature. Yellow light ($\lambda = 577\text{--}600$ nm wavelength) emitted by the pulsed dye laser is preferentially absorbed by hemoglobin (the major blood chromophore) in the ectatic capillaries of the upper dermis. Radiant energy is converted to heat, causing thermal damage and thrombosis in targeted vessels(1).

However, with PDL alone, few patients (< 10%) achieve complete blanching of their lesion, and multiple treatments (5–30 or more) are generally required. In a five-year study of 640 PWS patients at Bridgend General Hospital, Lanigan et al. concluded that the degree of fading achieved following PDL therapy is “variable and often unpredictable”(2). Huikeshoven et al. (3) published a 10-year follow-up study of 51 patients who had undergone PDL treatment for PWS birthmarks. They reported significant re-darkening of PWS since an initial course of PDL therapy (although PWS remained significantly lighter as compared to pre-treatment).

Because of the limitations of PDL PWS therapy, the search continues for other safe and more effective treatment modalities. Photodynamic therapy (PDT) may offer such an alternative. PDT utilizes a photosensitizer and light to generate reactive oxygen species and creates an opportunity for targeted lesion destruction. PDT has been used to treat a wide range of benign, pre-malignant and malignant conditions, including age-related macular degeneration(4), actinic keratoses(5) and cancers of the skin, lung and gastrointestinal tract(6).

PDT may offer several advantages for treatment of cutaneous vascular lesions. However, careful protocol design is required because the potential exists for complete vascular network destruction, which can result in necrosis, ulceration, and subsequent scarring. A small number of studies have been conducted using PDT as a stand-alone treatment of PWS, with varied success and safety outcomes. Collectively, the use of PDT to treat PWS has been associated with promising blanching, but also with prolonged photosensitivity and a significant risk of complications(7),(8)

Careful photosensitizer and light source selection is required to achieve desired efficacy during PDT treatment of PWS, while limiting injury to vessels at the desired depth. In this study, we propose the use of benzoporphyrin derivative monoacid ring A (BPD) and yellow light for PDT. BPD is an excellent photosensitizer for PWS treatment based on the following characteristics: 1) vascular predominance(9),(10),(11); 2) proven safety and efficacy in humans (4),(12) and 3) photosensitivity of relatively short duration (1–5 days depending on dose administered)(12).

We have proposed combining the photochemical and photothermal aspects of PDT and PDL therapy(9),(13). Combining these approaches allows the use of lower radiant exposures for each portion of the procedure, avoiding adverse effects such as scarring, while providing enhanced vascular shutdown. Our preliminary animal experiments(9;13) demonstrated that PDT+PDL combination therapy can achieve enhanced vascular effect without epidermal injury and may address limitations associated with the current standard of care treatment, PDL alone.

We report observations from a proof-of-concept, tolerance and safety dose ranging study designed to evaluate and compare PDL alone, PDT alone and PDT+PDL for PWS treatment. This is the first published report evaluating clinical use of the PDT+PDL approach.

MATERIALS AND METHODS

The Institutional Review Board at the University of California, Irvine approved the research protocol. Patients 18 or older with non-facial PWS were recruited. Exclusion criteria included history of allergy to study medication, history of photosensitizing conditions such as the porphyrias, use of photosensitizing or blood-thinning medications, active infections, and recent laser treatment of PWS.

Eight patients were enrolled. Three patients underwent two separate sets of treatment, for a total of 11 sets of treatment sites. Subject's ages ranged from 19 to 53 and 7 of 8 patients were female. Fitzpatrick skin types were II or III. Lesions were located on the trunk and extremities.

For each subject, four circular test sites with a 2-cm diameter were delineated on the day of treatment. Sites were documented with digital photography and chromameter (Minolta Inc.) measurements were taken. Site #1 served as a control and received no treatment. Site #2 was treated with PDL alone (585 nm, 7 mm spot, 8 J/cm² radiant exposure, 30 ms cryogen spurt with a 20 ms delay). Sites #3 and #4 were treated with PDT alone and PDT+PDL, respectively.

After use of the PDL on site #2, patients received liposomal BPD-MA (verteporfin; Visudyne; QLT, Inc. Vancouver, Canada) by intravenous infusion. Drug administration procedures in the verteporfin package insert were followed. Each 15 mg vial of medication was reconstituted with 7 ml sterile water, providing 7.5 ml of a 2 mg/ml solution of verteporfin. The reconstituted verteporfin was protected from light and used within four hours of preparation. The volume of reconstituted verteporfin required to achieve a dose of 6 mg/m² body surface area (calculation based on weight and height as provided in drug package information) was withdrawn and diluted with 5% dextrose for a total infusion volume of 30 ml. The full infusion volume was administered mechanically over a 10-min period at a rate of 3 ml/min using a syringe pump and in-line filter.

Irradiation of the PDT test site was initiated 15 min after the start of the 10-min BPD infusion with an argon pumped dye laser (Lumenis Inc., Santa Clara, CA) tuned to 576 nm with an output irradiance of 100 mW/cm². To study effectiveness and safety of PDT at different light doses, total CW radiant exposure administered was steadily increased over the course of the study by increasing total time of laser exposure. Two subjects each received a CW radiant exposure of 15, 30, 45, 60, and 75 J/cm², and one subject received a radiant exposure of 90 J/cm².

For the combined PDT+PDL test site, PDT was performed as described in the preceding paragraph. This was followed immediately by PDL irradiation at the same parameters as the PDL alone test site.

Subjects returned for follow-up visits at 1 and 3 days; and 1, 2, 4, 8 and 12 weeks post intervention. At each visit, documentation of PWS appearance was obtained by visual inspection, digital photography and chromameter measurements. Patients were questioned regarding adverse effects. Pre- and 12-week post treatment measurements of erythema (a*), were compared for the various treatment groups using repeated measures analysis of variance.

RESULTS

Safety and Tolerability

Treatments were well tolerated with most subjects reporting no discomfort during PDT (only subject 1 reported mild temporary discomfort) and mild discomfort during PDL therapy. No subjects reported increased discomfort during PDT+PDL as compared to PDL alone.

No serious adverse events were reported. One patient experienced extravasation at the i.v. site (antecubital fossa of arm) and required photoprotection of this area for several weeks. This patient received a repeat treatment without incident, six weeks later. Epidermal changes were limited to fine scabbing and temporary mild hyperpigmentation at PDL-treated sites, which resolved without treatment. Other adverse effects were reported, but were not thought to be related to treatment. One subject experienced viral symptoms three days post-treatment including fever, chills and nasal congestion. Other family members were similarly affected. A second subject developed a crust at the PDT+PDL site four weeks post-intervention. The subject reported that similar crusting had happened before, sometimes related to trauma. This complication resolved without treatment or sequelae. A third subject reported an asthma flare two weeks post-treatment. This subject has a long history of significant asthma.

Visual Assessment of Blanching Response

No changes were observed at control sites. We also did not observe any PWS blanching at PDT alone sites.

Clinical assessments of PDL alone versus PDT+PDL test sites are summarized in Table 1. At PDT radiant exposures of 15 and 30 J/cm², blanching was similar at the PDL and PDT+PDL sites. Starting at a PDT radiant exposure of 30 J/cm², a greater amount of purpura was noted at the PDT+PDL site as compared to the PDL alone site (Figure 1). Starting at a PDT radiant exposure of 75 J/cm², improved efficacy was noted at the PDT+PDL site (Figure 2). Near complete blanching was achieved in one of the subjects who received a light dose of 75 J/cm².

Chromametric Measurements

Chromometer measurement of a* values pre-treatment were compared to those measured at 12 weeks post-treatment. The a* value is a measurement of color on the red-green scale, with higher a* values indicating increasing redness. The average change in a* over the 12 week study period for each of the test sites was as follows: Control 0.48; PDT alone -0.14; PDL alone -2.67; PDT+PDL -3.22. Repeated measures analysis of variance of a* values for control as compared to other test sites revealed statistical significance for the PDL alone group ($p = 0.03$) and the PDT+PDL group ($p = 0.05$). Comparisons between the different intervention sites were not statistically significant.

DISCUSSION

Several important observations were made during this dose ranging study. First, PDT alone and PDT+PDL therapy, using BPD and the selected light parameters, did not demonstrate any major adverse effects. Epidermal changes were limited to fine scabbing in areas treated with the PDL and temporary mild hyperpigmentation in the same areas, all of which resolved without treatment. Similar hyperpigmentation is frequently seen with PDL alone treatment and is generally well tolerated by patients. Prior studies utilizing blue light and red light PDT for PWS treatment have resulted in skin necrosis and ulceration, possibly due to utilization of high light intensities or selection of longer wavelengths. PWS lightening was achieved with PDT

+PDL without adverse effects using a vascular specific photosensitizer (BPD), lower irradiance (100 mW/cm^2) and PDT light doses up to 90 J/cm^2 .

Photosensitizers previously utilized for PDT vascular lesion treatment have resulted in severe photosensitivity of two weeks or more. BPD administration results in a photosensitivity period in humans of 5 days or less. We did carefully counsel subjects regarding photosensitivity precautions and subjects left our center wearing protective clothing. However, several subjects drove after treatment from our center in Southern California to their homes (an hour or more away) without sequelae. Further, no photosensitive reactions were reported, except for the one subject in whom extravasation occurred. As noted above, she reported mild stinging in the area of extravasation, but covering of the area prevented any further cutaneous effects.

Second, improved efficacy of PDT+PDL over PDL alone was observed and was dose-dependent. Increased purpura was noted by the investigators in the PDT+PDL sites of subjects who received PDT radiant exposures equal to or greater than 30 J/cm^2 . We also noted increased blanching of the PDT+PDL sites over PDL sites in subjects that received PDT light doses of 75 or 90 J/cm^2 .

Interestingly, our studies did not find significant improvement of PDT alone as compared to control sites. We expect that higher light or drug doses will be required in order to achieve desired effects with PDT alone. This is undesirable because of time considerations (with the current protocol, dose of 90 J/cm^2 requires 15 min of irradiation) and financial considerations (cost of photosensitizer). Further studies will be required to better elucidate dosing requirements for PDT alone (using BPD and yellow light) for treatment of PWS.

This study builds on findings from our earlier in vivo animal studies demonstrating the potential of the PDT+PDL combination intervention to achieve significant vascular effect. Our current pilot human study provides evidence that PDT+PDL may offer enhanced blanching effect for removal of PWS. We did note that dosing effects noted in animal models were not directly transferable to clinical studies. As such, dose ranging studies such as the current one will be required as protocol adjustments are made.

With additional study of the PDT+PDL treatment protocol, we envision that parameters could be ultimately adjusted based on individual lesion characteristics. Longer wavelengths may be useful for treatment of thicker lesions such as blebbed port wine stain, hemangiomas and other vascular malformations.

In conclusion, in this preliminary report, PDT+PDL was shown to be a potentially efficacious option for treatment of PWS and no long term adverse effects were noted. PDT alone did not result in PWS blanching. Further prospective, comparative, and controlled multi-center clinical studies are required to further develop the PDT+PDL protocol which may offer enhanced efficacy as compared to current standard of care treatment with PDL alone. We are continuing evaluations with the rodent dorsal skin fold window chamber to evaluate the use of alternative light sources and determine methods to safely and effectively irradiate larger treatment areas in a single session. Once our protocol is optimized further, we intend to expand our pilot study into a phase II randomized, clinical trial study testing the effectiveness of PDT+PDL. It is our belief that this protocol may offer an alternative treatment option for PWS birthmarks and may offer a safe and more consistent blanching effect. This protocol may also be adapted for treatment of other cutaneous vascular lesions including malignancies and hemangiomas.

Acknowledgments

This work was supported in part by grants obtained from the National Institutes of Health (AR51443 to KMK), Sturge Weber Foundation (KMK), Arnold and Mabel Beckman Foundation and the A. Ward Ford foundation (BC).

Institutional support was provided by the National Institutes of Health Laser Microbeam and Medical Program (LAMMP). This investigation was also supported by the US Public Health Service research grant M01 RR00827 from the National Center for Research Resources, University of California, Irvine. BPD and administration kits were generously provided by QLT (Vancouver, BC, Canada). We thank Drs. Wim Verkruijsse, Sol Kimel and Lars Svassand for their advice and assistance.

References

1. Kelly KM, Nelson JS. An update on the clinical management of port wine stains. *Lasers Med Sci* 2000;15:220–226.
2. Lanigan SW. Port-wine stains unresponsive to pulsed dye laser: explanations and solutions. *Br J Dermatol* 1998;139:173–177. [PubMed: 9767228]
3. Huikeshoven M, Koster PH, de Borgie CA, Beek JF, van Gemert MJ, van der Horst CM. Redarkening of port-wine stains 10 years after pulsed-dye-laser treatment. *N Engl J Med* 2007;356(12):1235–1240. [PubMed: 17377161]
4. Sickenberg M. Verteporfin therapy for choroidal neovascularization: from concept to proof of efficacy. *Semin Ophthalmol* 2001;16(4):177–180. [PubMed: 15513439]
5. Jeffes EW, McCullough JL, Weinstein GD, Fergin PE, Nelson JS, Shull TF, et al. Photodynamic therapy of actinic keratoses with topical 5-aminolevulinic acid (ALA): a pilot dose-ranging study. *Arch Dermatol* 1997;133:727–732. [PubMed: 9197826]
6. Marcus, SL. Lasers in photodynamic therapy. In: Waynant, RW., editor. *Lasers in Medicine*. Boca Raton: CRC Press; 2002. p. 287–324.
7. Gu Y, Huang NY, Liang J, Pan YM, Liu FG. Clinical study of 1949 cases of port wine stains treated with vascular photodynamic therapy (Gu's PDT). *Ann Dermatol Venereol* 2007;134(3 Pt 1):241–244. [PubMed: 17389848]
8. Qin ZP, Li KL, Ren L, Liu XJ. Photodynamic therapy of port wine stains – a report of 238 cases. *Photodiag Photodyn Ther* 2007;4:53–59.
9. Smith T, Choi B, Ramirez-San-Juan J, Nelson JS, Osann K, Kelly KM. Microvascular blood flow dynamics associated with photodynamic therapy, pulsed dye laser irradiation and combined regimens. *Lasers Surg Med* 2006;38:532–539. [PubMed: 16615132]
10. Fingar VH, Kik PK, Haydon PS, Cerrito PB, Tseng M, Abang E, et al. Analysis of acute vascular damage after photodynamic therapy using benzoporphyrin derivative (BPD). *Br J Cancer* 1999;79:1702–1708. [PubMed: 10206280]
11. Tsoukas MM, Gonzales S, Flotte TJ, Anderson RR, Sherwood ME, Kollias N. Wavelength and fluence effect on vascular damage with photodynamic therapy on skin. *J Invest Dermatol* 2000;114:303–308. [PubMed: 10651990]
12. Houle JM, Strong A. Duration of skin photosensitivity and incidence of photosensitivity reactions after administration of verteporfin. *Retina* 2002;22:691–697. [PubMed: 12476093]
13. Kelly KM, Kimel S, Smith T, Stacy A, Hammer-Wilson M, Svassand LO, et al. Combined photodynamic and photothermal induced injury enhances damage to in vivo model. *Lasers Surg Med* 2004;34:407–413. [PubMed: 15216534]
14. Huang YC, Ringold TL, Nelson JS, Choi B. Noninvasive blood flow imaging for real-time feedback during laser therapy of port wine stain birthmarks. *Lasers Surg Med*. In press.

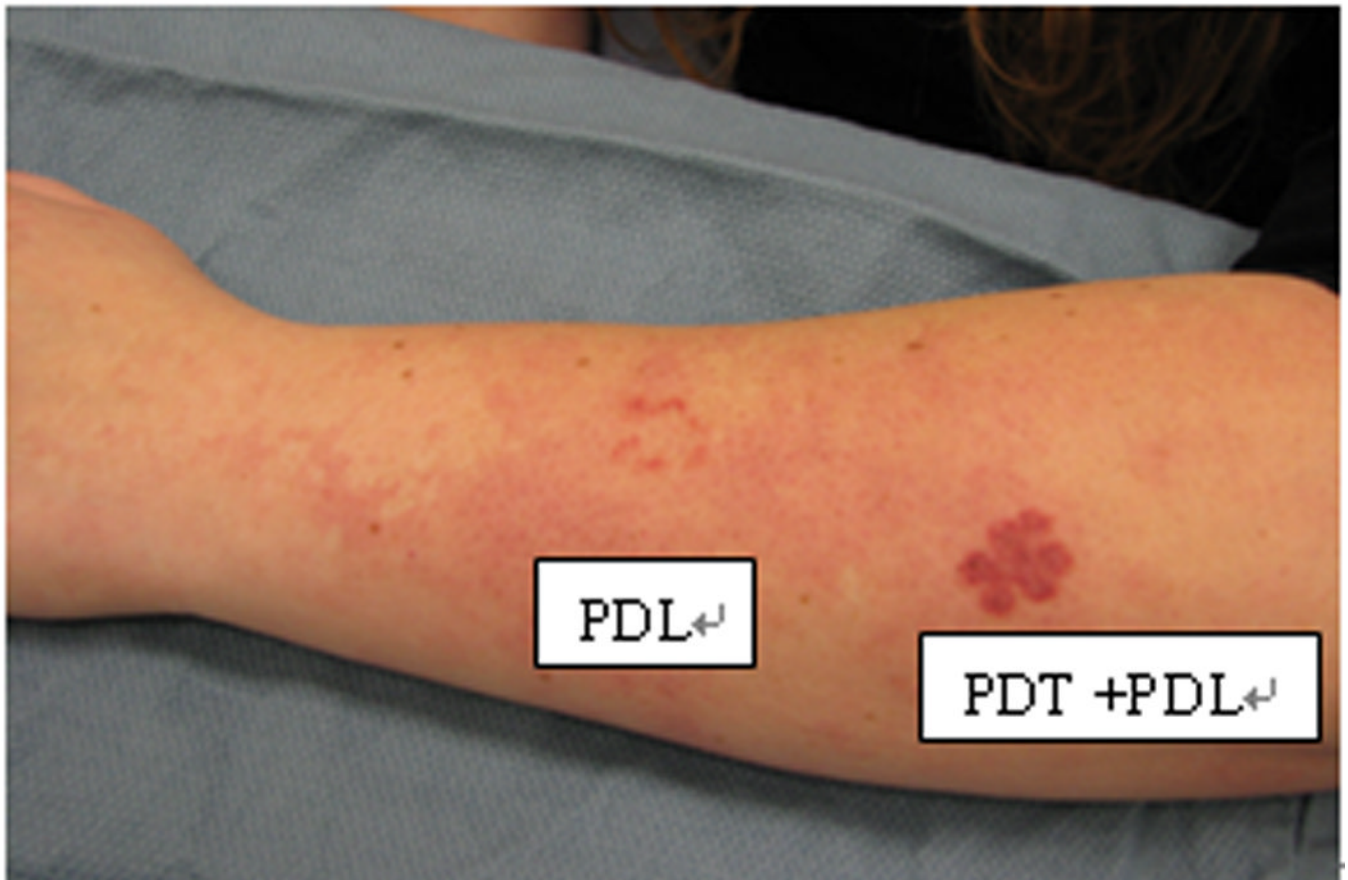


Figure 1. Increased post-treatment purpura noted one week post PDT+PDL treatment as compared to PDL alone therapy (PDT radiant exposure = 45 J/cm²).

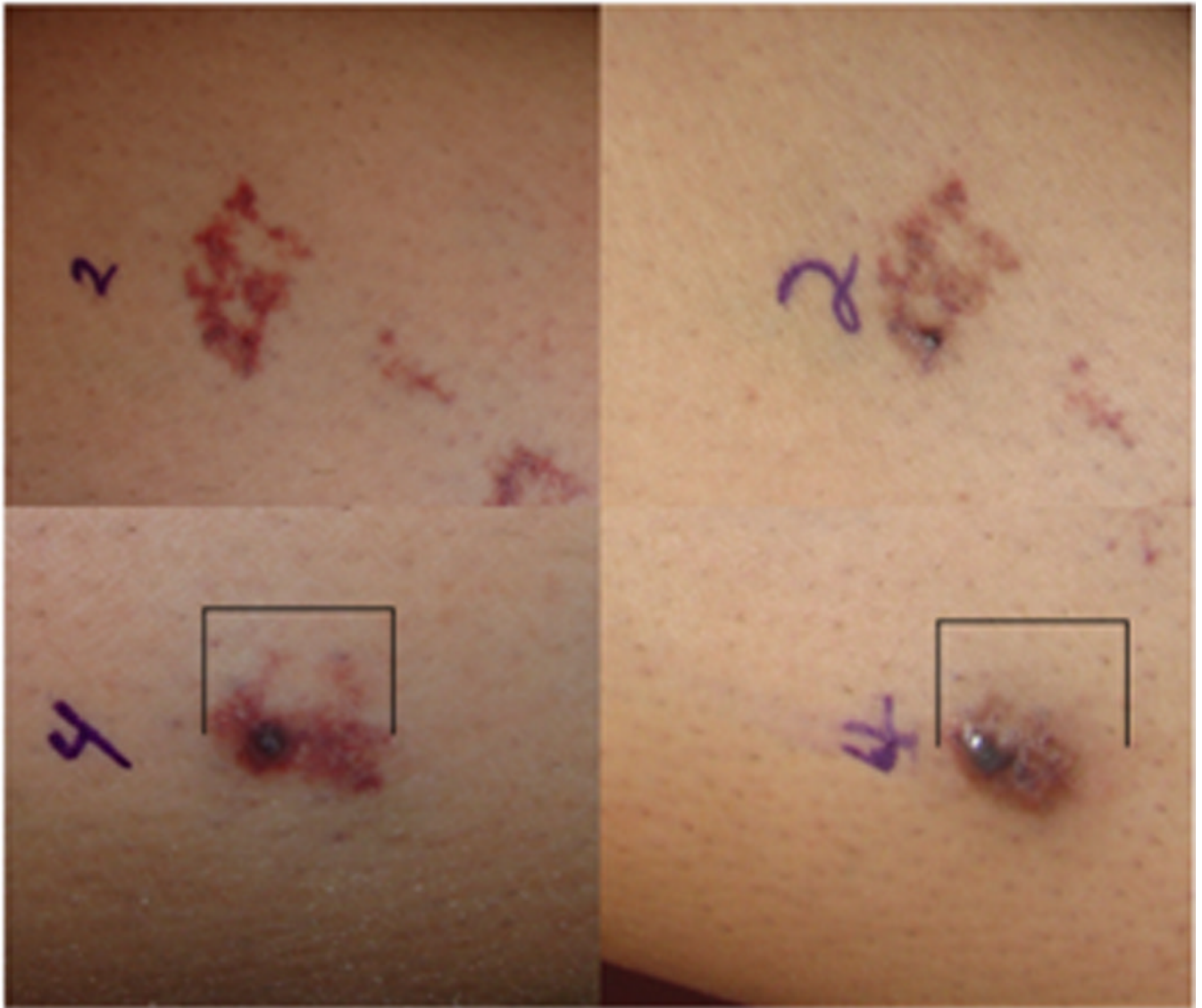


Figure 2. PDL site (test site 2) (top left) prior to and (top right) 12 weeks post-intervention. PDT+PDL (test site 4) (bottom left) prior to and (bottom right) 12 weeks post-intervention. The PDL therapy site remained unchanged in color and size. In contrast, the PDT+PDL treatment site decreased in area by ~50% and some areas of the PWS resolved completely. No changes were noted in control and PDT alone sites.

Table 1

Summary of Treatment Observations by Investigator

PDT Radiant Exposure (J/cm ²)	Subject #	Investigator Observations – PDL alone versus PDT +PDL
15	1 2	0/2 : Difference in purpura 0/2 : Difference in blanching
30	3 4	2/2 : Increased purpura PDT+PDL 0/2 : Difference in blanching
45	5 6	2/2 : Increased purpura PDT+PDL 1/2 : Equal blanching 1/2 : Improved blanching PDT+PDL
60	7 8	2/2 : Increased purpura PDT+PDL 0/2 : Difference in blanching
75	9 10	2/2 : Increased purpura PDT+PDL 2/2 : Improved blanching PDT+PDL
90	11	1/1 : Increased purpura PDT+PDL 1/1 : Improved blanching PDT+PDL