

CLINICAL REPORT

Occlusive Treatment Enhances Efficacy of Tacrolimus 0.1% Ointment in Adult Patients with Vitiligo: Results of a Placebo-controlled 12-month Prospective Study

Anke HARTMANN, Eva-Bettina BRÖCKER and Henning HAMM
Department of Dermatology, University of Würzburg, Würzburg, Germany

Topical tacrolimus was recently introduced as a novel therapeutic option in vitiligo. Excellent results were seen mainly on the face and neck areas. We treated 30 adult vitiligo patients with tacrolimus 0.1% ointment twice daily, and compared the results with those of placebo ointment. In 20 patients, defined areas on the right arm or leg were occluded overnight with 3 different dressings. Repigmentation was evaluated quantitatively and qualitatively. Quality of life changes were assessed with the Dermatology Life Quality Index. After 6 months, treatment was stopped in 7 of 30 patients as they did not show any repigmentation, 5 of them had no occlusive therapy. After 12 months, 17 of 21 patients (81%) with facial involvement showed repigmentation of the face. Although no or minimal repigmentation occurred on the extremities when using tacrolimus ointment alone, 80% of the patients showed repigmentation on the arms when using additional occlusive, especially hydrocolloid dressings. Hands, feet and lower legs were unresponsive. The best results were obtained in patients with long-standing vitiligo. Only minimal side-effects were noted. There was no significant elevation in tacrolimus blood levels, taking into account that occlusion was performed only on limited parts of the body. In conclusion, tacrolimus 0.1% ointment proved an effective and safe treatment option for adult patients with vitiligo. Beyond the face and neck areas, repigmentation could be achieved only by additional occlusion. **Key words:** vitiligo; tacrolimus; calcineurin inhibitors; occlusive dressings; DLQI.

(Accepted January 31, 2008.)

Acta Derm Venereol 2008; 88: 474–479.

Anke Hartmann, Department of Dermatology, University of Erlangen, Hartmannstraße 14, DE-91052 Erlangen, Germany. E-mail: anke.hartmann@uk-erlangen.de

Vitiligo is a common pigmentary disorder that may seriously affect quality of life (QoL). Autoimmune mechanisms are considered responsible for the destruction of melanocytes. This theory is supported by the association of vitiligo with other autoimmune disorders and by the identification of autoantibody-dependent and direct cytotoxic mechanisms (1). Therefore, besides surgical

regimens indicated only in stable vitiligo (2, 3), several immunomodulating strategies are increasingly used for repigmentation of active disease (4–6). Among these, topical and systemic corticosteroids, ultraviolet A (UVA) and ultraviolet B (UVB) phototherapy are the most common. However, limited effectiveness, particularly in acral regions, and local as well as systemic side-effects, especially in long-term therapy, are the main drawbacks of these strategies, and restrict their use, particularly in children.

Recently, a new class of topical immunomodulators, tacrolimus and pimecrolimus, were introduced as treatment modalities for vitiligo. Both have been demonstrated to inhibit the proliferation and activation of T-lymphocytes and to be highly effective and well-tolerated in the treatment of atopic dermatitis (7). Compared with cyclosporine they are 10–100 times more effective and suited for topical use, neither accumulating locally in the skin nor systemically (8). Since 2002, clinical studies of up to 6 months treatment duration in a limited number of patients have favoured the use of calcineurin inhibitors in vitiligo, especially in children, in whom they were shown to be equally as effective as corticosteroids (9–11). However, in adult patients the effect was restricted to the face and neck, whereas lesions in other body regions showed no or little remission (12–14).

In a prospective placebo-controlled right-left comparison study we investigated the efficacy and safety of tacrolimus 0.1% ointment for up to 12 months in 30 adult patients with vitiligo, and tested the influence of additional occlusive treatment. The results show that long-term treatment with topical tacrolimus is effective and safe in patients with long disease duration and that considerable repigmentation on the limbs may be achieved by occlusive therapy.

PATIENTS AND METHODS

Patients

Thirty-one adult vitiligo patients (24 women, 7 men) with symmetrical depigmented lesions were enrolled in a prospective study after obtaining written informed consent. Prior to implementation, this investigator-driven study was approved by the ethics committee of the local medical faculty. Patients with

spontaneous repigmentation and those who had received topical or systemic treatment during the last 6 months were excluded. Thirty patients (23 women, 7 men) with a mean age of 43.7 years (age range 19–65 years) completed the study. Twenty-two patients had vitiligo vulgaris, and 8 had vitiligo acrofacialis, according to the classification of Fitzpatrick (15). The mean disease duration was 15.8 years (range 8 months to 40 years; 11 patients with a disease duration of less than 10 years, 9 patients with more than 20 years, and 10 patients with a duration in between). Two patients had stable disease for more than one year, 28 had a progressive course. Half of the patients had been unsuccessfully treated previously, including corticosteroids, UVB and UVA phototherapy, excimer laser therapy, and topical pseudocatalase. Forty percent of the patients reported a positive family history for vitiligo and 48% a positive history for atopy. Prior to study entry, 2 patients were known to have autoimmune gastritis, 2 patients psoriasis, and one patient alopecia areata. Two patients had photobiological skin type I, 9 had type II, 16 type III, 2 type IV, and one type V.

Treatment regimen

A thin film of tacrolimus 0.1% ointment (Protopic®, Astellas Deutschland GmbH, formerly Fujisawa Deutschland GmbH, Munich, Germany) was applied twice daily on the depigmented lesions of the face and neck (21 of 31 patients) as well as of the right upper and lower extremity (31 patients). On the left side of the limbs a bland emollient (Unguentum Cordes, Ichthyol-Gesellschaft, Hamburg, Germany) was used as placebo. In 20 patients with widespread depigmentation on the right arm and leg, tacrolimus ointment was combined with overnight occlusive dressings in previously defined areas. A transparent household polyethylene foil (12 defined areas), a polyurethane foil (Opsite Flexifix, Smith and Nephew, Hull, UK; 7 areas), or a hydrocolloid wound dressing (Askina Transparent Biofilm, Braun, Melsungen, Germany; 5 areas) were used on depigmented areas of 80–150 cm² size. After 6 months, treatment was stopped if no repigmentation was observed. The responding regions were treated continuously for 12 months.

Evaluation of treatment efficacy and safety

Patients were examined monthly for 4 months, and thereafter bimonthly. At study entry and every 2 months, the size of the treated lesions was documented by digital photography and measured by planimetry. The latter was performed by outlining the margin of the depigmented lesion onto a transparent film with square centimetre division, and calculating the area by addition of the squares included. Treatment efficacy was classified by a grading system used by most investigators: grade 1: 0–25% repigmentation (no or weak effect), grade 2: > 25–50% (moderate effect), grade 3: > 50–75% (good effect), and grade 4: > 75% (excellent effect). Colorimetric assessment of pigmentation (content of melanin) was performed with a Mexameter MX 18 (Courage & Khazaka Electronics GmbH, Cologne, Germany) based on photometry. Melanin content of the vitiligo lesions were measured before treatment and after 6 and 12 months on 4 different points randomly chosen within the depigmented areas, and were compared with uninvolved surrounding skin. Before and at the end of treatment, disease activity was assessed by the Vitiligo Disease Activity (VIDA) score described by Njoo et al. (16). In this scoring system, using the patient's own judgement of the present disease activity, the term "active" is defined as expansion of existing or appearance of new lesions.

Laboratory blood tests, including differential blood count and serum analysis of anti-thyroid antibodies, antinuclear antibodies and total IgE levels, were performed before and after 6 and

12 months of therapy. Tacrolimus serum concentrations were measured after 6 and 12 months, between 6 h and 8 h post-dose, using a micro-enzyme immunoassay (MEIA, Abbott, Wiesbaden, Germany) with a quantification limit of 1.5 ng/ml.

Quality of life assessment

All patients completed the Dermatology Life Quality Index (DLQI) questionnaire introduced by Finlay & Khan (17) immediately before and at the end of the study. The total DLQI score was calculated by addition of the scores of each of the 10 questions, resulting in a score between 0 (no impairment of QoL) and 30 (maximal impairment of QoL). In addition, the following 2 questions relating to special problems of vitiligo patients were addressed: (i) How extensively do you have to protect your skin from sunlight? and (ii) How much are you afraid that the skin lesions will expand? According to the DLQI assessment, 4 alternative responses were allowed: "not at all", "a little", "a lot", or "very much" with corresponding scores of 0, 1, 2 and 3.

Statistical analysis

For statistical evaluation, Student's *t*-test was used by applying Applet Java Software. The significance level was set at $p=0.05$.

RESULTS

Patient profile

Thirty patients (23 women, 7 men) completed 6 months of treatment, one patient dropped out because of non-compliance. After evaluation of treatment outcome at 6 months, all 23 patients responding to therapy continued the study and completed 12 months of treatment. Mean disease activity before therapy, assessed by the VIDA score, was +2.76 (Table I). In 15 patients (50%) elevated anti-thyroid antibodies were found, in 4 patients associated with slightly elevated serum thyroxin levels. In 6 patients IgE levels were raised above the cut-off of 100 kU/l. Ten of 30 patients had positive antinuclear antibodies.

Treatment outcome

The mean \pm standard deviation (SD) amount of tacrolimus 0.1% ointment used per month was 41.6 ± 16.9 g.

Table I. Vitiligo Disease Activity (VIDA) score at entry and end of the study (before and after treatment)

VIDA score	Patients (n)	
	Before treatment	After treatment
+4	12	1
+3	7	1
+2	5	
+1	4	
0	2	5
-1		23
Mean score	+2.76	-0.5

After 6 months, 23 of 30 patients (77%) showed distinct repigmentation, either in the face (mean repigmentation 34.0%) or arms (mean repigmentation 7.3%) when treated with tacrolimus ointment. Whereas the best results were achieved when a hydrocolloid foil was used as occlusive dressing (mean repigmentation 50%), no or weak response was seen on the other lesions. Initial repigmentation was observed in periorbital sites after a mean of 8.9 weeks (range 2–18 weeks), in perioral sites after 12.3 weeks (range 6–24 weeks), and on the lower arms after a mean of 27.8 weeks (range 8–40 weeks). On the dorsum of the hands, the lower legs (with and without occlusion) and on the feet no treatment response was seen in any of the patients. Seven of 30 (23%) patients (5 women, 2 men) did not respond to therapy at all, neither on the face nor on the extremities. Therefore, treatment was stopped in these patients after 6 months. Five of them had used no occlusive therapy, 2 had used polyurethane foil.

After 12 months, 17 of 21 patients (81%) with vitiligo lesions on the face showed repigmentation. Treatment response was rated excellent (grade 4) in 10 patients (Fig. 1), good in 5 patients, moderate in one, and weak or absent (grade 1) in 5 patients. Overall repigmentation was $60.5 \pm 40\%$ in the responding patients and the size of involved areas diminished by $79.4 \pm 27.1\%$ on average. Response to treatment showed a slight correlation with skin phototype, with better a outcome in darker skinned patients.

In 16 of 17 patients (94%) who used additional occlusive dressings on the arms, repigmentation could be observed. Whereas no occlusion, or the use of household polyethylene foil, had no or a weak effect, polyurethane foil and hydrocolloid dressing led to moderate to excellent repigmentation, respectively (Table II, Fig. 2). These results could be confirmed by colorimetric measurement, showing a significant increase in melanin index when polyurethane foil and hydrocolloid

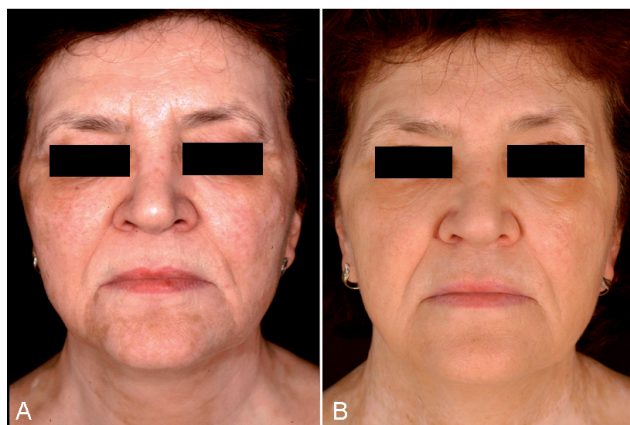

Fig. 1. A 61-year-old woman with progressive vitiligo since 14 years. (A) Before therapy. (B) After 9 months of treatment with 0.1% tacrolimus ointment.

Table II. Mean \pm SD response after 12 months treatment with tacrolimus 0.1% ointment in 30 patients. All patients had lesions on the extremities, 21 of 30 patients had lesions on the face. 7 patients stopped treatment after 6 months because of lack of response

	Occlusion (no. of lesions)	% Repigmentation
Face	None (21)	60.5 ± 40
Arms	None (26)	1.5 ± 4.7
	Polyethylene foil (10)	10.5 ± 7.9
	Polyurethane foil (4)	38.8 ± 20.9
	Hydrocolloid dressing (3)	86.7 ± 5.8
Legs	None (13)	0
	Polyethylene foil (2)	0
	Polyurethane foil (3)	0
	Hydrocolloid dressing (2)	0

SD: standard deviation.

dressing were used (data not shown). Repigmentation started significantly earlier in the hydrocolloid group (11.3 ± 3.4 weeks) compared with the polyurethane group (29.3 ± 4.6 weeks, $p < 0.0001$). However, good therapeutic results could also be achieved in the polyurethane foil group despite later onset of repigmentation (Fig. 3). It was notable that patients with long disease duration showed significantly better results than those with a shorter history. Patients with a disease duration of more than 10 years had an overall mean repigmentation of lesions of the face and arms of $49.7\% \pm 37.9$, compared with $14.7\% \pm 27.3$ in patients with a disease duration of less than 10 years ($p = 0.0009$). Overall disease activity, as assessed by the VIDA score, was significantly decreased at the end of the study ($p < 0.0001$) (Table I). On the placebo-treated sites, 3 patients showed initial

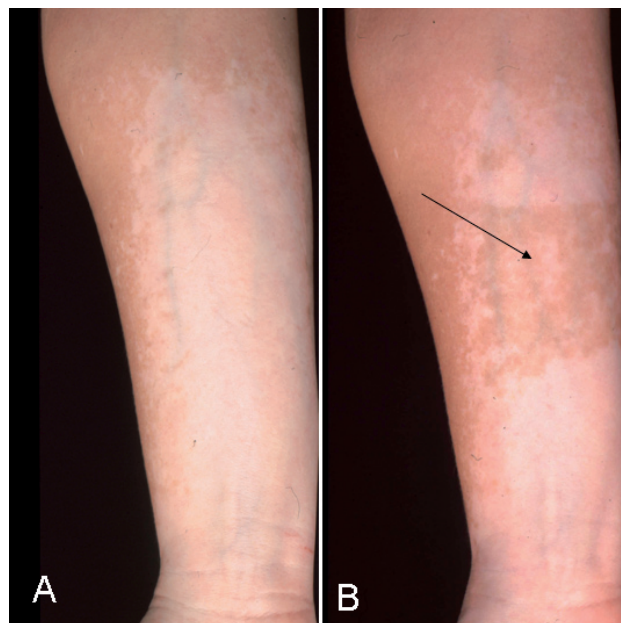


Fig. 2. A 43-year-old woman with progressive vitiligo since 22 years. (A) Before therapy. (B) After 9 months of treatment with 0.1% tacrolimus ointment applied on the entire right arm, combined with hydrocolloid dressing (arrow).

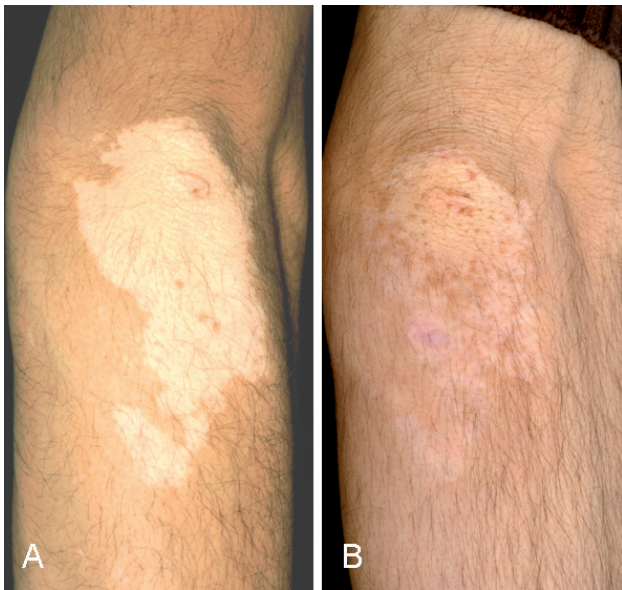


Fig. 3. A 26-year-old man with progressive vitiligo since 14 years. (A) Before therapy. (B) After 12 months of treatment with 0.1% tacrolimus ointment applied on the elbows combined with occlusion by polyurethane foil.

repigmentation and 4 patients had progressive disease despite contralateral repigmentation.

In all but 2 patients tacrolimus serum concentrations were below the detection level (1.5 ng/ml) after 6 and 12 months. Two patients showed detectable levels of 3.0 and 3.6 ng/ml, respectively, after 6 months, and levels below 1.5 ng/ml at the end of the study. However, occlusive treatment was performed in only limited parts of the body. There was no significant change in laboratory parameters and in ANA titres at the end of the treatment period. All of the patients showing elevated anti-thyroid antibodies were induced to take a specific medication. In 3 patients the anti-thyroid antibodies were increased and in 8 of 15 patients the initially elevated levels were lowered at the end of treatment. Total IgE levels were increased in 3 and decreased in one patient at the end of the study.

Adverse effects

Side-effects were documented in 80% of the patients. In most cases, they were of minor degree and confined to the application sites. Adverse events included transient facial flushing ($n = 16$), enhanced heat intolerance ($n = 9$), especially when drinking alcohol, burning ($n = 4$), mild pruritus ($n = 2$), and mild perioral folliculitis ($n = 2$). Facial flushing occurred irrespective of whether or not tacrolimus ointment was applied on the face. In 11 patients it was present during the entire treatment period, and in 3 patients it was described as moderate to severe. Interestingly, all 6 patients reporting none of these adverse events belonged to the treatment group with no or minimal repigmentation. None of the side-effects led to discontinuation of therapy. No skin

atrophy, teleangiectasia, cutaneous infections or ocular problems were observed or reported by the patients. No systemic side-effects related to administration of tacrolimus ointment were noticed.

Quality of life

The mean \pm SD DLQI score was 12.4 ± 6.5 (range 2–27) before treatment and decreased to mean \pm SD 9.3 ± 5.6 (range 1–23) after 12 months of therapy, indicating significant improvement of QoL ($p = 0.001$). The initial mean DLQI score for patients with no or poor treatment response (group A, 12.0 ± 7.2) was comparable to those for patients with moderate to excellent results (group B–D, 12.6 ± 6.2). However, at the end of therapy, mean DLQI score in the latter groups was 8.6 ± 4.9 , in contrast to 10.3 ± 6.9 for patients in the group treated without success. Thus, response to treatment could ameliorate the DLQI score significantly ($p = 0.006$) whereas no or poor outcome did not. As to the 2 additional questions, 50% of the patients agreed to the need for protection against sunlight and 80% agreed to fear of progression with the highest score at the beginning of the study. At the end of treatment, question 1 improved by 40%, and question 2 by 29.3%, as calculated according to the DLQI.

DISCUSSION

Topical corticosteroids and phototherapy are the most common treatment options currently used in vitiligo. Long-term therapy, however, which is mostly required to obtain and maintain efficient repigmentation is hampered because of local and systemic side-effects.

Topical calcineurin inhibitors, especially tacrolimus, have recently been shown to be a new promising therapeutic tool in vitiligo (9–14). In a right-left comparison study of 2 months duration on children, tacrolimus 0.1% ointment was found to be as effective as 0.05% clobetasol propionate (9). In a recent open-label study on 19 patients with minimum age of 15 years, twice daily application of 0.1% tacrolimus over 6 months led to excellent repigmentation on the face and neck areas in 68% of patients, whereas no significant effect could be achieved on the trunk and extremities (12). Patients with a disease duration of more than 10 years were excluded.

Although protection from the sun during treatment with tacrolimus ointment is recommended by the manufacturer, several clinical studies propagate the enhancing effect of UVB phototherapy in combination with tacrolimus in inducing repigmentation (18–20). In a study on 110 patients, combined treatment of tacrolimus and narrow-band UVB led to good to excellent response in 42% of the lesions. However, the effect on the extremities was disappointing (18). Whereas in pla-

cebo-controlled studies the combined use of tacrolimus ointment and 308-nm excimer laser was superior to laser treatment alone (19, 20), tacrolimus in combination with narrow-band UVB did not prove more efficient than UVB phototherapy alone (14).

In the present prospective study we evaluated the placebo-controlled application of tacrolimus 0.1% ointment for up to 12 months in 30 adult patients with vitiligo. By the end of treatment, 17 of the 21 patients with facial lesions (81%) showed repigmentation on the face and neck areas (mean response of 79.4% surface area). On the extremities there was almost no effect when applying tacrolimus ointment openly, which is in accordance with previous results (12). However, when using polyurethane foil or hydrocolloid dressing for overnight occlusive treatment, moderate to excellent repigmentation could be achieved, depending on the dressing used. Thus, we showed for the first time that occlusion therapy can enhance the effect of topical tacrolimus therapy in vitiligo. As hydrocolloid dressings lead to higher stratum corneum water holding capacity compared with polyurethane foils (21), they may be more suitable for enhancing transcutaneous penetration of topically applied agents. In the past, tacrolimus and pimecrolimus have been shown to be effective in descaled plaque-type psoriasis and pyoderma gangrenosum, when applied under plastic foils as occlusive bandages, with no local or systemic side-effects (22, 23). However, serum concentrations of the drugs were not measured. In our study, all patients had tacrolimus serum levels below the detection limit of 1.5 ng/ml after 12 months, indicating that long-term topical treatment with additional long-term occlusion of areas up to 150 cm² does not lead to accumulation of tacrolimus in the blood. Detectable tacrolimus blood levels were found in only 2 patients after 6 months, but below the level of 5–20 ng/ml intended for systemic treatment (24). In both patients, tacrolimus levels were below the detection limit in subsequent measurements. Several retrospective studies on more than 300,000 children and adults did not indicate an increased risk of non-melanoma skin cancer or lymphoma in those treated with topical calcineurin inhibitors (25, 26).

Like other topical treatment modalities in vitiligo, tacrolimus achieves the best results when used on the face and neck areas. This fact has been explained by the greater density of hair follicles in these areas and, thus, the greater melanocyte reservoir (27, 28). Recently, it could be shown that tacrolimus significantly enhances the proliferation of both melanocytes and melanoblasts (29). In our study, treatment response showed a slight correlation with skin type, as excellent results were more often seen in darker skinned patients.

Previous studies have not analysed the relationship between the duration of vitiligo and the therapeutic success of topical immunomodulators. In a recent

study, patients with a disease duration of greater than 10 years have even been excluded (12). Interestingly, in our study patients with a history of more than 10 years benefited more from tacrolimus treatment than patients with shorter histories.

In accordance with previous observations, our study showed that vitiligo affects the QoL of the patients to a significant extent, comparable to that in patients with atopic dermatitis (4, 16, 30). Depending on the treatment outcome, QoL may improve significantly (32% in patients with moderate to excellent results compared with 14% in cases with poor outcome).

In conclusion, tacrolimus ointment seems to be a safe and effective treatment option for vitiligo in adult patients, even in those with long disease duration and in long-term treatment. It may significantly improve the QoL of affected patients. In regions beyond the face and neck, additional occlusion may significantly enhance the therapeutic result and may shorten the time until the start of repigmentation. Larger placebo-controlled studies using calcineurin inhibitors in combination with occlusion, penetration enhancers, or phototherapy, or in higher concentrations, are required to determine the exact role of these potent drugs in vitiligo treatment and their optimal mode of use.

ACKNOWLEDGEMENTS

The authors wish to thank Fujisawa Deutschland GmbH, Munich, Germany, for financial support of this study and Mr G. A. Krämer for performing digital photography.

Conflict of interest: This investigator-driven study was sponsored by Fujisawa Deutschland GmbH, Munich, Germany. The publication was supported by Astellas Pharma GmbH. The authors have no other financial or non-financial conflicts of interest.

REFERENCES

1. Ongena K, Van Geel N, Naeyaert JM. Evidence for an autoimmune pathogenesis of vitiligo. *Pigment Cell Res* 2003; 16: 90–100.
2. Njoo MD, Westerhof W, Bos JD, Bossuyt PM. A systematic review of autologous transplantation methods in vitiligo. *Arch Dermatol* 1998; 134: 1543–1549.
3. Hartmann A, Brocker EB, Hamm H. Repigmentation of depigmented hairs in stable vitiligo by transplantation of autologous melanocytes in fibrin suspension. *J Eur Acad Derm Venereol* 2008; 22: 624–626.
4. Hartmann A, Lurz C, Hamm H, Brocker EB, Hofmann UB. Narrow-band UVB311 nm vs. broad-band UVB therapy in combination with topical calcipotriol vs. placebo in vitiligo. *Int J Dermatol* 2005; 44: 736–742.
5. Tjoe M, Gerritsen MJ, Juhlin L, van de Kerkhof PC. Treatment of vitiligo vulgaris with narrow band UVB (311nm) for one year and the effect of addition of folic acid and vitamin B12. *Acta Derm Venereol* 2002; 82: 369–372.
6. Hartmann A, Brocker EB, Becker JC. Hypopigmentary skin disorders: current treatment options and future directions. *Drugs* 2004; 64: 89–107.

7. Paller AS, Lebwohl M, Fleischer AB Jr, Antaya R, Langley RG, Kirsner RS, et al. Tacrolimus ointment is more effective than pimecrolimus cream with a similar safety profile in the treatment of atopic dermatitis: results from 3 randomized, comparative studies. *J Am Acad Dermatol* 2005; 52: 810–822.
8. Cather JC, Abramovits W, Menter A. Cyclosporine and tacrolimus in dermatology. *Dermatol Clin* 2001; 19: 119–137.
9. Lepe V, Moncada B, Castaneda-Cazares JP, Torres-Alvarez MB, Ortiz CA, Torres-Rubalcava AB. A double-blind randomized trial of 0.1% tacrolimus vs 0.05% clobetasol for the treatment of childhood vitiligo. *Arch Dermatol* 2003; 139: 581–585.
10. Coskun B, Saral Y, Turgut D. Topical 0.05% clobetasol propionate versus 1% pimecrolimus ointment in vitiligo. *Eur J Dermatol* 2005; 15: 88–91.
11. Silverberg NB, Lin P, Travis L, Farley-Li J, Mancini AJ, Wagner AM, et al. Tacrolimus ointment promotes repigmentation of vitiligo in children: a review of 57 cases. *J Am Acad Dermatol* 2004; 51: 760–766.
12. Grimes PE, Morris R, Avaniss-Aghajani E, Soriano T, Meraz M, Metzger A. Topical tacrolimus therapy for vitiligo: therapeutic responses and skin messenger RNA expression of proinflammatory cytokines. *J Am Acad Dermatol* 2004; 51: 52–61.
13. Dawid M, Veensalu M, Grassberger M, Wolff K. Efficacy and safety of pimecrolimus cream 1% in adult patients with vitiligo: results of a randomized, double-blind, vehicle-controlled study. *J Dtsch Dermatol Ges* 2006; 4: 942–946.
14. Mehrabi D, Pandya AG. A randomized, placebo-controlled, double-blind trial comparing narrowband UV-B plus 0.1% tacrolimus ointment with narrowband UV-B plus placebo in the treatment of generalized vitiligo. *Arch Dermatol* 2006; 142: 927–928.
15. King RA, Oetting WS. Disorders of melanocytes. In: Freedberg IM, Eisen AZ, Wolff K, Austen F, Goldsmith LA, Katz SI, Fitzpatrick TB, editors. *Dermatology in general medicine*. New York: McGraw-Hill, 1999: p. 925–936.
16. Njoo MD, Bos JD, Westerhof W. Treatment of generalized vitiligo in children with narrow-band (TL-01) UVB radiation therapy. *J Am Acad Dermatol* 2000; 42: 245–253.
17. Finlay AY, Khan GK. Dermatology Life Quality Index (DLQI) – a simple practical measure for routine clinical use. *Clin Exp Dermatol* 1994; 19: 210–216.
18. Fai D, Cassano N, Vena GA. Narrow-band UVB phototherapy combined with tacrolimus ointment in vitiligo: a review of 110 patients. *J Eur Acad Derm Venereol* 2007; 21: 916–920.
19. Kawalek AZ, Spencer JM, Phelps RG. Combined excimer laser and topical tacrolimus for the treatment of vitiligo: a pilot study. *Dermatol Surg* 2004; 30: 130–135.
20. Passeron T, Ostovari N, Zakaria W, Fontas E, Larrouy JC, Lacour JP, Ortonne JP. Topical tacrolimus and the 308-nm excimer laser: a synergistic combination for the treatment of vitiligo. *Arch Dermatol* 2004; 140: 1065–1069.
21. Berardesca E, Vignoli GP, Fideli D, Maibach H. Effect of occlusive dressings on the stratum corneum water holding capacity. *Am J Med Sci* 1992; 304: 25–28.
22. Mrowietz U, Graeber M, Brautigam M, Thurston M, Wagenaar A, Weidinger G, Christophers E. The novel ascocmycin derivative SDZ ASM 981 is effective for psoriasis when used topically under occlusion. *Br J Dermatol* 1998; 139: 992–996.
23. Schuppe HC, Homey B, Assmann T, Martens R, Ruzicka T. Topical tacrolimus for pyoderma gangrenosum. *Lancet* 1998; 351: 832.
24. Prograf 5mg/ml. Astellas Pharma GmbH, Fachinformation, April 2006.
25. Arellano FM, Wentworth CE, Arana A, Fernandez C, Paul CF. Risk of lymphoma following exposure to calcineurin inhibitors and topical steroids in patients with atopic dermatitis. *J Invest Dermatol* 2007; 127: 808–816.
26. Margolis DJ, Hoffstad O, Bilker W. Lack of association between exposure to topical calcineurin inhibitors and skin cancer in adults. *Dermatology* 2007; 214: 289–295.
27. Ortonne JP, Schmitt D, Thivolet J. PUVA-induced repigmentation of vitiligo scanning electron microscopy of hair follicles. *J Invest Dermatol* 1980; 74: 40–42.
28. Cui J, Shen LY, Wang GC. Role of hair follicles in the repigmentation of vitiligo. *J Invest Dermatol* 1991; 97: 410–416.
29. Lan CC, Chen GS, Chiou MH, Wu CS, Chang CH, Yu HS. FK506 promotes melanocyte and melanoblast growth and creates a favourable milieu for cell migration via keratinocytes: possible mechanisms of how tacrolimus ointment induces repigmentation in patients with vitiligo. *Br J Dermatol* 2005; 153: 498–505.
30. Parsad D, Pandhi R, Dogra S, Kanwar AJ, Kumar B. Dermatology Life Quality Index score in vitiligo and its impact on the treatment outcome. *Br J Dermatol* 2003; 148: 373–374.