

JAMA Facial Plastic Surgery | Original Investigation

Photographic Standards for Patients With Facial Palsy and Recommendations by Members of the Sir Charles Bell Society

Katherine B. Santosa, MD; Adel Fattah, MD, PhD; Javier Gavilán, MD; Tessa A. Hadlock, MD; Alison K. Snyder-Warwick, MD

IMPORTANCE There is no widely accepted assessment tool or common language used by clinicians caring for patients with facial palsy, making exchange of information challenging. Standardized photography may represent such a language and is imperative for precise exchange of information and comparison of outcomes in this special patient population.

OBJECTIVES To review the literature to evaluate the use of facial photography in the management of patients with facial palsy and to examine the use of photography in documenting facial nerve function among members of the Sir Charles Bell Society—a group of medical professionals dedicated to care of patients with facial palsy.

DESIGN, SETTING, AND PARTICIPANTS A literature search was performed to review photographic standards in patients with facial palsy. In addition, a cross-sectional survey of members of the Sir Charles Bell Society was conducted to examine use of medical photography in documenting facial nerve function. The literature search and analysis was performed in August and September 2015, and the survey was conducted in August and September 2013.

MAIN OUTCOMES AND MEASURES The literature review searched EMBASE, CINAHL, and MEDLINE databases from inception of each database through September 2015. Additional studies were identified by scanning references from relevant studies. Only English-language articles were eligible for inclusion. Articles that discussed patients with facial palsy and outlined photographic guidelines for this patient population were included in the study. The survey was disseminated to the Sir Charles Bell Society members in electronic form. It consisted of 10 questions related to facial grading scales, patient-reported outcome measures, other psychological assessment tools, and photographic and videographic recordings.

RESULTS In total, 393 articles were identified in the literature search, 7 of which fit the inclusion criteria. Six of the 7 articles discussed or proposed views specific to patients with facial palsy. However, none of the articles specifically focused on photographic standards for the population with facial palsy. Eighty-three of 151 members (55%) of the Sir Charles Bell Society responded to the survey. All survey respondents used photographic documentation, but there was variability in which facial expressions were used. Eighty-two percent (68 of 83) used some form of videography. From these data, we propose a set of minimum photographic standards for patients with facial palsy, including the following 10 static views: at rest or repose, small closed-mouth smile, large smile showing teeth, elevation of eyebrows, closure of eyes gently, closure of eyes tightly, puckering of lips, showing bottom teeth, snarling or wrinkling of the nose, and nasal base view.

CONCLUSIONS AND RELEVANCE There is no consensus on photographic standardization to report outcomes for patients with facial palsy. Minimum photographic standards for facial paralysis publications are proposed. Videography of the dynamic movements of these views should also be recorded.

LEVEL OF EVIDENCE NA.

JAMA Facial Plast Surg. 2017;19(4):275-281. doi:10.1001/jamafacial.2016.1883
Published online January 26, 2017.

 Video

 Supplemental content

Author Affiliations: Author affiliations are listed at the end of this article.

Corresponding Author: Alison K. Snyder-Warwick, MD, Facial Nerve Institute, Division of Plastic and Reconstructive Surgery, Department of Surgery, Washington University School of Medicine, 660 S Euclid Ave, Campus Box 8238, St Louis, MO 63110 (snyderak@wudosis.wustl.edu).

To date, facial expression has been found to be the richest source of information about emotions.

Paul Ekman^{1(p3449)}

Regarded as a pioneer in the study of emotions and microexpressions, psychologist Paul Ekman¹ captures the integral role of facial expressions in recognizing emotions, which allows us to connect with one another on the most basic level. However, for patients with facial palsy, this fundamental visual tool of communication is compromised. The inability to communicate thoughts and interact with others is debilitating and results in substantial psychosocial morbidity in this patient population.^{2,3}

In addition, treatment of facial nerve disorders is challenging. Patients are seen with a diverse array of deficits, and various procedures and interventions exist for management. Given the amount of variability that can exist in how patients with facial palsy are seen and treated, it is imperative that clinicians caring for these patients use a uniform tool to document their outcomes. In essence, a single language is needed to allow meaningful comparison of outcomes.

The use of standardized high-quality medical photography is one method that can improve information exchange and outcome comparison in this patient population. Standards and guidelines for medical photography within various disciplines in plastic surgery, such as hand surgery, body contouring, and cosmetic surgery, have been thoroughly described.⁴⁻⁶ For example, in cosmetic surgery alone, a literature review revealed 79 articles describing photographic standards for various procedures, with most dedicated to standards for patients with rhinoplasty. Moreover, outcomes of facial reanimation procedures, similar to cosmetic surgery cases, are largely based on visual improvements after surgery.³ However, while a few studies⁷⁻⁹ have proposed the need for photographic standards for patients with facial palsy, no studies have addressed this specific topic in detail.

In this study, we performed a literature review of photographic standards among patients with facial palsy and performed a cross-sectional survey of members of the Sir Charles Bell Society (SCBS) (<http://www.sircharlesbell.org>) to examine the use of medical photography among clinicians devoted to treating patients with facial palsy. The SCBS is an international multidisciplinary group of health care professionals dedicated to progressing the management of facial nerve disorders. Because this group of practitioners focuses on care of the population with facial palsy, the society membership is a valuable group from which to canvas information. From these data, we propose a set of minimum photographic standards for patients with facial palsy and anticipate that they will be widely adopted and ultimately improve outcomes and enhance progress in the management of patients with facial paralysis.

Methods

Institutional review board approval was not required because this study involved a survey of health care professionals and a literature review; it did not involve patients or inter-

Key Points

Question How do clinicians specializing in facial paralysis use photography and videography to document facial nerve function in this special patient population?

Findings A cross-sectional survey of the Sir Charles Bell Society members, a group of professionals dedicated to caring for patients with facial palsy, revealed that all members used some form of photography to document outcomes; however, there was variability in which facial expressions were used.

Meaning There is no consensus on photographic standardization to report outcomes for patients with facial palsy; therefore, we propose minimum photographic standards for facial paralysis publications to improve exchange of information and comparison of outcomes.

ventions and did not include research on patients or animals. Patient information and care were not included in the study. The cross-sectional survey was disseminated to SCBS members in electronic form using an online tool. Participation in this web-based survey was voluntary, all responses were anonymous, and informed consent was waived given the minimal risks to participants. Waiver of informed consent was the consensus of multiple participating institutions.

The literature review searched EMBASE, CINAHL, and MEDLINE databases from inception of each database through September 2015. Under the guidance of a medical librarian, this search strategy involved Medical Subject Headings and free-text terms relating to facial palsy and photography (ie, *facial paralysis*, *facial reanimation*, *facial nerve weakness*, *facial nerve dysfunction*, *facial palsy*, *photography*, and *standards*). Additional studies were identified by scanning references from relevant studies. Only English-language articles were eligible for inclusion. These citations were imported into a computer program (EndNote X7; Clarivate Analytics), and any duplicates were identified and discarded. Articles that were included met the following criteria: they (1) discussed patients with facial palsy and (2) outlined photographic guidelines for this patient population. The lead authors (K.B.S. and A.K.S.-W.) reviewed each study according to these criteria. The literature review and analysis were performed in August and September 2015.

The cross-sectional survey (eFigure 1 in the Supplement) was disseminated to SCBS members in electronic form using an online tool (Qualtrics; <http://www.qualtrics.com>). This survey consisted of 10 questions related to facial grading scales, patient-reported outcome measures, other psychological assessment tools, and photographic and videographic recordings. Of these 10 questions, 6 were specifically directed toward the use of photography and videography in the practice of these clinicians. Careful attention to the creation of these questions was taken to avoid bias in responses. Closed single-response questions were used to categorize responses. Where necessary, open-ended "other" categories were used to allow respondents to specify details in free-text form. The survey and analysis were performed in August and September 2013.

Table 1. Results From the Literature Review

Source	Study Title	Views Discussed	Summary of Article
Ellis and Gillies, ¹⁰ 1979	"Evaluation of the Paralyzed Face"	Resting, frowning, squinting, eyebrow lifting, smiling, smiling with lower lip depression, pursing the lips	Authors describe how clinicians should evaluate the paralyzed face. They assert that standardized photographs serve as medicolegal documentation and will allow the surgeon to select the appropriate management strategy.
Mitchell, ¹¹ 1981	"Preoperative and Postoperative Photographic Standards"	Repose, maximal mimic muscle contraction	This letter to the editor was written in response to an article on interfascicular facial nerve repair. The author's critique was that there was inadequate documentation of the patient's outcome in the original article and argues for the need for standardization of photography in publications for this patient population.
el-Naggar et al, ⁹ 1995	"Life-Size Photograph Transparencies: A Method for the Photographic Detection and Documentation of Recovery From Facial Paralysis"	Not applicable	By overlapping life-size photographic transparencies, the authors argue that this method provides an objective method to track the progress of a patient with facial palsy.
Barrs et al, ¹² 2001	"Digital Camera Documentation System for Facial Nerve Outcome Assessment"	Raising eyebrows, eyes closed tightly, smiling, puckering of lips, wrinkling of nose, drawing corner of mouth down	The authors describe an easy and efficient method to document facial nerve function by digital photography.
Henderson et al, ⁶ 2005	"Photographic Standards for Facial Plastic Surgery"	Anterior-posterior left and right lateral, left and right oblique, smile, pucker, wrinkle nose, close eyes tight, eyebrows raised	Through a series of photographs, the aim of the article is to provide the reader with guidelines and photographic standards for special facial plastic and reconstructive procedures (ie, rhinoplasty, mentoplasty, blepharoplasty, rhytidectomy or facial reanimation, browplasty, cheiloplasty, and cleft lip repair).
Schaaf et al, ¹³ 2006	"Standards for Digital Photography in Cranio-Maxillo-Facial Surgery, Part II: Additional Picture Sets and Avoiding Common Mistakes"	Full frontal view, closed eyes, wrinkling forehead, smiling, front view whistling, blowing out cheeks	The 2-part publication provides a set of photographic views for different craniofacial procedures. These standardized sets of photographs were approved and adopted by the Council of the European Association for Cranio-Maxillo-Facial Surgeons in 2005.
Niziol et al, ⁷ 2015	"Is There an Ideal Outcome Scoring System for Facial Reanimation Surgery? A Review of Current Methods and Suggestions for Future Publications"	Repose, eyebrows maximally raised, eyes tightly closed, narrow smile, maximum smile	This article was written as a literature review to identify an ideal scoring system for facial palsy. In their discussion, the authors note an abundance of grading scales that exist in the literature and propose a "quick and simple system" using a set of standardized still photographs.

Results

Summary of the Literature Review

In total, the database searches retrieved 435 citations. After review in the computer program, 43 duplicates were identified, leaving 392 citations that fit our search criteria. One additional citation was included after scanning references of relevant articles. After title, abstract, and full-text analysis by the lead authors, 7 studies met the final inclusion criteria. Publication dates ranged from 1979 to 2015. Six of the 7 articles discussed or proposed views specific to patients with facial palsy. However, none of the articles specifically focused on photographic standards for the population with facial palsy. Details of the literature search are listed in Table 1.

Survey Findings

We received responses from 83 of the 151 SCBS members (55%). All survey respondents used still photography. Of all views to capture facial nerve function, the 4 views that were most commonly used by respondents were at rest or repose (99.8% [82 of 83]), large smile showing teeth (92.8% [77 of 83]), elevation of eyebrows (88.0% [73 of 83]), and closure of eyes gently (88.0% [73 of 83]) (Figure 1A). These views are included in the House-Brackmann Facial Nerve Grading System and the Sunnybrook Facial Grading System, which were the 2 most commonly used grading systems by respondents in our survey. Of all respondents, 60.2% (50 of 83) reported using the House-Brackmann Facial Nerve Grading System to monitor facial nerve function, while 51.8% (43 of 83) reported using the

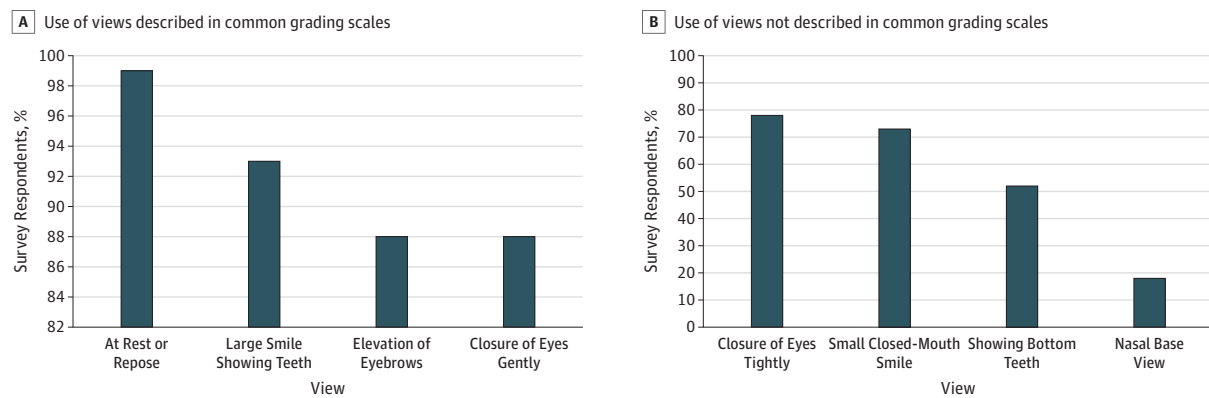
Sunnybrook Facial Grading System. The views not specifically mentioned in common grading scales were used less frequently and included closure of eyes tightly (78.3% [65 of 83]), small closed-mouth smile (73.4% [61 of 83]), showing bottom teeth (51.8% [43 of 83]), and nasal base view (18.1% [15 of 83]) (Figure 1B). Puckering of lips and snarling or wrinkling of the nose, which are described in the Sunnybrook Facial Grading System but not in the House-Brackmann Facial Nerve Grading System, were used by 81.9% (68 of 83) and 61.4% (51 of 83) of SCBS members, respectively. Additional free-texted views included puffing out cheeks (n = 1) and lateral views (n = 2).

Our group has reported videography use rates among SCBS members in a previous publication.¹⁴ In summary, 81.9% (68 of 83) of survey respondents reported using videography, of whom 70.6% (48 of 68) reported documenting the same movements on videography as in still photography.

Discussion

Although photographic standards have been well described and adopted in other highly visual fields of plastic surgery, such as cosmetic surgery, to our knowledge, no universal standards exist for patients with facial palsy or facial reanimation. Our literature search revealed few studies of photographic standards in patients with facial palsy, with only 7 articles describing the importance of medical photography in our patient population. Even among 6 of the 7 articles that propose specific photographic views for patients with facial palsy, there are notable differences in the number and selection of

Figure 1. Survey Findings



Responses were received from 83 of the 151 Sir Charles Bell Society members (55.0%). All survey respondents used still photography.

still views (Table 1). For example, the only view that was consistently proposed throughout the 6 articles was the full frontal view at rest or repose.

Similar to the literature review findings, our survey of SCBS members demonstrated variability in the types of views used by clinicians. Most respondents documented similar static views; however, not all of these views were used by all respondents. The 4 most common views (ie, at rest or repose, large smile showing teeth, elevation of eyebrows, and closure of eyes gently) are those that are described in the 2 most commonly used assessment scales by SCBS members, the House-Brackmann Facial Nerve Grading System and the Sunnybrook Facial Grading System. Less frequently obtained views, such as closure of eyes tightly, small closed-mouth smile, showing bottom teeth, and nasal base view, coincidentally are those not described in the 2 common scales.

Visual documentation of outcomes is incomplete even among SCBS members, whose practices focus more on care of patients with facial palsy. In other words, our findings reveal that almost half of the SCBS members are not documenting the function of all branches of the facial nerve. Dysfunction of the marginal mandibular branch commonly occurs in isolation, such as iatrogenically, acquired in association with a mandible fracture, or congenitally (eg, in asymmetric crying facies). Regardless of the mechanism of injury or presentation, testing and documenting the function of this branch is an integral aspect of a comprehensive facial nerve examination. Similarly, another view substantially underused by survey respondents and absent from our literature review was the nasal base view, which has also been discussed by Bhamra and colleagues.⁸ This view is especially important to assess symmetry of the external valve. Nasal obstruction is a common but underrecognized problem among patients with facial palsy, and static or dynamic support of the external nasal valve can improve patients' perception of nasal airflow.¹⁵

As demonstrated by our literature review and survey findings, there is substantial heterogeneity and a lack of consensus in photographic documentation of this patient population. Therefore, we propose a standardized set of photographs

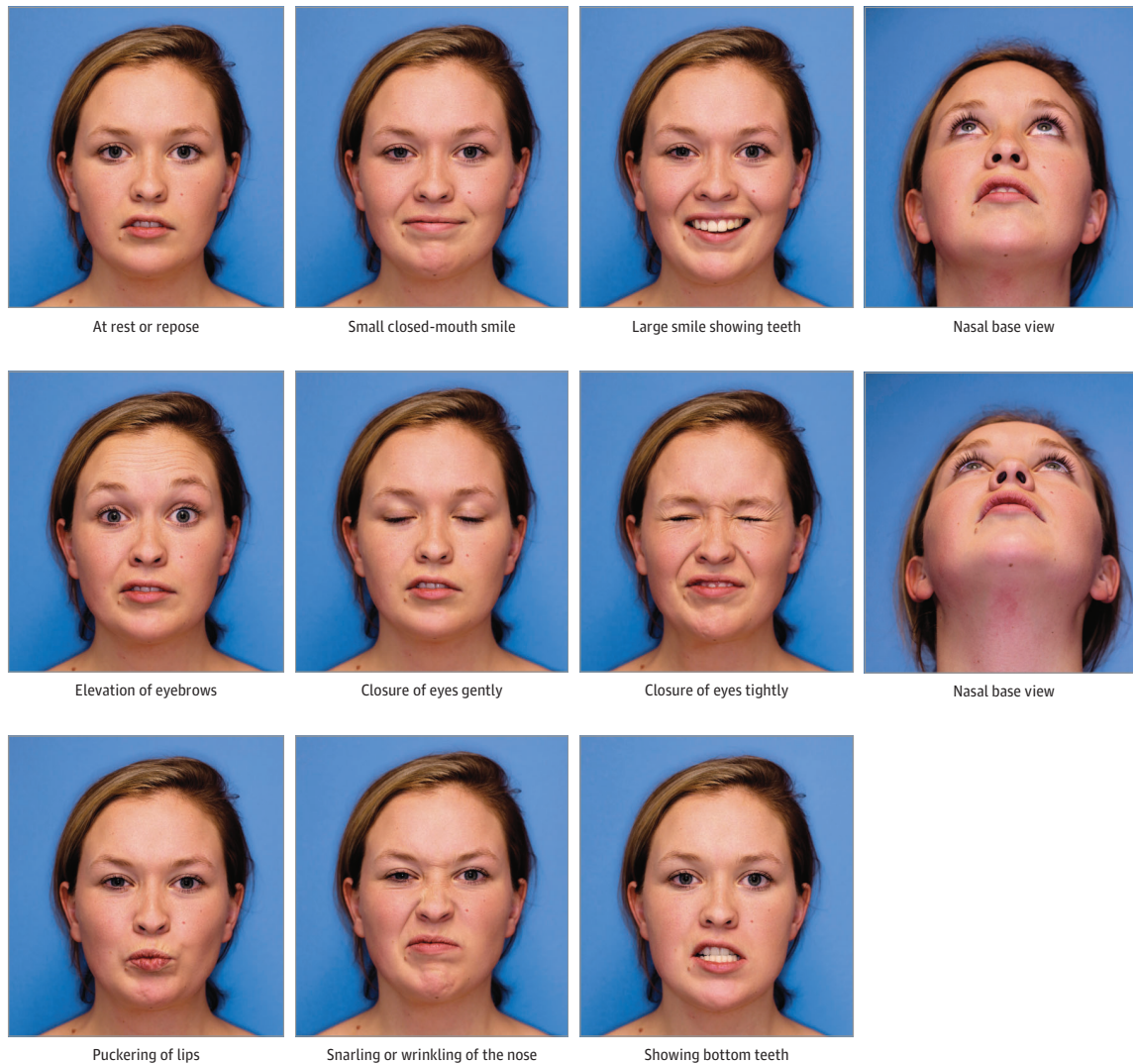
that should be used in outcomes analysis to improve information exchange and data comparison. This minimum set consists of the following 10 static views (Figure 2): (1) at rest or repose, (2) small closed-mouth smile, (3) large smile showing teeth, (4) elevation of eyebrows, (5) closure of eyes gently, (6) closure of eyes tightly, (7) puckering of lips, (8) showing bottom teeth, (9) snarling or wrinkling of the nose, and (10) nasal base view. Table 2 lists the different views in greater detail. Another view that can be considered is having patients puff out their cheeks. This view can help evaluate the severity of perioral incompetence in paralyzed faces and severity and tightness in patients with synkinesis (eFigure 2 in the Supplement). Moreover, because many approaches to reanimate the face include nerve substitutions or transfers (eg, masseteric nerve or hypoglossal nerve), it is imperative for clinicians to assess and document the function of any potential donor nerve on physical examination. The function of these common donors will not be captured with the standardized photographic and videographic views discussed in this study.

While these 10 static views are important, we should not underestimate the power of videography in capturing spontaneity of movement, synkinesis, and speech production. We encourage clinicians to record patients performing the views mentioned previously and to have patients recite simple sentences that require the production of bilabial and plosive sounds to assess speech (Video). We recommend using a sentence from the Goldman-Fristoe Test of Articulation 3 (Pearson Education, Inc), which incorporates most motor movements required for articulate speech production. Incorporating speech assessment may provide important assessments of improvement when comparing preintervention and postintervention function.

Strengths and Limitations

A strength of our study is the inclusion of a cross-sectional survey of SCBS members, an international group of clinicians who specialize in the care of patients with facial palsy. By leveraging the expertise of this group of practitioners, we present a minimum set of photographs and videography that can be eas-

Figure 2. Facial Palsy Static Views



A standardized set of photographs is proposed that should be used in outcomes analysis to improve information exchange and data comparison. This minimum set consists of 10 static views.

ily adopted by others caring for this special patient population. However, there are limitations that remain. Because of the paucity of literature dedicated to photographic standards for patients with facial palsy, we were not able to conduct a meta-analysis or systematic review, which would provide more robust evidence. In addition, because our study was cross-sectional in design, we capture the practice patterns of clinicians at a given snapshot of time, which for us in this study was August and September 2013. Since the surveying of these SCBS members in 2013, practice patterns, specifically the use of medical photography and videography, could have evolved. Moreover, while out of the scope of this study, we acknowledge the need for a standardized approach to incorporate medical photography and videography along with patient-reported outcomes for patients who undergo facial reanimation surgery for facial palsy.

The benefits of standardized medical photography and videography in this patient population are several. First, images and video obtained before and after surgery can demonstrate functional deficits or improvements over time, which can provide invaluable feedback to the surgeon and reassurance to the patient. This feedback to the patient with facial palsy is especially critical because improvements in facial nerve function are often subtle and slow progressing. Standardized photographs and videos in tandem with objective scoring and patient-reported outcome measures provide a comprehensive evaluation of the patient's progression over time. Second, medical photography is a useful teaching tool. High-quality images of our proposed 10 static views can help trainees better understand how different functions are related to the intricate branching patterns and course of the facial nerve, which can sometimes be challenging to comprehend. Third, and most

Table 2. Minimum Standard Photographic Views for Patients With Facial Palsy

View	Facial Nerve Branch Tested	Muscles Activated	Special Notes
At rest or repose	All	Not applicable.	Symmetry at rest is one of the most important views to capture. Specifically, the clinician should evaluate the position of the eyebrows, canthi, and oral commissures from side to side. With regard to the eye in this view, specific attention should be made to the height of palpebral aperture and lower eyelid position. Patients with unilateral facial palsy typically deviate the tip of their nose and upper and lower lips toward the uninjured or unaffected side. This view can also help assess the patient's resting tone.
Small closed-mouth smile	Zygomatic, buccal	Upper lip levators (major is levator labii superioris)	Not applicable.
Large smile showing teeth	Zygomatic, buccal, marginal mandibular	Upper lip levators, levators of the corner of the mouth, depressors of lower lip (innervated by marginal mandibular)	Damage of the marginal mandibular branch in a smile showing no teeth will produce little alteration. However, this view would capture obvious asymmetry of the lower lip depressors.
Elevation of eyebrows	Frontal	Frontalis	Not applicable.
Closure of eyes gently	Frontal	Orbicularis oculi	Eye closure is a complex action. The upper lid is controlled by the following 2 synergistic muscles and nerves: the palpebral portion of the orbicularis oculi (innervated by the frontal branch of the facial nerve) and the levator palpebrae (innervated by the superior ramus of the oculomotor nerve).
Closure of eyes tightly	Frontal	Orbicularis oculi, corrugator supercilii	Not applicable.
Puckering of lips	Buccal	Orbicularis oris, buccinator	Not applicable.
Showing bottom teeth	Marginal mandibular, cervical	Depressors of lower lip (innervated by marginal mandibular), platysma	Not applicable.
Snarling or wrinkling of the nose	Frontal, buccal	Corrugator supercilii, nasalis, depressor septi nasii, levator labii superioris aequae nasii	Not applicable.
Nasal base view	Buccal	Nasalis, depressor septi nasii, levator labii superioris aequae nasii	This view allows for an improved assessment of midline structures and symmetry. In addition, external nasal valve symmetry is best assessed using this view.

important, standardized medical photography and videography are integral to communicating results to other clinicians caring for these patients. Studies involving this patient population are often underpowered and anecdotal because the clinical volume of patients with facial nerve disorders is low. One solution to this problem is to use standardized medical photographs and videos in scientific presentations and publications. It is equally important to adopt standardized videography to monitor the progress of these patients before and after surgery. Because medical photography captures the patient's facial nerve function at a single moment in time, it can occasionally be misleading and should be supported and corroborated by standardized videography.

While grading of these suggested views and movements was out of the scope of the present article, other groups have successfully developed and validated an electronic, clinician-graded facial function scale, referred to as the eFACE,¹⁶ which can be applied to these proposed standards. Furthermore, as a result of the findings of the present study, the SCBS urges practitioners to use these minimum photographic and video-

graphic standards in practice. In addition, we also urge journal editors to adopt these standards for submission of manuscripts related to facial palsy. This requirement would improve exchange of information and may assist with execution of high-quality, multicenter studies needed in this patient population.⁸

Conclusions

With currently available techniques, it is difficult to compare outcomes of patients with facial palsy. To bridge this gap, we propose guidelines for photographic and videographic standards among patients with facial palsy consisting of 10 static views and their respective dynamic functions. Scientific presentations and publications related to facial palsy should fulfill these minimum photographic standards to encourage uniformity in depicting outcomes. Standardized medical photography is integral to allow exchange of information and ultimately to optimize the management of this complex and challenging condition.

ARTICLE INFORMATION

Accepted for Publication: September 30, 2016.

Published Online: January 26, 2017.
doi:10.1001/jamafacial.2016.1883

Author Affiliations: Division of Plastic and Reconstructive Surgery, Department of Surgery, Washington University School of Medicine, St Louis,

Missouri (Santosa); Facial Nerve Programme, Regional Paediatric Burns and Plastic Surgery Service, Alder Hey Children's National Health Service Foundation Trust, Liverpool, England (Fattah); Department of Otorhinolaryngology, La Paz University Hospital, Madrid, Spain (Gavilán); Facial Nerve Center, Division of Facial and Plastic and Reconstructive Surgery, Department of

Otology and Laryngology, Harvard Medical School and Massachusetts Eye and Ear, Boston (Hadlock); Facial Nerve Institute, Division of Plastic and Reconstructive Surgery, Department of Surgery, Washington University School of Medicine, St Louis, Missouri (Snyder-Warwick).

Author Contributions: Drs Fattah and Snyder-Warwick had full access to all the data in the study and takes responsibility for the integrity of the data and the accuracy of the data analysis. *Study concept and design:* Santosa, Fattah, Hadlock, Snyder-Warwick.

Acquisition, analysis, or interpretation of data: All authors.

Drafting of the manuscript: Santosa, Snyder-Warwick.

Critical revision of the manuscript for important intellectual content: Fattah, Gavilán, Hadlock, Snyder-Warwick.

Statistical analysis: Santosa, Snyder-Warwick.

Administrative, technical, or material support: Santosa, Fattah, Hadlock, Snyder-Warwick.

Study supervision: Santosa, Fattah, Snyder-Warwick.

Conflict of Interest Disclosures: None reported.

Funding/Support: Dr Santosa was in part supported by grant F32NS098561 from the National Institute of Neurological Disorders and Stroke, National Institutes of Health.

Role of the Funder/Sponsor: The National Institutes of Health did not have a role in any of the following: design and conduct of the study; collection, management, analysis, or interpretation of the data; preparation, review, or approval of the manuscript; or decision to submit the manuscript for publication.

Disclaimer: The content is solely the responsibility of the authors and does not necessarily represent the official views of the National Institutes of Health.

Additional Contributions: Andrew Yee, BS, provided the photographs and video, and Kim Lipsey, MLS, assisted with the literature search. Both are affiliated with Washington University in

St Louis and received no compensation outside of their usual salary. We thank members of the Sir Charles Bell Society for their participation and input. We thank the patient for granting permission to publish her images.

REFERENCES

- Ekman P. Darwin's contributions to our understanding of emotional expressions. *Philos Trans R Soc Lond B Biol Sci.* 2009;364(1535):3449-3451.
- Walker DT, Hallam MJ, Ni Mhurchadha S, McCabe P, Nduka C. The psychosocial impact of facial palsy: our experience in one hundred and twenty six patients. *Clin Otolaryngol.* 2012;37(6):474-477.
- Dey JK, Ishii M, Boahene KD, Byrne PJ, Ishii LE. Facial reanimation surgery restores affect display. *Otol Neurotol.* 2014;35(1):182-187.
- Wang K, Kowalski EJ, Chung KC. The art and science of photography in hand surgery. *J Hand Surg Am.* 2014;39(3):580-588.
- Wong MS, Vinyard WJ. Photographic standards for the massive weight loss patient. *Ann Plast Surg.* 2014;73(suppl 1):S82-S87.
- Henderson JL, Larrabee WF Jr, Krieger BD. Photographic standards for facial plastic surgery. *Arch Facial Plast Surg.* 2005;7(5):331-333.
- Nizioł R, Henry FP, Leckenby JI, Grobbelaar AO. Is there an ideal outcome scoring system for facial reanimation surgery? a review of current methods and suggestions for future publications. *J Plast Reconstr Aesthet Surg.* 2015;68(4):447-456.
- Bhama P, Gliklich RE, Weinberg JS, Hadlock TA, Lindsay RW. Optimizing total facial nerve patient management for effective clinical outcomes research. *JAMA Facial Plast Surg.* 2014;16(1):9-14.
- el-Naggar M, Rice B, Oswal V. Life-size photograph transparencies: a method for the photographic detection and documentation of recovery from facial paralysis. *J Laryngol Otol.* 1995;109(8):748-750.
- Ellis DA, Gillies TM. Evaluation of the paralyzed face. *J Otolaryngol.* 1979;8(6):473-476.
- Mitchell SA. Preoperative and postoperative photographic standards [letter]. *Arch Otolaryngol.* 1981;107(2):130.
- Barrs DM, Fukushima T, McElveen JT Jr. Digital camera documentation system for facial nerve outcome assessment. *Otol Neurotol.* 2001;22(6):928-930.
- Schaaf H, Streckbein P, Etorre G, Lowry JC, Mommaerts MY, Howaldt HP. Standards for digital photography in craniomaxillo-facial surgery, part II: additional picture sets and avoiding common mistakes [published correction appears in *J Craniomaxillofac Surg.* 2006;34(7):443]. *J Craniomaxillofac Surg.* 2006;34(6):366-377.
- Fattah AY, Gavilan J, Hadlock TA, et al. Survey of methods of facial palsy documentation in use by members of the Sir Charles Bell Society. *Laryngoscope.* 2014;124(10):2247-2251.
- Kayabasoglu G, Nacar A. Secondary improvement in static facial reanimation surgeries: increase of nasal function. *J Craniofac Surg.* 2015;26(4):e335-e337. doi:10.1097/SCS.0000000000001769
- Banks CA, Bhama PK, Park J, Hadlock CR, Hadlock TA. Clinician-graded electronic facial paralysis assessment: the eFACE. *Plast Reconstr Surg.* 2015;136(2):223e-230e. doi:10.1097/PRS.0000000000001447