

ORIGINAL RESEARCH

Novel Treatment of Onychomycosis using Over-the-Counter Mentholated Ointment: A Clinical Case Series

Richard Derby MD, Patrick Rohal MD, Constance Jackson MD, Anthony Beutler MD, and Cara Olsen PhD, MPH

Background: Current medication treatments for onychomycosis have less than full cure-rate efficacy and have the potential for adverse side effects. Vicks VapoRub (The Procter & Gamble Company, Cincinnati, OH) has been advocated in the lay literature as an effective treatment for onychomycosis. This pilot study tested Vicks VapoRub as a safe, cost-effective alternative for treating toenail onychomycosis.

Methods: Eighteen participants were recruited to use Vicks VapoRub as treatment for onychomycosis. Participants were followed at intervals of 4, 8, 12, 24, 36, and 48 weeks; digital photographs were obtained during initial and follow-up visits. Primary outcome measures were mycological cure at 48 weeks and clinical cure through subjective assessment of appearance and quantifiable change in the area of affected nail by digital photography analysis. Patient satisfaction was a secondary outcome, measured using a single-item questionnaire scored by a 5-point Likert scale.

Results: Fifteen of the 18 participants (83%) showed a positive treatment effect; 5 (27.8%) had a mycological and clinical cure at 48 weeks; 10 (55.6%) had partial clearance, and 3 (16.7%) showed no change. All 18 participants rated their satisfaction with the nail appearance at the end of the study as “satisfied” (n = 9) or “very satisfied” (n = 9).

Conclusions: Vicks VapoRub seems to have a positive clinical effect in the treatment onychomycosis. (J Am Board Fam Med 2011;24:69–74.)

Keywords: Mentholated Ointment, Onychomycosis, Treatment

Toenail onychomycosis is a common diagnosis for primary care physicians. The prevalence of onychomycosis in the North American adult population may range from 2% to 18%, with prevalence increasing to 20% and 30% for those older than 60 years and 70 years, respectively.^{1–5} Onychomycosis is commonly associated with tinea pedis. Significant physical and psychological effects, such as pain and negative self-image, may occur in patients with onychomycosis.⁶

Dermatophytes *Trichophyton rubrum* and *Trichophyton mentagrophytes* are the predominant pathogens in onychomycosis; nondermatophytes (usually *Candida*) account for a smaller percentage (10% to 20%) of toenail onychomycosis.^{1,7} Presentation of infection may occur in various patterns: fungal invasion of distal or lateral margins of the nail (distolateral subungual onychomycosis); direct effect from above or on top of the nail with a powdery, white, patchy discoloration (superficial white ony-

This article was externally peer reviewed.

Submitted 26 May 2010; revised 20 August 2010; accepted 30 August 2010.

From the US Air Force 375th Medical Group, Family Medicine Residency Program, Belleville, IL (RD); the US Air Force 779th Medical Group, Department of Family Medicine, Malcolm Grow Medical Center, Joint Base Andrews, MD (PR); the US Air Force 28th Medical Group, Department of Family Medicine, Ellsworth AFB, SD (CJ); and the Departments of Family Medicine (AB) and Preventive Medicine and Biometrics (CO), Uniformed Services University, Bethesda, MD (AB).

Funding: Funding as provided by the TRUE Research Foundation, San Antonio, TX.

Conflict of interest: none declared.

Disclaimer: The opinions and assertions contained herein are the private views of the authors and are not to be construed as official or as reflecting the views of the Uniformed Services University of the Health Sciences, the US Air Force, or the US Department of Defense.

Corresponding author: Lt. Col. Richard Derby, 375th Medical Group, Family Medicine Residency Program, 180 S. Third Street, Suite 400, Belleville, IL 62220 (E-mail: Richard.derby-02@scott.af.mil).

chomycosis); or infection beginning from the proximal location beneath the nail bed (proximal subungual onychomycosis).⁷

Current treatment agents for onychomycosis include both systemic and topical medications. A meta-analysis of systemic therapies showed mycological cure rates of 76% with the use of terbinafine, 63% with the use of itraconazole pulse dosing, 61% with the use of griseofulvin, and 48% with the use of fluconazole.⁸ Downsides to oral therapy include the potential for adverse side effects, most notably hepatotoxicity, and the significant cost of the medication course, which is typically of 3 months' duration. Ciclopirox 8% is a topical lacquer solution that has been approved by the US Food and Drug Administration for treatment of onychomycosis, with reported mycological cure rates of 34% in meta-analysis studies of North America patients.⁹ Cure rates of ciclopirox 8% and other topical therapies that have not been approved by the US Food and Drug Administration (eg, amorolfine 5% and tioconazole 28%) are lower than those observed with systemic treatments, and the course of topical treatments ranges from 6 to 12 months.⁷

Vicks VapoRub (The Proctor & Gamble Company, Cincinnati, OH) has been popularized by lay medical Web sites as a home cure for onychomycosis.¹⁰ No published trials examining the effect of this compound on onychomycosis have been accomplished. However, the active and inactive ingredients in Vicks VapoRub (thymol, menthol, camphor, and oil of Eucalyptus) have shown efficacy against dermatophytes *in vitro*.¹¹⁻¹⁴ The purpose of this pilot study was to test the efficacy of Vicks VapoRub as a safe, cost-effective alternative for treating toenail onychomycosis in an outpatient clinic setting.

Methods

The study protocol was approved by the institutional review board of the Malcolm Grow US Air Force Medical Center. Participants were recruited from an outpatient family medicine clinic that serves both an active duty and civilian (dependent and retiree) populations. Information posters were placed in the clinic lobbies to advertise the study. Patients used contact details on the posters to arrange an appointment with study investigators. During the initial appointment, the study was explained and informed consent for participation was

obtained. Demographic data (age, sex, military status) was obtained along with historic data (duration of dystrophic nail, prior treatment for onychomycosis, chronic medical diseases, medication use, and allergy history).

Inclusion criteria were men and women older than 18 years of age with clinical onychomycosis that was evident on at least one great toenail. Exclusion criteria included any history of allergic sensitivity to Vicks VapoRub or its active ingredients (thymol, camphor, menthol, or oil of Eucalyptus); any use of oral antidermatophyte medication within the last year; any deformity of the affected nail that would preclude sampling for potassium hydroxide (KOH) and culture or prevent adequate photographic assessment of the nail; and a negative culture of fungal infection from the sampling taken during the initial visit.

After consent was obtained, a digital photograph of the affected nail was taken, and then a nail wedge/clipping was collected for KOH microscopy and culture. The participant was then supplied with the study treatment (Vicks VapoRub) and instructed to apply a small amount of Vicks VapoRub with a cotton swab or finger to the affected nail at least once daily. If the culture of the nail sample was negative for fungal infection, volunteers were contacted and removed from the study. Volunteers with positive cultures were contacted for follow-up assessments at 4, 8, 12, 24, 36, and 48 weeks. Repeat digital photographs, assessment for adverse reactions, treatment effect, patterns of VapoRub use, and the patient's perceived tolerability of treatment were performed/assessed during each visit.

The primary outcome measures for the study were mycological cure at 48 weeks, defined as negative KOH and culture of nail sample, and clinical cure (clearance of dystrophic nail). Clearance of dystrophic nail was assessed by gross appearance at the end of the study period as "complete," "partial," or "no change." Clearance was quantified through serial digital photography of the affected nail. Photographic editing software (Photoshop CS3, Adobe Systems, Inc., San Jose, CA) was used to define the nail edges and the borders of the affected nail region so areas (in pixel units) of total nail and affected nail could be calculated. Using these areas, the ratio of affected nail area to total nail area was calculated for each photograph taken during the course of the study. A secondary outcome measured was patient satisfaction with the appearance

of the affected nail at the end of the study period; this was assessed using a single-item questionnaire scored on a 5-point Likert scale (1 = very satisfied, 2 = satisfied, 3 = neither satisfied nor dissatisfied, 4 = dissatisfied, and 5 = very dissatisfied).

Statistics

Descriptive statistics were used to report outcome data. Paired *t* test and Fisher's exact test were used to analyze significance of treatment effect from the initial to 48 week period and between infecting pathogen subtypes.

Results

Forty participants were recruited to the study over 10 months. Of these, 20 were removed because of a negative fungal culture result on the initial nail sampling. Two participants removed themselves from the study (1 at 12 weeks and the other at 24 weeks), citing an unwillingness to continue follow-up examinations/photographs. Thus, 18 of the 20 participants with culture-proven onychomycosis completed the 48-week study period.

Five of the 18 participants who completed the study were seen at every follow-up period and had photographs taken at 4, 8, 12, 24, 36, and 48 weeks. The remaining 13 participants attended the majority of follow-up appointments (average missed appointments = 1.8). Most missed appointments (16 of 23) were in the 4- or 8-week follow-up period; 6 were in the 12-week period; and 1 was in the 36-week period. At each follow-up visit, queries about compliance and use patterns (1–2 times per week, 3–5 times per week, or daily) showed that the majority of participants (15 of 18) reported daily application of the Vicks VapoRub and the remaining participants (3 of 18) reported use 3 to 5 times per week.

The outcome data are presented in Table 1. Overall, 15 of the 18 participants (83%) had a positive response to the Vicks VapoRub treatment for onychomycosis. Five participants (27.8%) had a mycological cure (negative nail culture) at 48 weeks; 4 of these 5 showed complete clinical and mycological cures (22.2%). However, one still had evidence of dystrophic nail. Ten participants (55.6%) showed evidence of partial clinical cure (decreasing area of dystrophic nail); 9 of these had positive nail cultures at 48 weeks and one had a negative nail culture. The remaining 3 participants

(16.7%) showed no significant clinical improvement through 48 weeks and had positive cultures at 48 weeks. Interestingly, all 18 participants rated their satisfaction with the appearance of the affected nail after the study course as either "very satisfied" (*n* = 9) or "satisfied" (*n* = 9). Photographs of the observed changes in the toenails of three participants are presented in Figure 1. The average ratio of affected to total nail area decreased from 63% at initial evaluation to 41% at 48 weeks (*P* < .001; paired *t* test).

Outcomes were better for the 5 participants with positive cultures for either *Candida parapsilosis* or *T. mentagrophytes*. All 5 of these participants showed complete clinical cure compared with none of the 13 participants with other organism growth (*P* < .001; Fisher's exact test). Four of these 5 participants also had negative cultures by the end of the study compared with one of the 13 remaining participants (*P* = .008; Fisher's exact test). All 5 participants with positive cultures for either *C. parapsilosis* or *T. mentagrophytes* were also highly satisfied with treatment compared with only 4 of the 13 remaining participants (*P* = .029; Fisher's exact test). Although these findings indicate a strong association between the organism and the success of treatment, they should be considered preliminary because they do not correspond to any preplanned hypothesis.

Discussion

We demonstrated in this pilot study that Vicks VapoRub provides a positive effect in the treatment of onychomycosis. This is the first clinical study in the literature to describe this finding.

To date, treatment for onychomycosis is accomplished primarily with oral (cure rates, 48% to 76%) and/or topical (34% cure rate with ciclopirox 8%)^{8,9} The cost for a complete course of oral medication treatment for onychomycosis ranges from \$780 to \$900 (not including associated costs for laboratory monitoring); a course of treatment with ciclopirox 8% is approximately \$200.¹⁵ A 1-year course of Vicks VapoRub, by comparison, can be expected to cost approximately \$24 to \$36 (the cost of 2 to 3 6-ounce jars).

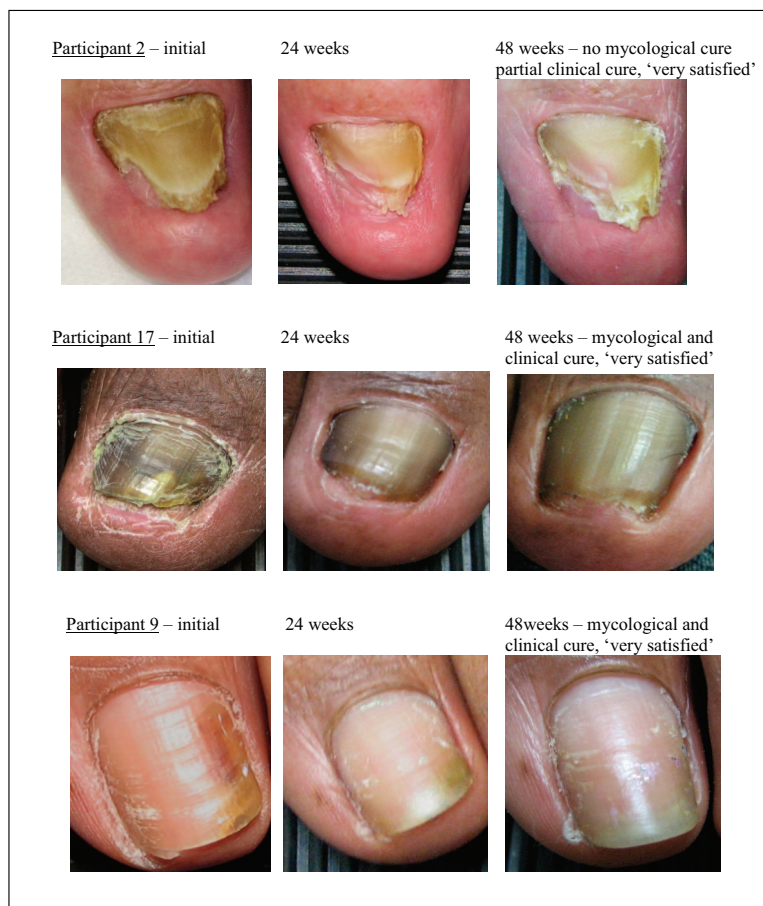
Key weaknesses if this study include the small sample size, the lack of a control group, and variability in the pathogens, as well as the initial degree of nail involvement between participants. These

Table 1. Participant Demographics, Culture Organism, Photographic Assessment of Percentage of Nail Affected Initially and at 12-Week Intervals, Final Clinical and Mycological Cure, and Satisfaction

Participant	Sex	Age (yr)	Organism	Initial Amount Affected (%)	Affected at 12 Weeks (%)	Affected at 24 Weeks (%)	Affected at 36 Weeks (%)	Affected at 48 Weeks (%)	Clinical Cure	Mycological Cure	Satisfaction*
1	Male	68	Fungal elements	61	58	64	—	45	Partial	No	2
2	Male	76	<i>Cryptococcus lomentii</i>	98	82	46	48	54	Partial	No	1
3	Male	30	<i>Trichophyton rubrum</i>	72	57	92	47	51	Partial	No	2
4	Male	37	<i>T. rubrum</i>	35	—	24	18	12	Partial	Yes	2
5	Female	52	<i>Candida parapsilosis</i>	44	22	22	25	27	Partial	No	1
6	Male	49	<i>T. rubrum</i>	70	50	60	44	47	Partial	No	2
7	Male	47	Fungal elements	59	—	45	64	47	Partial	No	2
8	Female	31	<i>T. rubrum</i>	39	—	37	49	48	No change	No	2
9	Female	37	<i>C. parapsilosis</i>	37	—	17	11	4	Complete	Yes	1
10	Female	52	<i>C. parapsilosis</i>	54	50	37	14	11	Complete	Yes	1
11	Female	85	Penicillium sp.	100	—	91	93	95	No change	No	2
12	Female	45	<i>Trichophyton mentagrophytes</i>	20	—	15	9	5	Complete	No	1
13	Female	69	Fusarium sp.	100	87	92	91	80	Partial	No	2
14	Male	54	<i>T. rubrum</i>	89	90	72	79	70	Partial	No	1
15	Male	40	<i>T. rubrum</i>	89	84	93	83	79	Partial	No	1
16	Male	57	<i>Candida albicans</i>	63	58	53	51	58	No change	No	2
17	Male	65	<i>T. mentagrophytes</i>	84	71	41	20	7	Complete	Yes	1
18	Female	32	<i>T. mentagrophytes</i>	16	11	7	5	5	Complete	Yes	1

*1 = very satisfied; 2 = satisfied.

Figure 1. Serial photographic assessment of clinical onychomycosis in selected participants.



weaknesses underscore the fact that this study does not prove or disprove the clinical utility of this unorthodox treatment of onychomycosis.

Nevertheless, the strength of this study is found in the simplicity of its design; we provided a relatively inexpensive and innocuous therapy with straightforward instructions for use and then measured for effect through objective culture and clinical appearance. Although inherently subjective, we believe the assessment of clinical appearance to be an important outcome measure. Nail fungal culture has good specificity and positive predictive value (>94%), but the sensitivity is poor (30% to 50%).⁷ Photoshop CS3 software allowed for measurement of the area ratio of clinically affected (dystrophic) nail to the total nail. Although an unvalidated method of measuring the degree of infection in the nail, it was useful in providing a more objective means of estimating effect and change in clinical appearance. The participants' positive satisfaction rat-

ings with the treatment irrespective of the final clinical outcome shows that there is potential benefit in providing this simple, innocuous treatment even with unproven or partial efficacy.

Future studies may benefit from grouping by the pathogens isolated. In the current study we enrolled 3 participants with cultures positive for *C. parapsilosis* and 3 with cultures positive for *T. mentagrophytes*. These 6 participants accounted for all 5 of the complete clinical cures (one participant with the *C. parapsilosis* organism had a partial cure). In contrast, of the 6 participants with cultures positive for *T. rubrum*, 5 had a partial cure and 1 had no change. Focusing future treatment studies on specific organisms may provide more details about treatment efficacy. Additional areas for future studies may include combining Vicks VapoRub with other medical and physical modalities (filing/clipping) or comparing efficacy based on the degree of nail involvement (mild vs severe).

Conclusion

In this pilot study, Vicks VapoRub seemed to have some clinical effect in treating onychomycosis, particularly when *C. parapsilosis* and *T. mentagrophytes* were the infecting organisms. Regardless of clinical effect, participants were highly satisfied with the simple, innocuous treatment strategy of once-daily application of Vicks VapoRub to the affected nail. Vicks VapoRub may represent a significant addition to the clinical options for treating onychomycosis, not only because of its clinical effect but also because of the minimization of side effects and its lower cost compared with established therapies. Such a treatment might be a viable first-line option for a condition with limited morbidity apart from cosmetic effect. Future studies are required for proof of efficacy and better delineation of treatment effects.

References

1. Gupta AK, Jain HC, Lynde CW, et al. Prevalence and epidemiology of onychomycosis in patients visiting physicians' offices: a multicenter Canadian survey of 15,000 patients. *J Am Acad Dermatol* 2000;43:244–8.
2. Erbagci Z, Tuncel A, Zer Y, Balci I. A prospective epidemiologic survey on the prevalence of onychomycosis and dermatophytosis in male boarding school residents. *Mycopathologia* 2005;159:347.
3. Ghannoum MA, Hajjeh RA, Scher R, et al. A large-scale North American study of fungal isolates from nails: the frequency of onychomycosis, fungal distribution, and antifungal susceptibility patterns. *J Am Acad Dermatol* 2000;43:641–8.
4. Gupta AK, Jain HC, Lynde CW, Summerbell RC. Prevalence of unsuspected onychomycosis in patients visiting dermatologists' offices in Ontario, Canada: a multicenter survey of 2001 patients. *Int J Dermatol* 1997;36:783–7.
5. Elewski BE, Charif MA. Prevalence of onychomycosis in patients attending a dermatology clinic in northeastern Ohio for other conditions. *Arch Dermatol* 1997;133:1172–3.
6. Drake LA, Patrick DL, Fleckman P, et al. The impact of onychomycosis on quality of life: development of an international onychomycosis questionnaire to measure patient quality of life. *J Am Acad Dermatol* 1999;41:189–96.
7. de Berker D. Fungal nail disease. *N Engl J Med* 2009;360:2108–16.
8. Gupta AK, Ryder JE, Johnson AM. Cumulative meta-analysis of systemic antifungal agents for the treatment of onychomycosis. *Br J Dermatol* 2004;150:537–44.
9. Gupta AK, Joseph WS. Ciclopirox 8% nail lacquer in the treatment of onychomycosis of the toenails in the United States. *J Am Podiatr Med Assoc* 2000;90:495–501.
10. Vicks VapoRub might help fight toenail fungus. *Consum Rep* 2006;71:49.
11. Pinto E, Pina-Vaz C, Salgueiro L, et al. Antifungal activity of the essential oil of *Thymus pulegioides* on *Candida*, *Aspergillus* and dermatophyte species. *J Med Microbiol* 2006;55(Pt 10):1367–73.
12. Salgueiro LR, Pinto E, Goncalves MG, et al. Chemical composition and antifungal activity of the essential oil of *Thymbra capitata*. *Planta Med* 2004;70:572–5.
13. Pina-Vaz C, Goncalves Rodrigues A, Pinto E, et al. Antifungal activity of *Thymus* oils, and their essential compounds. *J Eur Aca Dermatol Venerol* 2004;18:73–8.
14. Ramsewak RS, Nair MG, Stommel M, Selanders L. In vitro antagonistic activity of monoterpenes and their mixtures against "toe nail fungus" pathogens. *Phytother Res* 2003;17:376–9.
15. Lexi-Comp Reader version 2.4060407. Drug pricing information. Hudson, OH: Lexi-Comp, Inc.; 2006.