

## RESEARCH LETTERS

### The Fascial Plication Suture: An Adjunct to Layered Wound Closure

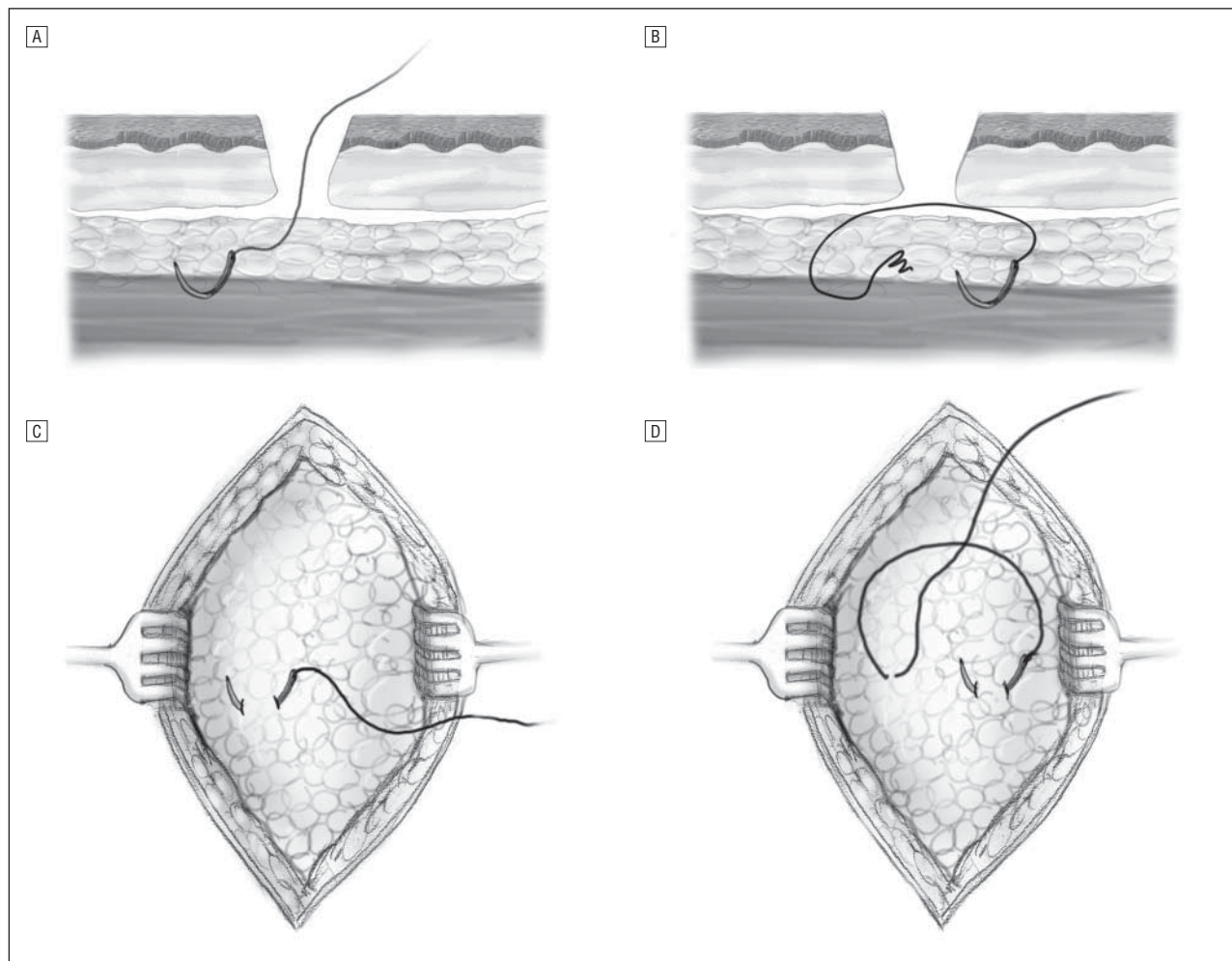
**M**inimizing surgical wound tension is generally accomplished by combining buried dermal sutures with an epidermal closure of choice. Several improvements on the buried dermal suture have been proposed over the years, from the buried vertical mattress technique<sup>1</sup> and its many variants<sup>2</sup> to the setback dermal suture.<sup>3</sup>

Despite the unique nature of wound closure from excisional surgery, most surgeons approach these closures as repairs of simple incisions. The added wound tension resulting from the extirpation of the excised tissue, over and above the tension across the surface of the wound that would be expected even from incisional sur-

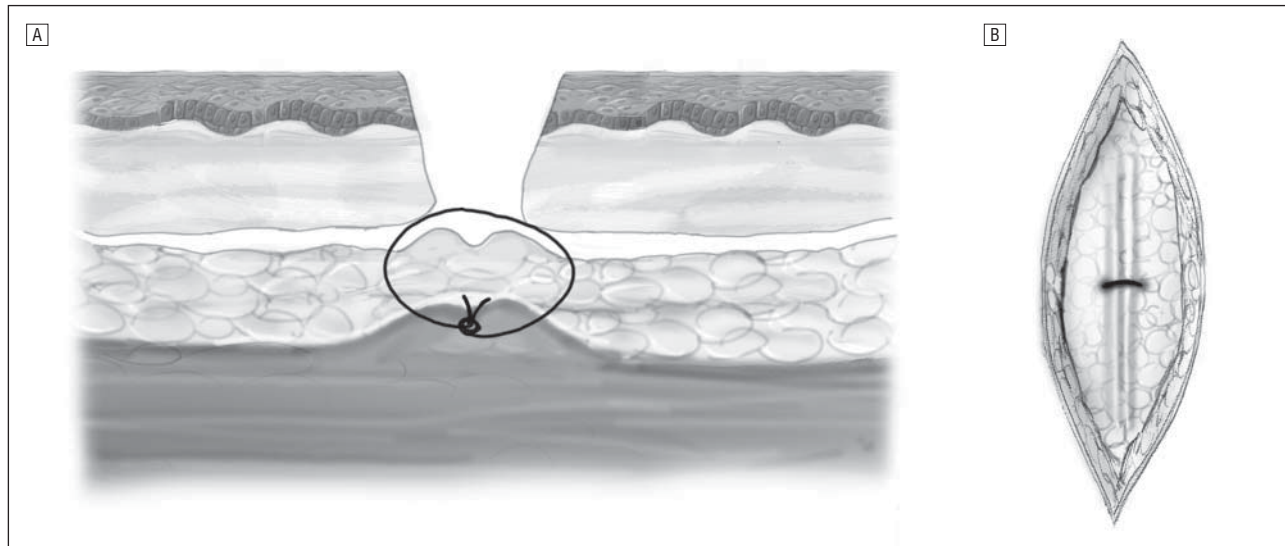
gery, may not be fully alleviated with standard layered-closure techniques. In excisions of large cysts or tumors, significant dead space may remain even with wounds closed using dermal sutures, potentially increasing the risk of hematoma formation or wound infection.

The plication of superficial muscle fascia has been used as a technique of choice in rhytidectomy surgery for decades. The popularity of this technique stems from the ability to effect long-lasting tissue drag. Extending the application of this technique to reconstructive procedures, Dzubow<sup>4</sup> described the use of multiple fascial plication sutures using nonabsorbable sutures in lieu of dermal sutures for select Mohs defects on the head and neck. Other authors have suggested fascial imbrication for select scalp and forehead defects.<sup>5</sup>

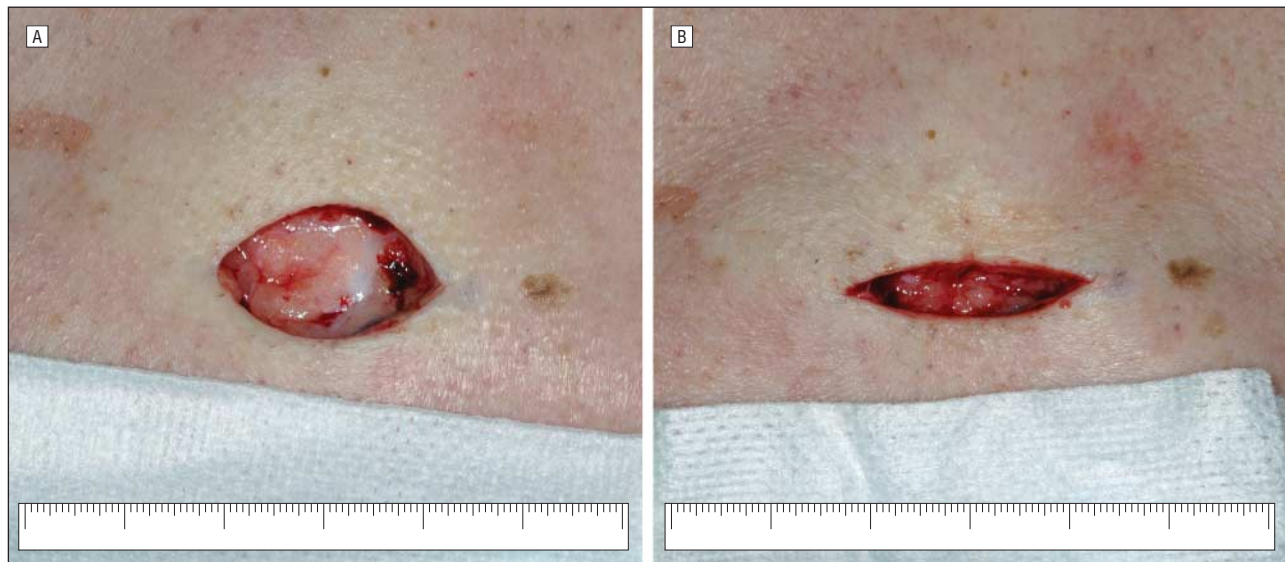
The fascial plication technique described herein is best suited to high-tension repairs on the trunk, neck, and shoulders—areas where general dermatologists perform the bulk of their procedures. Further study is needed to assess whether this technique confers a significant benefit over standard layered closure techniques.



**Figure 1.** A, First throw, cross-sectional view; B, second throw, cross-sectional view; C, first throw, surgeon's-eye view; D, second throw, surgeon's-eye view.



**Figure 2.** A, Final wound appearance, cross-sectional view; B, final wound appearance, surgeon's-eye view.



**Figure 3.** Defect before (A) and after (B) placement of single fascial plication suture; note enhanced fusiform appearance of the wound. Scale bar measures 6 cm in both panels.

**Methods.** After the excision is accomplished, the wound is widely undermined in the level of the superficial fat, and adequate hemostasis is obtained. For all but the deepest excisions, the muscle fascia will not be visible at this point. With absorbable suture (I favor 2-0 Vicryl; Ethicon Inc, Somerville, New Jersey), the first throw is accomplished by inserting the cutting or reverse-cutting needle gently into the fat and through the superficial fascia approximately 2 to 5 mm from the undermined edge of the wound (**Figure 1** A and B). A successful bite of the fascia may be tested by gently pulling on the suture and watching for characteristic uplifting of the area. The second throw is then performed by repeating the procedure on the opposite edge and at the same depth (Figure 1C and D). The knot is then tied, which results in a visible pleat and leads to a more fusiform appearance of the wound (**Figure 2** and **Figure 3**). Placing the sutures at the far lateral undermined edges should be avoided owing to a tendency for dimpling of the overlying skin. If 1 fascial plication suture

is used, this may be placed in the vertical midline of the wound; otherwise, a series of multiple evenly spaced plication sutures may be placed.

**Comment.** While this technique might theoretically increase risk of postoperative pain from deep tissue trauma or infection through the breach in the superficial muscle fascia, these issues have not been a problem in my experience. In hundreds of wound closures using this technique on the shoulders and trunk, I have found improved outcomes with less spread-scar formation, less dehiscence, and less tendency toward hematoma formation, especially on large defects. A randomized controlled trial is needed to determine whether this technique truly offers a clinically and statistically significant benefit over standard layered wound closure techniques. This technique shifts the burden of tension from the dermis to the fascia, theoretically resulting in a lower-tension closure, dramatically improved dead-space mini-

mization, and, hopefully, a cosmetically and functionally improved reconstruction.

Jonathan Kantor, MD, MSCE

Accepted for Publication: July 14, 2009.

Author Affiliation: North Florida Dermatology Associates, Jacksonville, Florida.

Correspondence: Dr Kantor, North Florida Dermatology Associates, 1551 Riverside Ave, Jacksonville, FL 32082 (jonkantor@gmail.com).

Financial Disclosure: None reported.

1. Zitelli JA, Moy RL. Buried vertical mattress suture. *J Dermatol Surg Oncol*. 1989;15(1):17-19.
2. Alam M, Goldberg LH. Utility of fully buried horizontal mattress sutures. *J Am Acad Dermatol*. 2004;50(1):73-76.
3. Kantor J. The set-back buried dermal suture: an alternative to the buried vertical mattress for layered wound closure. *J Am Acad Dermatol*. In press.
4. Dzubow LM. The use of fascial plication to facilitate wound closure following microscopically controlled surgery. *J Dermatol Surg Oncol*. 1989;15(10):1063-1066.
5. Radonich MA, Bisaccia E, Scarborough D. Management of large surgical defects of the forehead and scalp by imbrication of deep tissues. *Dermatol Surg*. 2002;28(6):524-526.

### Lack of Lower Extremity Hair Not a Predictor for Peripheral Arterial Disease

Peripheral arterial disease (PAD) afflicts 8 to 12 million Americans, but nearly 75% of them are asymptomatic.<sup>1</sup> Physicians rely on history and physical examination to determine which patients require further evaluation. Physical findings that have been associated with arterial disease include a unilaterally cool extremity, skin atrophy and lack of hair, and abnormal pedal pulses, among others.<sup>2</sup> The disease spectrum ranges from exertional calf pain to chronic limb ischemia necessitating amputation. The suspicion of arterial disease often leads to further examination of the lower extremity vascular supply. Measurement of the ankle-brachial index (ABI) is a noninvasive method for detecting PAD and is about 95% sensitive and specific when the diagnostic cutoff is 0.9.<sup>3</sup> In general, the accepted ABI for the presence of PAD is lower than 0.9, and that for severe disease is lower than 0.7.

The present observational case-control study was undertaken based on the clinical observation that many men seem to have hairless lower extremities. Our goal was to determine whether this physical sign is a predictor of PAD.

**Methods.** After obtaining institutional review board approval, we enrolled 50 subjects from Hershey Medical Center in the study. Twenty-five control subjects were recruited from various outpatient clinics and had documented normal ABI measurements (>0.9). Twenty-five subjects with PAD were recruited from the vascular clinic and had either an ABI lower than 0.9 or abnormal lower extremity arterial duplex findings. Subjects with ABIs lower than 0.9 due to disease other than PAD were excluded.

Subjects with diabetes who had abnormal ABIs were included in the disease group. Due to arterial calcification, the vessels in subjects with diabetes may be less compressible and so might generate falsely elevated indices.

Thus, the vascular disease of patients with diabetes is likely worse than the measured value.

Lower extremity hairs were counted on all subjects. First, a measurement was taken from the anterior tibial tuberosity to the proximal portion of the lateral malleolus. The distance was divided by 3, and hairs were counted at a location one-third of the distance proximal to the lateral malleolus. Scissors were used to trim hairs at this location to several millimeters in length. Temporary black hair dye was then applied to the area for approximately 1 minute. Excess dye was removed, and we took 2 pictures of the area using a magnified digital photography technique, which involved pressing the camera lens against the skin to make full contact while the photograph was taken. All photographs were taken with a Nikon D80 camera (Nikon USA Inc, Melville, New York), stored on a memory card, and uploaded to a computer where Photoshop (Adobe Systems Inc, San Jose, California) was used to crop them to standard dimensions of 2572 × 1564 pixels.

Hair count analyses were performed, and data were categorized as either leg hair present (1 or more hairs present in the examined field) or leg hair absent (no hairs present in the examined field). This assessment was performed on data from each of the 50 subjects. Statistical analysis was then completed using a  $\chi^2$  analysis.

**Results.** Of the 50 patients recruited for this study, 25 had existing PAD, and 25 were healthy controls (**Table**). Subjects in the control group had a mean age of 65 years (age range, 50-80 years). Those in the PAD group had a mean age of 75 years (age range, 55-88 years). Sixty-four percent of patients with PAD had absent leg hair, and 40% of patients without PAD had absent leg hair (Table). Using  $\chi^2$  analysis, we found no statistically significant relationship between disease presence and absence of lower extremity hair ( $P = .09$ ).

**Comment.** Peripheral arterial disease involves atherosclerotic occlusions in the arterial system distal to the aortic bifurcation.<sup>4</sup> It is mainly a disorder of advancing age, and one's risk of PAD is increased by cigarette smoking, diabetes, hypercholesterolemia, and hypertension.<sup>4</sup> Because many patients are asymptomatic, physicians must recognize the early signs and take appropriate action. The goal of the present study was to determine whether the absence of lower extremity hair is a useful predictor of PAD. No statistically significant difference was found between the numbers of diseased patients without leg hair ( $n = 16$ ) and control patients without leg hair ( $n = 10$ ) ( $P = .09$ ), sug-

**Table. Presence of Lower Extremity Hair in Patients With and Without PAD**

Lower Extremity Hair	Patients, No. (%)	
	With PAD <sup>a</sup> (n=25)	Without PAD (n=25)
Present	9 (36)	15 (60)
Absent	16 (64)	10 (40)

Abbreviation: PAD, peripheral arterial disease.

<sup>a</sup>By  $\chi^2$  analysis, no statistically significant relationship was found between disease presence and absence of lower extremity hair ( $P = .09$ ).