

being used. Monitoring of the antegrade selective perfusion pressure, which we believe to be a critical component of assessment of the cerebral perfusion, might be easier with axillary cannulation with an arterial pressure line placed in the right radial artery. Also, axillary artery cannulation itself is not very complicated and is usually done within 30 minutes. Therefore, we still prefer using the axillary artery as a cannulation site.

Dr Küçükler and his colleagues have suggested an excellent and very important point: that surgeons should be aware of those patients whose aortic dissection extends into those arteries or whose right axillary artery takes off aberrantly from the descending aorta. Careful review of preoperative imaging will reliably identify an aberrant artery and extension of dissection into the innominate artery. A dissected axillary artery should be apparent at the time of direct examination. If the artery is dissected, we agree that alternative cannulation is required. A well performed side graft anastomosis should not lead to a pressurized false lumen, even if the arch is dissected. Careful clamping of the innominate artery, after examination of the vessel, will prevent clamping off of the true lumen.

Since the publication of the article, our aortic surgery practice has continued to expand. The axillary artery cannulation technique remains a reproducible and reliable method of arterial outflow in our hands as well as others<sup>2-4</sup> and will continue to be our choice. However, it is crucially important to be aware of the pitfalls suggested by Dr. Küçükler and others and to use judicious clinical judgment for each case for its safe and successful use.<sup>1,5</sup>

Hiroo Takayama, MD

Craig R. Smith, MD

Michael E. Bowdish, MD

Allan S. Stewart, MD

Division of Cardiothoracic Surgery  
Columbia University  
New York, NY

## References

1. Taşdemir O, Sarıtaş A, Küçükler S, Ozatik MA, Sener E. Aortic arch repair with right brachial artery perfusion. *Ann Thorac Surg.* 2002;73:1837-42.
2. Halkos ME, Kerendi F, Myung R, Kilgo P, Puskas JD, Chen EP. Selective antegrade cerebral perfusion via right axillary artery cannulation reduces morbidity and mortality after proximal aortic surgery. *J Thorac Cardiovasc Surg.* 2009;138:1081-9.
3. Etz CD, Plestis KA, Kari FA, Silovitz D, Bodian CA, Spielvogel D, et al. Axillary cannulation significantly improves survival and neurologic outcome after atherosclerotic aneurysm repair of the aortic root and ascending aorta. *Ann Thorac Surg.* 2008;86:441-6.
4. Svensson LG, Blackstone EH, Rajeswaran J, Sabik JF 3rd, Lytle BW, Gonzalez-Stawinski G, et al. Does the arterial cannulation site for circulatory arrest influence stroke risk? *Ann Thorac Surg.* 2004;78:1274-84.
5. Orihashi K, Sueda T, Okada K, Takahashi S. Compressed true lumen in the innominate artery: a pitfall of right axillary arterial perfusion in acute aortic dissection. *J Thorac Cardiovasc Surg.* 2009;137:242-3.

doi:10.1016/j.jtcvs.2009.10.026

## THEY ALSO SERVE WHO ONLY STAND AND WAIT

### To the Editor:

I read with great interest, and a degree of nostalgia, Dr Kumar's editorial<sup>1</sup> on the second assistant.

It brought back memories of a time long ago, when I was young and thirsty for learning. I spent 18 months as a Senior House Officer (the most junior member of the surgical team) in Southampton, UK, where my only role in theaters was to harvest a length of vein and then stand next to the surgeon as a second assistant.

Dr Kumar offers great advice on how to make the most of this time.

As he suggests, I developed my habit of making notes with illustrations during that time. I still have that habit and have a large collection of these handwritten notes and drawings, to which I refer at times even now.

I would often get bored with the repetitive nature of my job of harvesting vein and closing the leg. During one such period of boredom, I started using my left hand (I am right-handed) to do parts of the procedure. I soon became adept at using my left hand as well, a skill that I use on many occasions now with great advantage.

Being a second assistant for a long time can, however, be a source of despair, especially if the opportunities to open or close the chest or do a top-end anastomosis do not materialize. "They also serve who only stand and waite."<sup>2</sup> I would think of Milton.

Being a second assistant also allows the mind to drift without anybody noticing (at times). Daydreaming can be a wonderful experience (at times). I had chosen cardiac surgery to be a top-notch cardiac surgeon, nothing less. When I was 20-something, just holding the retractor as a second assistant did not make the goal seem nearer. Was it possible that the dream could go sour?

I had the opportunity to work as a second assistant with some great surgeons, and some not so fantastic. As Dr Kumar says, it is a very impressionable part of one's life and can have a profound bearing on one's later career.

But alas, the days of the second assistant are numbered. The European Union's working time directive<sup>3</sup> has cursed the current and future generations of trainees with only 48 hours of work per week. This has resulted in severe manpower shortages in hospitals across the United Kingdom, and almost all our surgical procedures are now done with a single assistant. We have learned to adapt to this and now do not find the need for second assistants except for the most complex cases. The loss, however, will be that of the trainees who will miss out on such a wonderful training opportunity.

And for those lucky enough to have this chance, make the most of it. Look at it as an opportunity that has knocked on your door...and if you don't answer soon, it will go away forever.

Vipin Zamvar, MS

Royal Infirmary of Edinburgh  
Edinburgh, UK

## References

1. Kumar TK. The second assistant in cardiac surgery: the challenges and answers. *J Thorac Cardiovasc Surg.* 2009;137:1311-4.
2. Milton J. When I consider how my light is spent. In: Ricks C, ed. *The Oxford book of English verse.* New York: Oxford University Press USA; 1999. p.168.

3. EUR-Lex [Internet]. Luxembourg: Publications Office of the European Union; c2009 [updated 2009 Nov 12; cited 2009 Oct 10]. Council Directive 93/104/EC of 23 November 1993 concerning certain aspects of the organization of working time; [about 1 screen]. Available from: <http://eur-lex.europa.eu/LexUriServ/LexUriServ.do?uri=CELEX:31993L0104:EN:HTML>

doi:10.1016/j.jtcvs.2009.09.060

### INTRA-ATRIAL REROUTING BY THE POSTERIOR LEFT ATRIAL WALL FLAP FOR TOTAL ANOMALOUS PULMONARY VENOUS RETURN DRAINAGE INTO THE CORONARY SINUS IN NEONATES

#### To the Editor:

We read with great interest the new procedure for total anomalous pulmonary venous return (TAPVR) drainage into the coronary sinus (CS), which Yamagishi and colleagues<sup>1</sup> successfully performed for an infant weighing 5.5 kg. Briefly, the roof of the CS was incised toward the left atrium (LA) to create a flap from the posterior wall of the LA (= the anterior wall of the common chamber and the CS). The flap thus created was then moved anteriorly to cover the entire atrial communication and the CS orifice. However, we were unable to find any follow-up

reports on this procedure. We recently successfully performed this procedure for 2 neonatal cases and recognized several important features associated with this surgery.

#### CASE 1

A baby girl with a birth weight of 2.7 kg underwent this new procedure for TAPVR drainage into the CS at 8 days of age. She was discharged on postoperative day 22 without any complications. Postoperative echocardiogram demonstrated a large communication between the LA and the common chamber (Figure 1, A). An abnormal continuous flow was detected at the superior wall of the CS. This flow was directed toward the common chamber and appeared to be a small coronary arterial flow (Figure 1, B). This abnormal flow disappeared 2 months after the operation. One year after the operation, the patient was doing well with no evidence of arrhythmia.

#### CASE 2

The new procedure was also performed on a 20-day-old baby girl (birth weight, 3.0 kg) who had

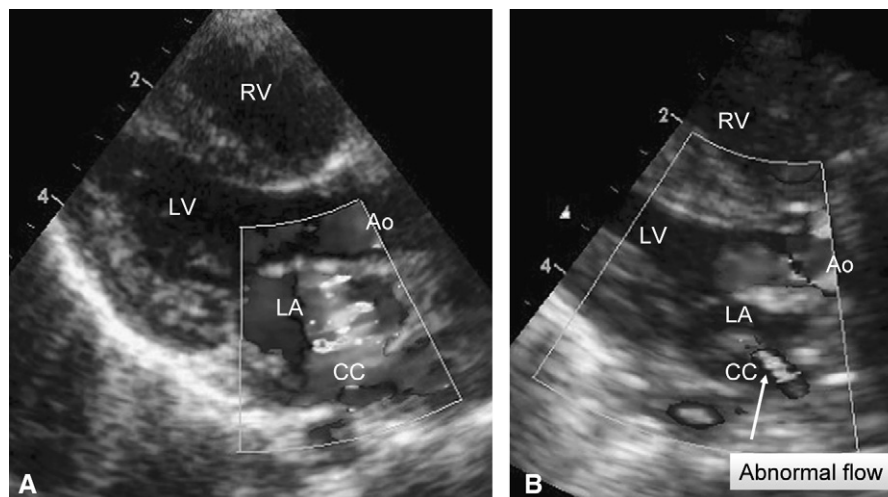
TAPVR drainage into the CS. Because the posterior wall flap of the LA was not sufficiently large to cover the entire atrial septal defect and CS orifice, a fresh autologous pericardial patch was applied to close the rest of the atrial communication. At 1 year and 7 months after the operation, she is in good clinical status with no arrhythmia.

The usual surgical treatment for TAPVC to the CS is either the CS cut-back procedure or the Van Praagh technique.<sup>2</sup> The advantages of this new procedure compared with these previously performed procedures are as follows:

1. Sufficiently wide communication between the LA and the common chamber can be obtained.
2. Neither prosthetic materials nor autologous pericardium is required for closing the atrial communication and the CS orifice.

However, the following cautionary points should be noted:

1. During making the CS anterior wall flap, the incision line may enter into the pulmonary venous orifices.
2. Anastomosing the flap to the anterior edge of the CS orifice may damage the atrioventricular node.



**FIGURE 1.** A, Echocardiogram after surgery. Parasternal long-axis view during the diastolic phase showing a large communication between the LA and the common chamber. B, Another parasternal long-axis view showing an abnormal continuous flow from the posterior wall of the new LA toward the common chamber. RV, Right ventricle; LV, left ventricle; Ao, aorta; LA, left atrium; CC, common chamber.