



The Babinski sign in Renaissance paintings—a reappraisal of the toe phenomenon in representations of the Christ Child: observational analysis

François Sellal,^{1,2} Laurent Tatu³

¹Neurology Department, Hôpitaux Civils de Colmar, Colmar, France

²INSERM U-1118, University of Strasbourg, Strasbourg, France

³Department of Anatomy and Department of Neuromuscular Diseases, CHRU Besançon, University of Franche-Comté, Besançon, France

Correspondence to: F Sellal francois.sellal@ch-colmar.fr (ORCID 0000-0002-8581-7372)

Additional material is published online only. To view please visit the journal online.

Cite this as: *BMJ* 2020;371:m4556 <http://dx.doi.org/10.1136/bmj.m4556>

Accepted: 16 November 2020

ABSTRACT

OBJECTIVE

To investigate systematically the presence of the Babinski sign in paintings of the Christ Child by the greatest painters of the Renaissance.

DESIGN

Observational analysis.

SETTING

Large collection of paintings depicting the Christ Child from Flemish, Rhenish, and Italian schools between 1400 and 1550 CE, searched using published catalogues and Google.

STUDY SAMPLE

302 Renaissance paintings (by 19 painters) depicting the Christ Child.

MAIN OUTCOME MEASURE

Babinski sign, defined as a hallux extension with an amplitude greater than 30°. The presence of foot sole stimulation was also noted.

RESULTS

An unquestionable upgoing toe was apparent in 90 (30%) of the 302 paintings. The Babinski sign was present in more than 60% of Christ Child paintings by Rogier van der Weyden, Hans Memling, Martin Schongauer, and Matthias Grünewald. A bilateral Babinski sign was observed in three paintings. Stimulation of the sole was noted in 48/90 (53%) paintings and was always present in paintings by Andrea del Verrocchio, Leonardo da Vinci, and Giorgione. No association existed between the presence of the Babinski sign and the period during which the painter was active.

CONCLUSIONS

Four main factors were noted in relation to the representation of the Babinski sign in paintings of the Christ Child: the physiological toe phenomenon in infants, the representation of the nudity of the Christ by painters during the 15th century to demonstrate

the incarnation, Renaissance painters' need for precise observation of anatomy, and the desire of some Rhenish and Flemish painters to depict very realistic details. Italian Renaissance painters, whether Mannerist or not, tended to idealise the beauty of human body, and they often did not reproduce the Babinski sign.

Introduction

Since Babinski's seminal description before the Biological Society of Paris on 22 February 1896, the *phénomène des orteils* (toe phenomenon) has been considered a strong sign of pyramidal tract dysfunction.¹ The phenomenon consists of hallux extension during stimulation of the lateral plantar region of the foot. Less than a decade after its description, some neurologists noticed that eminent Renaissance painters had depicted this neurological phenomenon in representations of the Christ Child.²⁻³ A revolution in painting during the 15th century allowed this kind of representation, as artists demonstrated the incarnation of the Christ by presenting the nudity of the Christ Child, who now appeared in a very realistic form.

The presence of the Babinski sign in paintings of the Christ Child raises the question of the physiological plantar reflex in newborns and children. Because the pyramidal tract is not fully developed at birth, dorsiflexion of the big toe can be observed in neonates either spontaneously or on stimulation of the sole of the foot.^{3,4} This question, particularly the nature of the plantar reflex in children and the related terminology, was a matter of debate for decades and is still discussed.^{5,6}

Previous attempts to assess the Babinski sign in paintings of the Christ Child were made before the internet era.^{2,7,8} At that time, access to the *catalogue raisonné* of each painter was limited and references were strongly dependent on the author's personal knowledge.

Our aim in this study was to use a strict and specific method to systematically investigate the presence of the Babinski sign in paintings of the Christ Child by the greatest painters who were active during the Renaissance, which we define here as between 1400 CE and 1550 CE. We hypothesised that the representation of a Babinski sign could be linked to the painter's Mannerist tendency, to a copying effect, or to a greater knowledge of anatomy and physiology during the Renaissance, as the relations between art and medicine were very strong during this period.

WHAT IS ALREADY KNOWN ON THIS TOPIC

Previous investigations of the depiction of the Babinski sign in paintings of the Christ Child in the Renaissance were conducted before the Internet era and were therefore incomplete

WHAT THIS STUDY ADDS

The main factors in the representation of the sign in this period are the physiological toe phenomenon, a trend towards representing the nudity of the Christ Child, and a desire to represent anatomy precisely
Rhenish and Flemish painters tended to depict realistic details, whereas Italian painters tended to idealise their subjects

Methods

We did an extensive search to investigate the presence of the Babinski sign in paintings of the Christ Child from the greatest artists of the period 1400-1550 CE. In addition to using the published catalogues, we did Google searches for the term “Christ Child paintings” in conjunction with each of the following terms: “Jesus Christ birth”, “Nativity”, “Presentation of Jesus in the Temple”, “Adoration of the Magi”, and “Madonna and Child”, to browse the larger collection of paintings depicting Jesus as a newborn.

We limited our analysis to the most famous painters from the Flemish, Rhenish, and Italian schools: Jan van Eyck, Rogier van der Weyden, Fra Angelico, Masaccio, Hans Memling, Andrea del Verrocchio, Sandro Botticelli, Fra Filippo Lippi, Domenico Ghirlandaio, Martin Schongauer, Gérard David, Leonardo da Vinci, Albrecht Dürer, Lucas Cranach the Elder, Matthias Grünewald, Michelangelo, Giorgione, Raphael, Hans Baldung-Grien, Tiziano, Paolo Caliari Veronese, and Il Tintoretto.

We considered that a hallux extension was indisputable, and represented a Babinski sign, when its amplitude was greater than 30° from the sole of the child's foot. In each case, we also checked for the presence of stimulation of the infant's foot sole by another person's body part, contact of the foot with clothes, or self-stimulation by the child.

Patient and public involvement

We did not involve patients and the public in this research.

Results

We omitted three painters from the analysis: Il Tintoretto (c1518-94) and Michelangelo (1475-1594), who painted the Christ Child either not at all or very rarely, and Hans Baldung-Grien (c1484-1545), in whose paintings Christ's feet were systematically not visible (either wrapped in swaddling clothes or hidden).

For the 19 remaining painters, we found 302 paintings depicting a Christ Child whose feet were sufficiently visible to allow us to look for the Babinski sign. We found an unquestionable upgoing toe in 90 (30%) paintings. The Babinski sign was present in more than 60% of paintings of the Christ Child by Rogier van der Weyden, Hans Memling, Martin Schongauer, and Mathias Grünewald. Conversely, Fra Angelico, Masaccio, Tiziano, and Jan van Eyck did not depict the Christ Child with an upgoing toe at all (table 1). No simple relation existed between the presence of a Babinski sign and the period during which the painter was active (fig 1). In the 90 paintings, the earliest depictions of the Babinski sign were present in paintings by Rogier van der Weyden (*Saint Luke Drawing the Virgin*, c 1435-40, Museum of Fine Arts, Boston (fig 2, A); *Duran Virgin*, c1430-35, Museo del Prado, Madrid).

We observed stimulation of the sole of Christ's foot in 48/90 (53%) of the paintings in which the Babinski

sign was present. No paintings by Matthias Grünewald or Veronese depicted stimulation of the foot, but it was always present in paintings by Verrocchio, Leonardo da Vinci, and Giorgione. Stimulation was variably observed in other paintings (table 1). No association was apparent between the presence of the Babinski sign and the type of painting (Nativity, Presentation of Jesus in the Temple, Adoration of the Magi, or Madonna and Child).

We observed a bilateral Babinski sign in three paintings, one of which was *The Virgin and Child with Two Angels* by Andrea del Verrocchio (National Gallery, London) (fig 2, D), painted in around 1470 with his assistant Lorenzo di Credi (c1459-1537). Clear stimulation of the soles of the Christ Child's feet by the angel's elbow is visible in this painting. Two paintings by Leonardo da Vinci also showed a bilateral Babinski sign (*Madonna of the Carnation*, c1479, Alte Pinakothek, Munich; *Madonna Benois*, c1480, Hermitage Museum, Saint Petersburg).

Discussion

The presence of the Babinski sign has already been reported for some Renaissance paintings, and the first observations date from the beginning of the 20th century.²⁻³ More recently, several articles have highlighted paintings by Botticelli containing the Babinski sign.⁷⁻⁹ However, some other paintings with the toe phenomenon have scarcely been written about,^{8,10} and, until now, no systematic study of the Babinski sign in paintings of the Christ Child from the Renaissance period (1400-1550 CE) has been reported. We did such a study using a specific and strict method, and we observed that 30% (90/302) of the corpus of paintings portrayed the Babinski sign, with a stimulating factor in 53% (48/90) of cases.

Possible explanations

This frequency mainly results from the artistic revolution of the 15th century. In the Middle Ages, when trying to illustrate Jesus Christ, painters often represented him as a small man, with a child's height but the body and the face of an adult. Even though this way of depicting the Christ Child is still used in some Orthodox traditions, it might be regarded as an incongruity, as highlighted by Huysmans: “To make the inexpressible childhood of a God (...) they created a hybrid being, who is no longer a child, and who is not a God, some kind of monster.”¹¹ During the Renaissance, artists began to represent the nudity of the Christ Child to demonstrate the incarnation of Christ, who was subsequently portrayed in a very realistic form. Modern art historians postulate that the imagery of the overtly sexed Christ was an affirmation of kinship with the human condition.¹²

As a consequence of a growing desire for realism, most Renaissance painters no longer depicted the Christ Child as a small man but as a real infant. If they had live infants as models, they were more likely to involuntarily reproduce the Babinski sign. This realism was not merely the consequence of the Italian

Table 1 | Overview of corpus of 302 paintings

Artist (dates)	Paintings (n=302)	Babinski sign (n=90)	Stimulation when Babinski sign is present (n=48)
Jan van Eyck (c1390-1441)	6	0	0
Fra Angelico (c1400-1455)	15	0	0
Rogier van der Weyden (c1400-1464)	13	8	2
Masaccio (1401-1428)	8	0	0
Fra Filippo Lippi (1406-1469)	26	1	1
Andrea del Verrocchio (c1435-1488)	8	4	4
Hans Memling (c1435-1494)	17	11	3
Sandro Botticelli (144-1510)	30	12	9
Domenico Ghirlandaio (1448-1494)	12	1	1
Martin Schongauer (c1450-1491)	8	5	2
Gérard David (c1450-1523)	25	8	4
Leonardo da Vinci (1452-1519)	9	2	2
Albrecht Dürer (1471-1528)	13	5	4
Lucas Cranach the Elder (1472-1553)	47	18	6
Matthias Grünewald (c1475-1528)	3	2	0
Giorgio Barbarelli (1477-1510)	5	2	2
Raphael (1483-1520)	33	9	8
Tiziano (c1488-1576)	12	0	0
Paolo Caliari Veronese (1528-1588)	12	2	0

Renaissance revolution, as it is much more the hallmark of Flemish and Rhenish painters (particularly van der Weyden, Memling, Schongauer, and Grünewald), known for their tendency to paint precise, sometimes trivial, realistic details from everyday life. This trend towards realistic depictions is also shown by the fact that in these paintings, the infants, clothes, and general surroundings belong to the Western world contemporary to the painters and are not representative of the Middle East in the first century CE. This tendency may also explain the painters' frequent reproduction of the Babinski sign as soon as representation of the infant's nudity became acceptable, examples of which are given in figure 2 (A-C and E). By contrast, Italian painters tended to depict idealised human bodies, with a quest for perfect beauty, as seen in the models of antiquity. Therefore, some painters, such as Fra Angelico, Masaccio, or Tiziano, failed to reproduce the Babinski sign in paintings of the Christ Child.

The stimulating atmosphere of the Renaissance period and the need for a scientific approach and precise observation of live infants to improve likenesses has been proposed as a possible explanation of the representation of the Babinski sign in paintings of the Christ Child. The particular influence of the Renaissance led to accurate depiction of natural phenomena, especially in painting. Botticelli was an example of this new focus; 40% (12/30) of his paintings in this study depict a Babinski sign. Nevertheless, many great painters such as Raphael, known to have an eye for the finest details of their subjects, almost never depicted the Christ Child with an upgoing toe. Many Renaissance painters were aware of medical and anatomical realities; neurological abnormalities such as ulnar claw or facial dystonia appear in Renaissance paintings,^{13 14} and some painters, such as Michelangelo and da Vinci, did anatomical dissections. However, this pursuit of anatomical knowledge seems not to have been a determining factor for the depiction

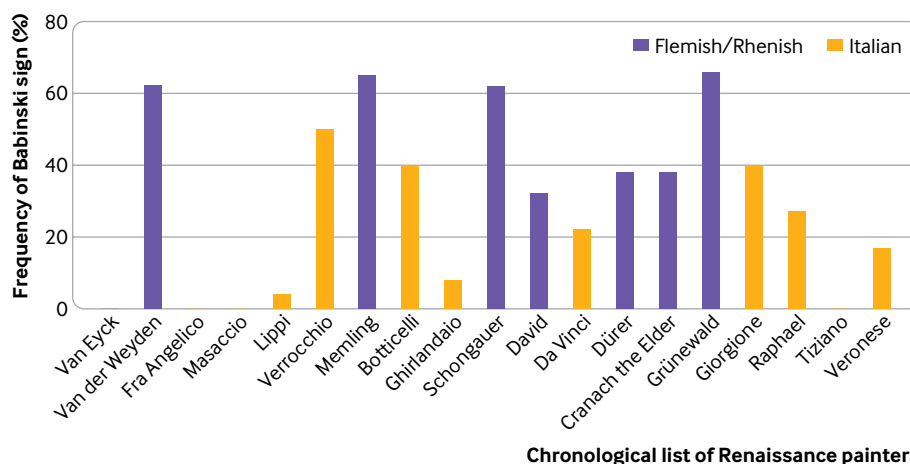


Fig 1 | Chronological overview of 19 painters included in study. Frequency of Babinski sign in paintings by artists

of the Babinski sign in painting; da Vinci, who was an anatomist and contributed to the study of the nervous system,¹⁵ depicted the Babinski sign in only 22% (2/9) of his paintings of the Christ Child. Similarly, no Tiziano paintings portray the toe phenomenon. However, Tiziano, with his student Jan van Calcar (c1499-1545), certainly participated in the illustrations for the anatomical masterpiece *De Corporis Fabrica* by Andreas Vesalius (1514-64).¹⁶

To explain about 30% of the paintings displaying a Babinski sign in our study, two other mechanisms can be discussed: the “master-student effect,” and the copying effect. In our corpus, a master-student effect could be suspected regarding Leonardo da Vinci and his master Andrea del Verrochio. It is interesting to note that the three paintings of the Christ Child with a bilateral Babinski sign were produced by Andrea del Verrochio (*The Virgin and Child with Two Angels*, c1470) (fig 2, D) and Leonardo da Vinci (*Madonna of the Carnation*, c1479, and *Madonna Benois*, c1480).

This hypothesis of artistic filiation is supported by the bilateral Babinski sign that was recently observed on a sculpture attributed to da Vinci (*Virgin with the Laughing Child*).¹⁷

The practice of copying works of art was frequent during the Renaissance, particularly for Virgin and Christ Child paintings. The painting *Saint Luke Drawing the Virgin*, of which many copies exist, is a clear example of this.¹⁸ However, examples of serial paintings, such as *Madonna and Child with the Milk Soup* by Gérard David, which was reproduced in at least three versions, are rare. The Babinski sign is not present in the version of this painting exhibited in the Palazzo Bianco in Genoa, whereas it is present in the other two versions. Cranach the Elder frequently produced serial paintings of the Madonna and Child, reproducing the Babinski sign each time, but this phenomenon cannot explain the occurrence of the sign in other paintings by the same artist, such as *The Virgin and Child with a Bunch of Grapes* (Fig 2, E).



Fig 2 | Details from five paintings depicting a Babinski sign. A: Rogier van der Weyden, *St Luke Drawing the Virgin* (1435-40), Boston Fine Arts Museum (USA). B: Gérard David, *Virgin Among the Virgins* (c1509), Musée des Beaux-Arts de Rouen (France). C: Martin Schongauer, *Orlier Altarpiece* (1470-75), Musée Unterlinden, Colmar (France). D: Verrocchio, *The Virgin and Child with Two Angels* (1476), National Gallery, London (UK). E: Lucas Cranach the Elder, *The Virgin and Child with a Bunch of Grapes* (c1525), Alte Pinakothek, Munich (Germany)

An alternative hypothesis is that the dorsiflexion of the toes in some of Botticelli's or Cranach's infants is a Mannerist stylistic choice, as shown also by the formalised placements of the fingers.⁹ However, this cannot be the correct explanation, as Mannerism is an artistic style that emerged only in the later years of the Italian High Renaissance (around 1520), breaking all the codes of anatomical accuracy, proportion, and balance.¹⁹ Mannerism is clearly absent in paintings by Flemish painters such as Rogier van der Weyden or Gérard David or Rhenish painters such as Martin Schongauer, who frequently depicted the Babinski sign. Examples of works containing the Babinski sign by these artists are in figure 2 (A, B, and C).

Many studies of the plantar reflex in infants have been published. These have sometimes reported contradictory findings about the flexion or extension response (Babinski sign) of this reflex. One reason for these heterogeneous results may be the interference of the grasp reflex of the toes, which is generally present during the first year of life. Taking the grasp reflex into account, the physiological response of the plantar reflex until the age of 6 months is hallux extension. The main factor in eliciting the hallux extension in infants seems to be the intensity of the stimulus.^{4 20} In our corpus, we observed stimulation of the foot in 53% (48/90) of the paintings. We obviously could not evaluate the intensity of this stimulus. Nevertheless, as already noted, in some cases the stimulus was directly applied to the lateral part of the sole, the site known to elicit the Babinski sign.⁷

At the age of 6 months, hallux extension usually ceases to be the manifestation of the plantar reflex.^{4 20} Nativity, Adoration of the Magi, and Presentation at the Temple paintings are supposed to be set during the first week of Jesus's life, and Madonna and Child paintings during the first year. Evidently, the age of the Christ Child as depicted in paintings does not correspond to the chronological reality of these events. We therefore cannot show a relation between the frequency of the Babinski sign and the subject matter of the paintings in our series. Even if a preoccupation with realism dominated in this artistic period, the painted Christ Child usually appears older than the reality. As determining the precise age of the model is difficult, we are not able to establish a correlation with the myelinisation of the nervous system. The use of older children as models might therefore explain the low frequency of the depiction of the Babinski sign by some painters.

Conclusions

The Babinski sign is frequently depicted in the Renaissance paintings of the Christ Child that we analysed: 90/302 (30%). Several factors contributed to this phenomenon, including the physiological plantar reflex in newborns and children, a revolution in painting in the 15th century (the authorisation to portray the nudity of the Christ Child to demonstrate the incarnation), and the need the Renaissance painters felt to use a scientific approach and precise

observation of anatomy. Finally, a taste for painting precise, sometimes trivial, and very realistic details from everyday life was a more common characteristic of Rhenish and Flemish painters and explains why they would be more likely to involuntarily depict the Babinski sign when painting live infants. As for Italian Renaissance painters, although some portrayed the toe phenomenon, their tendency to idealise the beauty of human body, whether Mannerist or not, may explain the fact that they often did not reproduce the Babinski sign.

We thank Suzanne Braun for the fruitful discussions, Moana Jardin and Nathalie Naffzger for the graphic work, and Jennifer Dobson for proofreading the article.

Contributors: FS and LT designed and conceptualized the study, acquired and interpreted the data, and drafted the manuscript. The corresponding author attests that all listed authors meet authorship criteria and that no others meeting the criteria have been omitted. FS is the guarantor.

Funding: None.

Competing interests: All authors have completed the ICMJE uniform disclosure form at www.icmje.org/coi_disclosure.pdf and declare: no support from any organisation for the submitted work; no financial relationships with any organisations that might have an interest in the submitted work in the previous three years; no other relationships or activities that could appear to have influenced the submitted work.

Ethical approval: Not needed.

Data sharing: No additional data available.

The lead author (the manuscript's guarantor) affirms that this manuscript is an honest, accurate, and transparent account of the study being reported; that no important aspects of the study have been omitted; and that any discrepancies from the study as planned (and, if relevant, registered) have been explained.

Dissemination to participants and related patient and public communities: As the results of this study do not have any direct implications for patient care, we do not intend to disseminate the results to any patient or public communities.

Provenance and peer review: Not commissioned; externally peer reviewed.

This is an Open Access article distributed in accordance with the Creative Commons Attribution Non Commercial (CC BY-NC 4.0) license, which permits others to distribute, remix, adapt, build upon this work non-commercially, and license their derivative works on different terms, provided the original work is properly cited and the use is non-commercial. See: <http://creativecommons.org/licenses/by-nc/4.0/>.

- Babinski J. Sur le réflexe cutané plantaire dans certaines affections organiques du système nerveux central. *C R Séances. Soc Biol* 1896;3:207-8.
- Laignel-Lavastine M. L'extension des orteils dans l'art. *Nouv. icon. Salpêtrière* 1905;18:117-20.
- Rosenblum S. Du développement du système nerveux au cours de la première enfance. Thesis. Le François, Paris, 1915.
- Van Gijn J. The plantar reflex. An historical, clinical and electromyographic study. Thesis. The Netherlands Krips Repro, Meppel, 1977.
- Ng YT, Bodensteiner JB. The extensor plantar response in neonates is not the same as the Babinski sign. *Pediatr Neurol* 2005;32:218, author reply 218-9. doi:10.1016/j.pediatrneurol.2004.10.006
- Landau WM. The extensor plantar response in neonates is not the same as the Babinski sign. *Pediatr Neurol* 2005;33:223. doi:10.1016/j.pediatrneurol.2005.07.001
- Cone TE Jr, Khoshbin S. Botticelli demonstrates the Babinski reflex more than 400 years before Babinski; pediatrics in art. *Am J Dis Child* 1978;132:188. doi:10.1001/archpedi.1978.02120270086018
- Massey EW, Sanders L. Babinski's sign in medieval, Renaissance, and baroque art. *Arch Neurol* 1989;46:85-8. doi:10.1001/archneur.1989.00520370087025
- Di Rocco C. Botticelli and the Babinski sign. *Childs Nerv Syst* 2006;22:1061-2. doi:10.1007/s00381-006-0144-1
- Tatu L. A newly discovered Babinski sign in a Renaissance painting. *Eur Neurol* 2017;77:195. doi:10.1159/000455844

- 11 Huysmans JK. *De Tout*. Chapter 10. Noëls au Louvre. Stock, 1902: 137-47.
- 12 Steinberg L. *The sexuality of Christ in Renaissance art and in modern oblivion*. 2nd ed. University of Chicago Press, 1996. doi:10.7208/chicago/9780226226316.001.0001
- 13 Bono F, Morelli M, Quattrone A. Facial dystonia as depicted in art in the time of Leonardo da Vinci. *Lancet Neurol* 2015;14:351. doi:10.1016/S1474-4422(15)70012-8
- 14 Vein AA, Mouret A. Claw hand in a Renaissance portrait. *Lancet Neurol* 2018;17:742. doi:10.1016/S1474-4422(18)30282-5
- 15 Pevsner J. Leonardo da Vinci's studies of the brain. *Lancet* 2019;393:1465-72. doi:10.1016/S0140-6736(19)30302-2
- 16 Hazard J. [Jan Stephan Van Calcar, a valuable and unrecognized collaborator of Vesalius]. *Hist Sci Med* 1996;30:471-80.
- 17 Brigo F, Caglioti F. Babinski sign in the only existing sculpture by Leonardo. *Childs Nerv Syst* 2019. doi:10.1007/s00381-019-04342-6
- 18 Ishikawa C. Rogier van der Weyden's Saint Luke drawing the Virgin reexamined. *Journal of the Museum of Fine Arts Boston* 1990;2:49-64.
- 19 Charlier P, Lippi D, Perciaccante A, Appenzeller O, Bianucci R. Neurological disorder? No, Mannerism. *Lancet Neurol* 2019;18:135. doi:10.1016/S1474-4422(18)30447-2
- 20 Gingold MK, Jaynes ME, Bodensteiner JB, Romano JT, Hammond MT. The rise and fall of the plantar response in infancy. *J Pediatr* 1998;133:568-70. doi:10.1016/S0022-3476(98)70071-X