

Ataxia-Telangiectasia: Atypical Presentation and Toxicity of Cancer Treatment

Rochelle A. Yanofsky, Sashi S. Seshia, Angelika J. Dawson, Kent Stobart, Cheryl R. Greenberg, Frances A. Booth, Chitra Prasad, Marc R. Del Bigio, Jens J. Wrogemann, Francesca Fike, Richard A. Gatti

ABSTRACT: Background: The onset of progressive cerebellar ataxia in early childhood is considered a key feature of ataxia-telangiectasia (A-T), accompanied by ocular apraxia, telangiectasias, immunodeficiency, cancer susceptibility and hypersensitivity to ionizing radiation. **Methods:** We describe the clinical features and course of three Mennonite children who were diagnosed with A-T following the completion of therapy for lymphoid malignancies. **Results:** Prior to cancer therapy, all had non-progressive atypical neurological abnormalities, with onset by age 30 months, including dysarthria, dyskinesia, hypotonia and/or dystonia, without telangiectasias. Cerebellar ataxia was noted in only one of the children and was mild until his death at age eight years. None had severe infections. All three children were "cured" of their lymphoid malignancies, but experienced severe adverse effects from the treatments administered. The two children who received cranial irradiation developed supratentorial primitive neuroectodermal tumors of the brain, an association not previously described, with fatal outcomes. **Conclusions:** The range of neurological presentations of A-T is broad. Ataxia and telangiectasias may be minimal or absent and the course seemingly non-progressive. The diagnosis of A-T should be considered in all children with neuromotor dysfunction or peripheral neuropathy, particularly those who develop lymphoid malignancies. The consequences of missing the diagnosis may be dire. Radiation therapy and radiomimetic drugs should be avoided in individuals with A-T.

RÉSUMÉ: Mode de présentation atypique et toxicité du traitement anticancéreux chez les patients atteints d'ataxie-télangiectasie. Contexte : L'apparition d'une ataxie cérébelleuse progressive dans la petite enfance est considérée comme une manifestation clé de l'ataxie-télangiectasie (A-T), accompagnée d'apraxie oculaire, de télangiectasies, d'un déficit immunitaire, de susceptibilité au cancer et d'hypersensibilité aux radiations ionisantes. **Méthodes :** Nous décrivons les manifestations cliniques et l'évolution chez trois enfants mennonites chez qui un diagnostic d'A-T a été posé après un traitement pour cancer lymphoïde. **Résultats :** Avant le traitement anticancéreux, tous présentaient des anomalies neurologiques atypiques non évolutives, dont l'âge de début se situait vers 30 mois, soit de la dysarthrie, des dyskinesies, de l'hypotonie et/ou de la dystonie sans télangiectasies. Une ataxie cérébelleuse a été notée chez un seul des enfants et elle est demeurée légère jusqu'à son décès à l'âge de huit ans. Aucun n'a présenté d'infection grave. Les trois enfants ont été « guéris » de leur cancer lymphoïde. Cependant tous ont présenté des effets secondaires du traitement. Les deux enfants qui ont reçu une irradiation crânienne ont présenté des tumeurs cérébrales neuroectodermiques primitives sus-tentorielles, une association jamais décrite auparavant, dont l'issue a été fatale. **Conclusions :** Le mode de présentations neurologiques de l'A-T est vaste. L'ataxie et les télangiectasies peuvent être minimales ou absentes et sans évolution apparente. Le diagnostic d'A-T devrait être envisagé chez tous les enfants qui présentent une dysfonction neuromotrice ou une neuropathie périphérique, surtout chez ceux qui présentent éventuellement un cancer lymphoïde. Si le diagnostic n'est pas posé, les conséquences peuvent être sérieuses. La radiothérapie et les médicaments radiomimétiques devraient être évités chez les individus atteints d'A-T.

Can. J. Neurol. Sci. 2009; 36: 462-467

Ataxia-telangiectasia (A-T) is an autosomal recessive genomic instability syndrome characterized by progressive cerebellar ataxia, oculocutaneous telangiectasias, immunodeficiency, hypersensitivity to ionizing radiation, and cancer predisposition, with lymphoid malignancies predominating in the first two decades of life¹⁻¹⁰. Mutations in the Ataxia-telangiectasia mutated (ATM) gene result in markedly decreased or absent levels of ATM kinase, a protein that phosphorylates many downstream targets. A deficiency of ATM kinase leads to cell cycle defects, faulty repair of DNA damage, defective apoptosis, and poor responses to oxidative stress^{1,3,11}.

From the Section of Pediatric Hematology/Oncology (RAY, KS), Department of Pediatrics & Child Health (RAY, AJD, CRG, FAB), Departments of Biochemistry & Medical Genetics (AJD, CRG), Division of Laboratory Medicine & Pathology, Section of Genetics and Metabolism (AJD), University of Manitoba & Health Sciences Centre (AJD, MRD, JJW), Winnipeg, MB; Section of Pediatric Neurology (SSS), Department of Pediatrics, University of Saskatchewan, Saskatoon, SK; Department of Pediatrics, Northern Alberta Children's Cancer Program (KS), University of Alberta, Edmonton, AB; Department of Pediatrics (CP), University of Western Ontario, London, ON, Canada; Department of Pathology (MRD), Diagnostic Imaging, Section of Pediatric Radiology (JJW), Departments of Pathology & Laboratory Medicine and Human Genetics (FF, RAG), UCLA/Geffen School of Medicine, Los Angeles, CA, USA.

RECEIVED FEBRUARY 4, 2009. FINAL REVISIONS SUBMITTED MARCH 25, 2009.

Correspondence to: Rochelle A. Yanofsky, Section of Pediatric Hematology/Oncology, CancerCare Manitoba, 675 McDermot Ave., Winnipeg, Manitoba, R3E 0V9, Canada.

We describe three Mennonite children who were diagnosed with A-T after completing treatment for lymphoid malignancies. All had mild, atypical, seemingly non-progressive pre-existing neurological abnormalities, without telangiectasias. Subsequently, all suffered severe adverse effects of cancer therapy; two developed supratentorial primitive neuroectodermal tumors (PNET) of the brain following cranial irradiation.

CASE REPORTS

Patient 1 (Index case)

This child was born at term to a Mennonite mother and a Salvadorian father. Consanguinity was denied. The family history was positive for dystonia in several maternal male and female cousins, many of whom are now over 30 years old; none were available for examination. The child was noted to be clumsy at age one year, when he began to walk. Speech was delayed. He was diagnosed with T-cell acute lymphoblastic leukemia (T-ALL) without central nervous system involvement at age 20 months. He was treated with multiagent systemic chemotherapy, intrathecal chemotherapy, cranial irradiation (1800 centigray [cGy]) and mediastinal irradiation (300 cGy), according to Pediatric Oncology Group Protocol 9404. He did not experience excessive toxicity during treatment. His care was transferred to our center three months after he completed therapy. Dysarthria, jerky movements of the eyes, face, head and neck, generalized dyskinesia, and mild ataxia were noted at that time, with no telangiectasias. He drooled continually. His mother did not feel that his neurological function had deteriorated since infancy.

A serum alpha-fetoprotein (AFP) level was performed as a screening test for A-T when he was four years and four months old, and was elevated (Table). Subsequent testing confirmed the diagnosis of A-T (Table and Figure 1). Magnetic resonance imaging (MRI) of the brain was normal, as were his serum IgG, IgA, and IgM levels.

At age seven years and nine months, he presented with recurrent vomiting and lethargy. Magnetic resonance imaging of

Table: Results of testing for Ataxia-Telangiectasia (A-T)

Patient	1	2	3
Age at diagnosis of A-T	4 y, 4 mo	10 y	17 y
Serum AFP* (µg/L)	135	32	178
Rearrangements of chromosomes 7 & 14†	Increased	Increased	Increased
Colony Survival Assay (Survival fraction)‡	19%	20%	6%
ATM Protein§	Absent	Absent	Absent

*Serum Alpha-fetoprotein: Normal range 0-7 after age two years;

†Cytogenetic analysis of spontaneous and bleomycin-treated peripheral blood lymphocytes⁵⁷; ‡Radiosensitivity assay. Diagnostic range is <21%^{60,61}; §Ataxia-telangiectasia mutated protein (immunoblot)³⁵.

the brain showed two mixed cystic and solid tumors with peripheral enhancement, including one in the left temporoparietal region (5.2 to 5.8 cm diameter) and one in the left occipital lobe (2.5-3.1 cm diameter) (Figure 2). The histologic diagnosis was supratentorial PNET (Figure 3). Gross residual tumor remained following surgery. The family opted for palliation. The child died four months later. An autopsy was not performed.

Patient 2

This child was born at term to Mennonite parents, who were second cousins. The family history was positive for familial dystonia in several paternal male and female relatives, including the father's sister, who is now over 50 years old and has cervical dystonia. The child was noted to have poor balance and coordination when he started to walk at age one year. He

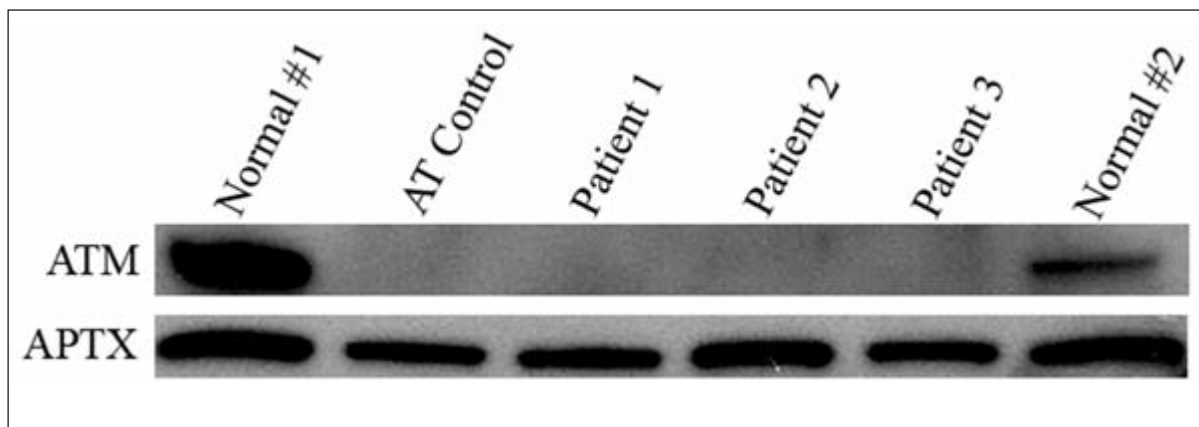


Figure 1: Immunoblot of nuclear lysates, developed with antibodies to ATM and Aprataxin (APTX) (loading control). Note absence of ATM protein in Patients 1, 2 and 3.

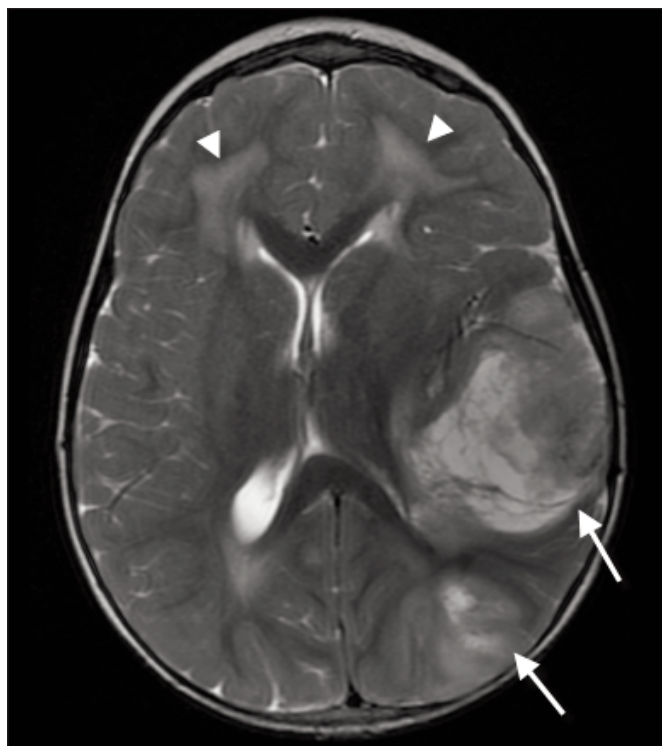


Figure 2: Patient 1: Axial T2-weighted MRI at level of basal ganglia showing multifocal PNET (arrows) and white matter injury from previous chemotherapy and radiotherapy (arrowheads).

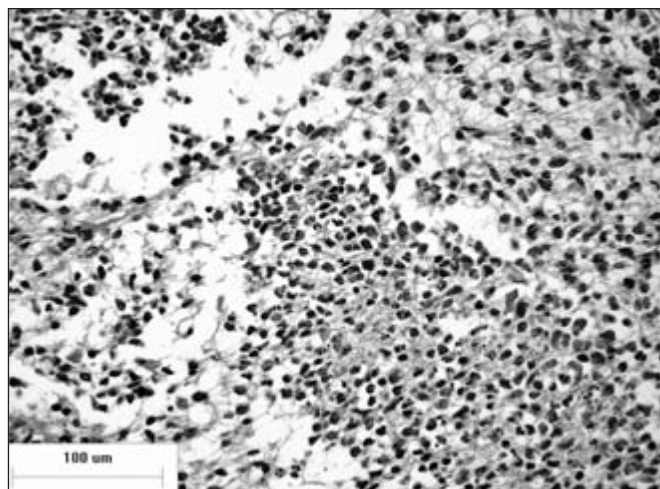


Figure 3: Patient 1: Microscopic examination of the tumor showed a highly cellular small cell neoplasm with brisk mitotic activity and necrosis. The cells were immunoreactive for S100, neuron specific enolase (NSE), synaptophysin, protein gene product 9.5 (Pgp9.5), neuronal nuclei (NeuN) (regional), Ki67 (>50%) and glial fibrillary acidic protein (GFAP) (very rare), but not epithelial membrane antigen (EMA) or cytokeratin CAM5.2. The final diagnosis was supratentorial PNET (WHO grade IV).

exhibited choreiform posturing of his hands and twisting movements of his mouth. He was diagnosed with familial dystonia. He did not have telangiectasias, then or subsequently. His development was normal.

He was diagnosed with high-risk T-cell ALL with central nervous system involvement at age 31 months. Computed tomogram scan of the brain performed with and without contrast revealed no significant abnormalities. He received multiagent chemotherapy, intrathecal methotrexate, and craniospinal irradiation (2400 cGy to the brain and 600 cGy to the spine), according to regimen C of Children's Cancer Group protocol 1882. He exhibited neurodevelopmental regression ten months after starting therapy, and was considered to have severe treatment-related leuko-encephalopathy, a diagnosis supported by MRI of the brain. He completed therapy at age six years. Seizures, growth hormone deficiency, hypothyroidism, precocious puberty, bilateral conductive hearing loss, and scoliosis were diagnosed between ages eight and ten years.

Because of the severe adverse effects that he experienced from radiation therapy, his pre-existing neurological abnormalities, and our experience with the index case, he was evaluated for A-T at age ten years. His serum AFP level was elevated (Table). Subsequent testing confirmed the diagnosis of A-T (Table and Figure 1).

The child developed a right hemiparesis and lethargy at age 12 years. An MRI of the brain showed two mixed solid and

cystic tumors, including one in the left parieto-occipital lobe (4.3 to 6.2 cm in diameter), and one in the left parietal region (1.7 to 2.8 cm diameter) (Figure 4). The solid portion of the masses showed avid gadolinium enhancement. The histologic diagnosis was supratentorial PNET (Figure 5). Gross residual tumor remained following surgery. The family opted for palliation. The child died six months later. An autopsy was not performed.

Patient 3

This child was born at term to an Australian mother and a Mennonite father. Patients 2 and 3 were second cousins. Patient 3 was not related to Patient 1 by family history. Generalized hypotonia was evident by age 30 months, accompanied by delayed fine motor skills, clumsiness, and slurred speech. His handwriting was subsequently noted to be slow and disorganized. At age 12 years he presented with generalized lymphadenopathy and was diagnosed with stage IV T-cell lymphoblastic non-Hodgkin lymphoma, with bone marrow involvement, but no central nervous system involvement. He was lymphopenic, with an absolute lymphocyte count of $0.675 \times 10^9/L$ (normal 1.2 to 5.2). Serum IgG, IgA, and IgM levels were normal. He received intensive multiagent chemotherapy and intrathecal methotrexate, without radiation therapy, according to Children's Cancer Group protocol 5941. He completed treatment at age thirteen years and six months. He had significant problems with peripheral neuropathy, a toxicity which was likely due to vincristine, and which has still not completely resolved.

Because of his pre-existing neurological abnormalities and his relationship to Patient 2, he was screened for A-T at age seventeen years. His serum AFP level was elevated (Table).

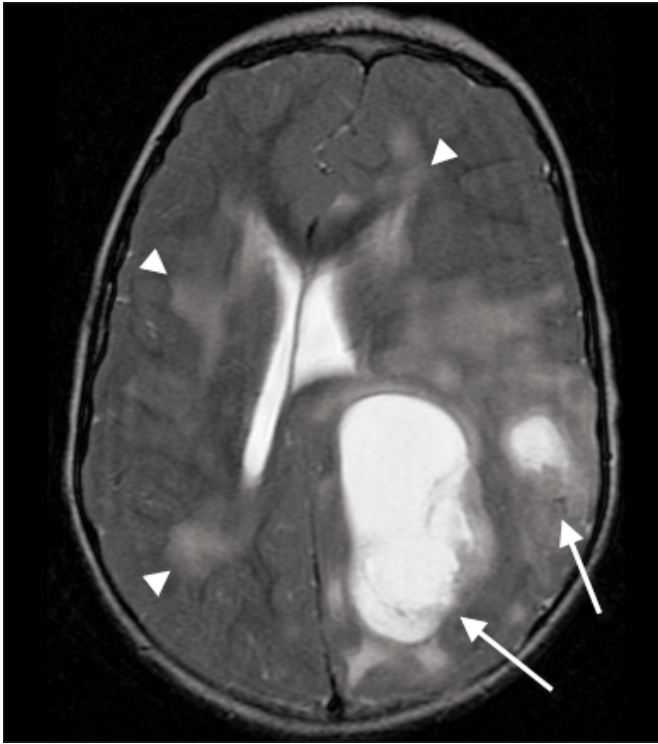


Figure 4: Patient 2: Axial T2-weighted MRI at level of lateral ventricles showing multifocal PNET (arrows) and white matter injury from previous chemotherapy and radiotherapy (arrowheads).

Subsequent testing confirmed the diagnosis of A-T (Table and Figure 1). At age 23 years, his neurologic status is stable. He remains cancer-free.

DISCUSSION

Individuals with “classic” A-T are usually ataxic by age two years, and are often wheelchair-bound by age ten years. Telangiectasias are typically evident by age six to ten years^{1,11-13}. Our patients had seemingly non-progressive neurological abnormalities, including dysarthria, dyskinesia, generalized hypotonia and/or dystonia, and drooling, without telangiectasias. Only Patient 1 was ataxic when first referred. None had excessive problems with recurrent infection, even while receiving treatment for their lymphoid malignancies.

Milder phenotypes or atypical presentations of A-T have been described in the literature^{1,11,13-28}. Some individuals with A-T have no neurological signs or symptoms¹⁷. Others have no telangiectasias, even in adulthood^{1,11,13}. Mild ataxia, the onset of ataxia in adulthood,^{21,23} slow neurological deterioration²⁰, a progressive axonal sensorimotor polyneuropathy²⁹⁻³², and late-onset spinal muscular atrophy²⁵ have also been described. Extrapyraxial features are more prominent in older children. Dystonia^{22,28} or chorea²⁶ may be the initial or most prominent manifestation of A-T. Oculomotor apraxia^{33,34}, drooling, progressive hypomimia, slow speech with abnormalities of articulation, and progressive difficulty with chewing and

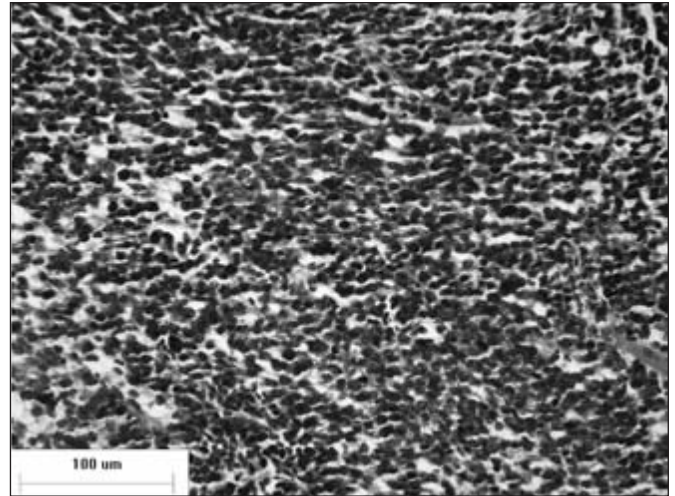


Figure 5: Patient 2: Microscopic examination of the tumor showed a highly cellular small cell neoplasm with brisk mitotic activity and endothelial hyperplasia. The cells were immunoreactive for Pgp9.5, synaptophysin (regional), NeuN (rare), and Ki67 (~20%), but not GFAP or cytokeratin CAM5.2. The final diagnosis was supratentorial PNET (WHO grade IV).

swallowing are commonly seen^{2,4-6,12,23}. Handwriting is typically affected by age eight years¹¹.

Milder A-T phenotypes are sometimes associated with missense mutations and/or reduced (but detectable) amounts of ATM protein^{1,14,19-21,24,27,35}. Our A-T patients had a “milder” neurological phenotype. However, they had no ATM protein and did not have missense mutations, nor did they have the c.5932 G>T ATM mutation previously reported in other Mennonite families^{36,37}. The results of their genotyping and haplotyping analyses are beyond the scope of this paper and will be reported subsequently.

The lifetime frequency of cancer in A-T patients approaches 38%⁹, with 5% of patients developing more than one malignancy³. As exemplified by our patients, the diagnosis of malignancy may precede the diagnosis of A-T^{38,39}; management of the cancer may be confounded by increased sensitivity to ionizing radiation and radiomimetic drugs³⁹⁻⁴⁵.

Patients 1, 2, and 3 were cured of their lymphoid malignancies. However, all had severe adverse effects from the treatment that they received. Patient 3 had a severe peripheral neuropathy which was likely due to vincristine. This is in keeping with the reported heightened sensitivity to the neurotoxic effects of vincristine seen in individuals with neuromuscular disorders⁴³.

Patients 1 and 2 received cranial irradiation; both developed a second malignant neoplasm (a supratentorial PNET of the brain). This was likely radiation-induced, and had a fatal outcome. While medulloblastomas^{41,46,47}, astrocytomas^{9,46,48-51}, craniopharyngiomas⁵², and primary central nervous system (CNS) lymphomas⁵³ have been described in individuals with A-T, supratentorial PNET's have not. Also of note is that ATM gene mutations do not appear to play a role in the pathogenesis of

medulloblastoma in children who do not have A-T⁵⁴. The development of a PNET of the brain following cranial irradiation has been described in individuals without A-T, but is very uncommon; it is usually fatal⁵⁵. To our knowledge, our patients represent the first published cases of a second malignant neoplasm in the radiation field in patients with A-T, as well as the first published cases of a supratentorial PNET of the brain following cranial irradiation in individuals with A-T. It is intriguing that the brain tumors seen in these two patients appeared to be multifocal.

Patient 2 also experienced many other adverse effects of craniocervical irradiation, including leukoencephalopathy, growth hormone deficiency, precocious puberty, hypothyroidism, bilateral conductive hearing loss, and scoliosis. Leukoencephalopathy has been described in children with A-T after prophylactic cranial irradiation⁵⁶ as well as in children without A-T.

Serum alpha-fetoprotein is a simple, rapid, and reliable screening test for A-T; it is elevated in more than 90% of A-T cases¹. Cytogenetic studies reveal rearrangements involving chromosomes 7 and 14 in 5 to 15 percent of normal peripheral blood lymphocytes in individuals with A-T⁵⁷⁻⁵⁹. However, karyotyping can be technically difficult because the patients are often lymphopenic and the lymphocytes may not respond well to phytohemagglutinin (PHA). Confirmatory tests for A-T include the colony radio-sensitivity assay and identification of the ATM protein by immunoblotting^{1,35,60-62}. These tests currently take three months to complete. DNA sequencing is usually not definitive because the full spectrum of ATM mutations has not yet been established and not all mutations are detected by any single laboratory platform⁶³. A new flow cytometry-based assay that detects ATM kinase activity in peripheral blood mononuclear cells promises to shorten diagnostic testing to three days⁶⁴.

The range of neurological presentations of A-T is broad. Ataxia may be minimal or absent and the course seemingly non-progressive. The diagnosis of A-T should be considered in all children with neuromotor dysfunction or peripheral neuropathy, especially those who develop acute lymphoblastic leukemia, non-Hodgkin lymphoma or Hodgkin lymphoma. Radiation therapy and radiomimetic drugs such as bleomycin are best avoided in A-T patients with cancer^{3,39,46,65}. The observations herein suggest that cranial irradiation may be especially dangerous. The need for a cooperative experience in the treatment of A-T patients who develop cancer is being addressed by the A-T Cancer Clinic at St. Jude Children's Research Hospital²⁴.

ACKNOWLEDGEMENTS

The authors thank Dr. Shareef Nahas for his technical assistance; Diane Riordan for her cytogenetic expertise; Dr. Sara Israels for critiquing the manuscript; and Florinia Vicente for her assistance in preparing the manuscript.

FUNDING SOURCES

Dr. Gatti's work was supported by grants from the Ataxia-Telangiectasia Medical Research Foundation (Los Angeles), the A-T Ease Foundation (New York), and USPHS grants NS 052528 and AI 067769.

REFERENCES

1. Chun HH, Gatti RA. Ataxia telangiectasia, an evolving phenotype. *DNA Repair*. 2004;3:1187-96.
2. Regueiro JR, Porras O, Lavin M, Gatti RA. Ataxia-Telangiectasia. A primary immunodeficiency revisited. *Immunol Allergy Clin N Am*. 2000;20:177-206.
3. Spacey SD, Gatti RA, Bebb G. The molecular basis and clinical management of ataxia telangiectasia. *Can J Neurol Sci*. 2000; 27:184-91.
4. Crawford TO. Ataxia Telangiectasia. *Sem Pediatr Neurol*. 1998; 5:287-94.
5. Gatti RA, Boder E, Vinters HV, Sparkes RS, Norman A, Lange K. Ataxia-Telangiectasia: an interdisciplinary approach to pathogenesis. *Medicine*. 1991;70:99-117.
6. Boder E. Ataxia-telangiectasia: an overview. In: Gatti RA, Swift A, editors. *Ataxia-telangiectasia: genetics, neuropathology, and immunology of a degenerative disease of childhood*. New York, NY: Alan R. Liss;1985. p. 1-63.
7. Gatti RA, Good RA. Occurrence of malignancy in immunodeficiency diseases. *Cancer*. 1971;28:89-98.
8. Boder E, Sedgwick RP. Ataxia-Telangiectasia. A familial syndrome of progressive cerebellar ataxia, oculocutaneous telangiectasia, and frequent pulmonary infection. *Pediatrics*. 1958;21:526-54.
9. Morrell D, Cromartie E, Swift M. Mortality and cancer incidence in 263 patients with ataxia telangiectasia. *J Natl Cancer Inst*. 1986;(77):89-92.
10. Taylor AMR, Metcalfe JA, Thick J, Mak Y-F. Leukemia and lymphoma in ataxia telangiectasia. *Blood*. 1996;87:423-38.
11. Gatti RA. Ataxia-telangiectasia. In: Scriver CR, Beaudet AL, Sly WS, Valle D, editors. *The metabolic & molecular bases of inherited disease*. 8th ed. New York, NY: McGraw-Hill; 2001. p. 705-21.
12. Cabana MD, Crawford TO, Winkelstein JA, Christensen JR, Lederman HMI. Consequences of the delayed diagnosis of ataxia-telangiectasia. *Pediatrics*. 1998;102:98-100.
13. Gilad S, Chessa L, Khosravi R, Russell P, Galanty Y, Piane M, et al. Genotype-phenotype relationships in ataxia-telangiectasia and variants. *Am J Hum Genet*. 1998;62:551-61.
14. Alterman N, Fattal-Valevski A, Moyal L, Crawford TO, Lederman HM, Ziv Y, et al. Ataxia-telangiectasia: mild neurological presentation despite null ATM mutation and severe cellular phenotype. *Am J Med Genet A*. 2007;143:1827-34.
15. Crawford TO, Skolasky RL, Fernandez R, Rosquist KJ, Lederman HM. Survival probability in ataxia telangiectasia. *Arch Dis Child*. 2006;91:610-11.
16. Taylor AMR, Byrd PJ. Molecular pathology of ataxia telangiectasia. *J Clin Pathol*. 2005;58:1009-15.
17. Trimis GG, Athanassaki CK, Kanariou MM, Giannoulia-Karantana AA. Unusual absence of neurologic symptoms in a six-year old girl with ataxia-telangiectasia. *J Postgrad Med*. 2004; 50:270-1.
18. Taylor AMR, Groom A, Byrd PJ. Ataxia-telangiectasia-like disorder (ATLD)-its clinical presentation and molecular basis. *DNA Repair*. 2004;3:1219-25.
19. Sutton IJ, Last JIK, Ritchie SJ, Harrington HJ, Byrd PJ, Taylor AMR. Adult-onset ataxia telangiectasia due to ATM 5762ins137 mutation homozygosity. *Ann Neurol*. 2004;55:891-5.
20. Dork T, Bendix-Waltes R, Wegner R-D, Stumm M. Slow progression of ataxia-telangiectasia with double missense and in frame splice mutations. *Am J Med Genet*. 2004;126A:272-7.
21. Saviozzi S, Saluto A, Taylor AMR, Last JIL, Trebbini F, Paradiso MC, et al. A late onset variant of ataxia-telangiectasia with a compound heterozygous genotype, A8030G/7481insA. *J Med Genet*. 2002;39:57-61.
22. Goyal V, Behari M. Dystonia as presenting manifestation of ataxia telangiectasia: a case report. *Neurol India*. 2002;50:187-9.
23. Crawford TO, Mandir AS, Lefton-Greif MA, Goodman SN, Goodman SN, Sengul H, et al. Quantitative neurologic assessment of ataxia-telangiectasia. *Neurology*. 2000;54: 1505-09.
24. Lavin MF, Concannon P, Gatti RA. Eighth international workshop on ataxia-telangiectasia (ATW8). *Cancer Res*. 1999;59:3845-9.

25. Larnaout A, Belal S, Ben Hamida C, Ben Hamida L, Hentatif F. Atypical ataxia telangiectasia with early childhood lower motor neuron degeneration: a clinicopathological observation in three siblings. *J Neurol.* 1998;245:231-5.
26. Klein C, Wenning GK, Quinn NP, Marsden CD. Ataxia without telangiectasia masquerading as benign hereditary chorea. *Mov Disord.* 1996;11:217-20.
27. McConville CM, Stankovic T, Byrd PJ, McGuire QYY, Lennox GG, Taylor MR. Mutations associated with variant phenotypes in ataxia-telangiectasia. *Am J Hum Genet.* 1996;59:320-30.
28. Bodensteiner JB, Goldblum RM, Goldman AS. Progressive dystonia masking ataxia in ataxia-telangiectasia. *Arch Neurol.* 1980;37:464-5.
29. Verhagen MM, van Alfen N, Pillen S, Weemaes CM, Yntema JL, Hiel JAP, et al. Neuromuscular abnormalities in ataxia telangiectasia: a clinical, electrophysiological and muscle ultrasound study. *Neuropediatrics.* 2007;38:117-21.
30. Willems PJ, Van Roy BC, Kleijer WJ, Van der Kraan M, Martin JJ. Atypical clinical presentation of ataxia telangiectasia. *Am J Med Genet.* 1993;45:777-82.
31. Wong V, Yu YL, Chan-Lui WY, Woo E, Yeung CY. Ataxia telangiectasia in Chinese children. A clinical and electrophysiological study. *Clin Neurol Neurosurg.* 1987;89:137-144.
32. Barbieri F, Santoro L, Crisci C, Massini R, Russo E, Campanella G. Is the sensory neuropathy in ataxia telangiectasia distinguishable from that in Friedreich's ataxia? Morphometric and ultrastructural study of the sural nerve in a case of Louis Bar syndrome. *Acta Neuropathol.* 1986;69:213-19.
33. Lewis RF, Crawford TO. Slow target-directed eye movements in ataxia-telangiectasia. *Invest Ophthalmol Vis Sci (IVOS).* 2002;43:686-91.
34. Lewis RF, Lederman HM, Crawford TO. Ocular motor abnormalities in ataxia telangiectasia. *Ann Neurol.* 1999;46: 287-95.
35. Chun HH, Sun X, Nahas SA, Teraoka S, Lai CH, Concannon P, et al. A. Improved diagnostic testing for ataxia-telangiectasia by immunoblotting of nuclear lysates for ATM protein expression. *Mol Genet Metab.* 2003;80:437-3.
36. Orton NC, Innes AM, Chudley AE, Bech-Hansen NT. Unique disease heritage of the Dutch-German Mennonite population. *Am J Med Genet.* 2008;146A:1072-87.
37. Mitui A, Bernatowska E, Pietrucha B, Piotrowska-Jastrzebska J, Eng L, Nahas S, et al. ATM gene founder haplotypes and associated mutations in Polish families with ataxia-telangiectasia. *Ann Hum Genet.* 2005;69:657-64.
38. Loeb DM, Lederman HM, Winkelstein JA. Lymphoid malignancy as a presenting sign of ataxia-telangiectasia. *J Pediatr Hematol Oncol.* 2000;22:464-7.
39. Gotoff SP, Amirmokri E, Liebner EJ. Ataxia telangiectasia. Neoplasia, untoward response to x-irradiation, and tuberculous sclerosis. *Am J Dis Child.* 1967;114:617-25.
40. Abadir R, Hakami N. Ataxia telangiectasia with cancer. An indication for reduced radiotherapy and chemotherapy doses. *Br J Radiol.* 1983;56:343-5.
41. Hart RM, Kimler BF, Evans RG, Park CH. Radiotherapeutic management of medulloblastoma in a pediatric patient with ataxia telangiectasia. *Int J Radiat Oncol Biol Phys.* 1987;13: 1237-40.
42. Pritchard J, Sandland MR, Breatnach FB, Pincott JR, Cox R, Husband P. The effects of radiation therapy for Hodgkin's disease in a child with ataxia telangiectasia: a clinical, biological and pathological study. *Cancer.* 1982;50:877-86.
43. Toledano SR, Lange BJ. Ataxia-Telangiectasia and acute lymphoblastic leukemia. *Cancer.* 1980;45:1675-8.
44. Cunliffe PN, Mann JR, Cameron AH, Roberts KD. Radiosensitivity in ataxia-telangiectasia. *Br J Radiol.* 1975;48:374-6.
45. Morgan JL, Holcomb TM, Morrissey RW. Radiation reaction in ataxia telangiectasia. *Amer J Dis Child.* 1968;116:557-8.
46. Kersey JH, Spector BD, Good RA. Primary immunodeficiency diseases and cancer: the immunodeficiency-cancer registry. *Int J Cancer.* 1973;12:333-47.
47. Shuster J, Hart Z, Stimson CW, Brough AJ, Poulik MD. Ataxia Telangiectasia with cerebellar tumor. *Pediatr.* 1966;37:776-86.
48. Varan A, Büyükpamukçu M, Ersoy F, Sanal Ö, Akyüz C, Kutluk T, et al. Malignant solid tumors associated with congenital immunodeficiency disorders. *Pediatr Hematol Oncol.* 2004;21: 441-51.
49. Miyagi K, Mukawa J, Kinjo N, Horikawa K, Mekar S, Nakasone S, et al. Astrocytoma linked to familial ataxia-telegiectasia. *Acta Neurochir (Wien).* 1995;135:87-92.
50. Groot-Loonen JJ, Slater R, Taminiou J, Voûte PA. Three consecutive primary malignancies in one patient during childhood. *Pediatr Hematol Oncol.* 1988;5:287-92.
51. Berkel AI, Ersoy F. Ataxia-telangiectasia and malignancies. *Turk J Pediatr.* 1974;26:82-9.
52. Masri AT, Bakri FG, Al-Hadidy AM, Musharbash AF, Al-Hussaini M. Ataxia-telangiectasia complicated by craniopharyngioma – a new observation. *Pediatr Neurol.* 2006;35:287-8.
53. Murphy RC, Berdon WE, Ruzal-Shapiro C, Hall EJ, Kornecki A, Daneman A, et al. Malignancies in pediatric patients with ataxia-telangiectasia. *Pediatr Radiol.* 1999;29:225-30.
54. Liberzon E, Avigad S, Cohen IJ, Yaniv I, Michovitz S, Zaizov R. ATM gene mutations are not involved in medulloblastoma in children. *Cancer Genet Cytogenet.* 2003;146:167-9.
55. Hader WJ, Drovini-Zis K, Maguire JA. Primitive neuroectodermal tumors in the central nervous system following cranial irradiation. *Cancer.* 2003;97:1072-6.
56. Eyre JA, Gardner-Medwin D, Summerfield GP. Leuko-encephalopathy after prophylactic irradiation for leukemia in ataxia telangiectasia. *Arch Dis Child.* 1988;63:1079-93.
57. Lowery MC, Sinclair-Hess C, Carey JC, Brothman AR. Ataxia telangiectasia revitalized: the importance of cytogenetic analysis in the diagnosis of AT. *Appl Cytogenet.* 1994;20:49-51.
58. Kojis TL, Gatti RA, Sparkes RS. The cytogenetics of ataxia-telangiectasia. *Cancer Genet Cytogenet.* 1992;56:143-56.
59. Aurias A, Dutrillaux B, Buriot D, Lejeune J. High frequencies of inversions and translocations of chromosomes 7 and 14 in ataxia telangiectasia. *Mutat Res.* 1980;69:369-74.
60. Sun X, Becker-Catania SG, Chun HH, Hwang MJ, Huo Y, Wang Z, et al. Early diagnosis of ataxia-telangiectasia using radiosensitivity testing. *J Pediatr.* 2002;140: 724-31.
61. Huo YK, Wang Z, Hong JH, Chessa L, McBride WH, Perlman SL, et al. Radiosensitivity of ataxia-telangiectasia, X-linked agammaglobulinemia, and related syndromes using a modified colony survival assay. *Cancer Res.* 1994;54:2544-7.
62. Perlman S, Becker-Catania S, Gatti RA. Ataxia-Telangiectasia: diagnosis and treatment. *Sem Pediatr Neurol.* 2003;10:173-82.
63. Mitui M, Nahas SA, Chun HH, Gatti RA. Diagnosis of ataxia-telangiectasia: ATM mutation associated with cancer. In: Nakamura RM, Grody WW, Wu JT, Nagle RB, editors. *Cancer diagnostics: current and future trends.* Totowa, NJ: Humana Press; 2004. p. 473-87.
64. Nahas SA, Butch AW, Du L, Gatti RA. Rapid flow cytometry-based structural maintenance of chromosomes 1 (SMC1) phosphorylation assay for identification of ataxia-telangiectasia homozygotes and heterozygotes. *Clin Chem.* 2009;Jan 15. [Epub ahead of print].
65. Sandoval C, Swift M. Treatment of lymphoid malignancies in patients with ataxia-telangiectasia. *Med Pediatr Oncol.* 1998;31: 491-7.