

## Color Vision Outcome after Phacoemulsification with Intraocular Lens Implant in Patients with Diabetes Mellitus

Nimra Gul, Iqra Iqbal, Amna Farooq

### ABSTRACT

**Objective:** To determine the impaired color function in pseudophakic background diabetic retinopathy patient

**Methodology:** After the ethical approval from The University of Faisalabad under ethical approval number TUF/Dean//2019/39 the cross-sectional study was conducted in the Ophthalmology department of Madina Teaching Hospital Faisalabad which is associated hospital of the The University of Faisalabad. Fifty eight volunteers of both gender and age ranging between 35-75 years were studied through non-probability convenient sampling technique. Duration of study was September 2018 to February 2019. Visual acuity was tested from LCD Snellen at a 6 meter distance. Color vision was tested by conventional Farnsworth D15 test, along with slit-lamp and +70D lens to evaluate retinopathy severity, after proper consent of the patient. The test was performed after taking complete ocular, medical, surgical and drug history. Each pseudophakic eye was tested monocular and each subject was tested thrice.

**Results:** Results were analyzed using SPSS version 22. Significant association was seen between the color vision in pseudophakic diabetic patient with background retinopathy ( $p < 0.05$ ), using Pearson Chi-Square. Color vision by conventional D-15 showed mean of  $\pm 2.17$  and standard error of  $\pm 1.05$ . While pseudophakic group showed mean of  $\pm 1.05$  and standard error of  $\pm 0.116$ .

**Conclusion:** There is color defect in pseudophakic diabetic with background retinopathy. The dyschromatopsia is more in the blue axis. Color vision defect (CVD) seen more in uncontrolled diabetic than controlled. Color vision defect (CVD) increases with the course of retinopathy. Color vision checking must be made an integral part of examination specifically in diabetic retinopathy patient.

**KEYWORDS:** Color vision, Cataract, Diabetes mellitus, Diabetic retinopathy, Phacoemulsification, Intra ocular lens implant.

### INTRODUCTION

Diabetes mellitus (DM) is an important health problem that induces severe complications. Worldwide more than 285 million people are affected by diabetes mellitus.<sup>1</sup> Ocular problems of Diabetes mellitus are progressive and rapidly becoming the world's most major cause of morbidity.<sup>2</sup> subjects with diabetes mellitus are at risk of developing lens opacities and cataract with visual at earlier age as compare to subjects without diabetes.<sup>1</sup> Cataracts and diabetic retinopathy (DR) are the leading causes of acquired blindness worldwide.<sup>3</sup>

with IOL implant for cataracts caused by Diabetes mellitus. Surgical procedure for vision troubling cataracts caused by diabetes also increases the course of retinopathy for diabetics causing further difficulties.<sup>1</sup> It was evident that cataract extraction may possibly lead to a breakdown of the blood-retinal barrier and the blood-aqueous barrier and enhanced intraocular inflammatory response, all of which may result in the occurrence of DR in patients with diabetes.<sup>3</sup> Regarding vision function, previous studies have shown that contrast sensitivity, impaired color vision (ICV), multifocal visually evoked potential (mfVEP), and multifocal electroretinogram (mfERG) are affected by diabetes, both with and without DR.<sup>4</sup> Recent past study reported that 50% of the patients in the Early Treatment Diabetic Retinopathy Study had ICV with abnormal hue discrimination. Color vision testing provides an adequate and precise method through which

Nimra Gul OD; MPHIL  
The University of Faisalabad  
Iqra Iqbal BSOP; MPHIL  
Superior University, Faisalabad  
Amna Farooq BSEN, MPHIL  
Government College University

**Correspondence:**  
Nimra Gul  
E-Mail: nimra.gul@tuf.edu.pk

damage to the retina can be measure. Color vision is diagnostic tool of determine retinopathy severity.<sup>2</sup> Much of the color vision loss and increase in frequency of blue–yellow defects with age is attributable to changes in the color and clarity of the ocular media, and in particular, the lens of the eye.<sup>4</sup> Conflicting results has been reported by previous studies concerning the association of color visual impairment after phacoemulsification for cataracts in retinopathy. Some researcher found more ICV in pseudophakic patients’, on the other hand some demonstrated that older pseudophakic patients’ color vision resembles that of younger observers.<sup>4</sup> Diabetes induced microangiopathy leads to diabetic retinopathy (DR), cataract, glaucoma, nephropathy, and neuropathy.<sup>3</sup> The risk of retinopathy increases with the duration of diabetes. Factors that further increase the risk include: poorly controlled diabetes, high blood pressure, high cholesterol levels, and family history of severe diabetic retinopathy.<sup>4</sup> Diabetics have a higher incidence of visual function alterations depending on the severity of disease. The color vision defect often precedes the onset of retinopathy.<sup>5</sup> Advancing Age, macular edema, diabetic retinopathy or neovascularization contribute in ICV that may progress with progression of diabetic retinopathy.<sup>6</sup> Decline in color vision frequently produces changes in clinical measures like visual acuity.<sup>6</sup> Presence of maculopathy and the increased macular thickness in retinopathy may the results in deterioration of color vision and mostly tritan-like defect are common.<sup>7</sup>

Outcome after cataract surgery was reported to be worse in diabetic patients especially in those with diabetic retinopathy.<sup>8</sup> A high glucose concentration in the body also leads to the formation of cataract as the ocular complication by glycosylation and have been associated with impaired color vision (ICV).<sup>9</sup> ICV could affect daily routine activities including driving, education, occupation, discrimination, health and personal safety. That all will ultimately, would impact on their social role and quality of life.<sup>9</sup> There is limited studies that assess the color vision after phacoemulsification with IOL Diabetic retinopathy. The aim of this study was to determine the assess color function in

pseudophakic background diabetic retinopathy patient.

## METHODOLOGY

After the ethical approval from The University of Faisalabad under ethical approval number TUF/Dean//2019/39 the cross-sectional study was conducted in the Ophthalmology department of Madina Teaching Hospital Faisalabad which is associated hospital of the “The University of Faisalabad (TUF)”. A sample of 58 Patients both male and female was taken, using non-probability convenient sampling technique. Duration of study was September 2018 to February 2019. Best corrected V/A at least 6/12 was taken. All pseudophakic diabetic patients with background retinopathy were included. Both type 1 and type 2 diabetes were taken with age limit 30-75 years and Reliable systemic mental approach. While, any previous laser treatment, any ocular condition likely to change color vision like glaucoma or macular degeneration, any systemic disease other than diabetes, IOP above normal ranges, posterior capsule opacities (PCO), significant macular edema, Retinopathy classification done using ICDR classification Pre-proliferative retinopathy and Proliferative retinopathy were excluded. Color vision was determined by Farnsworth D15 test. During this test subjects were instructed to arrange 15 caps on the basis of hue, which were placed randomly on the white background while sitting at a testing distance of 50cm from caps, in a well-illuminated room. This test was performed both monocularly and binocularly and each subject was tested thrice. Slit-lamp and +70D lens were used to evaluate retinopathy severity after proper consent of the patient. The analysis was done by entering whole data into the software of SPSS version 20. Association between color vision defect and pseudophakic diabetic patient with background retinopathy was checked using Pearson Chi-Square for the association. Research was done after proper approval from ethical committee of institution

## RESULTS

The study was included 58 subjects consisting of 20 patients in Group 1 (Age 35 to 55 years) in

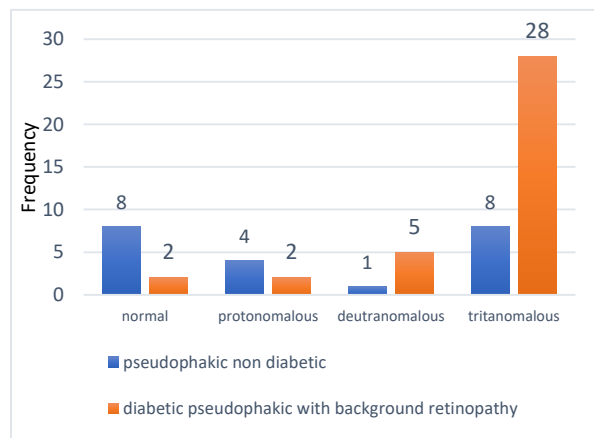
which there was 16 females and 4 males and Group 2 (Age 56 to 75 years) consist of total 38 patients in whom there were 22 males and 16 females. Trichromatic defect distribution was found by calculating the frequency out of total 58 subjects. The most present color defect was blue with percentage 61% while for red-green it was 10.2%.

Color vision by conventional D-15 showed mean of  $\pm 2.17$  and standard error of  $\pm 1.05$ . While pseudophakic group showed mean of  $\pm 1.05$  and standard error of  $\pm 0.116$ .

Chi\_square test was used to determine significance level between color-vision defect and pseudophakic diabetic with background retinopathy which showed p value 0.05 which is significant. This shows color vision decreases as diabetes gets sever. Patients having retinopathy found to have defected color vision in all three-axis red, green and blue. Color defect was found more in blue-axis in background retinopathy patients rather red-green.

Figure 1 depicts population with normal color vision, protanomalous, deuteranomalous, and tritanomalous while the pseudophakic diabetic with background retinopathy with blue color for its Presence and red for absence of retinopathy.

Figure 1: Bar graph showing color vision in pseudophakic background diabetic retinopathy

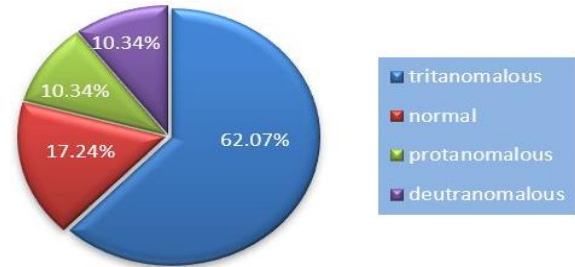


Age wise distribution of diabetes includes Group 1: 35-55 years contain 7 normal 3 type I diabetes and 10 type II diabetic subjects. Group 2: 56-75 years contain 14 normal, 10 type I and 14 type II diabetic subjects.

Figure 2 shows population in terms of percentage with non-diabetic in blue color as 36.21%, Type-

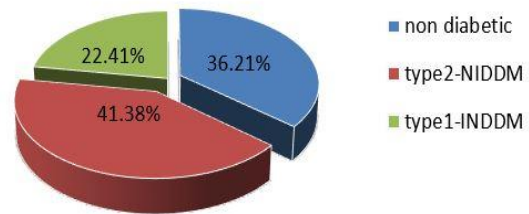
1 diabetic with green color as 22.41% and Type-2 diabetic in red color as 41.38% respectively. It shows that type 2 is more prevalent than type 1, where insufficient insulin is present in body to meet the needs of glucose metabolism

Figure 2: Pie chart of the frequency of the type of diabetes.



Color defect increases as course of diabetes increases. A tritanomalous as utmost prevalent color defect out of all color defects among pseudophakic population. Red-green color defects found mostly to be of genetic cause than acquired so clinically percentage found to be less than blue in pseudophakic diabetics with retinopathy. Figure 3 shows distribution of color defect.

Figure 3: Pie chart of the frequency of color vision defects



## DISCUSSION

Diabetic retinopathy (DR) remains the leading cause of legal blindness and moderate visual impairment and impaired color vision (ICV), among patients with diabetes. It was hypothesized by the previous studies that the formation of new vessels may not adequately supply oxygen for the metabolic needs of the photoreceptors, resulting in death of photoreceptors and hence affecting color vision.<sup>10</sup>

In this present study the main objective is to evaluate the color vision in pseudophakic diabetic with background retinopathy in age group 30-75.

Total 58 subjects were examined divided into two groups group 1 containing 30-55 with 20 observations and group 2 containing 56-75 years of age with 38 observations. A total of 26 males and 32 females both with type1 and type2 diabetes studied. Subjects were categorized as non-diabetic (n=21) type1 diabetic (n=13) and type2 diabetic (n= 24). Type 2 diabetes with 40.68% was more prevalent than type1 with 22.03%. Out of 58 subject's female having diabetes were more than males. Best corrected visual acuity up to 6/12 was taken the mean for visual acuity was 0.88. All the subjects with PCO and diabetic retinopathy except background stage and with clinically significant CMO were excluded.

Cause for the poorer chromatic vision following cataract surgery is additionally increased short-wavelength light transmission through intraocular lenses causing retinal damage. In present study it's found that color vision in diabetic pseudophakes was worse in those with background retinopathy for which P value found to be 0.05 showing significant association between color vision and background retinopath. Impairment of color vision found mostly along tritan axis especially for diabetics with retinopathy. The distribution of color defect was 16.9% normal color vision, 10.2% proton and deuteron defect and 61% tritan defect. Tritan discrimination sensitivity measurements considered to be as a way of selection for serious retinopathy. There are not enough diabetic pseudophakes with maculopathy and proliferative retinopathy to appear at the results of these conditions on tritan sensitivity. The principle for reduced chromatic vision in diabetic pseudophakes is additionally because of retinal damage by short-wavelength radiations (either from the light microscope or post-operatively). In phacoemulsification there is a shorter quantity once the retinal tissue is exposed to the radiation from the light microscope on removal of the lens. Previous study conducted to find color vision in pseudophakes diabetic and normal by Knowles and colleagues found that color vision decreases after cataract removal both in diabetic and non-diabetic but in diabetic the results are promising depending on severity of diabetes. Color discrimination sensitivity was found out in twenty-two diabetic pseudophakes with no retinopathy, twenty-three diabetic pseudophakes

with background retinopathy and thirty-four non-diabetic pseudophakes, all of whom had reasonable vision. In all three groups, red-green discrimination sensitivity was worse inside the pseudophakes (normal's,  $p < 0.001$ ; no retinopath,  $p = 0.467$ ; background retinopathy,  $p = 0.057$ ). All subjects had extracapsular cataract surgery or phacoemulsification with posterior chamber implants. Patients were examined for minimum of three months after cataract surgery. Subjects and controls were excluded if their vision was however 6/12, if that they'd had previous optical treatment.<sup>11</sup>

Previous study by Gella et al assessed color vision abnormalities in a cohort of subjects with type 2 diabetes mellitus using Farnsworth-Munsell 100 hue test.<sup>10</sup> They found higher proportions of color vision impairment in diabetic subjects with and without retinopathy. Most of the subjects were also found to have a blue-yellow color defect. Interestingly they reported more color impairment in the females as compared to men.<sup>10</sup> The error score was higher in subjects with diabetes having impaired color vision. Michael et al exemplified that with increasing age, yellow chromophores continuously accumulate inside the lens in nuclear cataract reducing the transmission of blue light to the retina, and resulting in blue-yellow color vision defects. Hence normal age-related color vision changes and those found in diabetic patients are predominantly deficient in the blue-yellow.<sup>12</sup> Ventruba et al. attributed abnormal color discrimination to a reduction in the transmission of light to the photoreceptors. They further explained that blue vision affect more rather than the red-green mechanism because of the lower density and number of blue cones in the fovea. Ventruba et al demonstrated color vision can significantly improve in subjects who underwent cataract surgery.<sup>13</sup> Our results disagree with Ventruba et al as we found more color vision impairment after IOL implantation. However, Gella et al reported, the presence of posterior subcapsular cataract and negative history of cataract surgery did not show significant association with ICV.<sup>10</sup> Similar to our results previous study performed by Radwan et al found Tritan deficiency most frequently in diabetic subjects with retinopathy. Aforementioned study also found Color deficiency

in the form of deutan and protan and combined color deficiency and total color blindness in few participants.<sup>7</sup> Results of fong et al are also in line with current results and found tritan-like visual defect in patients with diabetic retinopathy.<sup>14</sup> Lopez et al agree with our results and reported the alteration in Color vision in 67% of the patients with diabetes and commonest was tritan visual impairment.<sup>6</sup> Lopz et al did not found protan or deutan color deficiency in their participants.<sup>6</sup> Current study emphasizes that the impairment in color vision is frequently found in subjects with diabetes, so this aspect of visual impairment should also be considered and assessed great caution routine clinical examination.

## CONCLUSION

The present study was about to determine the impaired color function in pseudophakic background diabetics. It is suggested from the present study that color vision measurements identify a significant loss in performance in diabetic retinopathy group. This study indicates that cataract surgery in diabetics causes more loss of color function usually in tritan axis. Loss of color increases with course of retinopathy. The study emphasizes on making the color vision test an integral part of the examination for all the patients undergoing cataract surgery, especially in diabetics.

**Disclaimer:** There is no disclaimer.

**Conflict of interest:** None

**Funding disclosure:** None

## REFERENCES

1. Kelkar A, Kelkar J, Mehta H, Amoaku W. Cataract surgery in diabetes mellitus: A systematic review. *Indian J Ophthalmol.* 2018 ;66(10):1401-1410. doi: 10.4103/ijjo.IJO\_1158\_17
2. Vieira-Potter VJ, Karamichos D, Lee DJ. Ocular Complications of Diabetes and Therapeutic Approaches. *Biomed Res Int.* 2016; 2016:3801570. doi:10.1155-2016/3801570.
3. Tham Y, Liu L, Rim TH, et al. Association of Cataract Surgery With Risk of Diabetic Retinopathy Among Asian Participants in the Singapore Epidemiology of Eye Diseases Study. *JAMA Netw Open.* 2020;3(6): e208035. doi: 10.1001/jamanetworkopen.2020.8035
4. Wolff BE, Bearse MA Jr, Schneck ME, Dhamdhare K, Harrison WW, Barez S, et al . Color vision and neuroretinal function in diabetes. *Doc Ophthalmol.* 2015 ;130(2):131-9. doi: 10.1007/s10633-014-9476-4.
5. Kiziltoprak H, Tekin K, Inanc M, Goker YS. Cataract in diabetes mellitus. *World J Diabetes.* 2019 15;10(3):140-153. doi: 10.4239/wjd.v10.i3.140.
6. Lopez M, Martin R, Martinez R, Garcia J, Sanchez R, Lopez I, Garcia M, Mayo A, Pastor JC. What is the Cause of the Impaired Color Vision in Diabetic Patients? *Investigative Ophthalmology & Visual Science.* 2002 ;43(13):564.
7. Radwan TM, Ghoneim EM, Ghobashy WA, Orma AA. Assessment of Color Vision in Diabetic Patients. *International Journal of Ophthalmic Research* 2015;1(1):19-23 Available from: URL: [http:// www.ghrnet.org/index.php/ijor/article/view/1001](http://www.ghrnet.org/index.php/ijor/article/view/1001).
8. Ahmed F, Malik FI, Azmat CE, Gul A, Raza A. Visual Function Tests as cost Effective Screening Tools For Diabetic Retinopathy. *Pakistan Journal of Ophthalmology.* 2020 22;36(1).
9. Tan NC, Yip WF, Kallakuri S, Sankari U, Koh YLE. Factors associated with impaired color vision without retinopathy amongst people with type 2 diabetes mellitus: a cross-sectional study. *BMC Endocr Disord.* 2017 2;17(1):29. doi: 10.1186/s12902-017-0181-7.
10. Gella L, Raman R, Kulothungan V, Pal SS, Ganesan S, Srinivasan S, et al. Color vision abnormalities in type II diabetes: Sankara Nethralaya Diabetic Retinopathy Epidemiology and Molecular Genetics Study II report no 2. *Indian J Ophthalmol.* 2017 ;65(10):989-994. doi: 10.4103/ijjo.IJO\_601\_16.
11. Knowles PJ, Tregear SJ, Ripley LG, Casswell AG. Colour vision in diabetic and normal pseudophakes is worse than expected. *Eye.*1996 ;10(1):113-6. Doi 10.1038/i.1996.19.
12. Michael R, Bron AJ. The ageing lens and cataract: A model of normal and pathological ageing. *Philos Trans R Soc Lond B Biol Sci.* 2011; 366:1278–92.
13. Ventruba J. The influence of IOL implantation on visual acuity, contrast sensitivity and colour vision 2 and 4 months after cataract surgery. *Cesk Slov Oftalmol.* 2006;62:133–43
14. Fong DS, Barton FB, Bresnick GH, Early Treatment Diabetic Retinopathy Study Research Group. Impaired color vision associated with diabetic retinopathy: Early treatment diabetic retinopathy study report no. 15. *American journal of ophthalmology.*1999;128(5):612-617

***Authors' Contribution***

<b>Nimra Gul</b>	Study design, data collection, manuscript writing and data analysis
<b>Iqra Iqbal</b>	Study design Literature search, data collection, drafting
<b>Amna Farooq</b>	Study design, data collection, drafting, revised and approved
	All authors are equally accountable for accuracy, integrity of all aspects of the research work and approved the manuscript

---

Date of Submission: 06-12-2021  
Revised: 01-08-2022  
Accepted: 04-08-2022