



Evaluation of Hematological and Histopathological Effects of *Dennettia tripetala* Fruit Extract on Isoniazid-Induced Seizure in Wistar Rats

Finbarrs-Bello E.^{1*}, Odo C. E.¹ and Ojuolape S. G.^{1,2}

¹Department of Anatomy, Faculty of Basic Medical Sciences, Enugu State University of Science and Technology, Parklane, Enugu State, Nigeria.

²Department of Anatomy, Kampala International University, Western Campus, Ishaka-Bushenyi, Uganda.

Authors' contributions

This work was carried out in collaboration among all authors. Author FBE gave the concept, designed the study and did the acquisition of data. Author OCE analyzed and interpreted the data. Author OSG drafted the manuscript. All authors critical revised the manuscript for important intellectual content. All authors read and approved the final manuscript.

Article Information

Editor(s):

(1) Dr. Jaffu Othniel Chilongola, Tumaini University, Tanzania.

Reviewers:

(1) S. Danish Kadir, University of Pharmacy, Bangladesh.

(2) Atiq-ur-Rehman, The University of Lahore, Pakistan.

Complete Peer review History: <http://www.sdiarticle4.com/review-history/55832>

Received 27 January 2020

Accepted 02 April 2020

Published 07 April 2020

Original Research Article

ABSTRACT

Seizure is one of the neurological and episodic clinical challenges and, one underutilized option for medication-resistant in seizure is the use of medicinal plants. *Dennettia tripetala* has been found to possess anti-seizure effects. This study estimates the hematological parameters and examines the histopathological effect of ethanolic extract of *Dennettia tripetala* fruit on Isoniazid-induced seizure on the temporal lobe. Twenty-four (24) adult Wistar rats were randomized into six groups (1-6) of four rats each (n=4). The positive and negative control groups (group 1 and 2) received Isoniazid 300 mg/kg, i.p (inducing agent) and 1 ml, i.p normal saline (vehicle); while the rats in groups 3, 4, 5 and 6 were induced with 300 mg/kg of Isoniazid and treated with 250 mg/kg, 500 mg/kg and 750 mg/kg of the extract and 50 mg/kg of sodium valproate, o.p respectively. In the hematological study, the blood parameters RBC, PCV and HB decreased, while WBC remained normal and decrease eosinophils count was noted. Histopathological changes observed in the untreated seizure induced (positive control) group presented atrophied neurons, shrunken neurons,

coagulative necrosis and microcystic spaces. The extract treated groups exhibited dose dependent reduction in the above histopathological features as well as the sodium valproate standard drug group. This implies that, *Dennettia tripettala* fruit extract at high dose exerts hematotoxic effect, while neuroprotective effect was observed at low dose. In conclusion, it is safe and effective at low dosage.

Keywords: *Dennettia tripettala*; seizure; isoniazid; atrophy; hematotoxicity; neuroprotective.

ABBREVIATIONS

GABA: Gamma Amino-Butyric Acid; **PCV:** Packed Cell Volume; **HB:** Hemoglobin Concentration; **WBC:** White Blood Cell; **D.P.X:** Dibutylphthalate Polystyrene Xylene.

1. INTRODUCTION

Seizure is one of the most common neurological conditions in the world [1]. It has an estimated neuro-epidemiological index of at least 65 million people worldwide living with seizures with large proportion of sufferers' resident within the developing countries [2]. Its recognizable feature is an excessive neuronal activity in the cortical areas of the brain such as the frontal and temporal lobes [3]. The etiology/pathogenesis is traceable to several factors including: Brain damage (traumatic brain injury, stroke, brain tumors), infections scarring (gliosis), hypoxia, severe hypoglycemia, very high fever and abnormal electrical activity in the brain [4]. Sometimes, it could be initiated by drug related adverse reaction or overdose, in the case with Isoniazid [5]. Primarily, there is loss of gamma amino-butyric acid (GABA) mediated inhibitory interneurons and increased hyper excitability of the neurons leading to recurrent seizure episodes [5,6].

Isoniazid is one of the most commonly prescribed tuberculosis chemotherapy regimens [7]. Isoniazid overdose is known to causes recurrent seizures, profound metabolic acidosis, coma and even death [7]. The Isoniazid-induced seizure represents a pathophysiological state of decrease availability of gamma aminobutyric acid (inhibitory neurotransmitter) and increase the level of glutamate (excitatory neurotransmitter) in the affected brain areas [8]. This dysfunctional milieu disrupts the glutamate and gamma aminobutyric acid balance which consequently leads to excessive excitatory signals in the brain and altered brain electroencephalography wave patterns [9].

Conventional anticonvulsants are the typical pharmacotherapy used for seizure which target different membrane channels, receptors and neurotransmitters in the brain. Sodium valproate

as an anticonvulsant, acts via the voltage dependent sodium channels blockage and inhibition of gamma-aminobutyric acid transaminase with increases brain levels of GABA [10]. The increase in the turnover of gamma-aminobutyric acid (GABA) potentiates a GABAergic function which is able to be in control of seizure generation and propagation [11]. But, the refractory rate of sodium valproate is high, coupled to incidence of side effect and inadequate of curative potential.

Pepper fruit botanically known as *Dennettia tripetala* of family *annonaceae*, is known with local names as: ako in Edo, opipi in Idoma, nkarika in Ibibio, mmimi in Igbo and *ata igbere* in Yoruba language. *D. tripetala* is a well-known medicinal in the southern parts of Nigeria and consumed due to the spicy taste of the fruit and leaf [5,12]. Phytochemical screening of the ethanolic extract showed the presences of tannins, alkaloids, steroids, flavonoids, cardiac glycosides, saponins, and terpenoids. It also contains antioxidant vitamins C and E, as well as the B group of vitamins B1, B6, B9 and B12 [5,13], which provides a scientific basis for the use of *D. tripetala* in traditional medicine. Previous studies also documented its hypnotic, anticonvulsant, and anxiolytic effects in mice and rats [5,14].

Most synthetic anticonvulsants including sodium valproate had been found to have adverse effects on the on the targeted organs. Furthermore, about 30% of patients with epilepsy have seizures that do not react adequately to conventional antiepileptic drugs [11]. These restrictions with conventional antiepileptic drugs showcases the need to seek new drugs that could be more efficacious as the action of conventional antiepileptic drugs, with less side effects so as to achieve a better treatment outcome for seizures. This therefore calls the need to seek for an effective herbal medicine for

seizure that can possibly offer the required opportunities for the isolation of important compounds which can be used in the development of better, affordable and well tolerated antiepileptic drugs. Thus, the ineffectiveness of these synthetic drugs, along with their serious side effects makes any safe and effective herbal medicine an attractive possibility. Therefore, this work investigates the effect of the ethanolic extract of *D. tripetala* fruits on the isoniazid induced seizure on the hematological parameters and temporal lobe histology. It showcases the comparative therapeutic potentials of *D. tripetala* extract and sodium valproate. This knowledge can be used by pharmaceutical industries to produce cheaper and less toxic drug for the populace or serve as an alternative for seizure therapy.



Dennettia tripetala fruits

2. MATERIALS AND METHODS

2.1 Plant Collection, Identification and Preparation

Fresh samples of *D. tripetala* fruit were harvested from farmlands, in Igbo-Eze-South local Government Area of Enugu State Nigeria. The fruits were identification and authentication by plant curator in the Department of Plant Science and Biotechnology of the University Nigeria Nsukka. The fruits were selected of impurities, washed and air dried for 7 days. The dried fruits were pulverized into powdered form; 863.54 g of the powder was soaked in 2.2 litre of 90% ethanol and allowed to stand for 48 hours with intermittent stirring. Thereafter, the mixture was filtered with a meshwork and what-man paper No 1. The filtrate was left in an open space for ethanol to evaporate and form paste with percentage yield of 4.26%. It was stored in a refrigerator at 4°C and constituted to desired volume when required.

2.2 Drugs and Chemicals

Isoniazid (Isonamede India, PubChem ID: 3767) was procured from a registered pharmaceutical store and the stock solution of INH was prepared by dissolving 300mg of the tablets in 10 ml of distilled water at room temperature.

2.3 Experimental Animal and Ethical Approval

Twenty four (24) wistar rats were obtained from the animal house of the Zoology Department of University of Nigeria, Nsukka. The rat were housed at the animal facility of ESUT College of Medicine where the study was conducted, acclimatized for two weeks with free access to food and water, under light and dark phase of 12 hours within 24 hours at a room temperature during the period of the experiment [15]. Thereafter, the rats were randomized into six groups of four (4) rats' per-cage.

2.4 Experimental Design

Group 1 (Positive control): 300 mg/kg of Isoniazid (single dose, i.p).

Group 2 (Negative control): 0.1 ml normal saline (vehicle, i.p).

Group 3 (Low dose treatment): 300 mg/kg of Isoniazid (single dose, i.p) and 250 mg/kg of extract, p.o.

Group 4 (Medium dose treatment): 300 mg/kg of Isoniazid (single dose, i.p) and 500 mg/kg of extract, p.o.

Group 5 (High dose treatment): 300 mg/kg of Isoniazid (single dose, i.p) and 750 mg/kg of extract, p.o.

Group 6 (standard treatment): 300 mg/kg of Isoniazid (single dose, i.p) and 50 mg/kg, p.o of sodium valproate.

2.5 Haematological Study

The rats were anesthetised by xylazine and ketamine (v/v); 2 ml blood samples was collected via the retro-orbital vessels from each rat into heparinized tubes and immediately used for the determination of RBC, PVC, HB, WBC the leucocytes differential counts. Total red blood cell (RBC) and white blood cell (WBC) counts were estimated using the visual method. The percentage packed cell volume (PCV) and blood

hemoglobin concentrations (HB) and Leucocytes differential counts of all samples were estimated as specified the physiology practical manual for ESUT college of medicine. The film were evenlycovered with leishmans' stain and after 2 minutes by means of a clean pipette an equal quantity of water added, mixedand allowed to stand for 10 minutes. The mixture was poured off and the film was washed in a gentle stream of water, dried with filter paper andexamined under a high power microscope; the different types of white cells (leucocytes) were systematically counted and categorized until a total of 100 white cells have been counted.

2.6 Histological Studies

The brain tissues were harvested at the end of blood sample collection and fixed in 10% neutral

formal saline for 48 hrs, afterwards the temporal lobes were dissected and processed manually for paraffin wax embedding, sections of 5 um thickness were obtained using the rotary microtomy, deparaffinized sections were stained using hematoxylin and eosin (Hand E). The stained sections were then dried and mounted in Dibutylphthalate Polystyrene Xylene (D.P.X), micrographed and interpreted.

2.7 Statistical Analysis

Data was analyzed by one way analysis of variance (ANOVA) using the Statistical Package for Social Sciences (SPSS version 21) for windows (SPSS Inc., Chicago, USA). The results were presented as mean ± standard deviation (SD). Statistical significance was considered at P=.05.

3. RESULTS

Hematological findings:

Table 1. Effect of ethanolic extract of *Dennettia tripetala* on RBC, PCV and HB on seizure model

Test group	RBC count	PCV %	HB g/dl
Isoniazid (300 mg/kg)	5.80±0.75	44.50±2.65	14.83±0.88
Normal saline	5.00±0.82	39.75±5.56	13.25±1.86
250 mg/kg extract & 300 mg/kg Isoniazid	4.64±0.56*	38.25±5.06	12.53±1.82
500 mg/Kg Extract& 300 mg/kg Isoniazid	4.39±0.47	36.75±4.11*	11.95±1.45*
750 mg/kg Extract& 300 mg/kg Isoniazid	6.00±0.00	50.00±0.00	16.70±0.00
50 mg/kg Sodium Valproate & 300 mg/kg Isoniazid	2.00±0.14	47.25±2.06	16.07±0.70

Key: *P=.05, when compared with group 1. a P=.05RBC counts showed statistically significant decrease in group 3(P=.05), non-significant decrease were also observed in groups 3 and 4. PCV and HB also showed a statistical significant decrease (P=.05) in group 4 when compared with group 1, while only group 6 showed a significant increase in HB (P=.05) when compared with group 2

Table 2. Effect of ethanolic extract of *Dennettia tripetala* on total WBC and differential counts on test groups

Test groups	TWBC count	Neutrophils %	Lymphocytes %	Monocytes %	Eosinophils %	Basophils %
Isoniazid (300 mg/kg)	6.28±3.96	51.75±7.68	41.75±8.66	3.50±0.58	2.25±0.50	0.75±0.50
Normal saline	3.23±1.45	58.50±7.51	34.75±8.96	3.75±0.96	2.50±0.58	0.50±0.58
250 mg/kg extract & 300 mg/kg isoniazid	3.33±0.48	48.25±13.72	46.75±12.37	3.75±1.50	1.25±0.50	0.00±0.00
500 mg/kg extract & 300 mg/kg Isoniazid	3.68±0.76	55.25±14.36	41.25±13.94	2.75±0.96	0.75±0.96*	0.00±0.00
750 mg/kg extract & 300 mg/kg Isoniazid	4.60±0.00	37.00±0.00	60.00±0.00	3.00±0.00	0.00±0.00	0.00±0.00
50 mg/kg valproate & 300 mg/kg Isoniazid	8.30±0.50	66.00±3.65	30.50±5.74	0.25±0.50	0.50±0.58*	0.00±0.00

Key:*(P=.05) No significant effect on the WBC across the groups , for differential leucocytes counts only eosinophil count was significantly(P=.05) decreased in groups 3, 4 and 6 which represents the low , medium dose of the extract and standard drug the sodium valproate respectively

Histological Observations:

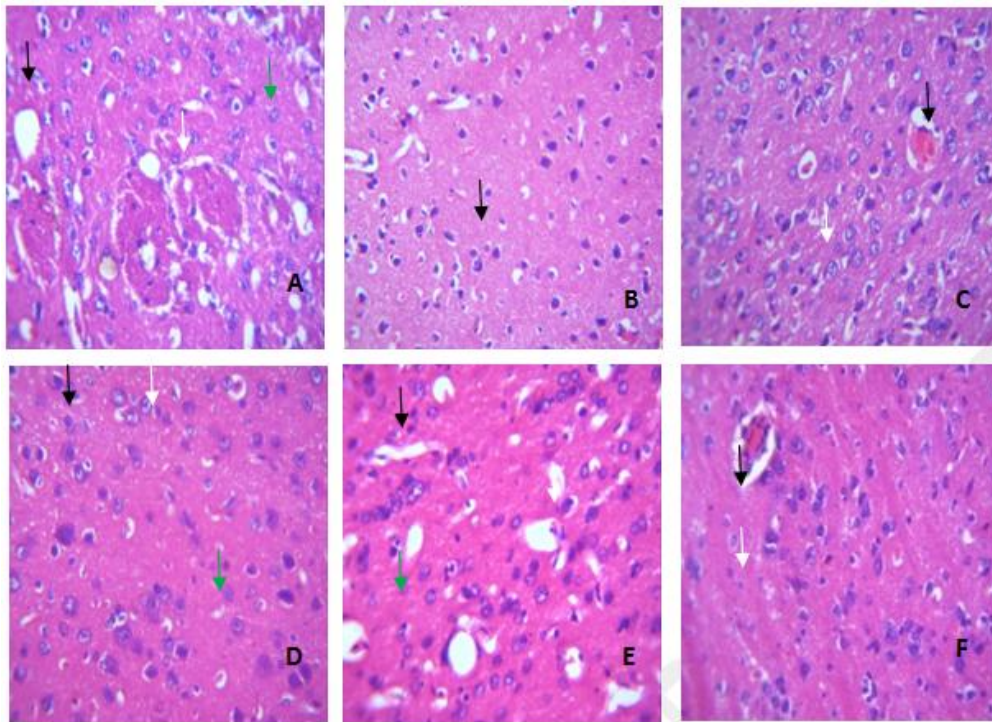


Fig. 1. Photomicrograph of temporal lobe (A) positive control (Isoniazid 300 mg/kg) coagulative necrosis (white arrow), microcystic space (black arrow), neurons atrophy (green arrow) and shrinking neurons (SN). (B) Negative control (1 ml normal saline) normal neuronal cell (black arrow). (C) 250 mg/kg of *D. tripetala* and 300 mg/kg of Isoniazid, few atrophic neurons (white arrow) and intracytoplasmic inclusion (black arrow). (D) 500 mg of *D. tripetala* and Isoniazid 300 mg/kg, few atrophic neurons (green arrow), intracytoplasmic inclusion (black arrow) and shrinking neurons (white arrow). (E) 750 mg/kg and Isoniazid reduced microcystic space (black arrow), atrophic neurons (green arrow) and mild shrinking neurons (white arrow). (F) Sodium valproate treated large nuclei and basophilic inclusions (black arrow) with few atrophic neurons (white arrow). H&E. x400

4. DISCUSSION

Hematological assessment is vital in the evaluation of causes, effect of treatments and recovery in most illnesses. Thus, the total blood parameter testing is carried out on seizure patients to access the overall health and identify their likely conditions such as; infections and anemia that might trigger seizure, and to monitor the possible occurrence of medication-induced side effects [16]. In this study, we evaluated the hematologic parameters and found that the RBC counts was significantly decreased in the low extract group ($p < 0.05$), following the seizure induction by Isoniazid, while the diseased observed in the rest groups was insignificant. In a similar study, Daniel and Clement [17] earlier reported decrease in RBC counts with the *D. tripetala* fruit in the absence of seizure in rats.

The role of the extract on the RBC is primarily due to the presence of certain phytochemical constituent like alkaloids. Although, secondary effect of direct bone marrow suppression might also be attributed to the effect on RBC count in the case of sodium valproate, For example, the aplastic anemia and peripheral cytopenia could explain the characterised hematologic toxicity associated with sodium valproate [18,19].

Conversely, PCV and blood HB counts showed insignificant decreases in the treated model (Table 1). A direct modulatory relationship exists between RBC, PCV and HB concentration physiologically, therefore, an alteration in one parameter alternately impact another. Hence, the importance of evaluating blood parameters while on certain medications such as herbal and anticonvulsants. Hematotoxic effect has also

been reported on Isoniazid overdose which might have interplayed to cause further disease in the treatment groups.

The lack of statistical evidence on the effect of the total white blood count possesses a question of whether this suggests that the extract exhibited a protective effect or the harmful effect of Isoniazid. This is not likely the case with sodium valproate which has been shown to suppress leucocytosis, induce thrombocytopenia and agranulocytosis [18]. Sodium valproate group showed a significant increase compared with negative control (Table 2), This may be a representation of a normal physiological response of the body which triggers the migration of WBC to defend the RBC against hemolysis, Eosinophil counts decreased in the in sodium valproate, the low and medium dose of the extract. This effect might be attributed to the phytochemical components of the extracts and the valproate could be related to its effect on the hematopoietic stem cells.

Consistently, loss of neurons has been a histopathological feature associated with focal temporal seizure particularly in humans [20]. The positive control or non treated seizure group (Fig. 1a) revealed characteristic features of the neuronal degenerative changes: atrophied and shrunken neurons, coagulative necrosis and microcystic spaces. These can be attributed to the acute neurotoxic effect of the high dose of Isoniazid (INH). The atrophied neurons observed in the non treated seizure group were reduced following extract treatments with varying doses. Thus, the extract exhibited dose dependant effect, its low to medium dosages displayed potent property while the high dose could be toxic. In this regards, only the low and medium dose of the extract could be comparable to sodium valproate treatment. This implies the extract exerts similar activity as the standard drug sodium valproate by providing some measures of neuroprotective effects on the temporal lobe histology. Furthermore, Isoniazid toxicity is refractory to anticonvulsant and responsive to treatment with high dose of pyridoxine (vitamin B6) as demonstrated in our previous studies on the anticonvulsant effect of this extract [5]. However, the study is a pointer to the fact that *D. tripetala* fruit extract has promising potential in the search for an entity with anti-seizure activity but this might require further studies on the fractionated components or the isolated compound.

5. CONCLUSION

The *D. tripetala* extract has dose dependant effects on the seizure model (both hematologically and histologically) of the temporal lobe compare to sodium valproate.

CONSENT

It is not applicable.

ETHICAL APPROVAL

The study protocol was reviewed and approved by the ESUCOM animal research committee. Animals were cared for in accordance with the institutional and international guidelines.

ACKNOWLEDGEMENT

The authors would like to thank the staff of the physiology and histology laboratories for the technical assistance.

COMPETING INTERESTS

Authors have declared that no competing interests exist.

REFERENCES

1. WHO. Epilepsy care in the world. Geneva; World Health Organization. 2005;8-16.
2. Nwani PO, Nwosu MC, Asomugha LA, Enwereji KO, Arinzechi EO, Ogunniyi AO. Epidemiology of active epilepsy in a suburban community in Southeast Nigeria: A door-to-door survey. Nigeria Journal of Clinical Practice. 2015;18(4):527-533.
3. Fisher R, Van-Emde BW, Blume W, Elger C, Genton P, Lee P, Engel J. Epileptic seizures and epilepsy: Definitions proposed by the International League Against Epilepsy (ILAE) and the International Bureau for Epilepsy (IBE). Epilepsia. 2005;46(4):470-472.
4. Athanassios V, John EG, Dimitrios N. Risk factors associated with epilepsy: Case study-control study. Health Science Journal. 2012;6(3):509-517.
5. Elizabeth FB, Ignatius IO, Samsudeen GO, Abonyi EO. Antioxidant and anticonvulsant effect of *Dennettia tripetala* on rat model of Isoniazid-induced seizure. European

- Journal of Medicinal Plants. 2019;30(2):1-10.
6. Bertram GK, Serzan BM, Anthony JT. Sedative-Hypnotic drugs: Basic and clinical pharmacology. 11th International Ed, McGraw Hill Companies Inc. Singapore. 2009;371-509.
 7. Puri MM, Lokender K, Vishwakarma PD, Behera D. Seizures with single therapeutic dose of isoniazid. Indian Journal of Tuberculosis. 2012;59:100-102.
 8. Tuba Şafak, Ali EK, Şeref KC, Yunusur C. What is the cause of seizure: Isoniazid poisoning or epidural hematoma? A case report. JEMCR. 2015;1:3-5.
 9. Tuba Şafak, Ali EK, Şeref KC, Yunusur C. What is the cause of seizure: Isoniazid poisoning or epidural hematoma? A case report. JEMCR. 2015;1:3-5.
 10. Treiman DM. GABAergic mechanism in epilepsy. Epilepsia. 2001;42(3):8-12.
 11. Vinay K, Sandeep KS, Nagarajan K, Praveen KD. Effects of lycopene and sodium valproate on pentylenetetrazol-induced kindling in mice. Iranian Journal of Medical Sciences. 2016;41(5):430-36.
 12. Egharevba HO, Idah EA. Major compounds from the essential oil of the fruit and comparative phytochemical studies of the fruits and leaves of *Dennettia tripetala* Barker F. found in North Central Nigeria. International Journal of Pharmacognosy and Phytochemical Research. 2015;7(6):1262-1266.
 13. Sylvia OI. A review of the uses and medicinal properties of *Dennettia tripetala* (Pepper fruit). Medical Sciences. 2015;3(4):104-111.
 14. Oyemitan IA, Iwalewa EO, Akanmu MA, Olugbade TA. Antinociceptive and anti-inflammatory effects of essential oil of *Dennettia tripetala* G. Baker (Annonaceae) in rodents. Afric. J. Tradit. Complement. Altern. Med. 2008;5:355-362.
 15. ESUT College of Medicine. Manual for practical physiology. Teamwork Publications Int'l Ltd. Enugu. 2016;65-67.
 16. Nass RD, Sassen R, Elger CE, Surges R. The role of postictal laboratory blood analyses in the diagnosis and prognosis of seizures. Seizure. 2017;47:51-65.
 17. Daniel EI, Clement ON. Effect of ethanolic extract of *Dennettia tripetala* fruit on haematological parameters in albino wistar rat. Nigerian Journal of Physiological Sciences. 2008;23(1-2):13-17.
 18. Acharya S, Bussel JB. Heamtologic toxicity of sodium valproate. Journal of Pediatric Hematology and Oncology. 2000;22(1):62-65.
 19. Kaipainen P, Westermarck T, Atroshi F, Kaski M, Iivanainen M. Clinical and hematological profiles during valproate treatment of epileptic patients with intellectual disability-case study and mini review. Provisional Chapter; Intech Open Science. 2014;1-10.
 20. Ingmar B, Roberto S, Gernil H, Rolan C, Katja K, Christian C, et al. Histopathological findings in brain tissue obtained during epilepsy surgery. N. Engl. J. Med. 2017;377:1648-1655.

© 2020 Finbarrs-Bello et al.; This is an Open Access article distributed under the terms of the Creative Commons Attribution License (<http://creativecommons.org/licenses/by/4.0>), which permits unrestricted use, distribution, and reproduction in any medium, provided the original work is properly cited.

Peer-review history:

The peer review history for this paper can be accessed here:
<http://www.sdiarticle4.com/review-history/55832>