



## **A Case of Furuncular Myiasis Due to *Cordylobia anthropophaga* in Infant in Makkah, Saudi Arabia**

**Raafat A. Hassanein<sup>1,2\*</sup>, Amal M. Almatary<sup>3,4</sup> and Mohammad O. Alkurbi<sup>1</sup>**

<sup>1</sup>Department of Laboratory Medicine, Faculty of Applied Medical Sciences, Umm Al-Qura University, Saudi Arabia.

<sup>2</sup>Department of Zoonoses, Faculty of Veterinary Medicine, Assiut University, Assiut, Egypt.

<sup>3</sup>Parasitology Unit, Maternity and Children Hospital, Makkah, Saudi Arabia.

<sup>4</sup>Department of Parasitology, Faculty of Medicine, Assiut University, Egypt.

### **Authors' contributions**

This work was carried out in collaboration among all authors. Author RAH designed the study, wrote the protocol and wrote the first draft of the manuscript. Authors AMA and MOA managed the analyses of the study. Author MOA managed the literature searches. All authors read and approved the final manuscript.

### **Article Information**

#### Editor(s):

(1) Cynthia Aracely Alvizo Báez, Autonomous University of Nuevo Leon, Mexico.

#### Reviewers:

(1) S. K. Kuria, Walter Sisulu University, South Africa.

(2) Papa Kofi Amissah-Reynolds, University of Education, Winneba, Ghana.

Complete Peer review History: <http://www.sdiarticle4.com/review-history/56084>

**Case Study**

**Received 02 February 2020**

**Accepted 09 April 2020**

**Published 14 April 2020**

### **ABSTRACT**

The cutaneous myiasis has been rarely reported in Saudi Arabia. We intended to describe here a case of furuncular cutaneous myiasis caused by *Cordylobia anthropophaga* larvae in infant from south area in Makkah, Saudi Arabia. A female infant, 17-day-old, had lived with her family in area closed to animal houses. Physical examinations showed 2 tender erythematous nodules with small central ulceration on the infant back and hand. During investigation, 2 larvae came out from the lesion. *C. anthropophaga* was identified by paired mouth hooks (toothed, spade-like, oral hooks) and 2 posterior spiracles, which lack a distinct chitinous rim. Although rarely described in Saudi Arabia until now, cutaneous myiasis should be expected in people living nearby such livestock, with flies and poor hygienic conditions.

**Keywords:** *Cordylobia anthropophagi*; cutaneous; myiasis; furuncular myiasis; Saudi Arabia.

## 1. INTRODUCTION

Myiasis is defined as the infestation of live human and vertebrate animals with dipterous larvae, which, at least for a certain period, feed on the host's dead or living tissue, liquid body-substances, or ingested food. It can involve cutaneous, enteric, ophthalmic, nasopharyngeal, auricular, and urogenital systems by larvae of the order of Diptera (true flies). It is widespread in tropical and subtropical areas, including Central America, South America, and tropical Africa [1,2]. In addition, myiasis is continuously recorded throughout the world due to travelers returning from endemic areas. It has been reported in several countries, including France [3] China [4], US [5], Japan [6], Saudi Arabia [7,8].

The cutaneous myiasis is the most frequent and impressive form and it can be divided into 3 types by clinical features and type of larvae: furuncular, creeping (migratory) and wound (traumatic) myiasis [9].

Furuncular myiasis is defined as the penetration of the larvae inside the healthy skin and development of a boil-like nodule. It is more common in tropical countries and can be caused by *Dermatobia hominis*, *C. anthropophaga*, *Cuterebra* sp. and *Wohlfahrtia vigil* [10,11,12,13,14].

*Gasterophilus* and *Hypoderma* are two flies that produce a creeping myiasis. Flies that cause wound myiasis include screwworm flies such as *Cochliomyia hominivorax* and *Chrysomya bezziana*, and *Wohlfahrtia magnifica* [9].

The human botfly, *Dermatobia hominis* (Linnaeus, 1781), causes obligatory myiasis and this parasite depends on the host to complete its life cycle [15]. Humans can be infested through direct exposure to environments contaminated with eggs of the fly [16].

In this study, we present the case of furuncular myiasis in an infant living with her family nearby livestock's area, with flies and poor hygienic conditions south of Makkah, KSA. The larva was removed from a boil-like lesion of infant back and hand and identified as *C. anthropophaga* from morphology.

## 2. CASE REPORT

A 17-day-old female infant presented to pediatric department at Maternity and Children hospital,

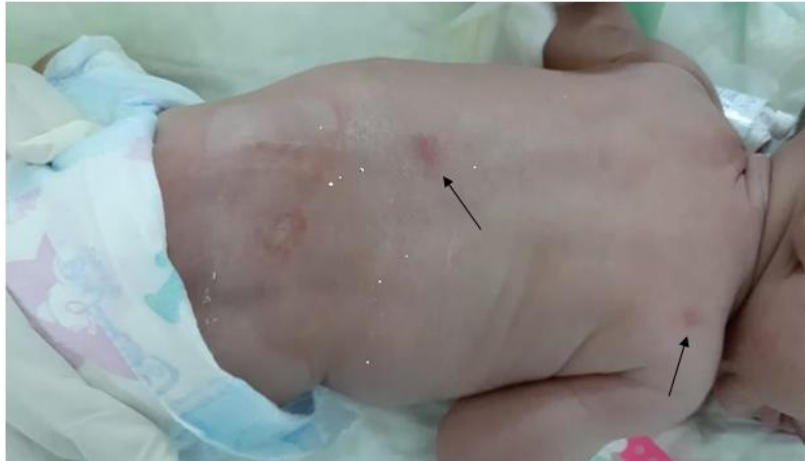Makkah, Saudi Arabia on 10 February 2020, with 1-week history of 5 painful erythematous nodules boil-like lesions with a small central punctum appeared on her back and developed as an abscess on the back and hand (Fig. 1). A third instar larva 8x3 mm in size (Fig. 2), yellowish color with cylindrical body was removed from two of the lesions and identified in the parasitology unit, Maternity and Children Hospital.

The larvae were first washed in distilled water and then cleared in 10% sodium hydroxide (NaOH) solution for 1 h. The larvae were washed again in distilled water, transferred to 10% acetic acid for 30 min and washed again in distilled water. The specimens were then dehydrated in ascending series of ethanol (30%, 50%, 70% and 90%) for 30 min each. The larvae were then soaked in absolute alcohol for at least 1 h and then transferred into Xylene for one hour. At this stage, all the internal organs of the maggot were removed and the posterior spiracles were cut transversely, also the anterior end cut transversely and the medium portion longitudinally, then specimens were mounted onto a glass slide using DPX and left to dry to the next day. The slides were examined under a light microscope for taxonomy studies and identification [17].

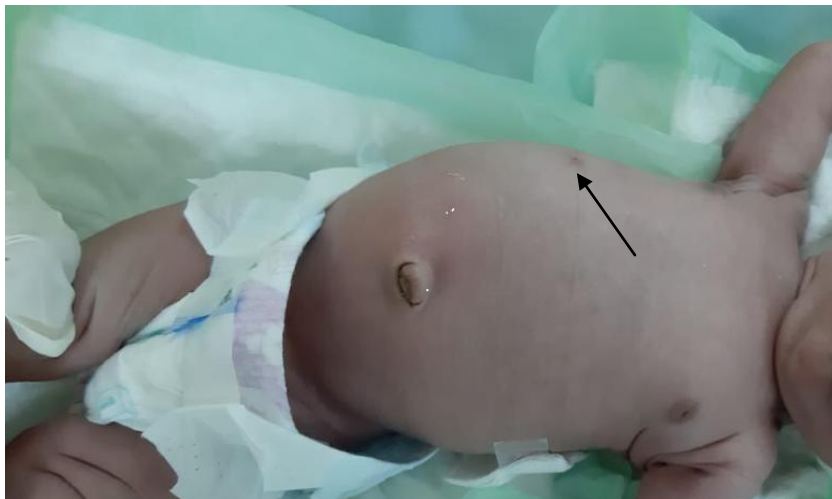The morphology of the larvae body was almost completely covered by conic small black, scattered spines with a brown apex, pointing towards the posterior end (Fig. 3). Two copper-colored posterior spiracles, each bearing 3 sinuous spiracular slits which lack a distinct chitinous rim (Fig. 4). In the anterior end of larva, the mouth with a pair of spade-like stout hooks with curved and sharp tips without cluster of conic denticles and anterior spiracles were characteristically observed (Fig. 5). These morphological characteristics were consistent with those described for *C. anthropophaga* [18].

Laboratory tests demonstrated high monocytes  $2.54 \times 10^3/\text{UI}$ , high eosinophils  $1.40 \times 10^3/\text{UI}$ , high Mean Corpuscular Haemoglobin 33.1 pg, high Bilirubin (5.1  $\mu\text{mol/L}$ ), high potassium-k (5.7 mmol/L), high creatinine (41.0  $\mu\text{mol/L}$ ), high calcium (2.8 mmol/L), low SGOT/AST (30) indicating renal impairment.

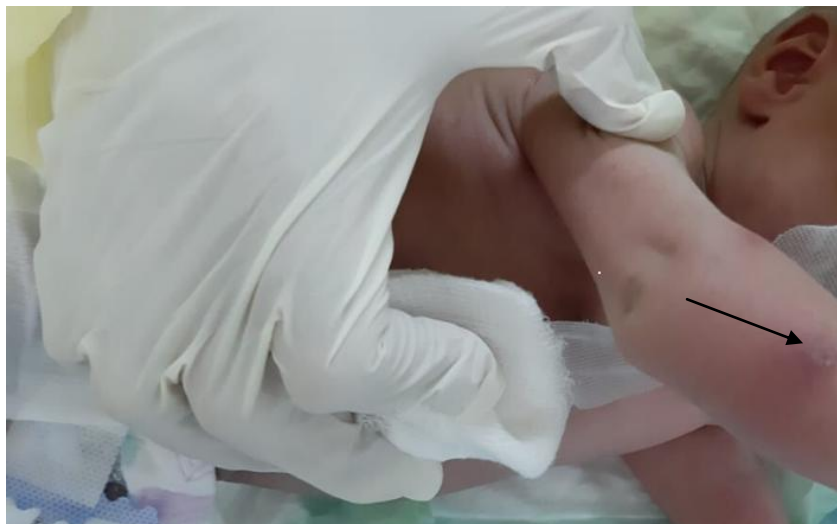Skin lesions were markedly improved after the remove of larvae and 2-week antibiotic treatment, and there was no recurrence.



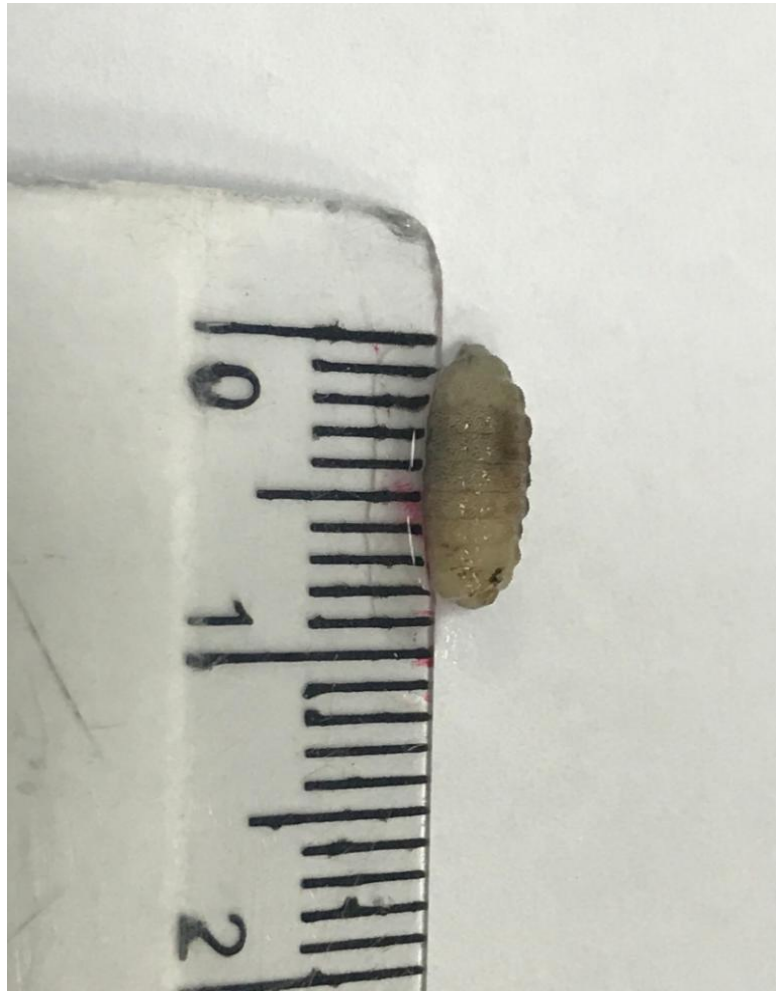
**Fig. 1A.** Boil-like lesions caused by *Cordylobia anthropophaga* on the back of the patient



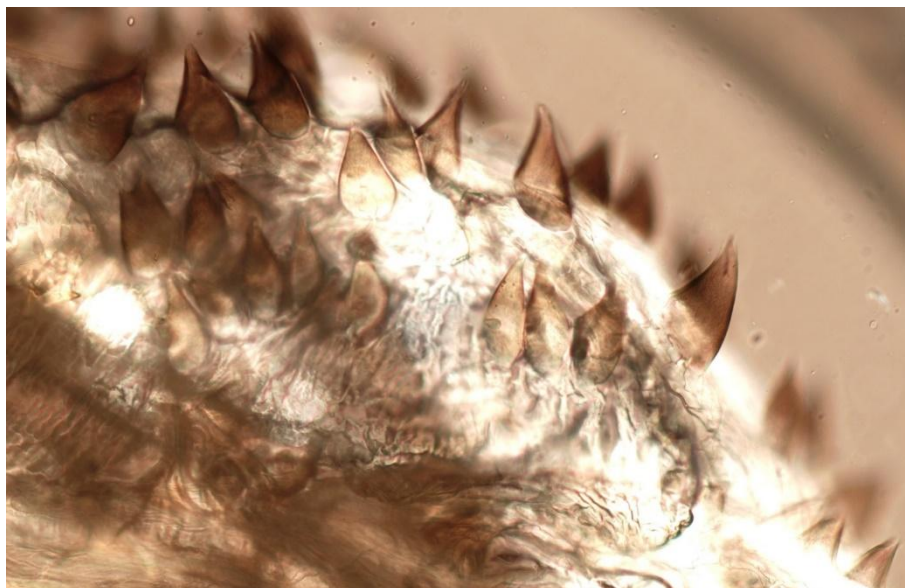
**Fig. 1B.** Boil-like lesions caused by *Cordylobia anthropophaga* on the abdomen of the patient



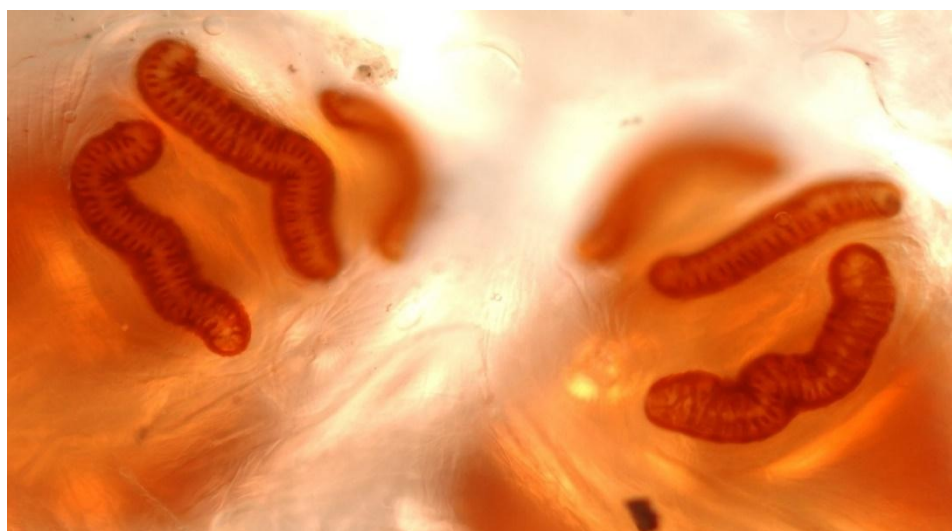**Fig. 1C.** Boil-like lesions caused by *Cordylobia anthropophaga* on the hand of the patient




**Fig. 2. Barrel-shaped larvae were about 8 mm in length and 4 mm in width**



**Fig. 3. Conic spines on the body with a brown apex, pointing towards the posterior end (magnification 20X)**



**Fig. 4. Two copper-colored posterior spiracles, each carrying 3 sinuous spiracular slits which lack a distinct chitinous rim (magnification 20X)**



**Fig. 5. Anterior end of *C. anthropophaga* showing paired mouth hooks (toothed, spade-like, oral hook) protruded ventrally from anterior 2 black mouth-hooks (magnification 20X)**

### 3. DISCUSSION

The definitive study on the Tumbu fly (*C. anthropophaga*) was carried out in Sierra Leone in 1923 [10]. In Africa, furuncular myiasis is caused by 3 species of the genus *Cordylobia*: *C. anthropophaga* (endemic throughout Africa), *C. rodhaini* (parts of Africa with rainforests) and *C. ruandae* (Zaire border and Rwanda), whereas *D. hominisis* common in Central and South America [3]. Among *Cordylobia* spp.,

*C. anthropophaga* is the dominant causative agent compared with the other species [19].

The larvae can penetrate the unbroken skin of the host, who is usually lying on the ground or by the contaminated clothes. Interestingly, the host usually feels no symptoms at the time of skin penetration by larvae. Therefore, most patients do not think maggots as a cause of their skin problems. Within 1 to 2 weeks, the larvae develop into the second and third instars and the

8x3mm sized mature larvae that can emerge from the central pore of the skin lesions [20].

In this report, morphological characteristics of larvae of *C. anthropophaga* (ex, a pair of spade-like hooks, anterior spiracles, and posterior spiracles) are well observed in Figs. 3, 4 and 5. These morphological characteristics were consistent with those described for *C. anthropophaga* [4,13,14,18]. In the posterior spiracles, the 3 spiracular openings are slightly sinuous slits in *C. anthropophaga*, whereas tortuously sinuous in *C. rodhaini*. *C. anthropophaga* has mouth hooks with curved and sharp tips, but there is neither cluster of conic denticles nor oral grooves. On the other hand, *C. rodhaini* has mouth-hooks with broad and rounded tips and cluster of conic denticles as typical feature.

Therefore, sufficient knowledge and experience for diagnosis is needed to avoid misdiagnosis, such as pyoderma, impetigo, staphylococcal furunculosis, and cutaneous leishmaniasis [1].

Early lesions may resemble other reactions due to insect bite, but furuncular lesions with an intense inflammatory reaction in the surrounding tissue rapidly develop [20,21].

Myiasis has a greater economic impact as an infestation of animals than of humans; there are no species of Diptera which are restricted to humans for their development but there are many that have a very restricted host range on animals [22,23].

The infestation for our case may be occurs through a fly itself where the infant family lived near animal houses such as sheep, horses and cattle in south area in Makkah (Malikan area), Saudi Arabia. This case report again highlights this disease should be expected in people living nearby such livestock, with flies and poor hygienic conditions. These people should be taught hygienic practices and methods to control fly population.

The "tumbu fly", *C. anthropophaga*, is an agent of obligatory cutaneous (furuncular) myiasis, widely distributed in the sub-Saharan region [24], although at least one autochthonous case has been recently reported in Saudi Arabia [25]. This species, with rodents as natural hosts, has secondarily adapted to other wild and domestic animals and to humans [26].

Myiasis is more common in summer and spring seasons of tropical countries [27]. Our case occurs in February where the end of winter and atmospheric temperature in Makkah area is slightly high especially at daytime like spring temperature.

The goal of treatment is removal of the larva and prevention of the secondary infection. Occlusion, larvicides such as ivermectin, or manual squeezing can be used to remove the larva. Occlusion deprives the larva of oxygen and either kills the larva or induces it to move upward in search of air [1]. Manually squeezing out the larva is therapeutic option in all forms of furuncular myiasis. Sometimes, surgical removal is needed for removing the larvae or their fragments [28].

#### 4. CONCLUSION

In conclusion, we report a case of furuncular cutaneous myiasis on the back and hand in an infant by *C. anthropophaga*, living nearby such livestock, with flies and poor hygienic conditions, which has been rarely described in Saudi Arabia. Considering the increasing close association with animal houses, physicians should be more concerned about clinical manifestations of cutaneous myiasis and morphologic characteristics of dipterous larvae.

#### CONSENT

As per international standard informed and written parental consent has been collected and preserved by the authors.

#### ETHICAL APPROVAL

As per international standard written ethical permission has been collected and preserved by the author(s).

#### ACKNOWLEDGEMENT

The authors would like to express sincere appreciation to staff members and technicians of the Maternity and Children Hospital, Makkah, Saudi Arabia for their assistance in parasitological identification and data collection.

#### COMPETING INTERESTS

Authors have declared that no competing interests exist.

## REFERENCES

1. McGraw TA, Turiansky GW. Cutaneous myiasis. *J Am Acad Dermatol.* 2008;58: 907-926.
2. Veraldi S, Brusasco A, Suss L. Cutaneous myiasis caused by larvae of *Cordylobia anthropophaga* (Blanchard). *Int J Dermatol.* 1993;32:184-187.
3. Dehecq E, Nzungu PN, Cailliez JC, Guevart E, Delhaes L, Dei-Cas E, Bourel B. *Cordylobia anthropophaga* (Diptera: Calliphoridae) outside Africa: A case of furuncular myiasis in a child returning from Congo. *J Med Entomol.* 2005;42:187-192.
4. Deng Y, Liu F, Chen X, Lu S. The first imported cutaneous myiasis due to *Cordylobia anthropophaga* in China. *Int J Dermatol.* 2013;52:120-122.
5. Wangia M, Glenn C, Mitchell C, Fisher S. Florid *Cordylobia anthropophaga* furuncular myiasis from travel in Nigeria. *J Dermatol.* 2012;39:1099-1100.
6. Fujisaki R, Makimura K, Hayashi T, Yamamura M, Yamaoka T, Shiraishi K, Ishibashi S, Kawakami S, Kurihara T, Nishiya H. Exotic myiasis caused by 19 larvae of *Cordylobia anthropophaga* in Namibia and identified using molecular methods in Japan. *Trans R Soc Trop Med Hyg.* 2008;102:599-601.
7. Omar MS, Abdalla RE. Cutaneous myiasis caused by tumbu fly larvae, *Cordylobia anthropophaga* in southwestern Saudi Arabia', *Trop Med Parasitol.* 1992;43:128-9.
8. Almatary AA, Hassanein R, Makhlof RT, Hanaa Y, Bakir HY, Amr M, Mohamed AM. First record of indigenous furuncular myiasis due to *Cordylobia anthropophaga* in unusual ecologic niche, Makkah, Saudi Arabia, *International Journal of Tropical Disease & Health.* 2016;19(1):1-7. [Article no. IJTDH.29086] [ISSN: 2278-1005] [NLM ID: 101632866] Available:www.sciencedomain.org
9. Robbins K, Khachemoune A. Cutaneous myiasis: a review of the common types of myiasis. *Int J Dermatol.* 2010;49:1092-1098.
10. Blacklock B, Thompson MG. A study of the Tumbu fly *Cordylobia anltropophlaga*, Gruinberg in Sierra Leone. *Annials of Tropiical Medicinie anitd Paralsitology.* 1923;17:443.
11. Caissie R, Beaulieu F, Giroux M, Berthod F, Landry PE. Cutaneous myiasis: Diagnosis, treatment and prevention. *J Oral Maxillofac Surg.* 2008;66:560-568.
12. Lachish T, Marhoom E, Mumcuoglu KY, Tandlich M, Schwartz E. Myiasis in travelers. *J Travel Med.* 2015;22:232-236.
13. Song SM, Kim SW, Goo YK, Hong Y, Ock MS, Cha HJ, Chung DI. A case of furuncular myiasis due to *Cordylobia anthropophaga* in a Korean traveler returning from Uganda. *Korean J Parasitol.* 2017;55:327-331.
14. Ko JY, Lee I, Park1 BJ, Shin1 JM, Ryu J. A case of cutaneous myiasis caused by *Cordylobia anthropophaga* larvae in a Korean Traveler Returning from Central Africa, *Korean J Parasitol.* 2018;56(2):199-203. Available:https://doi.org/10.3347/kjp.2018.56.2.199
15. Martinez-Hernandez F, Vega-Memije ME, Villalobos G, Perez-Rojas D, Asz-Sigall D, Rivas N, Alejandro R, Maravilla P, Valdovinos MR. Myiasis caused by *Dermatobia hominis* in Mexico: morphological and molecular identification using the cytochrome oxidase I gene', *Rev Inst Med Trop Sao Paulo.* 2019;61:e45.
16. Millikan LE. Myiasis. *Clin Dermatol.* 1999; 17:191-195.
17. Khalifa RM, Mowafy NM. Light and scanning electron microscopical identification of sarcophagid larva causing intestinal myiasis. *Egypt J Med Sci.* 1997; 18:235-43.
18. Zumpt F. Myiasis in man and animals in the Old World. A text book for physicians, veterinarians and zoologists. London, UK. Butterworths. 1965;70-77.
19. Tamir J, Haik J, Schwartz E. Myiasis with lund's fly (*Cordylobia rodhaini*) in travelers. *J Travel Med.* 2003;10:293-295.
20. Ockenhouse CF, Samlaska CP, Benson PM, Roberts LW, Eliasson A, Malane S, Menich MD. Cutaneous myiasis caused by the African tumbu fly (*Cordylobia anthropophaga*). *Arch Dermatol.* 1990;126: 199-202.
21. Chopra A, Probert AJ, Beer WE. Myiasis due to tumbu fly. *Lancet.* 1985;1:1165.
22. Hall M, Wall R. Myiasis of Humans and Domestic Animals, *Adv Parasitol.* 1995;35: 257-334.
23. Ogo NI, Onovoh E, Okubanjo OO, Galindo RC, De la Lastra JM, De la Fuente J. Molecular identification of *Cordylobia*

- anthropophaga blanchard* (Diptera: Calliphoridae) larvae collected from dogs (*Canis familiaris*) in Jos South, Plateau State, Nigeria. Onderstepoort J Vet Res. 2012;79:E1-4.
24. Hall MJR, Smith KGC. Diptera causing myiasis in man. In: Lane RP, Crosskey RW, editors. Medical insects and arachnids. London: Chapman and Hall. 1993;429–69.
  25. Afifi MA, Jiman-Fatani AA, Alsiny FI, Anshasi WS. A new focus of autochthonous transmission of *Cordylobia anthropophaga* in Saudi Arabia. J Microsc Ultrastruct. 2015;3:82–5.
  26. Scholl PJ, Catts EP, Mullen GR. Myiasis (Muscoidea, Oestroidea). In: Mullen G, Durden L, editors. Medical and veterinary entomology. San Diego: Elsevier. 2009; 309–38.
  27. Sharma K. Ophthalmomyiasis externa: A case report from Alkharj, Saudi Arabia, Saudi Journal of Ophthalmology. 2018;32: 250–252.
  28. Lane RP, Lowell CR, Griffiths WA, Sonnex TS. Human cutaneous myiasis - A review and report of three cases due to *Dermatobia hominis*. Clin Exp Dermatol. 1987;12:40-45.

© 2020 Hassanein et al.; This is an Open Access article distributed under the terms of the Creative Commons Attribution License (<http://creativecommons.org/licenses/by/4.0>), which permits unrestricted use, distribution, and reproduction in any medium, provided the original work is properly cited.

*Peer-review history:*

*The peer review history for this paper can be accessed here:*  
<http://www.sdiarticle4.com/review-history/56084>