Immediate effects of electrical stimulation on serratus anterior muscle activity in people with hemiplegia post-stroke

Palak Anand Kakwani, Ramesh Debur

Biofeedback Lab, M.S. Ramaiah College of Physiotherapy, Bengaluru, India.

This article is distributed under the terms of the Creative Commons Attribution Noncommercial License (CC BY-NC 4.0) which permits any noncommercial use, distribution, and reproduction in any medium, provided the original author(s) and source are credited.

Abstract

Upper limb impairment occurs in approximately 80% of stroke survivors, with altered scapular kinematics playing a key role in dysfunction. Serratus anterior weakness post-stroke contributes to abnormal scapular motion, limiting shoulder and arm function. This study explored whether Electrical Stimulation (ES) could immediately enhance serratus anterior activity in individuals with post-stroke hemiplegia. A pre-post intervention design was used involving 19 individuals within three months post-stroke. Surface Electromyography (sEMG) recorded serratus anterior activity during a forward reach task. The Fugl-Meyer Assessment (FMA) was also administered. Participants received 20 minutes of ES targeting the serratus anterior, after which sEMG and FMA were reassessed. Wilcoxon signed rank test compared pre- and post-intervention sEMG values. Statistical analysis showed a significant change in the area under the curve value ($p < 0.01$) but no significant change in RMS value. There was no change in FMA scale. Electrical stimulation showed significant changes in the muscle activity of the serratus anterior, indicating a reduction in the cost of the muscle work done during the forward reach task.

Key Words: stroke, serratus anterior, electrical stimulation, surface electromyography.

Eur J Transl Myol 35 (4) 14082, 2025 doi: 10.4081/ejtm.2025.14082

A stroke is an abrupt loss of neurological function caused by an interruption in the blood flow to the brain.[1] Strokes are the second leading cause of mortality and disability globally.[2] Of all the types of stroke, ischemic stroke accounts for approximately 80% of cases.[1]

It is caused by a blood clot that obstructs or restricts blood flow, depriving the brain of necessary oxygen and nutrients. Haemorrhagic stroke is defined as cerebral bleeding caused by the rupture of a blood vessel in or around the brain.[3] The clinical presentation and deficits following a stroke will vary depending on the severity of the lesion and the area of the brain affected.[4] Studies suggest that upper limb movements get impaired in 80% of individuals suffering acute stroke and 40% of people with chronic stroke, limiting the functional activities of daily living.[1] Upper extremity motions are substantially impaired in hemiplegics following a stroke due to abnormality in the muscle tone, followed by a lack of voluntary control.[4]

During movements of the upper limb, the scapula plays a central role in normal shoulder kinematics.[4] The scapula's role is to align the glenoid fossa for optimal contact with the humeral head; to provide a stable base for controlled motions and add range to elevation of the upper extremity.[5] The scapula on the thorax rotates the glenoid fossa upward from its resting position, which leads to elevation of the arm.[5] This motion of the scapula on the thorax is produced by a balanced force couple between serratus anterior and trapezius.[5]

Following a stroke, these forces are disturbed due to muscle imbalance, which leads to impairment of upper extremity movements.[6]The serratus anterior, because of its long moment arm (leverage), generates more torque and has been shown to have a dominant role in the force couple.[5] It is known to be the only muscle that is capable of simultaneously producing upward rotation, external rotation, and posterior tilt of the scapula, which is a prerequisite for arm elevation.[5]

Immediately after a stroke there is a stage of flaccidity with lack of voluntary control succeeded by development of spasticity leading to alterations in kinematics of the shoulder joint hampering the symmetry of scapulothoracic joint.[7] Scapular dyskinesis is caused by many neurological components including loss of joint sense and abnormality in motor functions.[7] In the flaccid stage, reduction of scapular muscles tone changes the glenoid fossa angle resulting in depression and protraction of the scapula. During spasticity, the scapular alignment changes to depression along with retraction and adduction at the shoulder joint due to predominance of the flexor tone.[8,9]

The serratus anterior muscle is vulnerable to overstretching

and premature fatigue post-stroke.[1] The muscle has late activation and early deactivation during a forward flexion task in people with stroke, as opposed to healthy adults, where the serratus anterior had simultaneous activation along with the anterior deltoid.[10] During flexion activities of the shoulder, the anterior orientation of the scapula is necessary, and only the serratus anterior muscle can produce it.[11] Kibler *et al.*[12] Kisner and Colby[13] and Choi[14] confirmed from their studies that upper extremity functions will improve by strengthening the serratus anterior muscle.

Various interventions have been applied to improve movements of the upper extremity in people with stroke, such as neuromuscular electrical stimulation, manual therapy, functional training, bracing, or taping techniques. There is mounting proof that Electrical Stimulation (ES) accelerates the recovery of motor function of the upper extremity in people with stroke.[16] ES, a term which is often used interchangeably with Neuromuscular Electrical Stimulation (NMES), is commonly administered at frequencies in the higher range (20-50Hz) to induce muscle contraction and tetany.

NMES is commonly used to improve the strength of the muscles as well as retrain the muscles.[17] While long-term NMES protocols have demonstrated efficacy in improving motor function, understanding the immediate effects of a single session can inform early-phase rehabilitation interventions.

Knutson *et al.* conducted a study that suggests that the use of NMES as an adjunct for upper extremity rehabilitation can improve muscle strength in individuals with chronic stroke by increasing the activated motor units, the rate and synchronisation of muscle activation.[19] Therefore, ES as a therapy can be beneficial in people with stroke to improve muscle strength.[17]

The Fugl-Meyer Assessment (FMA) scale is widely recognized as a reliable tool for evaluating motor function after a stroke, with a high correlation coefficient of 0.9. The FMA utilizes a comprehensive numerical scoring method to assess six specific areas of the patient's condition: range of motion, pain, sensitivity, motor functions of upper and lower extremity balance along with coordination and speed, amounting to a total of 226 points.[4]

EMG is an abbreviation for electromyography. It is a method for assessing and recording electrical signals in muscles. The EMG signal detects electrical currents in muscles during contraction to show neuromuscular activity in medical and biological terms. The musculoskeletal system is under constant control by the nervous system, directing muscle movement. Consequently, the EMG signal is a complex signal that is regulated by the nervous system and is solely influenced by muscle anatomical and physiological characteristics. Surface EMG in which the electrical activity of a muscle or a group of muscles is recorded by placing the electrodes over the skin, has been used in neuro rehabilitation for decades.[18]

This study aimed to evaluate the immediate impact of a single ES session on serratus anterior muscle activity during a forward reach task, using surface EMG as an outcome measure. The findings are intended to guide clinicians in optimizing scapular-focused rehabilitation strategies in the early post-stroke period.

Materials and Methods

Study design and setting

A prospective, single-arm, pre-post intervention study was conducted at Ramaiah Memorial Hospital, Bengaluru, between July 2023 and June 2024. The study received approval from the Institutional Ethics Committee of Ramaiah University of Applied Sciences (MSRMC/EC/PG-17/06-2023)Written informed consent was obtained from all participants prior to study participation.

Participants

Nineteen individuals with stroke (mean age 55.4 ± 14.5 years; 17 males, 2 females) participated in the study. Participants were recruited from inpatient and outpatient physiotherapy departments.

Inclusion criteria

The inclusion criteria adopted included: i) diagnosis of ischemic or hemorrhagic stroke (confirmed via neuroimaging); ii) time since stroke onset: 0–3 months (acute and subacute phase); iii) age ≥ 18 years; iv) ability to sit independently for at least 10 minutes.

Exclusion criteria

The exclusion criteria were: i) severe cognitive impairment (based on clinical judgment and medical records); ii) sensory deficits affecting the hemiparetic upper limb; iii) modified Ashworth scale score ≥3 for shoulder musculature; iv) prior use of electrical stimulation for the serratus anterior in the current rehabilitation program

Materials required

Electromyography (EMG) electrodes were used to record activity of the serratus anterior muscle (*Supplementary Figure 1*), with a pair of surface electrodes applied to the muscle (*Supplementary Figure 2*) and connected via EMG cables and sensors to the recording system (*Supplementary Figure 3*). Nuprep gel was applied at the electrode sites to reduce skin impedance and improve signal quality. Participants were seated on a stool without back support (*Supplementary Figure 4)* to standardize posture and minimize compensatory movements. A camera captured participant movements for subsequent analysis. A crutch was always provided to facilitate isolation of serratus anterior activity and minimize involvement of other muscles (*Supplementary Figure 5*). Upper extremity motor function was assessed using the Fugl-Meyer Assessment Scale.

Procedure

Baseline assessment was conducted for all participants. Demographic data and stroke characteristics were recorded. The Fugl-Meyer Assessment for the upper extremity (FMA-UE) was administered by a trained physiotherapist. Surface EMG recording was then performed to measure neuromuscular function of Serratus Anterior muscle.

Participants were seated upright on a stool without back support. The hemiparetic hand was supported on a crutch positioned in the sagittal plane. Surface EMG electrodes (3

mm diameter) were placed on the belly of the serratus anterior muscle at the 6th and 8th ribs along the mid-axillary line, in accordance with SENIAM guidelines. A ground electrode was placed at the C7 spinous process. Skin preparation included cleaning with Nuprep gel.
Participants performed a standardized forward reach task: from resting position, reaching forward without compensatory trunk movements. Three trials were recorded, with 10 seconds rest between trials. EMG data were captured throughout each movement.

Electrical stimulation protocol

After baseline assessment, participants received a 20-minute session of ES targeting the hemiparetic serratus anterior (*Supplementary Table 1*)
Surface EMG was re-recorded immediately after ES during repeat forward reach trials.

Outcome measures

EMG is traditionally used for assessing muscle activity. The aim of our study was to note the change in the serratus anterior muscle activity post-electrical stimulation. Surface (sEMG) is a non-invasive technique that is known to capture the changes in the muscle response by detecting electrical signals produced during muscle contractions. By placing electrodes on the skin over the muscles, sEMG provides data on muscle activation levels, allowing us to assess the impact of electrical stimulation on muscle function.
sEMG values were denoted as: i) root mean square maximum value, also denoted as RMS is the value widely used to quantify the amplitude of the muscle activity;[19] ii) the area under the curve is the integration of EMG amplitude and the time duration taken to perform a task; the area under the curve has been used to quantify work done by the muscle; iv) Power is obtained by normalizing area under the curve value divided by the time taken to perform the task; we used power generated by the muscle to estimate the metabolic cost of forward reach task; Fugl-Meyer Assessment Upper Extremity score was taken as a secondary outcome measure to capture any functional changes.

Preparation of the setup

A stool without a backrest was placed, and a crutch was used for the patient to support the hand during the forward reach task. An EMG monitor was placed next to the stool so that cables could be connected to the patient's body and reach while the task was being performed. One HP web camera was arranged in the side to record the sagittal view.

Preparation of the patient

sEMG electrodes (3mm) were placed on the participant's body on the Serratus anterior muscle over the muscle belly at 6th and 8th ribs along the mid-axillary line and the ground electrode was placed at the level of C7 spinous process. The electrodes were applied according to the SENIAM guidelines for surface EMG electrode placement. The area of application was cleaned with the help of Nuprep gel to avoid any skin impedance. The electrode sensors were secured in place with tape to prevent movement artifacts. EMG cable A was attached to the serratus anterior muscle of the hemiparetic side (*Supplementary Figure 6*).

Baseline data recording

In the test position the baseline data was recorded when the participant was at rest and not doing the task.

Data recording

The data was recorded using a single channel of EMG when the participant was asked to do a forward reach task. Three trials were recorded for average purposes.

Measurement of EMG

The data recorded was when the participant started the forward reach task and the recording was stopped when the participant came back to the starting position. A ten-second rest was given between each trial to achieve a baseline value of the muscle activity. Maximum and average values of root mean square and area under the curve values were noted for analysis.

Performing the task

The patient is instructed to sit upright with the feet on the floor with the hip, knee, and ankle in 90-degree flexion. The hemiparetic hand is supported on a crutch, which is adjusted at 90 degrees in the sagittal plane. Following that, the patient is asked to perform a forward reach movement without involving the trunk to maximize serratus anterior muscle activity. The EMG activity is recorded throughout the movement. The participant is asked to do three trials (*Supplementary Figure 7*).

Data analysis

Statistical analysis was performed using Jamovi software. Normality of data was assessed using the Shapiro-Wilk test. As EMG variables were non-normally distributed, Wilcoxon signed-rank tests were used to compare pre- and post-intervention values. Significance was set at $p<0.05$.

Results

Participant characteristics

Nineteen participants completed the study. Stroke types included middle cerebral artery infarct (68.5%), corona radiata infarct (10.5%), thalamic bleed (5.3%), pontine infarct (11.6%), and gangliocapsular bleed (5.3%).Shapiro wilk was done for normality.

Descriptive statistics

Data normality was assessed using the Shapiro-Wilk test (*Supplementary Table 2*). Participant characteristics were summarized, including distribution by gender (Table 1) and age (Table 2, *Supplementary Figure 8*), as well as by type of infarct (Table 3). EMG variables were then analyzed, including RMS maximum values (*Supplementary Table 3*, *Supplementary Figures 9 and 10*), RMS average values (*Supplementary Table 4*, *Supplementary Figures 11 and 12*), and area under the curve (Table 4, Figures 1 and 2), providing a detailed description of muscle activity across the study population.

Inferential statistics

Wilcoxon signed rank test was used for inferential analysis (Table 5). No change was observed in FMA-UE scores post-intervention.

Table 1. *Descriptive statistics for participant age.*

Participant characteristics	Mean ± standard deviation	Maximum age	Minimum age
Age (years)	55.4 years ± 14.5	79 years	35 years

Table 2. *Frequency and percentage of gender.*

Gender	Frequency	%
Male	17	89.5
Female	2	10.5

Table 3. *Descriptive statistics for the types of infarct participants had.*

Type of infarct	Gender	Frequency	%
MCA	Male	12	63.2
	Female	1	5.3
Corona Radiata	Male	2	10.5
	Female	0	0
Thalamic	Male	1	5.3
	Female	0	0
Pontine	Male	1	5.3
	Female	1	5.3
GC bleed	Male	1	5.3
	Female	0	0

Table 4. *Descriptive statistics for the area under the curve value.*

Variables	N	Median (mV) (IQR)
Area under the curve pre intervention	19	9.43 mV (17.1-5.69)
Area under the curve post intervention	19	21.0 mV(28.6-15.1)

Table 5. *Wilcoxon signed rank test for area under the curve value.*

Wilcoxon w	Statistical value	p value
Area under the curve pre and post intervention	15.0	<0.001*

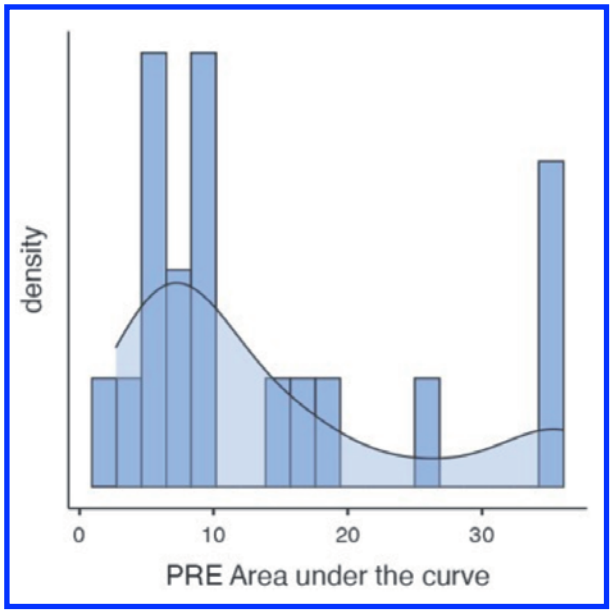

Figure 1. *Graphical representation Pre Area Under the curve.*

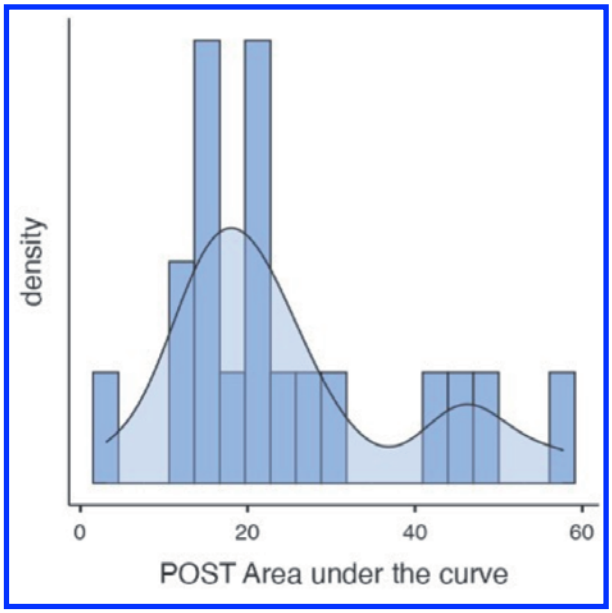

Figure 2. *Graphical representation Post Area Under the curve.*

Discussion

This study demonstrates that a single session of ES applied to the serratus anterior muscle significantly enhances its activity, as reflected by increased AUC during a functional forward reach task in people with hemiplegia post-stroke.

Inhibition of neural drive post-stroke refers to the diminished ability of the brain to generate and transmit effective motor commands to the muscles, a common and debilitating consequence of cerebrovascular events. Strokes disrupt the normal functioning of the motor cortex and its descending pathways, such as the corticospinal tract, leading to an imbalance between excitatory and inhibitory neural signals. This imbalance often manifests as muscle weakness, impaired voluntary movement, and, in some cases, spasticity due to the overactivity of inhibitory neural circuits. Addressing neural drive inhibition is crucial for rehabilitation, as restoring the balance of neural activity can significantly enhance motor recovery. Interventions such as ES are employed to modulate neural activity, promote neuroplasticity, and improve muscle activation by disinhibiting the neural drive.

The increase in the area under the curve value post stimulation suggests an increase in the total amount of muscle activation over time. Electrical stimulation leads to additional recruitment of muscle fibers, including those not normally activated during voluntary contraction of the muscle due to reduced neural drive post-stroke. This finding is consistent with the work of Hesam-Shariati *et al.*,[20] who highlighted AUC as a sensitive marker of muscle activity improvements in neurorehabilitation interventions. RMS values trended upward but did not reach statistical significance. Root Mean square value represents the peak force produced by the muscle. In normal muscle function, Motor Units (MUs) are recruited in an orderly manner based on their size, where smaller MUs are activated first, followed by larger ones as more force is needed. This orderly recruitment ensures efficient muscle function and minimizes fatigue. However, when the motor units are recruited using various modalities like electrical stimulation, there is disruption in the order of recruitment of motor units, leading to decreased contraction efficiency and a higher risk of neuromuscular fatigue, causing an increase in the duration of the muscle remaining activated, but no significant increase in the peak force produced by the muscle.

Our results align with a study done by Suresh[21] who studied about the orderly recruitment of motor units in healthy individual's vs people with stroke. Due to reversal order of recruitment of motor units no significant change is observed in the force produced by the muscle.

The lack of immediate change in FMA-UE is not surprising given the short-term nature of the intervention and the multifactorial nature of functional recovery, which depends on synergistic activation of multiple muscle groups beyond the serratus anterior.

Limitations of the study include small sample size and single-session design limit generalizability. there was no follow up to see the change achieved in cost of work done by the muscle was maintained or not.

Clinical implications

Early targeting of scapular stabilizers, particularly the serratus anterior, via ES may reduce muscle work cost, delay fatigue, and promote more efficient upper limb movements. Incorporating ES into early rehabilitation could facilitate recovery of scapular mechanics and upper extremity function.

Future directions

Future research should explore multi-session ES protocols, combine ES with functional task training, and investigate effects on long-term functional outcomes. Expanding EMG analysis to include synergistic scapular muscles would provide a more comprehensive understanding of shoulder mechanics post-stroke.

Conclusions

A single session of ES significantly improves serratus anterior muscle activity in people with hemiplegia post-stroke. Incorporating targeted ES of scapular stabilizers in early rehabilitation may enhance upper extremity recovery.

List of abbreviations

AUC, Area Under the Curve
AROM, Active Range Of Motion
FMA, Fugl-Meyer Assessment Scale
RMS, Root Mean Square
sEMG, surface Electromyography

Acknowledgments

The authors thank the participants for their involvement.

Conflict of interest

The authors declare no conflict of interest, and the study did not receive any funding.

Ethics approval and consent to participate

The study received approval from the Institutional Ethics Committee of Ramaiah University of Applied Sciences (MSRMC/EC/PG-17/06-2023).

Contributions

PAK, conceptualization, data collection, methodology, investigation, writing – original draft, visualization; RD, supervision, methodology, validation, writing – review & editing. All authors have reviewed and approved the final version of the manuscript and agree to be accountable for all aspects of the work.

Conference presentation

A part of this study was presented in Karnataka Physiocon 2025, An International Physiotherapy Conference held in Bangalore on 25,26th April 2025.

Corresponding author

Ramesh Debur, M.S. Ramaiah College of Physiotherapy, M.S. Ramaiah Nagar, Mathikere, Bengaluru, Karnataka, 560054, India.
Tel.: 9845544848
ORCID ID: 0000-0002-6653-5580
E-mail: rameshdebur@gmail.com

Co-author

Palak Kakwani
ORCID ID: 0009-0003-4873-5524
E-mail: palakkakwani@gmail.com

References

1. Kazi EN, Ganvir SS. Scapular malalignment in patients with stroke: A narrative. Int J Physiother Res 2021;9:4051–7.
2. Donkor ES. Stroke in the 21st century: A snapshot of the burden, epidemiology, and quality of life. Stroke Res Treat 2018;2018:3238165.
3. Magid-Bernstein J, Girard R, Polster S, et al. Cerebral hemorrhage: Pathophysiology, treatment, and future directions. Circ Res 2022;130:1204–29.
4. Naviwala AS, Patil S, Kumar A. Immediate effects of Kinesio taping on upper extremity movements in post-stroke hemiplegics. Int J Health Sci Res 2020;10:49–57.
5. Levangie PK, Norkin CC. Joint structure and function: A comprehensive analysis. 4th ed. Philadelphia: F.A. Davis Co.; 2005.
6. Jaraczewska E, Long C. Kinesio taping in stroke: Improving functional use of the upper extremity in hemiplegia. Top Stroke Rehabil 2006;13:31–42.
7. Kibler WB, Ludewig PM, McClure P, Uhl TL, Sciascia A, editors. Scapular Summit 2009: July 16, 2009, Lexington, Kentucky. J Orthop Sports Phys Ther 2009;39:A1–A3.
8. Cailliet R. The shoulder in hemiplegia. 3rd ed. Philadelphia: F.A. Davis Co.; 1980. p. 78–86.
9. Chaco J, Wolf E. Subluxation of the glenohumeral joint in hemiplegia. Am J Phys Med 1971;50:139–143.
10. De Baets L, Jaspers E, Janssens L, Van Deun S. Characteristics of neuromuscular control of the scapula after stroke: A first exploration. Front Hum Neurosci 2014;8:933.
11. Kapadia N, Moineau B, Marquez-Chin C, Popovic MR. Feasibility and significance of stimulating interscapular muscles using transcutaneous functional electrical stimulation in able-bodied individuals. J Spinal Cord Med. 2021;44:S185–92.
12. Burkhart SS, Morgan CD, Kibler WB. Shoulder injuries in overhead athletes: The “dead arm” revisited. Clin Sports Med 2000;19:125–58.
13. Kisner C, Colby LA, Borstad J. Therapeutic exercise: Foundations and techniques. 7th ed. Philadelphia: F.A. Davis Co.; 2017.
14. Park SI, Choi YK, Lee JH, Kim YM. Effects of shoulder stabilization exercise on pain and functional recovery of shoulder impingement syndrome patients. J Phys Ther Sci 2013;25:1359–62.
15. Kirar B, Pattnaik M, Mohanty P. Effect of bilateral

repetitive protraction in antispastic position of suspended upper extremity on motor performance and scapular position in stroke. Adv Neurol Neurosci 2021;4:19–25.
16. de Kroon JR, IJzerman MJ, Chae J, et al. Relation between stimulation characteristics and clinical outcome in studies using electrical stimulation to improve motor control of the upper extremity in stroke. J Rehabil Med 2005;37:65–74.
17. Doucet BM, Lam A, Griffin L. Neuromuscular electrical stimulation for skeletal muscle function. Yale J Biol Med 2012;85:201–15.
18. Reaz MB, Hussain MS, Mohd-Yasin F. Techniques of EMG signal analysis: Detection, processing, classification and applications. Biol Proced Online 2006;8:11–35.
19. Konrad P. The ABC of EMG: A practical introduction to kinesiological electromyography. Scottsdale, AZ: Noraxon USA Inc.; 2005.
20. Hesam-Shariati N, Trinh T, Thompson-Butel AG, et al. A longitudinal electromyography study of complex movements in poststroke therapy: Heterogeneous changes despite consistent improvements in clinical assessments. Front Neurol 2017;8:340.
21. Hu X, Suresh AK, Rymer WZ, Suresh NL. Assessing altered motor unit recruitment patterns in paretic muscles of stroke survivors using surface electromyography. J Neural Eng 2015;12:066001.

Disclaimer

All claims expressed in this article are solely those of the authors and do not necessarily represent those of their affiliated organizations, or those of the publisher, the editors and the reviewers. Any product that may be evaluated in this article or claim that may be made by its manufacturer is not guaranteed or endorsed by the publisher.

Submitted: 18 June 2025.
Accepted: 14 July 2025.
Early access: 22 August 2025.

Online supplementary material:

Supplementary Figure 1. EMG device with HP laptop and camera.

Supplementary Figure 2. 3mm EMG electrodes.

Supplementary Figure 3. EMG cables and sensors.

Supplementary Figure 4. The stool used for the study.

Supplementary Figure 5. The crutch that was used by the participant during the task

Supplementary Figure 6. Placement of sEMG electrodes for serratus anterior muscle.

Supplementary Figure 7. Image showing participant doing forward reach task.

Supplementary Figure 8. Graphical representation of age.

Supplementary Figure 9. Graphical representation Pre RMS maximum value.

Supplementary Figure 10. Graphical representation Post RMS maximum value.

Supplementary Figure 11. Graphical representation Pre RMS average value.

Supplementary Figure 12. Graphical representation Post RMS average value.

Supplementary Table 1. Parameters of the currents used.

Supplementary Table 2. Shapiro-Wilk test for Normality.

Supplementary Table 3. Descriptive statistics for root mean square maximum value. RMS, Root mean square.

Supplementary Table 4. Descriptive statistics for root mean square average value. RMS, Root Mean Square.

Supplementary Table 5. Wilcoxon signed rank test for RMS maximum and average values. RMS, Root Mean Square.