





Root canal treatment of a maxillary lateral incisor with type II Dens Invaginatus: a case report

Lucas Pinto Carpena¹ , Gabriel Lima Braz² , Lucas Peixoto de Araújo³ , Nádia de Souza Ferreira^{4*} 

¹ DDS, MSc, PhD, Dental School, Federal University of Pelotas (UFPEL), Pelotas, Rio Grande do Sul, Brazil.

² DDS, MSc student, Dental School, Federal University of Pelotas (UFPEL), Pelotas, Rio Grande do Sul, Brazil.

³ DDS, MSc, PhD, School of Dentistry, Department of Cariology, Restorative Sciences and Endodontics, University of Michigan, Ann Arbor, MI, USA.

⁴ DDS, MSc, PhD, Dental School, Federal University of Pelotas (UFPEL), Pelotas, Rio Grande do Sul, Brazil.

Corresponding author:

Prof. Nádia de Souza Ferreira.
Faculdade de Odontologia,
Universidade Federal de Pelotas.
457 Gonçalves Chaves Street,
Pelotas, RS, Brazil. CEP: 96015-560.
E-mail: nadia.ferreira@ufpel.edu.br

Editor: Dr. Altair A. Del Bel Cury

Received: March 23, 2025

Accepted: July 14, 2025

Aim: To report a case of endodontic treatment of an upper lateral incisor with type II Dens Invaginatus with the aid of operative microscopy and ultrasonic tips. **Case Report:** A 16 years-old female patient was referred for endodontic treatment of the left maxillary lateral incisor with diagnosis of symptomatic apical periodontitis and type II Dens Invaginatus. Removal of the intracanal calcified structure was carried out using long-shaft high-speed drills in conjunction with diamond-coated ultrasonic tips. Instrumentation was performed alternating between reciprocating and manual files up to the K 80 file. Intracanal medication based on 2% chlorhexidine gel and calcium hydroxide powder remained inside the canal for 14 days. Filling was executed by creating an apical plug with bioceramic sealer (Bio-C Repair, Angelus) and a Mineral trioxide aggregate (MTA, Angelus) backfill up to the cervical third. In the 14 months follow-up the periapical radiograph and CBCT showed signs of periapical bone repair. **Conclusion:** This report highlights the critical role of CBCT and the use of UT combined with microscopy in comprehensive treatment planning and execution. Additionally, it provides valuable clinical evidence demonstrating the feasibility and effectiveness of this approach.

Keywords: Dens in dente. Tooth abnormalities. Ultrasonics. Case reports as topic.



Introduction

Dens invaginatus (DI) is a dental anomaly characterized by a deep invagination of the coronal or root surface of the tooth delimited by the enamel itself¹. The precise etiology of DI remains unknown, with authors lacking consensus; however, a multifactorial origin is suggested, involving genetic factors and external influences during tooth development². The permanent upper lateral incisors are the most involved teeth³⁻⁵.

Clinically, the affected teeth can exhibit an unconventional crown anatomy in various shapes. The presence of an enlarged cingulum and deep palatal groove or foramen coecum are also reported, however diagnosis is mainly carried out through imaging examinations, radiographically it is possible to visualize the shape of the invagination eventually surrounded by a radiopaque enamel border⁶⁻⁸. When the enamel covering the invagination is naturally absent, it can function as a plaque retention factor. As bacteria and their by-products spread through the invagination, crossing the dentinal tubules, they can reach the dental pulp and trigger pathologies such as pulpitis, pulp necrosis, and periapical diseases. Consequently, endodontic treatment becomes imperative⁹.

Given the wide anatomical variability observed in such cases, modifications to conventional endodontic therapy are often necessary, posing a technical challenge for endodontists and general clinicians¹⁰. This paper aims to report and describe a clinical case of endodontic treatment of an upper lateral incisor with DI employing operative microscopy and ultrasonic tips (UT).

Case Report

This case report was conducted according to the PRICE guidelines for case reports in endodontics, a flowchart containing case details and an appropriate checklist were provided (**Figure 1**)¹¹. Informed consent was obtained prior to the submission of this study in line with the ICMJE Protection of Research Participants policy.

PRICE 2020 Flowchart

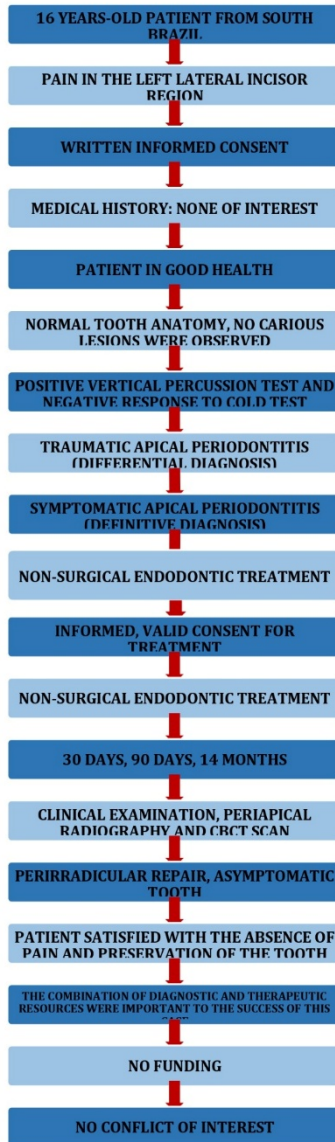


Figure 1. PRICE 2020 Flowchart

A 16 years-old female patient from south Brazil, presented with pain in the left maxillary lateral incisor area. The patient did not present any systemic health issues. Clinically, the referred tooth presented a common anatomy, and no carious lesions were observed (**Figure 2**). After a negative response to the cold test, an intraoral periapical digital radiographic (CDR Elite size 2, Dentsply Sirona, Charlotte, NC, USA) revealed a deep invagination of calcified tissue extending through the root, with no communication with the periodontium, compatible with type II DI, with an

associated radiolucent periapical lesion (**Figure 3**). A high-resolution cone-beam computed tomography (CBCT) (Eagle Edge 0.2 FS) was obtained with a small FOV (5x5 cm) and voxel size of 0.075 mm. CBCT revealed a hypodense apical lesion and confirmed Dens Invaginatus (**Figure 4**). Therefore, diagnosis of pulp necrosis and symptomatic apical periodontitis was established, and non-surgical endodontic treatment was agreed upon as the treatment plan.

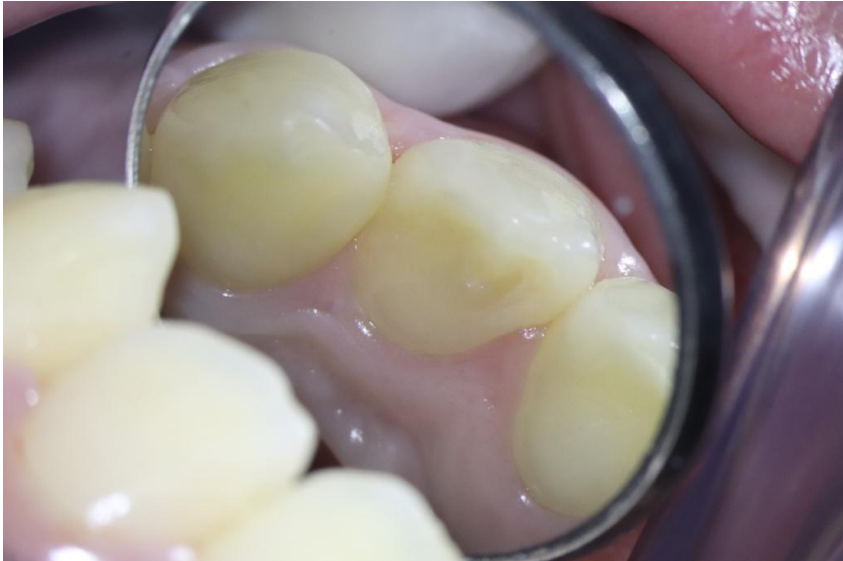

Figure 2. Initial clinical presentation of the case

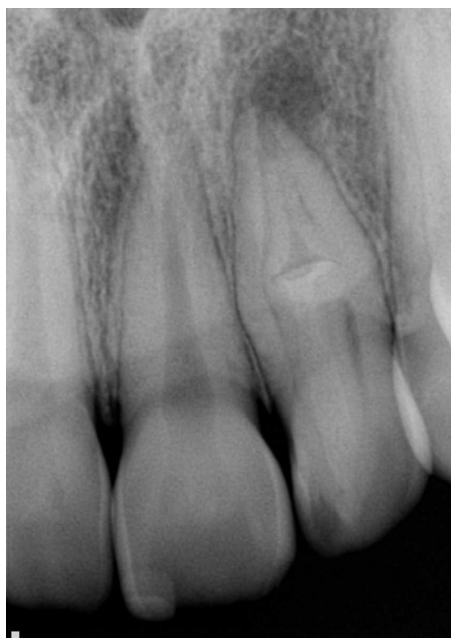

Figure 3. Initial periapical radiograph

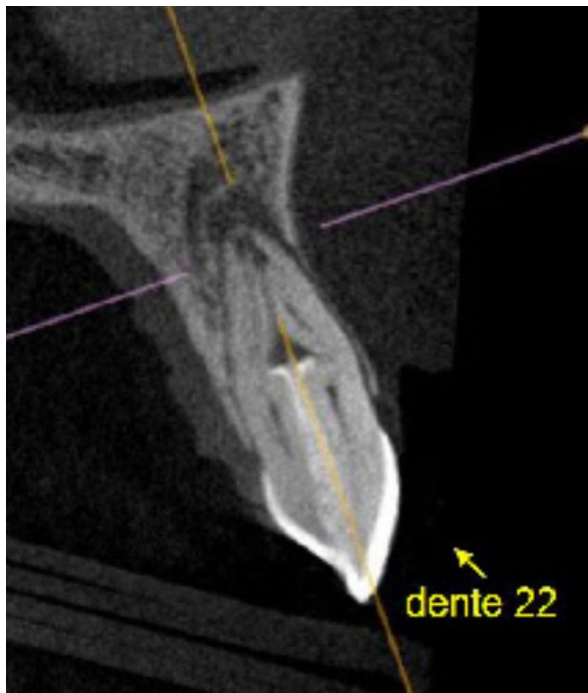

Figure 4. Initial cone beam computed tomography (CBCT)

During the clinical procedure, local anesthesia with lidocaine with 1:100:000 epinephrine (Alphacaine 2%, Nova DFL, Rio de Janeiro, Brazil) and rubber dam isolation were performed. From this point on, the procedure was carried out with the aid of microscopic using 4 up to 25 zoom magnification (OPMI Pico, Zeiss, Oberkichen, Germany) Using long-shaft high-speed drills associated with the FlatSonic UT (Helse Ultrasonic, São Paulo, Brazil) it was possible to obtain coronal access followed by removal of the intracanal calcified structure, thereby connecting the root canal and the invagination (**Figure 5**). The root canals length measures were determined electronically by a RomiApex A-15 apex locator (Romidan LTD, Kiryat Ono, Israel). Working length was established at the "0.0" reading of the electronic apex locator. The root canal was instrumented using the foraminal enlargement technique with reciprocating files using a Reciproc R50 file (VDW GmbH) along with manual files (Maillefer/Dentsply, Ballaigues, Switzerland) up to the K 80 file, 2% chlorhexidine gel associated with physiological saline solution was used for irrigation. After chemical-mechanical preparation, intracanal medication (ICM) based on 2% chlorhexidine gel and calcium hydroxide was placed and remained inside the root canal for 14 days.

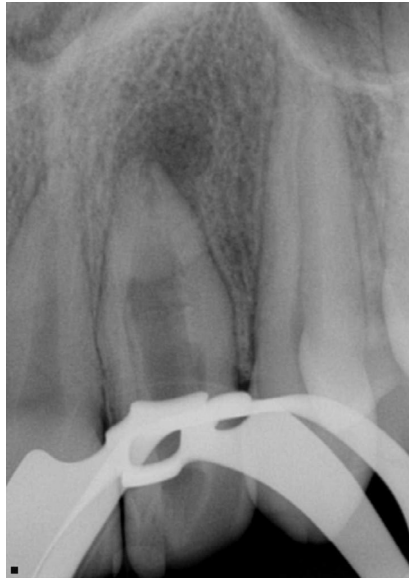

Figure 5. Removal of the intracanal calcified structure connecting the root canal and the invagination

In the second appointment, ICM removal and final irrigation were done with six 20 seconds cycles of passive ultrasonic irrigation (PUI), using the E1-Irrisonic tip (Helse Ultrasonics, São Paulo, Brazil). The initial three cycles used with physiological saline solution, while the subsequent ones involved the use of Ethylenediaminetetraacetic Acid (EDTA). Filling was performed by creating an apical plug with bioceramic sealer (Bio-C Repair, Angelus, Brazil) and Mineral trioxide aggregate (MTA) backfill up to the cervical third. Finally, the tooth was restored with bulk-fill composite resin (**Figure 6**).

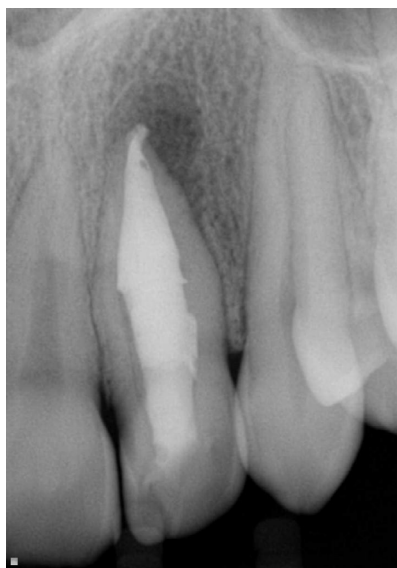


Figure 6. Root canal filling with an apical plug (Bio-C Repair, Angelus, Brazil) and Mineral trioxide aggregate (MTA).

Clinical and radiographic follow-up were carried out at 30 and 90 days, where the patient was found asymptomatic and with initial signs of periapical repair. A periapical radiograph and CBCT were performed 14 months after the procedure (**Figures 7 and 8**) demonstrates suggestive signs of periapical bone repair and, therefore, the success of the endodontic treatment.

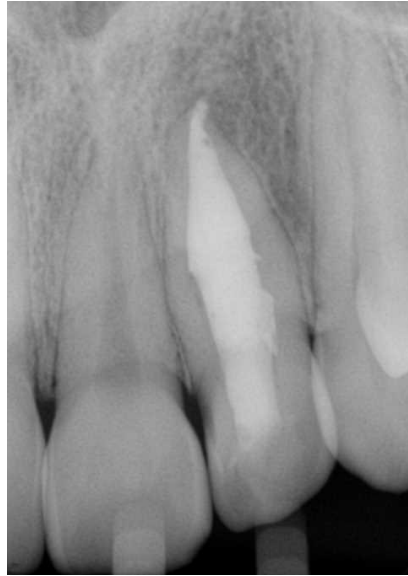

Figure 7. Radiographic follow-up after 14 months

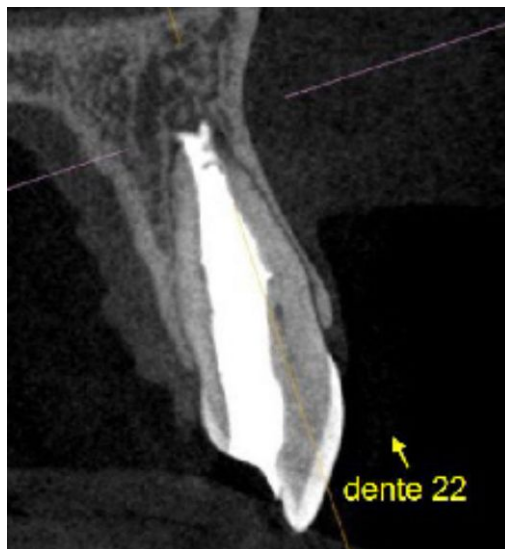

Figure 8. CBCT follow-up after 14 months.

Discussion

Endodontic treatment of DI is complex and determining an effective treatment plan depends on numerous factors, especially the anatomical variations present. Oehlers's widely used classification divides DI into three types: I) invagination limited to the crown; II) invagination extends through the root without communication with the periodontium; III) invagination extending through the entire root, opening into the periodontal ligament, either laterally (IIIa) or apically (IIIb), resulting in an additional foramen¹². In the present case, imaging suggesting the presence of intracanal calcified tissue that ended before the apical foramen was crucial for its classification as a type II DI.

Periapical radiographs can produce valuable but limited information in such cases. Therefore, when DI or a complex canal morphology is suspected, requesting a CBCT should be strongly considered, as it provides substantially more information about the internal root anatomy, allowing for the accurate classification of DI and its periradicular status^{9,13,14}. In this case, CBCT was instrumental in assessing the extent of the invagination and planning the path and depth of penetration before endodontic treatment, ensuring a more precise approach.

For teeth with DI and necrotic pulps or irreversible pulpitis, treatment options include non-surgical endodontic treatment, apical surgery, guided endodontics or extraction. Due to the extensive anatomical variability in DI, clinical decision-making must be tailored to each case¹⁵⁻¹⁷. When opting for a conventional endodontic treatment, adaptations for the conventional technique are often necessary. In type II DI cases, a viable approach involves uniting the main canal and the invagination using diamond-coated UT; however, this technique remains scarcely documented in the literature¹⁰. In the present case, UT combined with microscopic magnification were employed to create a single, widened root canal by removing obstructions and calcifications, increasing canal volume and surface area, and optimizing instrumentation by minimizing non-instrumented regions¹⁸.

Additionally, ultrasound was used to activate the irrigating solution, enhancing its effectiveness. The application of PUI improves root canal disinfection compared to conventional irrigation methods¹⁹ and has also been shown to reduce the risk of postoperative pain within the first 24 hours²⁰. For root canal sealing and to promote optimal repair conditions for the apical periodontium, an apical barrier was created following instrumentation. A bioceramic sealer was selected as the material for the plug, a technique that has been successfully reported in the literature²¹. As a bioactive material composed mainly of calcium and silicate elements, bioceramic sealers have the ability to induce regeneration of both cementum and the periodontal ligament²².

The success of the endodontic intervention in this case is supported by the 14-month follow-up, during which the tooth remained asymptomatic and showed radiographic and tomographic evidence of periapical repair. This case highlights the critical role of CBCT and the use of UT combined with microscopy in comprehensive treatment planning. Additionally, it provides valuable clinical evidence demonstrating the feasibility and effectiveness of this approach. Nevertheless,

long-term clinical and radiographic monitoring remains essential to ensure the sustained success of the treatment.

Conflict of Interest

The authors declare no conflict of interest.

Acknowledgment

The authors declare that there was no funding for this study.

Data availability

Datasets related to this article will be available upon request to the corresponding author.

Institutional Review Board Statement

This case report received approval from the local ethics committee (CAAE: 90621025.7.0000.5318)

Informed Consent Statement

A signed informed consent form was obtained from the patient, authorizing the use of clinical information and images for publication purposes.

Author Contribution

Lucas Pinto Carpena: Conceptualization; Data curation; Methodology; Writing - original draft; and Writing - review & editing. (ICMJE'S criteria: I; II; III; IV). **Gabriel Lima Braz:** Methodology, Data curation; Writing - original draft; and Writing - review & editing. (ICMJE'S criteria: I; II; III; IV). **Lucas Peixoto de Araújo:** Data curation; Methodology; Validation; Supervision; Writing - review & editing. (ICMJE'S criteria: I; II; III; IV). **Nádia de Souza Ferreira:** Conceptualization; Data curation; Methodology; Validation; Supervision; Roles/Writing - original draft; and Writing - review & editing. (ICMJE'S criteria: I; II; III; IV). All authors have had significant participation in the production of this manuscript, in alignment with the ICMJE recommendations: i) Substantial contributions to the conception or design of the work; or the acquisition, analysis, or interpretation of data for the work; ii) Drafting the work or revising it critically for important intellectual content; iii) Final approval of the version to be published; and iv) Agreement to be accountable for all aspects of the work in ensuring that questions related to the accuracy or integrity of any part of the work are appropriately investigated and resolved.

References

1. Zhu J, Wang X, Fang Y, Von den Hoff JW, Meng L. An update on the diagnosis and treatment of dens invaginatus. *Aust Dent J.* 2017 Sep;62(3):261-75. doi: 10.1111/adj.12513.

2. Alani A, Bishop K. Dens invaginatus. Part 1: classification, prevalence and aetiology. *Int Endod J*. 2008 Dec;41(12):1123-36. doi: 10.1111/j.1365-2591.2008.01468.x.
3. Schwartz SA, Schindler WG. Management of a maxillary canine with dens invaginatus and a vital pulp. *J Endod*. 1996 Sep;22(9):493-6. doi: 10.1016/S0099-2399(96)80086-0.
4. Kumar H, Al-Ali M, Parashos P, Manton DJ. Management of 2 teeth diagnosed with dens invaginatus with regenerative endodontics and apexification in the same patient: a case report and review. *J Endod*. 2014 May;40(5):725-31. doi: 10.1016/j.joen.2013.10.030. Epub 2013 Dec 15.
5. Kirzioğlu Z, Ceyhan D. The prevalence of anterior teeth with dens invaginatus in the western Mediterranean region of Turkey. *Int Endod J*. 2009 Aug;42(8):727-34. doi: 10.1111/j.1365-2591.2009.01579.x.
6. Bishop K, Alani A. Dens invaginatus. Part 2: clinical, radiographic features and management options. *Int Endod J*. 2008 Dec;41(12):1137-54. doi: 10.1111/j.1365-2591.2008.01469.x.
7. Gallacher A, Ali R, Bhakta S. Dens invaginatus: diagnosis and management strategies. *Br Dent J*. 2016 Oct;221(7):383-7. doi: 10.1038/sj.bdj.2016.724.
8. Genaro LE, Conte MB, Anovazzi G, Gonçalves A, Gonçalves MA, Capote TSO. Analysis of the Association of Foramen Cecum and Dens in Dente in Maxillary Lateral Incisor. *Eur J Dent*. 2021 May;15(2):242-6. doi: 10.1055/s-0040-1717157. Epub 2020 Oct 5.
9. Siqueira JF Jr, Rôças IN, Hernández SR, Brisson-Suárez K, Baasch AC, Pérez AR, et al. Dens Invaginatus: Clinical Implications and Antimicrobial Endodontic Treatment Considerations. *J Endod*. 2022 Feb;48(2):161-70. doi: 10.1016/j.joen.2021.11.014. Epub 2021 Dec 11.
10. Hernández SR, Pérez AR, Baasch AC, Brisson-Suárez K, Sellera DP, Ferrari PHP, et al. Management of teeth with dens invaginatus and apical periodontitis: A case series. *J Am Dent Assoc*. 2022 May;153(5):470-8. doi: 10.1016/j.adaj.2021.10.009.
11. Nagendrababu V, Chong BS, McCabe P, Shah PK, Priya E, Jayaraman J, et al. PRICE 2020 guidelines for reporting case reports in Endodontics: a consensus-based development. *Int Endod J*. 2020 May;53(5):619-26. doi: 10.1111/iej.13285.
12. Oehlers FA. Dens invaginatus (dilated composite odontome). I. Variations of the invagination process and associated anterior crown forms. *Oral Surg Oral Med Oral Pathol*. 1957 Nov;10(11):1204-18 contd. doi: 10.1016/0030-4220(57)90077-4.
13. Special Committee to Revise the Joint AAE/AAOMR Position Statement on use of CBCT in Endodontics. AAE and AAOMR Joint Position Statement: Use of Cone Beam Computed Tomography in Endodontics 2015 Update. *Oral Surg Oral Med Oral Pathol Oral Radiol*. 2015 Oct;120(4):508-12. doi: 10.1016/j.oooo.2015.07.033.
14. Leonardi Dutra K, Haas L, Porporatti AL, Flores-Mir C, Nascimento Santos J, Mezzomo LA, et al. Diagnostic accuracy of cone-beam computed tomography and conventional radiography on apical periodontitis: a systematic review and meta-analysis. *J Endod*. 2016 Mar;42(3):356-64. doi: 10.1016/j.joen.2015.12.015.
15. Cengiz SB, Korasli D, Ziraman F, Orhan K. Non-surgical root canal treatment of Dens invaginatus: reports of three cases. *Int Dent J*. 2006 Feb;56(1):17-21. doi: 10.1111/j.1875-595x.2006.tb00069.x.
16. Wayama MT, Valentim D, Gomes-Filho JE, Cintra LT, Dezan E Jr. 18-year follow-up of dens invaginatus: retrograde endodontic treatment. *J Endod*. 2014 Oct;40(10):1688-90. doi: 10.1016/j.joen.2014.01.047.
17. Ali A, Arslan H, Jethani B. Conservative management of Type II dens invaginatus with guided endodontic approach: A case series. *J Conserv Dent*. 2019 Sep-Oct;22(5):503-8. doi: 10.4103/JCD.JCD_30_20. Epub 2020 Aug 4.

18. Rivera-Peña ME, Duarte MAH, Alcalde MP, Furlan RD, Só MVR, Vivan RR. Ultrasonic tips as an auxiliary method for the instrumentation of oval-shaped root canals. *Braz Oral Res.* 2019 Feb 11;33:e011. doi: 10.1590/1807-3107bor-2019.vol33.0011.
19. Chalub LO, Nunes GP, Strazzi-Sahyon HB, Ferrisse TM, Dos Santos PH, Gomes-Filho JE, et al. Antimicrobial effectiveness of ultrasonic irrigation in root canal treatment: a systematic review of randomized clinical trials and meta-analysis. *Clin Oral Investig.* 2023 Apr;27(4):1343-61. doi: 10.1007/s00784-023-04897-4.
20. Shahravan A, Nekouei AH. Does ultrasonic activation of irrigation during endodontic therapy improve the clinical and microbiological effects? *Evid Based Dent.* 2022 Sep;23(3):118-9. doi: 10.1038/s41432-022-0819-9.
21. Pereira KFS, da Silva SO, Bastos HJS, Tomazinho LF, do Nascimento VR, Junqueira-Verardo LB, et al. Bioceramic cements: supporting in remineralization of osteolytic lesions in endodontic-periodontal diseases: a report of two cases. *Iran Endod J.* 2023;18(4):264-70. doi: 10.22037/iej.v18i4.41437.
22. Donnermeyer D, Bürklein S, Dammaschke T, Schäfer E. Endodontic sealers based on calcium silicates: a systematic review. *Odontology.* 2019 Oct;107(4):421-36. doi: 10.1007/s10266-018-0400-3. Epub 2018 Dec 15.