

Clinico-epidemiological Aspects of Cutaneous Lesions in Injecting Drug Users Visiting an Oral Substitution Therapy Centre in Northern India: A Cross-Sectional study

Shaminder Singh Dhillon¹, Tejinder Kaur¹, Neeru Bala¹, Mankaranpreet¹

¹ Department of Skin & VD, Government Medical College, Amritsar, Punjab, India

² Department of Psychiatry, Government Medical College, Amritsar, Punjab, India

Key words: intravenous drug users, oral substitution therapy centers, skin manifestations, dermoscopic findings

Citation: Dhillon SS, Kaur T, Bala N, Mankaranpreet. Clinico-epidemiological aspects of cutaneous lesions in Injecting Drug Users visiting an Oral Substitution Therapy Centre in Northern India: a cross-sectional study. *Dermatol Pract Concept*. 2022;12(4):e2022154. DOI: <https://doi.org/10.5826/dpc.1204a154>

Accepted: March 3, 2022; **Published:** October 2022

Copyright: ©2022 Dhillon et al. This is an open-access article distributed under the terms of the Creative Commons Attribution-NonCommercial License (BY-NC-4.0), <https://creativecommons.org/licenses/by-nc/4.0/>, which permits unrestricted noncommercial use, distribution, and reproduction in any medium, provided the original authors and source are credited.

Funding: None.

Competing interests: None.

Authorship: All authors have contributed significantly to this publication.

Corresponding author: Tejinder Kaur, Professor & Head, Department of Skin & VD, Government Medical College, Amritsar, Punjab, India. E-mail: tejinderkaurdr@gmail.com

ABSTRACT **Introduction:** Drug abuse has been taking a great toll on the health and well-being of the community for the past few decades. Substance abuse can lead to several cutaneous manifestations as direct injuries by the offending drug or the practices of drug usage cause secondary damage to the skin. The early recognition of these signs is of utmost importance to prevent long-term complications.

Objectives: To study the clinical-epidemiological profile of the skin diseases in Injecting Drug Users (IDU) attending an Oral Substitution Therapy (OST) Center in Northern India and to assess the psychological impact of skin conditions in IDUs attending OSTs.

Methods: This cross-sectional observational study involved 100 IDUs enrolled from the OST center who were subjected to brief history taking and clinical and dermoscopic evaluation of skin lesions. Dermatological quality of life index (DLQI), Depression, Anxiety, Stress Scale (DASS), and WHO-quality of life (QoL) questionnaire were used to evaluate the impact of skin lesions on psycho-social health and QoL of IDUs.

Results: Cutaneous lesions ranged from track marks to severe ulcerations and scarring. Mucosal lesions also took a toll on several patients. The patients had varying degrees of anxiety, depression, and mental stress.

Conclusions: Injecting Drug Abusers are prone to acquire skin diseases due to injury caused by drugs as well as by drug practices adopted and the degree of neglect may worsen these conditions. These cutaneous lesions hamper QoL and cause psychosocial disturbances.

Introduction

The WHO defines Drug abuse/Substance abuse as harmful or hazardous use of psychoactive substances, including alcohol and illicit drugs. Psychoactive substances are the pharmacological agents that alter the behavioral, cognitive, and physiological changes in the body that, on repeated use, lead to a phenomenon referred to as dependence syndrome. This includes a strong desire for the drug, impulse, and repeated use despite harmful effects. A high priority is given to drug use than to other activities and obligations, increased tolerance, and sometimes a physical withdrawal. No part of the world is free of drug abuse in the current times [1]. The advent of globalization has led to several variations in the culture and economic backgrounds in Indian population. Alongside positive implications, certain social drawbacks like substance abuse are an important measure to be taken care of. Several criminal acts and antisocial behaviors have been associated with drug abuse [2]. Several steps and special task forces are being generated by the Indian government at both the national and state level. Despite all the measures taken by the government and society drug abuse is one of the leading causes of crime in India. India is surrounded by the world's leading illicit drug-producing countries namely Thailand, Laos, and Myanmar constituting the golden triangle on the eastern side. Similarly, Afghanistan, Iraq, and Pakistan which constitute the golden crescent are located on the western borders of the nation. Thereby the incidence of substance abuse is on the rise especially in states like Punjab which has close geographic contact with the above-mentioned western border [3]. Drug abuse has several implications on human health and society. These include a weak immune system, increasing rates of malnutrition, and related disorders due to neglect, weight, and appetite loss. The toxicity of these drugs can lead to several hepatic and heart diseases. Neuronal damage may result in behavioural and cognitive disorders [4].

Besides involving these systems, substance abuse can lead to several cutaneous manifestations as well which could be either due to direct injury by the offending drug or the practices of drug usage can cause secondary damage to the skin structure or even a presentation of medical complication due to drug abuse visible on the skin [5]. The early recognition of these signs is of utmost importance to prevent long-term complications like necrosis. To ease the understanding, we have tried to classify the presentations.

Classification of Skin Manifestations:

- a. Injection-related/local effects.
- b. Infections: superficial, deep, viral disease transmission.
- c. Vascular complications.

1. Injection-related effects: most commonly encountered lesions in Injecting Drug Users (IDU) are the track marks mostly seen on the arms and especially over the antecubital fold [6]. These represent the sclerosed vessels resulting from localized thrombophlebitis due to an irritant drug being abused and extravasated. The dark color at the site is due to the post-inflammatory hyperpigmentary changes occurring in the skin with an underlying affected vessel.

Skin popping: Administering drugs into the skin may result in deep punched out ulcers which heal with atrophy. These ulcers usually get secondarily affected to form large ulcers which heal slowly [7].

2. Infections: skin and soft tissue infections are common in IDUs due to their injection practices and weakened immune systems. *Staphylococcus aureus* and streptococcal species which are normal commensals over skin enter the deeper tissues resulting in abscesses and cellulitis [8]. Moreover there are several impurities and adulterants in drugs that have deleterious effects on skin structures. Several uncommon pathogens such as *Clostridium* and *Eikenella* which reside in the oral cavity can result in superficial and deep-seated abscesses. Wound botulism, necrotizing fasciitis and tetanus can occur due to clostridial toxins usually in the skin poppers in whom inoculation of bacilli occurs in relatively anaerobic conditions such as skin which favors their growth and toxin production [9,10]. Use of nonsterile needles poses certain threats of various viral infections including Human immunodeficiency virus (HIV) and Hepatitis B and C viruses [11]. These infections can have various skin manifestations ranging from acute maculopapular rash to chronic skin diseases [12,13].

3. Vascular complications: repeated trauma to the veins leads to vessel wall changes causing thrombophlebitis and venous thrombosis. This leads to venous incompetence and ulcerations may ensue. Furthermore, lymphatic drainage may get compromised due to lymphatic damage deteriorating the picture and leading to chronic edema of the limb [14].

Accidental intra-arterial injections may result in ischemic changes due to drugs or adulterants. Some of the drugs such as cocaine are vasoconstrictors that can result in vasospasms and compromising the blood supply to a unit resulting in its necrosis. Drug-induced vasospasm and thrombosis may result in acute pain and burning sensation in the limb and further leading to edema and cyanosis. Scrotal necrosis is seen in pudendal artery thrombosis [15]. There are reports of penile ulceration following drug administered into dorsal penile vein [16]. Intravenous abuse of cocaine may result in secondary Raynaud phenomenon and digital ulcerations and infarction in organs like the liver and kidney.

Pseudoaneurysms and mycotic aneurysms can develop following vascular injuries and infections may develop in the vessel walls. A pulsatile or non-pulsatile mass may be seen in the distribution of a vessel which may be wrongfully considered as an abscess and if incised may result in fatal outcomes [17]. These aneurysms are generally infected by bacteria such as staphylococcus and streptococcus species. In some instances, *Candida albicans* may be the infectious agent [18].

Objectives

Primary Objective

1. To study the clinical-epidemiological profile of the skin diseases in IDUs attending Oral Substitution Therapy (OST) center in Northern India.

Secondary Objectives

1. To assess the socio-demographic profile of IDUs.
2. To assess the psychological impact of skin conditions in IDUs attending oral substitution therapy center.
3. To assess the quality of life (QoL) of IDUs attending oral substitution therapy center.

Methods

A total of 100 IDUs visiting the OST center at the Government Medical College, Amritsar, in Northern India who met the inclusion criteria were randomly enrolled in the study.

Inclusion criteria:

1. IDUs of both sex and aged more than 18 years.
2. IDUs visiting OST centers who gave consent for the study.

Exclusion criteria:

1. IDUs of drug abuse employing routes other than intravenous.
2. IDUs not giving consent for the study.
3. IDUs with other primary dermatoses.
4. IDUs with organic mental disorders or known significant medical conditions.

After signing written informed consent, a brief history regarding their drug abuse – duration, type of drug, and route of administration - was enquired from patients. History of any skin disease before IDU abuse was asked. A thorough clinical examination was done after full body exposure. Bed-side tests for skin diseases if required were done. Lesions were examined clinically and with dermoscope as well.

Questionnaires regarding the Dermatological QoL Index (DLQI) were filled to know about the impact of skin

conditions. Secondly, the Depression, Anxiety, Stress Scale (DASS) questionnaire for assessing the psychological status of patients on de-addiction therapy was filled. Thirdly, a WHO QoL index questionnaire was used to look into the overall QoL of these patients visiting the OST center. At last, the results were tabulated and statistically analyzed.

Results

In our study, we observed that the mean age of the IDUs was 30.08 with a majority in the age group of 21-30 years. Among the study group, 98 were males and 2 were females. Laborers accounted for the majority being 33% and 17 were drivers; the rest of the IDUs had several other professions. All the IDUs had heroin abuse while 8 had concomitant cocaine and 3 had cannabis addiction as well. The mean duration of drug abuse among the IDUs was 8.34 years while the maximum duration of injectables observed for the past was 1 to 5 years. In the study group, the last dose of the abused drug taken was less than one month in 76% while others had a lapse time of more than 1 month. Among the IDUs, 99 were being managed with buprenorphine and naloxone combination sublingual tablets and one was being given oral methadone. The literacy rate varied from 12/100 being illiterate to 8/100 being graduate (with a graduation degree in any field) and the rest had education level between primary to senior secondary education. Thirty-eight patients had income less than 10,000, 50 had 10,000 to 20,000 and 12 had more than 20,000 Indian rupees. Fifty-two IDUs were unmarried, 46 were married and 2 were divorced. A history of smoking was present in 57/100, while 82/100 were alcoholics. Of the 100 IDUs, 80 were positive for hepatitis C virus (HCV) infection, 10 had HIV infection and among them, 9 had concomitant HCV and HIV positivity. One among them had type 1 insulin-dependent diabetes mellitus, 1 was hypertensive, 1 had chronic kidney disease (Tables 1 and 2).

In the study group, 84 patients had black-colored spots and scars over their body, 34 reported a history of chronic itching and 6 had ulcers over various body parts. The duration of these complaints ranged from few months to several years. These lesions were clustered around upper limbs in 88% of all followed by 8% over lower limbs and 4% over the other body parts. Eight patients had a history of concomitant joint pains. Among these patients, 38% received topical or oral treatment. The commonly used topical agent was clobetasol cream and an oral agent was an antihistamine. Seven patients were on Highly Active Anti Retro Viral Therapy (HAART) and 2 were taking Anti Hepatitis C therapy (lepidasvir and sofosbuvir).

On examination, 92 patients had track marks, 54 had hesitation marks, 53 had tattoos while small round atrophic scars were present in all the patients. Scabies was the most

Table 1. Socio-Demographic Profile of the injecting drug users visiting Oral Substitution Therapy centers.

Age (Years)	N. of cases	Percentage
< 20	4	4.0%
21-30	53	53.0%
31-40	38	38.0%
> 40	5	5.0%
Sex		
Female	2	2.0%
Male	98	98.0%
Address (Rural/Urban)		
Rural	21	21.0%
Urban	79	79.0%
Marital Status		
Divorced	2	2.0%
Married	46	46.0%
Unmarried	52	52.0%
Education		
Diploma	2	2.0%
Elementary	18	18.0%
Graduate	8	8.0%
Illiterate	12	12.0%
Matriculation	23	23.0%
Primary	24	24.0%
Senior Secondary (post matriculation)	13	13.0%
Income (in Rupee)		
< 5000	11	11.0%
5000-10000	27	27.0%
> 10000	62	62.0%
Drug Abused		
Cocaine and heroin	8	8.0%
Heroin	89	89.0%
Heroin and cannabis	3	3.0%
Duration of abuse (years)		
0-5.0	29	29.0%
6-10.0	47	47.0%
> 10	24	24.0%
Treatment given		
Buprenorphine	99	99.0%
Methadone	1	1.0%
Smoking		
Absent	43	43.0%
Present	57	57.0%

Table 2. Chronic conditions and co-morbidities in injecting drug users.

Past Illness	N of cases	Percentage
Chronic kidney disease	1	1.0%
Hip joint surgery	1	1.0%
Pulmonary tuberculosis	1	1.0%
Type-1 diabetes	1	1.0%
Urticaria	1	1.0%
Urinary tract infection	1	1.0%
None	94	94.0%
Diabetes mellitus		
None	99	99.0%
Present	1	1.0%
Hypertension		
None	99	99.0%
Present	1	1.0%
HIV		
Negative	90	90.0%
Positive	10	10.0%
HBsAg	No. of cases	Percentage
Negative	100	100.0%
HCV	No. of cases	Percentage
Negative	20	20.0%
Positive	80	80.0%

HBsAg = hepatitis B surface antigen; HCV = hepatitis C virus; HIV = human immunodeficiency virus.

common skin disease affecting 23 patients of which nine had nodular lesions as well. Superficial dermatophytosis was seen in 12 patients. Six patients had facial melanosis, 4 had intertrigo, 2 had acne vulgaris and 2 had balanitis. Other skin and soft tissue ailments present were hyperhidrosis, urticaria, thrombophlebitis, acneiform eruptions, verrucae, and genital herpes (Table 3).

Angular cheilitis was seen in 2 patients, 45 had pigmentation over lips and seven had depigmented patches over the lips. Examination of buccal mucosa revealed bluish-black pigmentation in 77 patients and erosions in five ones. Dirty yellowish-brown staining over teeth was present in 69 patients and 2 had dental caries. On examination of the gingivolabial sulcus, 33 had pigmentary changes, 24 had Sub Mucosal Fibrosis, 8 had leukoplakia and 3 had cobblestone mucosa.

Hair examination revealed trichomycosis in 2 patients, generalized sparsity in 2 subjects, and andro-genetic alopecia in 1. Longitudinal melanonychia was the most common nail abnormality observed seen in 29 IDUs. A brownish discolored nail plate was seen in 4 IDUs, 3 ones had dystrophic nails, 2 had koilonychia and 1 had paronychia (Table 4).

Table 3. Skin conditions encountered in injecting drug users.

Skin Lesions Description	N of cases	Percentage
Track Marks	92	92.0%
Atrophic Scars	100	100.0%
Hesitation Marks	54	54.0%
Tattoos	53	53.0%
Others		
Acne vulgaris	2	2.0%
Acneiform eruptions, intertrigo	1	1.0%
Atrophic scars in groins and nodular scabies	1	1.0%
Balanitis	2	2.0%
Cholinergic urticaria	1	1.0%
Extensive Tinea corporis	1	1.0%
Facial melanosis	5	5.0%
Folliculitis, scabies	2	2.0%
Herpes genitalis	1	1.0%
Hyperhidrosis, tightness of skin	1	1.0%
Intertrigo	2	2.0%
Intertrigo, facial melanosis	1	1.0%
Keratosis pilaris	1	1.0%
Large atrophic scars on bilateral thighs	1	1.0%
Mottled pigmentation and hyperkeratosis on palms	1	1.0%
Post herpetic zosteriform scars	1	1.0%
Scabies	11	11.0%
Scabies and acne corporis	1	1.0%
Scabies nodular	8	8.0%
Scars in groin and pubic region	1	1.0%
Sebaceous cysts scrotum	1	1.0%
Seborrheic keratosis and facial melanosis	1	1.0%
Soft tissue swelling	1	1.0%
Thrombophlebitis	1	1.0%
Tineacorporis Cruris and facial melanosis	1	1.0%
Tineacorporis Cruris and ulcer on right palm, soft tissue swelling on right arm	1	1.0%
Tinea corp., scabies with folliculitis	1	1.0%
Tineacorporis	1	1.0%
Tineacorporis with ulcers	1	1.0%
Tineacurris	1	1.0%
Tineacurris, facial melanosis	1	1.0%
Trichomycosis	1	1.0%
Ulcer non-healing on left leg	1	1.0%
Ulcer on arm	1	1.0%
Ulcer over hand and facial melanosis	1	1.0%
Ulcers on left forearm	1	1.0%
Ulcers on thighs, hands and feet, xanthelasma palpebrum	1	1.0%
Warts on hands	1	1.0%
None	37	37.0%
Total	100	100.0%

Table 4. Oral and skin appendageal conditions seen in injecting drug users.

Mucosal Lesions_Lips	No. of cases	Percentage
Angular cheilitis	2	2.0%
Depigmented patches	7	7.0%
Discoloration	45	45.0%
None	46	46.0%
Total	100	100.0%
Buccal mucosa lesions		
Erosions	1	1.0%
Pigmentation	77	77.0%
None	22	22.0%
Total	100	100.0%
Mucosal Lesions_Teeth		
Caries	2	2.0%
Stained	69	69.0%
None	29	29.0%
Total	100	100.0%
Mucosal Lesions_Gingivolabial Sulcus		
Cobblestoning	3	3.0%
Erosions	1	1.0%
Gingival ulcer, SMF and pigmentation	1	1.0%
Gum recession with gingival erosion and leukoplakia	1	1.0%
Leukoplakia	7	7.0%
Micro erosions over labial mucosa, recession of gums	1	1.0%
Pigmentation	33	33.0%
Pigmentation, SMF	24	24.0%
SMF	6	6.0%
None	23	23.0%
Total	100	100.0%
Hair	No. of cases	Percentage
Androgenetic alopecia	1	1.0%
Sparsity	2	2.0%
Trichomycosis	2	2.0%
None	95	95.0%
Total	100	100.0%
Nails	No. of cases	Percentage
Clubbing	1	1.0%
Discolored	4	4.0%
Dystrophic nail	2	2.0%
Koilonychia	2	2.0%
Leukonychia	1	1.0%
Long, Melanonychia	29	29.0%
Onychomycosis	1	1.0%
Paronychia, longitudinal Melanonychia	1	1.0%
None	59	59.0%
Total	100	100.0%

SMF = submucosal fibrosis

Table 5. Psychological aspects and quality of life Parameters of injecting drug users.

DLQI Score (Dermatology Life Quality Index)		N of cases		Percentage	
0-1.0		0		0.0%	
2-5.0		26		26.0%	
6-10.0		54		54.0%	
11-20.0		20		20.0%	
21-30.0		0		0.0%	
Depression		No. of cases		Percentage	
0		90		90.0%	
1		5		5.0%	
2		3		3.0%	
3		1		1.0%	
4		1		1.0%	
Total		100		100.0%	
Anxiety		No. of cases		Percentage	
0		84		84.0%	
1		9		9.0%	
2		4		4.0%	
3		2		2.0%	
4		1		1.0%	
Total		100		100.0%	
Stress		No. of cases		Percentage	
0		73		73.0%	
1		13		13.0%	
2		9		9.0%	
3		3		3.0%	
4		2		2.0%	
Total		100		100.0%	
WHO-QOL	N	Minimum	Maximum	Mean	Std. Deviation
Age (Years)	100	19.00	60.00	30.08	6.53
Duration of Abuse (Years)	100	2.00	18.00	8.34	3.77
DLQI Score	100	2.00	18.00	7.88	3.28
WHO - QOL (BREF)_Domain 1	100	38.00	50.00	42.92	3.75
WHO - QOL (BREF)_Domain 2	100	31.00	44.00	34.35	4.92
WHO - QOL (BREF)_Domain 3	100	31.00	69.00	47.06	11.69
WHO - QOL (BREF)_Domain 4	100	31.00	44.00	37.50	3.89

DLQI revealed moderate effect (score 6-10) on QoL due to skin affection in 54% of patients, followed by mild effect (score 2-5) in 26% and very large effect (score 11-20) in 20 patients. Depression Anxiety Stress Score revealed extremely severe depression in 1, severe in 1, moderate in 3, and mild depression in 1 IDU. Anxiety observed was extreme in 1, severe in 2, moderate in 4, and mild in 9. The stress index showed extreme stress in 2, severe in 3, moderate in 9, and mild in 13.

WHOQ-OL questionnaire was used which gave a mean of 42.92, 34.35, 47.06, 37.50, with a standard deviation

(SD) of 3.75, 4.92, 11.69, and 3.89 in Domain 1, 2, 3, and 4, respectively (Table 5).

Conclusions

Drug abuse has been taking a great toll on the health and well-being of the community for the past few decades. A rise in injecting drug abuse has been posing threat to the individual health and thus to QoL. Skin is among the neglected organs among IDUs and the tendency of neglect increases with the duration of abuse [19]. Track marks are linear or

closely spaced needle pricks seen as black dots on the skin overlying veins in IDUs. (Figure 1). These are among the most common and absolute signs seen in active IDUs. There can be surrounding erythema or induration which depicts inflammatory reaction either due to extravasated drug or infection in the intradermal or subcutaneous tissue. Thrombophlebitis can be associated with track marks at times and can lead to cellulitis if not taken care of. On dermoscopic examination, these are seen as black dots or hemorrhages, comedones-like or plug arranged linearly with bluish-black to the erythematous background (Figure 2). Small rounded atrophic scars are another hallmark of injecting drug abuse. These are a result of skin popping that form small ulcers which heal with atrophy. In patients with the tendency to keloid formation, large nodular lesions may be seen instead of atrophic scars.

Among the infections and infestations, scabies was the most common disease encountered and the level of neglect further poses a threat to its treatment. Poor hygiene is a significant risk factor to acquire scabies besides deranged itch-scratch cycle, relatively immune-compromised status are other contributory factors. The diagnosis of scabies may be at times missed by psychiatrists and thought to be related to drug abuse- delusion of parasitosis [20]. In such instances full body exposure and site-specific examination may reveal burrows of mite and clinches the diagnosis. Superficial dermatophytosis, a fungal infection, is another common infection encountered among IDUs which presents as round and annular itchy plaques over the body (Figure 3). Other infections include bacterial folliculitis and infected wounds.

Viral disease transmission is common among IDUs due to sharing of syringes due to which there is an increased rate

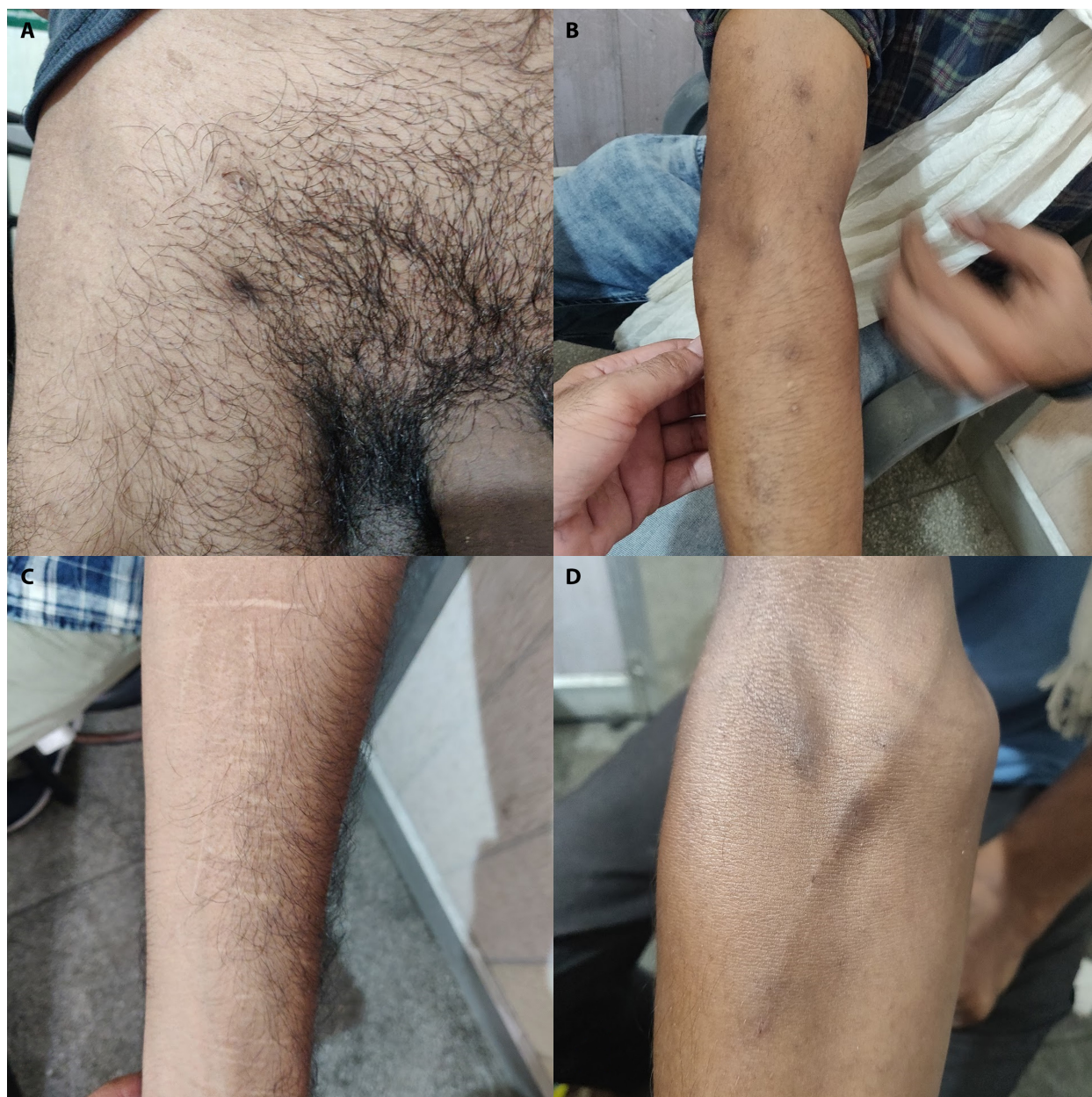

Figure 1. (A) Multiple depressed scar marks over inguinal region. (B) Skin popping marks. (C) Hesitation marks. (D) Track marks.

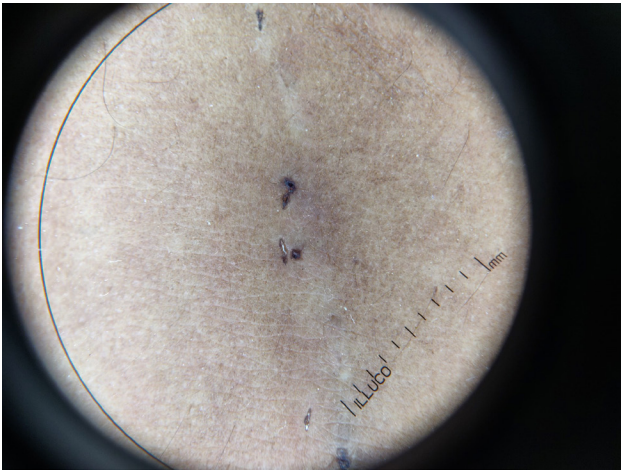


Figure 2. On dermoscopic examination (100X. ILLUCO), black dots or hemorrhages, comedones like or plug arranged linearly with bluish-black and brownish to reddish white background.

of incidence of viral Hepatitis and HIV-AIDS among them [21]. In our study, the majority of the patients were positive for HCV and HIV. This draws attention to checking the behavior and actions of IDUs and adopting measures preventing them.

The oral cavity is yet another area to be stressed upon in IDUs as they tend to be smokers, alcoholics, and tobacco abusers with poor oral hygiene and the degree of neglect they have may pose drastic effects such as oral malignancies [22,23]. The changes observed in our studies included pigmentation related to nicotine and depigmented patches too can be toxic reactions to the melanocytes. The gingivobial mucosa was the most exploited area in the oral cavity due to the habit of keeping the tobacco pouch undersurface of the lip and most patients had pigmentary changes, erosions, and submucosal fibrosis and few had leukoplakia and

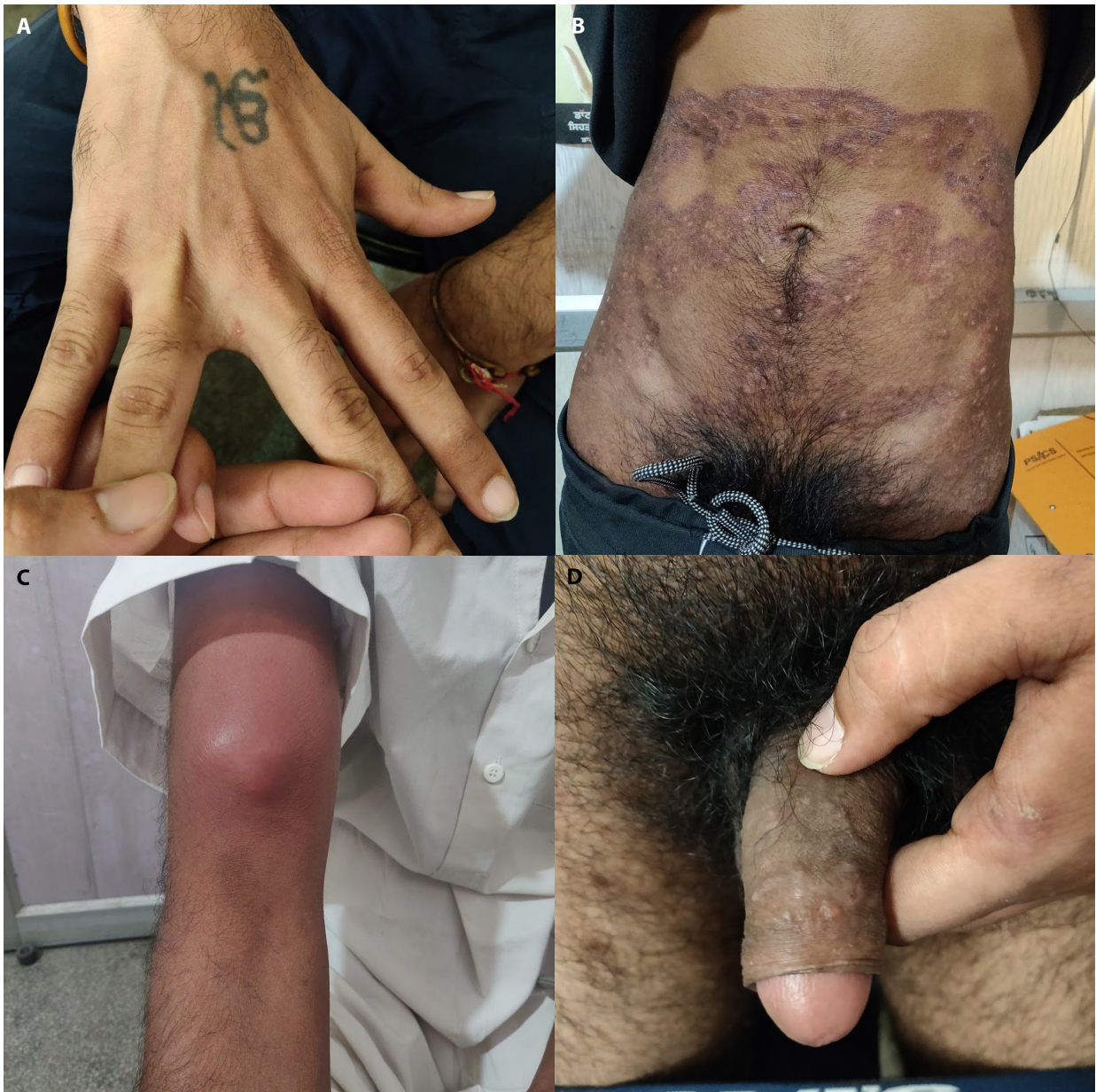

Figure 3. (A) Scabies mite burrows. (B) Extensive TineaCorporis. (C) Soft tissue swelling of arm (patient was T1 DM). (D) Herpes genitalis.

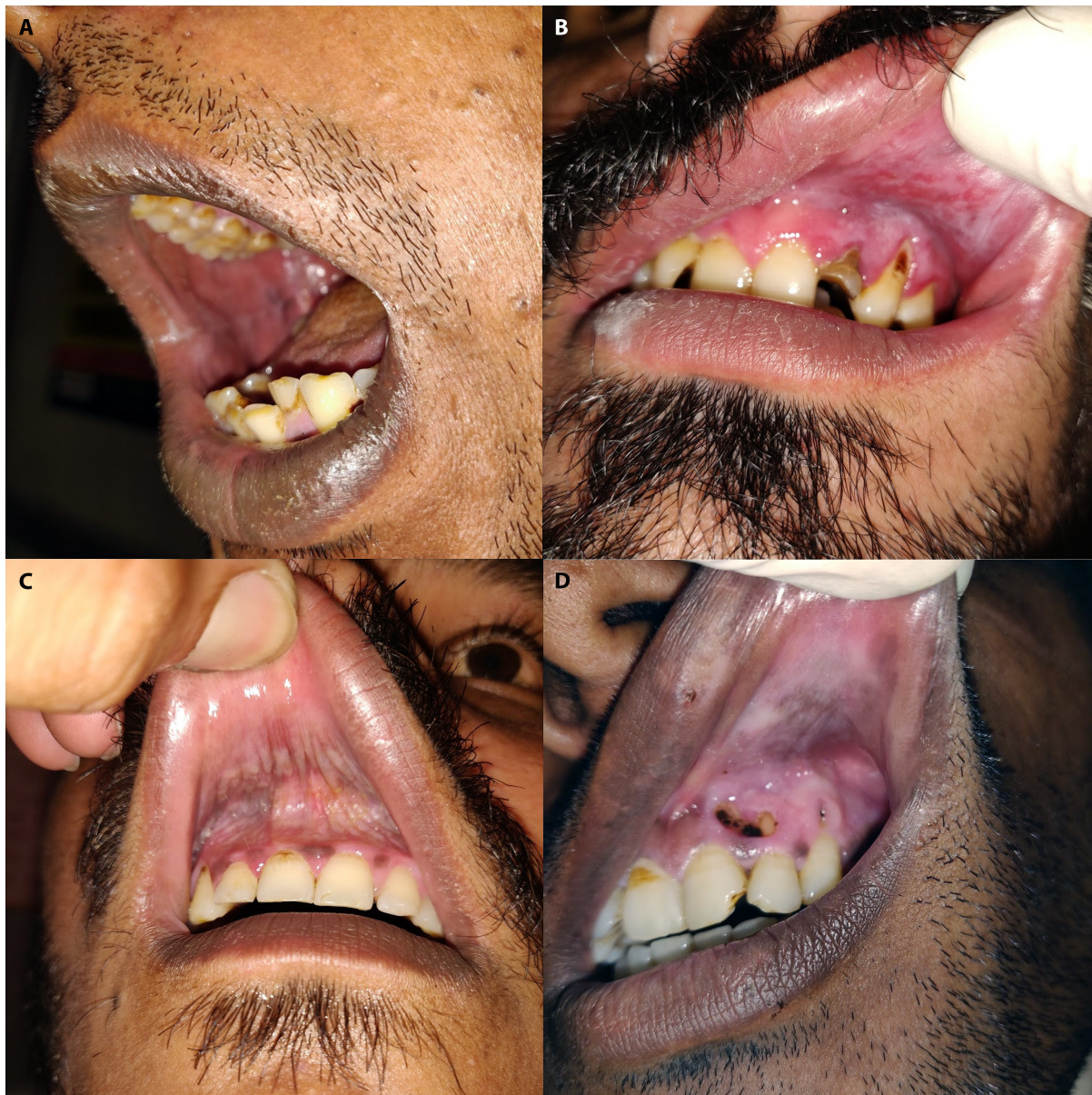

Figure 4. (A) Oral cavity pigmentation with caries teeth. (B) Cobble-stoning of gingivolabial sulcus with erosions. (C) Submucosal fibrosis with leukoplakia. (D) Gingivolabial mucosal fibrosis with ulceration.

cobble-stoning which tend to be premalignant conditions and may lead to drastic situations if not addressed accordingly (Figure 4).

In the assessment of QoL related to dermatological conditions, the dermatology QoL index has proven to be a good tool [24]. In our study, a majority of IDUs had moderately hampered life quality which means the skin conditions either due to the direct effect of drugs or secondary involvement has brought about changes in the daily routine of IDUs which can be social, psychological, or economic encroachment.

Similarly, the mental state of the patients was assessed by the Depression Anxiety Stress scale which is a crude and partially objective method of assessment of the inner horizon of patients. It revealed a significant alteration in the mental state of the IDUs.

The study had several limitations like the fact that the confirmatory diagnosis of the skin disorders was not established due to short interaction between patient and doctor and unavailability of investigations at the OST center. The second bias was the neglect shown by the IDUs towards skin conditions which lead to a certain degree of concealment of skin conditions. Thirdly, many IDUs did not consent for the full body examination leading to missing some important areas of examination like genitalia and groins which are potential sites for infections and sexually transmitted infections as well as spots of drug injection. Lastly, it was not a case control study and hence statistics could not be performed; moreover, the number of study patients was limited. These limitations can be overcome by bringing together the two specialties of de-addiction and Dermatology and stressing

over the need for periodic examination of the skin of IDUs to look for any direct or indirect effects of drug abuse.

Skin conditions occurring in IDUs are a result of direct injury to the skin by the offending drug or by the methods used to introduce drug into body. Track marks resulting from repeated intravenous drug abuse are the commonest occurrence followed by atrophic rounded scars due to drug popping into the skin. Infectious conditions of the skin are common which occur either because of the contaminated drug or by the neglect of an IDU in receiving treatment. Hesitation marks seen in a large number of candidates relate well with altered mental condition of the IDUs. Drugs and altered mental state form a vicious cycle such that it almost becomes impossible for IDUs to maintain a sound conscience and psychological and physical dependence further takes its toll. Thus, dermatologists and psychologists should collaborate to address the healthcare needs of an IDU so that timely necessary actions can be taken.

References

1. Ahmed N, Bano R, Agarwal V K, Kalakoti P. Substance abuse in India. *Pravara Med Rev.*2009;1(4).
2. Pierce M, Hayhust K, Bird M, et al. Insights into link between drug use and criminality: Lifetime offending of criminally active opiate users. *Drug Alcohol Depend.* 2017;179:309-316. DOI: 10.1016/j.drugalcdep.2017.07.024. PMID: 28837946. PMCID: PMC5608072.
3. Gupta VK, Kaur P, Singh G, Kaur A, et al. A study of profile of patients admitted in the drug de-addiction centres in state of Punjab. *Int J Res Health Sci.* 2013;vol 1:issue 2.
4. Fox TP, Oliver G, Ellis SM. The destructive capacity of drug abuse: an overview exploring the harmful potential of drug abuse both to the individual and society. *ISRN Addict.* 2013;2013:450348. DOI: 10.1155/2013/450348. PMID: 25938116. PMCID: PMC4392977.
5. Henning C, Miller J. Illicit drugs: what dermatologists need to know. *J Am Acad Dermatol.* 2013;69(1):135-142. DOI: 10.1016/j.jaad.2012.12.968. PMID: 23399461.
6. Khalsa JH, Triesman G, McCance-Katz E, Tedaldi E. Medical consequences of abuse and co-occurring infections. *Subst Abuse.* 2008;29(3):5-16. DOI: 10.1080/08897070802218661. PMID: 19042203. PMCID: PMC2654580.
7. Del Giudice P. Cutaneous complications of intravenous drug abuse. *Br J Dermatol.* 2004;150(1):1-10. DOI: 10.1111/j.1365-2133.2004.05607.x. PMID: 14746612.
8. Binswanger IA, Kral AH, Bluthenthal KN, Rybold DJ, Edlin BR. High prevalence of abscesses and cellulitis among community-recruited injection drug users in San Francisco. *Clin Infect Dis.* 2000;30(3):579-581. DOI: 10.1086/313703. PMID: 10722447.
9. Olopoenia LA, Mody V, Reynolds M. Eikenella corrodens endocarditis in an intravenous drug user: a case report and literature review. *J Natl Med Assoc.*1994;86:313-315. PMID: 8040909. PMCID: PMC2607643.
10. Cooper JG, Spike CE, Denton M, Jamieson S. Clostridium botulinum: an increasing complication of heroin misuse. *Eur J Emerg Med.* 005;12:251-252. DOI: 10.1097/00063110-200510000-00011. PMID: 16175065.
11. Drug use and viral infections (HIV, Hepatitis) drug facts. National Institute on drug abuse.16 Jun 2020. Available from www.drugabuse.gov/publications/drugfacts/druguse-viral-infections, accessed on September 2020
12. Altman K, Vanness E, Westergaard PR. Cutaneous manifestations of Human immune deficiency virus: a clinical update. *Curr Infect Dis Rep.* 2015;17(3):464. DOI: 10.1007/s11908-015-0464-y. PMID: 25821188. PMCID: PMC4447481.
13. Jones MA, Warken K, Tying SK. The cutaneous manifestations of viral hepatitis. *Dermatol Clin.* 2002;20(2):233-247, vi. DOI: 10.1016/s0733-8635(01)00010-9. PMID: 12120438.
14. Pieper B, Kirsner RS, Templin TN, Birk TJ. Chronic venous disease and injection drug use. *Arch Intern Med.* 2007;167(16):1807. DOI: 10.1001/archinte.167.16.1807-a. PMID: 17846403.
15. Somers WJ, Lowe FC. Localized gangrene of the scrotum and penis: a complication of heroin injection into the femoral vessels. *J Urol.* 1986;136(1):111-113. DOI: 10.1016/s0022-5347(17)44750-1. PMID: 3712594.
16. White WB, Barrett S. Penile ulcer in heroin abuse: a case report. *Cutis.* 1982;29: 62-3, 69. PMID: 7056068.
17. Georgiadis G, Bessias NC, Pavlidis PM, Pomoni M, Batakis N, Lazarides MK. Infected false aneurysms of the limbs secondary to chronic intravenous drug abuse: analysis of perioperative considerations and operative outcomes. *Surg Today.* 2007;37(10):837-844. DOI: 10.1007/s00595-006-3495-z. PMID: 17879032.
18. Kokovski L, Butany J, Nair V. Femoral artery pseudoaneurysm due to Candida albicans in an injection drug user. *Cardiovasc Pathol.* 2014;23(1):50-53. DOI: 10.1016/j.carpath.2013.07.003. PMID: 24012013.
19. Smith ME, Robinowitz N, Chaulk P, Johnson KE. Self-care and risk reduction habits in older injection drug users with chronic wounds: a cross-sectional study. *Harm Reduct J.* 2014;11(1):28. DOI: 10.1186/1477-7517-11-28. PMID: 25326686. PMCID: PMC4213493.
20. Elepern DJ. Cocaine abuse and delusions of parasitosis. *Cutis.* 1988;42:273-274. PMID: 3234026.
21. Degenhardt L, Peacock A, Colledge S, et al. Global prevalence of injecting drug use and sociodemographic characteristics and prevalence of HIV, HBV, and HCV in people who inject drugs: a multistage systematic review. *Lancet Glob Health.* 2017 Dec;5(12):e1192-e1207. DOI: 10.1016/S2214-109X(17)30375-3. PMID: 29074409. PMCID: PMC5683738.
22. Liu SW, Lien MH, Fenske NA. The effects of alcohol and drug abuse on the skin. *Clin Dermatol.* 2010;28(4):391-399. DOI: 10.1016/j.clindermatol.2010.03.024. PMID: 20620755.
23. Brewer JD, Meves A, Bostwick JM, Hamacher KL, Pittelkow MR. Cocaine abuse: Dermatological manifestations and therapeutic approaches. *J Am Acad Dermatol.* 2008;59(3):483-487. DOI: 10.1016/j.jaad.2008.03.040. PMID: 18467002.
24. Chen SC. Dermatology Quality of Life instruments: sorting out the quagmire. *J Invest Dermatol.* 2007;127(12):2695-2696. DOI: 10.1038/sj.jid.5701176. PMID: 18007683.