

Dermatoscopic Changes in Melanocytic Nevi After Intense Pulsed Light Treatment for Hair Removal: A Case Series

Nicoleta Neagu¹, Caterina Dianzani², Gianluca Avallone³, Iris Zalaudek⁴, Domenico Piccolo⁵, Giovanni Pellacani⁶, Sebastian Laspina⁷, Claudio Conforti⁸

1 Department of Epidemiology, University of Medicine, Pharmacy, Science and Technology 'George Emil Palade' of Târgu Mureș, Târgu Mureș, Romania

2 Plastic and Reconstructive Surgery Unit, Campus Bio-Medico University of Rome, Rome, Italy

3 Section of Dermatology, Department of Medical Sciences, University of Turin, Turin, Italy

4 Department of Dermatology, Maggiore Hospital, University of Trieste, Trieste, Italy

5 Skin Center-Dermo Aesthetic Laser Centers, Avezzano, Pescara and L'Aquila, Italy

6 Dermatology Unit, Department of Clinical Internal Anesthesiological and Cardiovascular Sciences, "Sapienza" University of Rome, Rome, Italy

7 Private practice, CLDL, Udine, Italy

8 IDI-IRCCS, Dermatological Research Hospital, Rome, Italy

Key words: intense pulsed light, nevi, post laser treatment, hair removal, dermoscopy

Citation: Neagu N, Dianzani C, Avallone G, et al. Dermatoscopic Changes in Melanocytic Nevi After Intense Pulsed Light (IPL) Treatment for Hair Removal: A Case Series. *Dermatol Pract Concept*. 2024;14(3):e2024162. DOI: <https://doi.org/10.5826/dpc.1403a162>

Accepted: February 27, 2024; **Published:** July 2024

Copyright: ©2024 Neagu et al. This is an open-access article distributed under the terms of the Creative Commons Attribution-NonCommercial License (BY-NC-4.0), <https://creativecommons.org/licenses/by-nc/4.0/>, which permits unrestricted noncommercial use, distribution, and reproduction in any medium, provided the original authors and source are credited.

Funding: None.

Competing Interests: None.

Authorship: All authors have contributed significantly to this publication.

Corresponding Author: Claudio Conforti, MD, IDI-IRCCS, Dermatological Research Hospital, Via dei Monti di Creta 104, 00167 Rome, Italy. Email: claudioconforti@yahoo.com

Introduction

Lasers and intense pulsed light (IPL) systems have become increasingly popular in dermatology and aesthetic medicine in the past two decades. Most frequently, they have been employed in unwanted hair removal procedures maintaining long-term results [1]. Their mechanism of action is through selective photothermolysis, by which photons exclusively target the hair follicle [2]. However, when applied in close proximity to a nevus, the energy absorbed by nevomelanocytes might induce thermal damage [3]. We report the

dermatoscopic changes of nevi in five patients who underwent IPL for hair removal.

Case Presentation

The dermatoscopic changes we have observed in our patients include brown pigmentary blotches with or without crust formation, gray-blue globules, gray-blue homogeneous areas, loss of pigment network, homogenous brown-gray areas and a peppering morphology (Table 1 and Figure 1).

Table 1. Case series characteristics

| | Gender, Age (years) | Intense pulsed light sessions | Time interval between intense pulsed light and nevi photography | Atypical nevi | Dermatoscopic changes of nevi |
|--------|---------------------|-------------------------------|---|---------------|---|
| Case 1 | M, 37 | 1 | 1 month | 8 | 4 nevi with brown pigmentary blotches, 6 with gray-blue globules, 3 with loss of pigment network |
| Case 2 | F, 74 | 1 | 2 months | 9 | 8 nevi with brown pigmentary blotches and crust formation, 1 with gray-blue homogenous areas |
| Case 3 | F, 30 | 2 | 2 weeks | 2 | 1 nevus with brown pigmentary blotches with crust formation, homogenous brown-gray areas and a 'peppering' morphology; 1 nevus with a central brown pigmentary blotch and crust formation |
| Case 4 | F, 23 | 7 | 1 week | 1 | 1 nevus with central brown pigmentary blotch |
| Case 5 | F, 18 | 5 | 1 week | 1 | 1 nevus with multiple brown pigmentary blotches and crust formation |

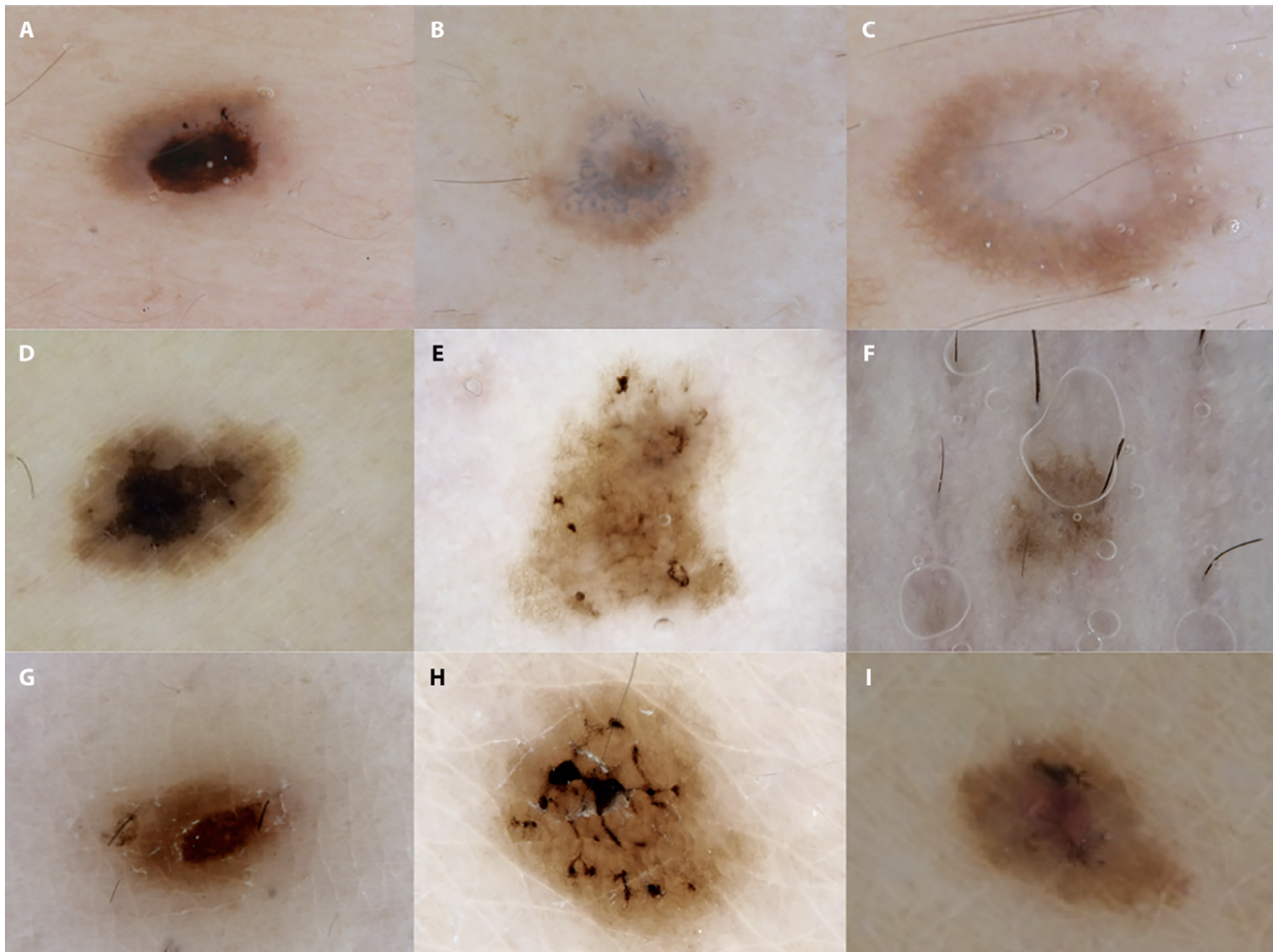


Figure 1. (A) Brown pigmentary blotch with crust formation and gray-blue areas. (B) Gray-blue globules and diffuse loss of pigment network. (C) Gray-blue globules and central loss of pigment network. (D) Brown pigmentary blotches with crust formation. (E) Diffuse brown pigmentary blotches with crust formation. (F) Gray areas and loss of pigment network. (G) Central brown pigmentary blotch. (H) Multiple brown-black pigmentary blotches with crust formation. (I) Brown pigmentary blotch and central gray-blue area.

Conclusions

Several studies have revealed that nevi might undergo both clinical and dermatoscopic changes after one or more sessions of laser or IPL for unwanted hair removal. Dermatoscopic changes have been reported through small case series and case reports: pigmentary blotches with crust formation [1,4]; pigmentary blotches with subsequent loss of pigment network [5]; asymmetric pigment network with gray-blue dots and milky red veil [6]; blue-gray areas, loss of pigment network and peppering morphology [3].

Histopathological examination showed an increased number of melanophages in the papillary dermis [1,3,5], scale-crust and melanin granules over a reticular stratum corneum [1], scarce nests of nevus cells with significant pigment loss, predominantly perifollicularly [3], increased vascularization, perivascular infiltrate and fibrosis [3,5,6]. Melan-A immunostaining revealed normal distribution of epidermal melanocytes and the absence of Melan-A dermal melanocytes [4].

Furthermore, regression of nevi has been reported after diode laser [5]. However, histopathology excluded any malignant transformation.

Ultraviolet radiation is known to cause DNA damage and mutagenesis, while the effects of visible light and infrared laser on tissues are primarily thermal. However, we cannot definitively exclude the potential for malignancy after repeated exposure to sublethal laser irradiation and thermal scarring of nevomelanocytes. Although the modifications described so far do not suggest a potential for malignant transformation, further studies with longer follow-up periods are

warranted in order to analyze the impact of laser and IPL treatments on pre-existing nevi.

References

1. Boleira M, de Almeida Balassiano LK, Jeunon T. Complete regression of a melanocytic nevus after epilation with diode laser therapy. *Dermatol Pract Concept*. 2015;5(2):99-103. DOI: 10.5826/dpc.0502a20. PMID: 26114064. PMCID: PMC4462911.
2. Thomas MM, Houreld NN. The “in’s and outs” of laser hair removal: a mini review. *J Cosmet Laser Ther*. 2019;21(6):316-322. doi: 10.1080/14764172.2019.1605449. Epub 2019 Apr 24. PMID: 31018716.
3. Pampín Franco A, Gamo Villegas R, Floristán Muruzábal U, Ascanio Armada L, Pinedo F, López-Esteban JL. Changes in melanocytic nevi after laser treatment evaluated by dermoscopy and reflectance confocal microscopy. *Int J Dermatol*. 2016 May;55(5):e307-9. doi: 10.1111/ijd.13083. Epub 2016 Feb 15. PMID: 26876612.
4. Hunziker MF, Mauad EB, Fernandes LF, Pinheiro AM. Changes in melanocytic nevi after treatment with intense pulsed light observed in total body mapping. *An Bras Dermatol*. 2016 Nov-Dec;91(6):862-864. doi: 10.1590/abd1806-4841.20165389. PMID: 28099625; PMCID: PMC5193214.
5. Martín JM, Monteagudo C, Bella R, Reig I, Jordá E. Complete regression of a melanocytic nevus under intense pulsed light therapy for axillary hair removal in a cosmetic center. *Dermatology*. 2012;224(3):193-7. doi: 10.1159/000338573. Epub 2012 May 7. PMID: 22571959.
6. Cices A, Dover JS, Labadie JG. Changes in melanocytic nevi treated with laser hair removal: A systematic review. *Lasers Surg Med*. 2023 Sep;55(7):617-624. doi: 10.1002/lsm.23712. Epub 2023 Jul 26. PMID: 37493510.