

Combination of Cemiplimab and Radiotherapy in Advanced Squamous Cell Carcinoma

André Aparício Martins¹, João Teixeira¹, Ricardo Vieira¹, Inês Coutinho¹

¹ Dermatology and Venereology Department, Unidade Local de Saúde de Coimbra, Coimbra, Portugal

Citation: Aparício Martins A, Teixeira J, Vieira R, Coutinho I. Combination of Cemiplimab and Radiotherapy in Advanced Squamous Cell Carcinoma. *Dermatol Pract Concept*. 2025;15(1):4814. DOI: <https://doi.org/10.5826/dpc.1501a4814>

Accepted: November 9, 2024; **Published:** January 2025

Copyright: © Aparício Martins et al. This is an open-access article distributed under the terms of the Creative Commons Attribution-NonCommercial License (BY-NC-4.0), <https://creativecommons.org/licenses/by-nc/4.0/>, which permits unrestricted noncommercial use, distribution, and reproduction in any medium, provided the original authors and source are credited.

Funding: None.

Competing Interests: None.

Authorship: All authors have contributed significantly to this publication.

Corresponding Author: André Aparício Martins, Dermatology and Venereology Department, Unidade Local de Saúde de Coimbra, Coimbra, Portugal, Praceta Prof. Mota Pinto 3004-561 Coimbra, Portugal. E-mail: andre.aparicio92@hotmail.com

Case Presentation

A 69-year-old man presented with a loco-regional recurrence of a squamous cell carcinoma (SCC) of the left auricle, 8 months after complete excision. The PET/CT scan confirmed the local recurrence, extending from the auricle to the inferior edge of mandibula, invading the parotid gland, with extensive cervical lymph node involvement. Disease was not amenable to surgery and immunotherapy with cemiplimab 350 mg every 3 weeks was started. During 2 treatment cycles, significant tumor enlargement was observed, with increasing local pain, dysphagia, left facial paralysis and massive local hemorrhage episodes (Figure 1 A). Hemostatic radiotherapy (20 Gy in 5 fractions) was proposed, with significant response in 3 weeks. On the third cycle of cemiplimab, the patient was asymptomatic with only a crusted plaque on physical examination (Figure 1 B). At the 12-week follow-up, CT scan showed an unspecific post-therapeutic tissue densification near left auricle, without cervical adenopathies, suggestive of complete response.

Teaching Point

Low doses (2-25 Gy) of hypofractionated radiation therapy can modulate immune cells and cause PD-1 overexpression in tumoral micro-environment [1]. These immunomodulatory mechanisms can be synergistic with immunotherapy, leading to a quicker and persistent clinico-radiological response, with prolonged progression-free survival [2]. In this patient, tumor enlargement after 2 cycles of cemiplimab, may correspond to pseudo-progression. However, impressive tumor growth, namely with severe hemorrhage, indicated the choice for hemostatic low-dose radiotherapy. Subsequent clinical evolution was impressive, illustrating an enhanced response, caused by combination of immunotherapy and low-dose radiotherapy. This therapeutic approach should be considered in challenging cases of advanced SCC, as in bulky disease, or in extremely symptomatic patients.

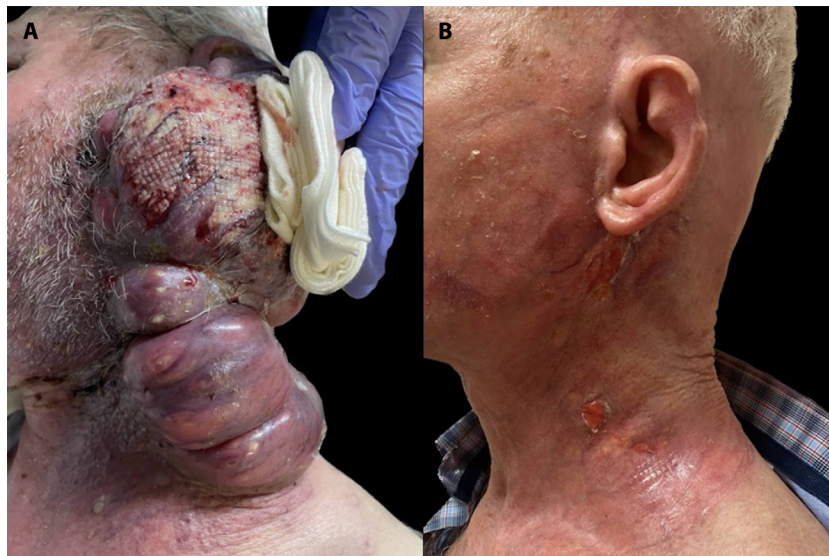


Figure 1. (A) Our patient squamous cell carcinoma after 2 cycles of cemiplimab and (B) its regression after hemostatic low-dose radiotherapy and 3 cycles of cemiplimab.

References

1. Kumari A, Simon SS, Moody TD, Garnett-Benson C. Immunomodulatory effects of radiation: What is next for cancer therapy? *Future Oncol.* 2016;12(2):239-256. DOI:10.2217/fon.15.300. PMID: 26621553. PMCID: PMC5479357.
2. Joseph K, Walker J, Raziee H, Faruqi S, Smylie M. PD-1 Blockade With Concurrent Radiotherapy for Locally Advanced Inoperable Cutaneous Squamous Cell Carcinoma. *J Cutan Med Surg.* 2022;26(3):243-248. DOI:10.1177/12034754211064273. PMID: 34866423.