

Improvement of the method of diagnostics and treatment of injuries and diseases of the maxillofacial region

Andrei Tsoi,¹ Abdyrakhman Eshiev,² Nursultan Kurmanbekov,² Daniyar Eshiev,² Nazgul Myrzasheva³

¹Department of Clinical Stomatology and Implantology, I.K. Akhunbaev Kyrgyz State Medical Academy, Bishkek;

²Department of Surgical Dentistry with a Course in Pediatric Surgical Dentistry, Osh State University, Osh;

³Department of Therapeutic Dentistry with a Course in Pediatric Therapeutic Dentistry, Osh State University, Osh, Kyrgyzstan

Abstract

This study aims to describe and apply a special endolift device in the treatment of various injuries to the zygomatic-orbital-facial complex as a means of forming an endoscopic space. A patented technique of creating an endoscopic area using an endolift device in the field of maxillofacial surgery, registered under the number 2082 dated 31.07.2018 in the Kyrgyz Republic, on the example of a clinical case, was presented. The endolift is a metal two-piece device that consists of a horizontal round mini plate up to 10 mm in diameter and a perpendicularly located hollow tube up to 4 mm in diameter in the centre of the plate with two holes at the top. The method of endoscopic space formation using endolift was used in 15 patients with various traumas to the maxillofacial region. An example of a clinical case is presented by patient J.B., 36 years

old, who underwent endoscopic minimally invasive surgery to reconstruct a mandibular fracture. The course of the operation included a small incision in the submandibular region, soft tissue separation, skeletonization of the jaw, and the formation of a tunnel, for the endolift. The endolift was inserted into the tunnel and an endoscope was inserted through it for visualisation. After alignment of the bone fragments and fixation with a miniplate through the endolift, the wound was sutured, and a dressing was applied. There were no complications during or after surgery in all 15 cases of surgery. Patients were discharged 3 days after the operation in satisfactory condition. The sutures were removed on the 7th day. Functional and cosmetic results were evaluated as satisfactory. The use of this method of treatment ultimately determines the degree of effectiveness, safety, and quality of life of the performed manipulations for patients, especially in countries with low levels of economic development.

Correspondence: Andrei Tsoi, Department of Clinical Stomatology and Implantology, I.K. Akhunbaev Kyrgyz State Medical Academy, 720020, 92 Akhunbaev Str., Bishkek, Kyrgyzstan.
E-mail: andreitsoi792@gmail.com

Key words: minimally invasive surgery, endolift, endoscopic space, access, zygomatic-orbital-facial complex.

Conflict of interest: the authors declare no potential conflict of interest.

Ethics approval: the study was approved by the Ethics Commission of the I.K. Akhunbaev Kyrgyz State Medical Academy, No. 13727.

Patient consent for publication: informed consent was obtained from all individuals included in this study.

Availability of data and materials: the data that support the findings of this study are available on request from the corresponding author.

Funding: none.

Acknowledgements: None.

Received: 24 July 2024.

Accepted: 30 August 2024.

Early view: 11 October 2024.

This work is licensed under a Creative Commons Attribution 4.0 License (by-nc 4.0).

©Copyright: the Author(s), 2024

Licensee PAGEPress, Italy

Healthcare in Low-resource Settings 2024; 12(s2):12843

doi:10.4081/hls.2024.12843

Publisher's note: all claims expressed in this article are solely those of the authors and do not necessarily represent those of their affiliated organizations, or those of the publisher, the editors and the reviewers. Any product that may be evaluated in this article or claim that may be made by its manufacturer is not guaranteed or endorsed by the publisher.

Introduction

A modern alternative method to classic wide-access surgery is small-access surgery, also known as minimally invasive surgery, which began to be actively developed only a few decades ago.¹ In endoscopic interventions, the amount of tissue damage is significantly less compared to surgery from classical access, which simplifies the identification of intact organs and tissues compared to traumatised ones.² This fact emphasises the promising development of minimally invasive methods in surgery. The fundamentals of minimally invasive surgery are based on the principles of endosurgery and the improvement of surgical instruments.³ Current methods of creating endoscopic access are not universal, and the convenience of instrument placement depends largely on the surgeon's experience. Accurate placement of all ports is one of the main factors affecting the success of endoscopic surgery. Inadequately developed endoscopic access techniques are considered one of the main causes of conversion (conversion to open surgery) and intraoperative complications.^{4,5} Against this background, there is a clear lag in the field of maxillofacial surgery, despite the particular importance of the aspects of aesthetics and functionality in this speciality. It is important to note that there is a huge need for surgical treatment using endoscopic techniques in the maxillofacial region due to the increasing incidence of new cases of facial trauma.^{6,7} In emergency practice, road traffic accidents and assault are the most common causes of maxillofacial injuries.^{8,9} From 2019 to 2021, inflammatory processes, trauma, congenital, and acquired pathology of the maxillofacial region were the main causes of hospitalisation in the maxillofacial surgery department of Osh hospital and accounted for 37.8%, 21.1%, and 22.3% of cases, respectively.¹⁰ Compared to open techniques in maxillofacial surgery, minimally invasive tech-

niques are gaining tremendous popularity worldwide due to various factors: lower traumatization and surgical stress; the possibility of surgery for cosmetic indications; increased endoscopic view of the operative field; simplification of access and surgical technique; prevention of rough postoperative facial scars; faster postoperative wound healing.¹¹⁻¹⁵ However, the moderate learning curve of endoscopic minimally invasive techniques requires surgeons to practice consistently, with a high degree of technical skill and confidence in handling instruments with limited visibility.¹⁶ In maxillofacial surgery, the role of minimally invasive endoscopic techniques remains insufficiently highlighted, despite their importance. Maxillofacial surgery is mainly represented by minimally invasive non-endoscopic methods in plastic and reconstructive surgery, or by the use of endoscopy requiring significant incisions.¹⁷⁻²¹ This fact emphasises the relevance of the development of theoretical and technical aspects of optimal endoscopic access.

Today, natural optical cavities and surgical cavities are used for sufficient visualisation during endoscopic operations in maxillofacial surgery. According to Fanelli *et al.*²² access can be performed transantral, transoral, intraarticular, and transcervical. For endoscope insertion, existing tissue damage or incisions in hidden or inconspicuous areas can be used to minimise the visibility of postoperative scars (scalp, behind the ears). According to the study by I. Yuldashev *et al.*,²³ in Bishkek for the period 2013-2017, traumatic injuries of the middle part of the face were treated using methods such as open repositioning, splint fixation, osteosynthesis, and maxillary sinus revision. Studying the progress in maxillofacial surgery, Pendharkar²⁴ and Abdulrahman²⁵ highlight the growing acceptance of endoscopic minimally invasive surgeries. It is noted that the benefits outweigh the challenges, especially in orthognathic surgery, with reduced tissue damage, scarring, and risk of infection. However, careful training is still crucial due to the complexity and sensitivity of the technique. The cost-effectiveness of these procedures has yet to be evaluated, reflecting the evolving status of the technique in operative practice. A meta-analysis of five studies by Cavalcanti *et al.*²⁶ found no statistically significant difference between open repositioning with internal fixation and endoscopic open repositioning with internal fixation in the treatment of adult condyle fractures in terms of the need for reoperation and/or facial nerve damage. However, despite the positive results of both methods, optimisation of the endoscopic surgical process and reduction of patient hospitalisation time remain urgent tasks.

The aim of this study is to propose a patent method for the treatment of various injuries to the zygomatic-orbital-facial complex based on the developed endolift as a means to form an endoscopic space, based on a clinical case study. This study, conducted over a period of approximately one year, involved a sample of 15 patients who underwent various maxillofacial surgical procedures using the endolift technique. Therefore, the limited sample size and lack of long-term results call for further studies with larger numbers of participants and long-term follow-up with patients.

Materials and Methods

Endolift design and application in maxillofacial surgery

To fulfil this goal, a special miniaturised device representing an endolift was designed and manufactured (Figure 1). The endolift device is used to form an endoscopic space for diagnosis and treatment in the field of maxillofacial surgery. This construction is

made of medical stainless steel or titanium (alloy VT1-0, VT1-00), which have the necessary biocompatibility. This device is a two-component structure, the elements of which are arranged perpendicularly to each other. Inside the operating cavity, there is a horizontal part in the form of a round plate curved to the middle with a diameter of up to 10 mm. A hollow tube up to 10 mm long and 4 mm in diameter is perpendicularly located in the central part of this plate. In the apical part of the tube on both sides, there are two holes with a diameter of up to 1 mm directed towards each other. To facilitate secure fixation of the endolift in a given position, ligatures are threaded through the lateral holes of the tube, thus ensuring stability and accurate placement during surgical interventions.

Patented method of endoscopic space shaping in maxillofacial surgery using an endolift

Using an innovative endolift device, a method has been developed to form an optical cavity for the diagnosis and treatment of various pathologies in maxillofacial surgery. This technology offers advantages in terms of surgical access and procedural flexibility. An invention patent No. 2082 dated July 31, 2018 was granted in the Kyrgyz Republic based on this method. This method involves a series of precise steps aimed at achieving optimal surgical results while preserving the natural aesthetic contours of the face. The technique involves making an incision, forming a tunnel, inserting the endolift, and then elevating it. The incision is made in an area carefully chosen to minimise visible scarring. The technique allows for the creation of a dome-shaped space above the operating field by lifting the endolift with ligatures threaded through the holes. The technique is performed as follows: first, a small (up to 10 mm) incision of the skin or oral mucosa is created in an area remote from the pathological focus, guided by careful aesthetic considerations (Figure 2). This incision is designed for

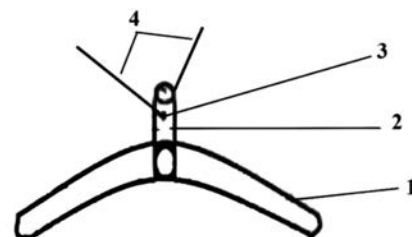


Figure 1. Schematic diagram of the endolift structure. Note: 1 – horizontal plate; 2 – hollow tube; 3 – paired holes at the top of the tube; 4 – ligatures coming out of the holes

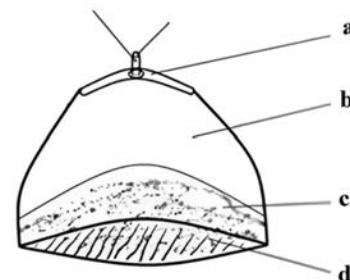


Figure 2. Technique of the method of optical cavity formation for diagnosis and treatment of various pathologies in maxillofacial surgery. Note: a, puncture for withdrawal of the endolift tube; b, free working space formed; c, d, surgical field, soft tissues and bone.

the insertion of the endolift and other instruments. After the initial incision, a tunnel is formed by detaching a skin-fat or mucosal flap directly from the incision before penetrating the intermuscular or interfascial spaces. An endolift is inserted into the central part of the formed tunnel, after which the skin or mucosa is punctured above the endolift tube, and the hollow part of the tube is brought out. The endolift is then raised with ligatures through the lateral openings of the tube, resulting in a dome-shaped working space above the operative field. The endolift is held in the raised state either by an assistant or fixed to the transverse post of the operating table using ligatures. By inserting the endoscope and/or other endoscopic instruments through the internal channel of the tube and additional ports in the working space, it is possible to perform surgical procedures at a 90° angle and to perform active drainage, irrigation of the working space, as well as other manipulations during surgical intervention. Endoscopic surgery using the endolifting technique was applied to 15 patients. The inclusion criteria were patients of any gender and age with various traumas to the maxillofacial region. A clinical case of surgery in a patient with a mandibular fracture is described in detail.

Results

The use of endolift in zygomatic-orbital surgery: a case-control study

This study was conducted in the Department of Oral and Maxillofacial Surgery of the Kyrgyz Republic. In the course of the study, after the development of the endolift device, a thorough evaluation of its effectiveness and practicality in clinical settings was carried out, with special emphasis on surgical interventions for various injuries of the zygomatic-orbital-facial complex. The use of the endolift in general included a series of 15 surgeries on injured patients with various maxillofacial injuries. The main objective of this study was to determine the capabilities of the endolift in providing optimal visualisation, creating the necessary space for accurate endoscopic interventions, and reducing procedural complexity. All patients were provided with a detailed explanation of the need for surgical intervention and the advantages of using the endoscopic method with the endolift. Each of the study participants signed an informed consent to participate in the study.

Tissue dissection was performed in a minimally visible location on the skin or through the oral mucosa. According to the technique, a tunnel was formed after the incision to insert the endolift and necessary instruments. After insertion of the device and withdrawal of its hollow tube outside, the endolift was lifted by ligatures by an assistant or fixed to the table post, and all necessary manipulations were performed. In all 15 cases of surgical interventions, no significant technical obstacles occurred throughout the operation. There were no cases of paraesthesia, facial nerve injury, infection, or bleeding. There were no intraoperative or postoperative complications, which confirms the high efficiency of the procedure and its safety for the patients. After the recovery period, the patients were discharged from the medical institution 3 days after the operation, and their clinical condition was considered satisfactory for further outpatient treatment. On the 7th day after discharge, a second examination and suture removal were performed.

Repair of a mandibular fracture with endolift: a clinical case study

This case report presents the clinical picture of patient J.B., 36

years old, with a fracture of the mandible located between the 5th and 6th teeth in the left lower quadrant, as shown in Figure 3. The patient was admitted with complaints of pain in the lower jaw on the left side, increasing when opening the mouth and chewing, as well as swelling and bite disturbance. During the objective examination there was facial asymmetry due to swelling in the left lower quadrant, the skin in the area of trauma was hyperaemic, and there were hematomas and abrasions. The mucous membrane of the left side of the mandible was hyperaemic, there were small abrasions. Teeth 3.5 and 3.6 were intact, but there was mobility in tooth 3.6. Between 3.5 and 3.6 teeth, there was a fracture with displacement. Palpation in the area between the 3.5 and 3.6 teeth caused sharp pain. Crepitation and mobility of the fragments in the fracture zone were detected. Limitation of mouth opening was observed (the patient was able to open the mouth no more than 2 cm), deviation of the mandible to the left when attempting to open the mouth fully, and bite disturbance due to displacement of the fragments.

Immediately after the patient came to the hospital, the patient was prescribed analgesics and anti-inflammatory therapy. The diagnosis was confirmed by additional investigations. The patient underwent a panoramic image (orthopantomogram), which revealed a fracture of the mandible with a fracture line between 3.5 and 3.6 teeth. Displacement of the fragments was observed in the medial-distal direction. Laboratory investigations included a general blood count and a coagulogram. The indices were free of significant abnormalities. A decision was made to use endoscopic minimally invasive intervention using endolift apparatus with repositioning of the mandibular bone fragments and fixation of the fragments with a miniplate. At the time of the examination, no contraindications to the surgical intervention were revealed. The patient was informed about the possible risks and complications associated with the operation and gave his consent to the surgical intervention. Before the operation, the patient was given a prophyl-

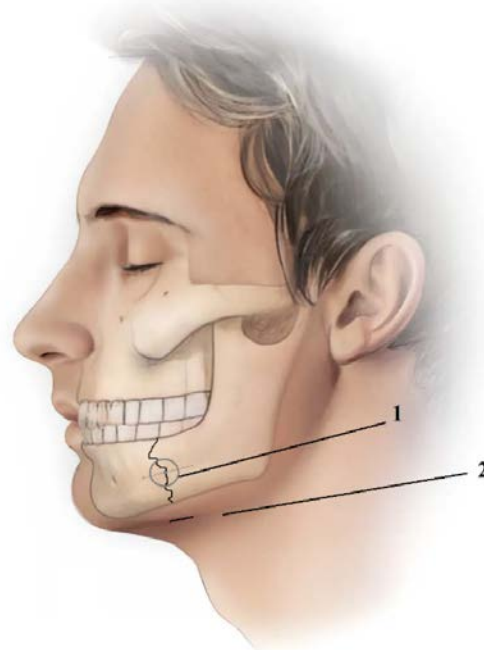


Figure 3. Fracture of the patient's mandible. Note: 1 – endolift location; 2 – main incision in the submandibular region for endolift insertion.

lactic dose of an antibacterial drug. Endoscopic repair of the mandibular fracture using the endolift technique was performed under general anaesthesia. The patient underwent a 1 cm incision in the submandibular region, after which soft tissues were layer by layer dissected and sectioned. The mandibular body was skeletonised, which made it possible to identify bone fragments in the fracture area and create a tunnel (Figure 3). After the tunnel was formed, the endolift device was inserted into the created canal, followed by a puncture of the overlying skin, which facilitated the extraction of its hollow tube. The endolift was then positioned and secured with ligatures threaded through the existing lateral holes in the apical part of the tube, thus creating a dome-shaped operative optic cavity over the surgical field. The assistant used the ligatures to stabilise the endolift apparatus. Once the optimal surgical field was established, the fibre optic endoscope was inserted through the hollow tube of the endolift apparatus, aligning the axis of observation with the surgical focus (Figure 4). Striking clarity and visualisation of the mandibular body and fracture line were achieved. A physiodispenser was then used to drill perforations in the mandibular bone through the hollow tube of the endolift, exactly aligned with the direct axis of surgical manoeuvring. If necessary, additional incisions (ports) could be created around the endoscopic space through which endoscopic or general surgical instruments were introduced. At the same time, the bone fragments were matched through the main incision site using endoscopic access with an angular trajectory exceeding 25°, after which a miniplate was inserted to immobilise the mandible. Then, a screwdriver was inserted through the internal channel of the hollow endolift tube, which was used to fix the miniplate with screws, maintaining alignment with the direct operative axis (at an angle of 90°) and placing it perpendicular to the fracture line. The occlusion and the volume of jaw movements were close to the physiological state.

Postoperative closure included suturing the wound with an atraumatic non-absorbable thread, followed by an aseptic dressing to ensure optimal wound healing and prevent nosocomial infections. The postoperative period also proceeded without complications. Three days after surgery, the patient was discharged for outpatient follow-up. The treatment plan included a consultation with an orthopaedic dentist to assess the condition of the teeth and possible further correction of the bite. A follow-up examination in 7-10 days was recommended to assess the healing dynamics and treatment efficacy. During the follow-up visit on the 7th day, the sutures were removed. Healing was without complications. Functional and cosmetic results of the treatment were evaluated as satisfactory.

Progressive treatment of mandibular fractures: endoscopic osteosynthesis with endolift

The main requirement for endoscopic surgery is the ability to form and preserve an optical cavity and to insert an endoscope. An important feature of this innovative method is its ability to perform osteosynthesis of mandibular fractures in various anatomical areas within a pre-formed optical cavity. This cavity is carefully designed specifically for endoscopic interventions to achieve the best possible results. This approach provides practitioners with comprehensive endoscopic manipulation and real-time visual control at all stages of the procedure, creating an optimal environment for surgical performance. It is possible to work through the main incision site at any angle convenient for the surgeon. The breakthroughs in this field are due to the use of a specialised device that replaces the traditional manual or self-locking retractor as a critical element for visibility and access to the surgical field. This device significantly improves the surgeon's working environment, allow-

ing him or her to perform precise manipulations with a high level of safety and minimal risk of complications. Due to these advances, endoscopic osteosynthesis for mandibular fractures of various localisations is now possible through external, cosmetic access. Miniaturised instruments are used, which avoids interference in the oral cavity. Unlike existing techniques, which are predominantly based on intraoral endoscopic interventions, the new approach eliminates the need to work in a narrow, slit-like, and deep anatomical space. This not only improves the endoscopic view but also reduces the risk of infectious complications in the operative field.^{27,28} Consequently, current techniques often require additional interventions outside the oral cavity due to the aforementioned limitations. Thus, the use of this innovative approach in endoscopic surgery of mandibular fractures represents a significant step forward in medical practice, providing surgeons with safer and more effective treatment methods, which in turn improve patients' quality of life and shorten their recovery period.

Discussion

Diagnosis and treatment of maxillofacial pathology require consideration of its unique features, including its complex network of vessels and nerves as well as the structure of soft and bony tissues. The anatomy requires that defects be repaired with minimal risk to vital structures. Optimal diagnosis and treatment require access in the form of minimally invasive incisions followed by tunnel formation; skin-fat or mucosal flap detachment; penetration into intermuscular or interfascial spaces; insertion of the endoscope and any other endoscopic instruments; a comfortable visualisation angle of the operative space; and manoeuvrability of movements.²⁹⁻³¹ All these factors ultimately determine the degree of effectiveness, safety, and quality of life of the manipulations performed on patients.

The unique structure of the endolift simplifies the work of surgeons by creating an optical cavity with a sufficient view of the surgical field. Endolift surgery provides a minimally invasive approach that minimises tissue damage and reduces postoperative scarring compared to traditional open surgery. In addition, endolift is affordable, especially in resource-limited settings. Computer

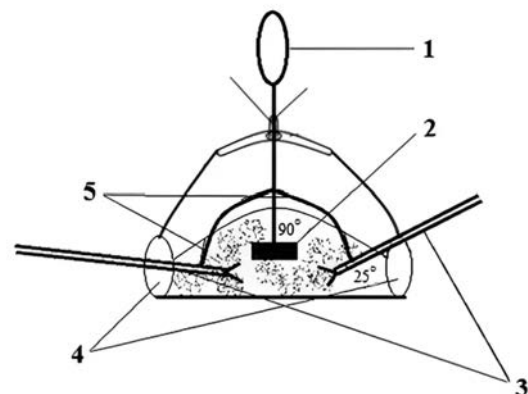


Figure 4. Use of endolift during mandibular fracture reconstruction Note: 1 – endoscope inserted through the endolift hollow tube; 2 – fracture/perforation line; 3 – endoscopic manipulators; 4 – main incision and additional port for insertion of endoscopic instruments; 5 – miniplate.

Navigation Systems (CNS) are a possible option to improve visualisation during surgical manipulations in the maxillofacial region. Alkhayatt *et al.*³² stated the usefulness of CNS in fracture reconstruction, resection of neoplasms, foreign body extraction, and jaw position correction. Navigation systems require specialised hardware and software and usually include preoperative planning and intraoperative guidance, but larger incisions may be required for access. Computed Tomography (CT) may also be used to improve intraoperative visualisation. In a study by Ren *et al.*,³³ the authors found that surgical treatment of fractures in 72 patients using CT was accompanied by a reduction in the need for incisions and internal fixation compared to conventional techniques applied to 71 patients in a control group.

The proposed patent technique with the use of endolift allows access to the surgical space through small skin or mucosal incisions up to 10 mm in the area remote from the pathological focus, providing less trauma, followed by a gentle process of tissue separation from each other to form a tunnel. In a retrospective study, Nural¹⁸ applied a novel method of vertical-space facelift with buccal fat elevation to the medial suborbital rim with a subciliary minimally invasive incision 1-2 mm below the eyelid margin from the medial canthus to 5-10 mm below the lateral canthus in 23 patients. Le Louarn³⁴ proposed the method of concentric malar (zygomatic) lifting with minimally invasive incisions. 342 patients with lower eyelid problems were treated with initial incisions of 2 cm for subperiosteal dissection and 1.5 mm diameter holes for forming pairs of holes required for malar lift. Although in both studies, the authors used minimally invasive small incisions, they did not use minimally invasive endoscopic techniques.

Tissue fixation with the endolift provides the possibility of unobstructed work by the surgeon in conditions of limited visibility and compact anatomy in surgery of the maxillofacial region.³⁵ For the formation of the optical cavity, Anehosur *et al.*³⁶ used periosteal elevators, Howarth's raspers, and a 4 mm endoscope at a 30° angle (Karl Storz, Tuttlingen, Germany) in the treatment of mandibular fracture. In a study by Chasan and Hauch,³⁷ the authors used Kirschner spokes (K-spokes) for fixation in eyebrow endolifting. Four small 1 cm incisions were made in 284 patients. K-spice fixation was done through special 16-gauge needles. The K-spokes and needles were inserted percutaneously at a 90° angle. This technique is also an effective option for temporary fixation with satisfactory results. However, it should be noted that the rate of postoperative complications after K-spice application reaches 18%.³⁸

In this technique, the endolift was inserted using ligatures through the holes of the hollow tube and held by an assistant or fixed to the table post. In addition to fixation, the structure of the endolift allows using the hollow tube for the insertion of an endoscope and special endoscopic instruments designed to work in narrow spaces of the oral cavity and other areas of the face with an optimal angle of 90°, which is also an advantage. It is possible to manipulate through the main incision with access greater than 25°, as in this clinical case of mandibular fracture. Sukegawa *et al.*³⁹ successfully removed infected interosseous spokes using an endoscopic, minimally invasive approach. For this procedure, an endoscope with a diameter of 4 mm at an angle of 70° was used in combination with an ultrasonic cutting instrument for bone dissection after a minimal incision in the jawline. This method allows for the removal of the spokes with minimal surgical intervention, reducing the risk of damage to surrounding tissues while providing effective treatment of infected areas without unnecessary complications.

Transoral and transfacial access was used to perform the elimination of posttraumatic facial injuries with endolift. Sublabial access with an incision up to 4 cm (Caldwell-Luke) is often used

to repair orbital fractures; an anthrostoma up to 4 mm is formed in the maxilla using an osteotome, followed by its expansion with a Kerrison pin up to 1×2 cm. A Greenberg retractor is used to fix the anthrostoma. In certain cases, a complex approach is appropriate. Procacci *et al.*⁴⁰ used transnasal access with megaanthrostomy for odontogenic cysts of the maxilla. In this case, endoscopy allowed seeing the medial and posterior parts of the lesion. A 4 mm 0°, 45° or 70° straight endoscope (Karl Storz GmbH & Co KG, Tuttlingen, Germany) was used. In this patent case, the angle of visualisation and active therapeutic manipulation was 90°. The size of the endoscope and its associated instruments had a diameter of no more than 4 mm, taking into account the maximum diameter of the hollow tube. Consequently, the present invention is not inferior in technical characteristics to endonasal endoscopic lifting.

In a clinical case where the patent technique was applied, it was possible to match the bone fragments through the main incision site, and a miniplate was inserted and fixed with screws. There were no intraoperative complications or technical difficulties. The postoperative period was smooth; no complications were detected. On the 3rd day, the patient was discharged from the hospital for outpatient treatment in satisfactory condition. On the 7th day, the sutures were removed. The cosmetic result was evaluated by the patient as excellent. Positive results were demonstrated by da Vinci SP single-port system for transoral resection in patients with squamous cell cancer of the oropharynx. The robotic system showed good manoeuvrability and console time.⁴¹

The proposed patent invention plays a key role in the diagnosis and treatment of a variety of injuries and diseases in the field of maxillofacial surgery, overcoming the limitations associated not only with surgical dentistry. The design of the endolift and the method of using it to create an endoscopic space contribute significantly to the development of this field of surgery. This approach provides surgeons with more flexible and precise tools to perform surgery with minimal impact on the natural anatomical contours of the face. The endolift provides the necessary stability during surgical interventions, playing a key role in the formation of the optical cavity, which is an essential element of many operations in this field. The main advantage of this method is a shorter hospital stay, reduced risk of complications, and faster recovery. The endolift device is universal and applicable to the entire spectrum of problems in the field of maxillofacial surgery.

Conclusions

The invention of the endolift is directed towards diagnostic and therapeutic endoscopic interventions in maxillofacial surgery. The minimally invasive technique offers precision and efficiency in creating an endoscopic field, aligning with the broader trend towards less invasive surgical approaches in modern medicine. The endolift's unique design allows the formation of a dome-shaped working area, addresses longstanding challenges in maxillofacial surgery related to visibility and maneuverability in confined spaces. The ability to introduce endoscopic instruments through the endolift's internal channel and additional ports exemplifies the concept of multimodal surgical access, a principle increasingly recognized in advanced surgical techniques. This versatility enables surgeons to execute treatments from numerous angles, actively manage the surgical site through drainage and irrigation, and perhaps eliminate the need for larger open surgeries.

The successful completion of fifteen surgeries employing this technology, encompassing both transoral and transfacial methods,

offers preliminary proof of the technique's efficacy in a variety of maxillofacial procedures. The thorough case study of patient J.B.'s mandibular fracture treatment exemplifies the endolift's practical use, demonstrating its ability to simplify difficult operations while minimising tissue trauma. This example is consistent with the expanding body of research favouring less invasive techniques in face trauma therapy. The endolift's ability to facilitate osteosynthesis in a pre-formed cavity is an innovative approach to maxillofacial bone recovery. This method has the potential to bridge the gap between traditional open operations and totally endoscopic treatments, providing a compromise that incorporates the advantages of both techniques. The endolift technique, despite its potential cost for low-income individuals, addresses healthcare access issues. However, increased time demands and medical personnel workload necessitate a thorough cost-benefit analysis. Minimal scarring, less tissue stress, enhanced field vision, and quicker recovery times lead to better cosmetic and functional results in maxillofacial surgery.

Although the results of the study are promising, the limited sample size and lack of long-term results call for further studies with larger numbers of participants and long-term follow-up with patients. Future research should explore endolift's potential applications beyond maxillofacial surgery, including general and specialized procedures. Standardised patient satisfaction and functional outcome assessments are crucial for patient-centered evaluation. A detailed economic evaluation of endolift against traditional techniques is essential for healthcare systems considering its implementation. Endolift offers better results and less invasive procedures, but extensive scientific examination and multi-center investigations are needed for effective integration. Advancements in technology could significantly influence patient treatment and facial reconstructive options.

References

- Hargest R. Five thousand years of minimal access surgery: 3000BC to 1850: Early instruments for viewing body cavities. *J R Soc Med* 2020;113:491-6.
- Hakim MA, McCain JP, Ahn DY, Troulis MJ. Minimally invasive endoscopic oral and maxillofacial surgery. *Oral Maxillofac Surg Clin North Am* 2019;31:561-7.
- Latka K, Kolodziej W, Pawlak K, et al. Fully endoscopic spine separation surgery in metastatic disease—case series, technical notes, and preliminary findings. *Med (Lith)* 2023;59:993.
- Darzi A, Mackay S. Recent advances in minimal access surgery. *BMJ* 2002;324:31-4.
- Trifkovic B, Budak I, Vukelic D, et al. Analysis of accuracy and precision of optical 3D digitisation devices in dental computer-aided-design and computer-aided-manufacturing systems. *Maejo Int J Sci Technol* 2017;11:45-57.
- Laloo R, Lucchesi LR, Bisignano C, et al. Epidemiology of facial fractures: Incidence, prevalence and years lived with disability estimates from the Global Burden of Disease 2017 study. *Inj Prev* 2020;26:i27-35.
- Postic SD. X-Ray Diffraction Technique in the Analysis of Phases of Hydroxylapatite and Calcium Phosphate in a Human Jaw. *Int J Biomed* 2014;4:109-11.
- Elkhwagi M, Eldegwi A. What is the role of the endoscope in the sinus preservation management of frontal sinus fractures? *J Oral Maxillofac Surg* 2020;78:1811.e1-9.
- Shetawi AH. Initial evaluation and management of maxillofacial injuries. 2021. Available from: <https://emedicine.medscape.com/article/434875>
- Eshiev A, Mirzasheva N. The results and main directions of improving the activity of the maxillofacial surgery department at oiuch. *Bull Osh State Univ* 2022;2:41-7.
- Tsoi AR, Yuldashev IM. Patent of the Kyrgyz Republic for the invention No. 2082/07.31.2018. The method of forming endoscopic space in maxillofacial surgery and endolift for its implementation. 2018. Available from: https://drive.google.com/file/d/1USKB1Th9YhYzN8z9ytKWzGfnwZx_xIsZ/view
- Kim JY, Lee YC, Kim SG, Garagiola U. Advancements in oral maxillofacial surgery: A comprehensive review on 3D printing and virtual surgical planning. *Appl Sci* 2023;13:9907.
- Choi H, Cho GJ, Jung KH, et al. The dual-port endoscope-assisted cyst enucleation on the maxillofacial region. *Maxillofac Plast Reconstr Surg* 2021;43:40.
- Nowak R, Rekas M, Ali MJ. Long-term outcomes of StopLoss™ Jones tube (SLJT) and minimally invasive conjunctivodacryocystorhinostomy. *Graefes Arch Clin Exper Ophthalmol* 2022;260:327-33.
- Makarov V, Yessentayeva S, Kadyrbayeva R, et al. Modifications to the video-assisted thoracoscopic surgery technique reduce 1-year mortality and postoperative complications in intrathoracic tumors. *Eur J Cancer Prev* 2024;33:53-61.
- Harvinder B, Ben H. Learning curve for minimally invasive surgery and how to minimize it. *Foot Ankle Clin* 2020;25:361-71.
- Ceresoli M, Pisano M, Abu-Zidan F, et al. Minimally invasive surgery in emergency surgery: A WSES survey. *World J Emerg Surg* 2022;17:18.
- Nural H. Vertical space lift: transcutaneous lower blepharoplasty, subperiosteal midface lift, and lower face lift: a novel technique of buccal fat suspension to medial infraorbital rim. *Aesthet Surg J Open Forum* 2021;4:ojab038.
- Wang Y, Ma D, Li Y, et al. Combined use of endoscopic techniques and virtual surgical planning for intraoral approach for hemi-mandibular resection and reconstruction. *Plast Reconstr Surg Glob Open* 2024;12:e5644.
- Oshurko AP, Oliinyk IY, Kuzniak NB. Anatomical and topographic classification of the mandibular canal with bone atrophy caused by the loss of the masticatory teeth. *Rom J Stomatol* 2022;68:160-6.
- Latka D, Waligora M, Latka K, et al. Virtual reality based simulators for neurosurgeons - what we have and what we hope to have in the nearest future. *Adv Intell Syst Comp* 2018;720:1-10.
- Fanelli CA, Vera LC, Ahn DY, McCain JP. A review of endoscopic surgical applications in oral and maxillofacial surgery. *Plast Reconstr Surg Glob Open* 2023;5.
- Yuldashev I, Rakhmanov A, Urgunaliyev B, et al. Frequency of midfacial traumatic injuries – A report from the maxillofacial reconstructive and plastic surgery department of Kyrgyz Republic health service Ministry's National Hospital, Bishkek from 2013-17 – A retrospective study. *Ann Maxillofac Surg* 2020;10:377-80.
- Pendharkar SS. Endoscopic perspective in oral and maxillofacial surgery. *RGUHS J Dent Sci* 2023;15:12-6.
- Abdulrahman A. Minimally invasive approaches in orthognathic surgery: A narrative review of contemporary techniques and their clinical outcomes. *J Pharm Bioallied Sci* 2024;16:1652-6.
- Cavalcanti SC, Taufer B, Rodrigues A, Luz JG. Endoscopic

- surgery versus open reduction treatment of mandibular condyle fractures: A meta-analysis. *J Craniofac Surg* 2021;49:749-57.
27. Boccuto M, Ottaviano G, Prosenikliev V, et al. Combined endoscopic and intraoral approach or intraoral alone in surgical management of odontogenic sinusitis. *Surgeries* 2021;2:399-408.
 28. Romano A, Norino G, Dell'Aversana Orabona G, et al. A large follicular dentigerous cyst: A new multi-portal access: Intraoral and endoscopic technique. *J Maxillofac Oral Surg* 2024;23:189-92.
 29. Sheinman V, Rudnitsky A, Toichuev R, et al. Implantable photonic devices for improved medical treatments. *J Biomed Opt* 2014;19:108001.
 30. Perkasa MF. Endoscopic transsphenoidal surgery and Haddad nasoseptal flap of Rathke's cleft cysts. *Gac Med Caracas* 2023;131:414-9.
 31. Bothra N, Gupta N, Nowak R, et al. The use of anterograde percutaneous transluminal coronary angioplasty balloons in congenital nasolacrimal duct obstruction: a cost-effective alternative to the traditional dacryoplasty balloons. *Ophthalmic Plast Reconstr Surg* 2020;36:302-4.
 32. Alkhayatt NM, Alzahrani HH, Ahmed S, et al. Computer-assisted navigation in oral and maxillofacial surgery: A systematic review. *Saudi Dent J* 2024;36:387-94.
 33. Ren H, Chen S, Zhang Y, An J, He Y. Intraoperative computed tomography in the surgical treatment of zygomatic complex fracture: a retrospective cohort study. *J Craniofac Surg*. 2024 May 7. doi: 10.1097/SCS.00000000000010201. Epub ahead of print.
 34. Le Louarn C. Concentric malar lift in the management of lower eyelid rejuvenation or retraction: A clinical retrospective study on 342 cases, 13 years after the first publication. *Aesthet Plast Surg* 2018;42:725-42.
 35. Oshurko AP, Oliinyk IY, Kuzniak NB. Variant anatomy of the mandibular canal topography. *Rep Morphol* 2022;28:62-8.
 36. Anehsur V, Joshi A, Rajendiran S. Endoscopic-assisted intraoral open reduction internal fixation of mandibular subcondylar fractures: Initial experiences from a tertiary-care maxillofacial center in India. *Cranio Maxillofac Trauma Reconstr* 2018;11:183-91.
 37. Chasan PE, Hauch AT. The K-wire fixation technique for endoscopic brow lift: A long-term follow-up. *Aesthet Plast Surg* 2020;40:1051-60.
 38. Wong KY, Mole R, Gillespie P. Kirschner wire breakage during removal, requiring retrieval. *Case Rep Surg* 2016;2016:7515760.
 39. Sukegawa S, Miyazaki R, Matsuki Y, et al. Endoscopic-assisted surgical removal of infected interosseous wires 40 years after mandibular surgery. *J Craniofac Surg* 2023;34:1556-8.
 40. Procacci P, Lanaro L, Molteni G, et al. Trans-nasal endoscopic and intra-oral combined approach for odontogenic cysts. *ACTA Otorhinolaryngol Ital* 2018;38:439-44.
 41. Costantino A, Sampieri C, Meliante PG, et al. Transoral robotic surgery in oropharyngeal squamous cell carcinoma: A comparative study between da Vinci Single-Port and da Vinci Xi systems. *Oral Oncol* 2024;148:106629.