



## Standard for Breast Conservation Therapy in the Management of Invasive Breast Carcinoma

Dr. Dhananjayan Govindarajan<sup>1</sup>, Dr. Hakeem Sulthan. Z<sup>2</sup>, Dr. N. K.S. Shaik Mujibur Rahman<sup>3\*</sup>

<sup>1</sup>Senior Resident, Department of General Surgery, Shri Sathya Sai Medical College & Research Institute, Ammapettai - 603108, Tamilnadu.

<sup>2</sup>Senior Resident, Department of General Surgery, Shri Sathya Sai Medical College & Research Institute, Ammapettai - 603108, Tamilnadu.

<sup>3</sup>Associate Professor, Department of General Surgery, Shri Sathya Sai Medical College & Research Institute, Ammapettai - 603108, Tamilnadu.

**Corresponding Author:** Dr N. K.S. Shaik Mujibur Rahman, Associate Professor, Department of General Surgery, Shri Sathya Sai Medical College & Research Institute, Ammapettai - 603108, Tamilnadu, India.

*Received Date: 11/07/2025*

*Revised Date: 10/08/2025*

*Accepted Date: 15/09/2025*

### KEYWORDS

Breast  
Conservation  
Therapy, Breast  
Carcinoma

### ABSTRACT:

Background: Multidisciplinary guidelines have been updated to reflect the continuing advances in the diagnosis and treatment of invasive breast cancer. The guidelines provide a framework for clinical decision-making for patients with invasive breast carcinoma based on review of relevant literature and include information on patient selection and evaluation, technical aspects of surgical treatment, techniques of irradiation, and follow-up care

### INTRODUCTION

The establishment of standards of care for medical treatment is a process of building consensus by using the best available scientific evidence. The treatment of patients with cancer has progressively become multidisciplinary. In an attempt to promote better and more consistent care of cancer patients.

Breast conservation treatment is defined as the excision of the primary breast tumor and adjacent breast tissue (breast-conserving surgery), usually followed by irradiation. Breast-conserving surgery also is commonly referred to as lumpectomy, partial mastectomy, and segmental mastectomy. The meetings and the resulting guidelines were considered only a point of departure from which to involve other disciplines within medicine, educate patients, and establish a framework for developing guidelines for the multidisciplinary management of other types of cancer. With the advances in knowledge in a variety of fields related to the treatment of early breast cancer, it is appropriate to revise these documents. In the original 1992 publication, the focus was on the treatment of invasive carcinoma of the breast.

The increased use of and improvements in mammographic technology have resulted in a marked increase in the diagnosis of ductal carcinoma in situ (DCIS). A body of knowledge has been developed on DCIS that necessitates a separate treatment of this subject in a companion document, *Standard for the Management of Ductal Carcinoma in Situ of the Breast (DCIS)*.

### REVIEW AND SUMMARY OF THE LITERATURE

Although radical and modified radical mastectomy (MRM) were the historical mainstays of the treatment of Stage I and II breast cancer for decades and MRM continues to be appropriate for some patients, breast conservation treatment has become the preferred method of treatment for many patients. The results of prospective, randomized trials as well as the results of large retrospective non randomized studies from single institutions have demonstrated the equivalence of mastectomy and breast conservation treatment for appropriately selected patients with early stage breast cancer.



**Table 1: Prospective Randomized trails comparing conservating surgery and radiation with mastectomy for early-stage breast cancer**

Trial	Treatment Period	Total Number of Patients	Stage	Surgery Primary for	Adjuvant Therapy
Milan I	1973–1980	701	I	Q, RM	CMF
Institut Gustave-Roussy	1972–1980	179	I	WE, MRM	None
NSABP B-06	1976–1984	1,219	I–II	WE, MRM	Melphalan, 5FU
National Cancer Institute	1979–1987	237	I–II	WE, MRM	AC
EORTC	1980–1986	868	I–II	LE, MRM	CMF
Danish Breast Cancer Group	1983–1989	904	I–III	Q, WE, MRM	CMF, Tamoxifen

**5FU:** 5-fluorouracil

**AC:** Doxorubicin, Cyclophosphamide

**CMF:** Cyclophosphamide, Methotrexate, 5-fluorouracil

**EORTC:** European Organization for Research and Treatment of Cancer

**LE:** Local excision

**MRM:** Modified radical mastectomy

**Q:** Quadrantectomy

**RM:** Radical mastectomy

**WE:** Wide excision

**Table 2: Survival Comparison for conservative surgery and radiation (CS and RT) versus mastectomy in Prospective Randomized Trials**

Trial	Endpoint	Overall Survival % (CS and RT / Mastectomy)	Disease-free Survival % (CS and RT / Mastectomy)
<b>Milan I</b>	18 years	65 (NS) / 65	–
<b>Institut Gustave-Roussy</b>	15 years	73 (0.19) / 65	–
<b>NSABP B-06</b>	12 years	63 (0.12) / 59	50 (0.21) / 49
<b>National Cancer Institute</b>	10 years	77 (0.89) / 75	72 (0.93) / 69
<b>EORTC</b>	10 years	65 (NS) / 66	–
<b>Danish Breast Cancer Group</b>	6 years	79 (NS) / 82	70 (NS) / 66

NS: Not significant (p-value not significant)

**EORTC:** European Organization for Research and Treatment of Cancer

### Prospective Randomized Trials

Six modern prospective randomized trials have compared mastectomy with conservative surgery and radiation for Stage I and II breast cancer (Table 1). 1-9 Whole breast irradiation with doses of 45 to 50 Gy was

used in all of the trials, and a boost to the primary site was employed in five of the six trials. In the National Surgical Adjuvant Breast and Bowel Project (NSABP) trial, a dose of 50 Gy was delivered to the entire breast without a boost. This trial required histologically negative margins of resection for patients undergoing



conservative surgery and radiation. For the remaining five trials, the total dose to the primary site was greater than or equal to 60Gy. The published results of these trials are presented in Tables 2 and 3.

There are no significant differences in overall or disease-free survival rates when comparing the two treatments in any of the trials. In particular, patients with histologically positive nodes treated with chemotherapy have not been found to have improved survival rates when treated with mastectomy either in the NSABP B-06 trial or the Milan I trial.<sup>5,10</sup>

In four of the six randomized trials, there was no significant difference in the risk of a recurrence in the treated breast or chest wall following mastectomy. In the National Cancer Institute (NCI) trial, a significantly higher local failure rate was observed in the breast conservation group. However, in this trial, only gross tumor removal was required for study entry. Similarly in the European Organization for Research and Treatment

of Cancer (EORTC) trial, 81 percent of the patients in the breast-conserving surgery arm had T2 tumors and 48 percent of the patients had microscopically positive margins.

Local recurrence after breast preservation may be due to inappropriate patient selection, inadequate surgery or radiation therapy, or biologically aggressive disease. Inadequate surgery may have contributed to the increased risk of breast recurrence in the NCI and the EORTC trials. Overall, the incidence of a recurrence in the treated breast ranges from 3 to 20 percent (Table 3).<sup>3,4,6,7,9,10</sup> The majority of failures in the treated breast can be salvaged with mastectomy, and survival following such treatment is approximately 70 percent at five years. As demonstrated in Table 3, primary mastectomy does not guarantee freedom from local recurrence in Stage I and II breast cancer. The incidence of chest wall recurrence ranges from 4 to 14 percent.

**Table 3: Comparisons of local recurrence following conservative surgery and radiation (CS and RT) or Mastectomy in prospective Randomized Trails**

Trial	Endpoint	CS and RT	Mastectomy
Milan I	Cumulative incidence at 18 years	7% (NS)	4%
Institut Gustave-Roussy	Cumulative incidence at 15 years	9% (NS)	14%
NSABP B-06	Cumulative incidence	10%	8%
National Cancer Institute	Crude incidence, median follow-up 10.1 yrs	19% (0.01)	6%
EORTC	Actuarial at 10 years	20% (0.01)	12%
Danish Breast Cancer Group	Crude incidence, median follow-up 3.3 yrs	3% (NS)	4%

- **CS and RT:** Conservative Surgery and Radiation Therapy
- **NS:** Not significant (p-value not significant)
- **EORTC:** European Organization for Research and Treatment of Cancer

A desire to avoid local recurrence is not a reason to encourage a patient who otherwise is a good candidate for breast conservation to choose mastectomy, since the procedures are associated with an equal risk of local failure in appropriately selected and treated women. A meta-analysis<sup>11</sup> of nine prospective randomized trials comparing conservative surgery and radiation to mastectomy has demonstrated no survival differences. Local recurrence was reported in 6.2 percent of the mastectomy patients and in 5.9 percent of the patients treated with breast conservation.<sup>11</sup> The randomized trials have also addressed the issue of second malignancy related to radiation. There has been no difference in the

incidence of contralateral breast cancer or a second non-breast cancer malignancy. In addition to the randomized trials comparing breast conservation (with excision and radiation) with mastectomy, ten randomized trials have compared conservative surgery alone with conservative surgery and radiation. The published results of nine of these trials are summarized in Tables 4 and 5.<sup>4,10,12-19</sup> The trials vary with regard to patient selection, the extent of surgery and radiotherapy, and the use of adjuvant systemic therapy. Quadrantectomy was employed in the Milan and Swedish studies, and adjuvant chemotherapy and/or tamoxifen was used in the NSABP, Milan, British, Scottish, and West Midlands trials. Despite these



differences, all of the trials demonstrated a reduction in the rate of recurrence in the breast in the irradiated group (an average crude rate of reduction of 84 percent, range 73 to 97 percent). A recent meta-analysis of ten randomized trials comparing conservative surgery to conservative surgery and radiation reported an absolute reduction in breast recurrence rates with radiation of 17

percent for axillary-node negative women (25 versus 7.8 percent) and 19 percent for axillary-node-positive women (35.4 versus 16.1 percent).<sup>11</sup> The absolute benefit from radiation for any recurrence was 16 percent for the node-negative group (44.7 versus 28.6 percent,  $p = < 0.00001$ ) and 8 percent for the node-positive group (58 versus 49.8 percent,  $p = 0.002$ ).

**Table 4: Prospective Randomized Trails comparing conservative surgery with and without radiation therapy comparison of local recurrence following conservative surgery and radiation (CS and RT) or Mastectomy in prospective randomized trails.**

Trial	Number of Patients	Tumor Size (cm)	Pathologic Nodal Status	Surgery	Systemic Therapy
Swedish <sup>12</sup>	381	< 2	N-	Q	None
Milan III <sup>10,13</sup>	601	< 2.5	N- or N+	Q	CMF or Tamoxifen N+
Ontario <sup>14</sup>	837	< 4	N-	L	None
NSABP B-06 <sup>4</sup>	1,265	< 4	N+ or N-	L	L-Pam, 5FU for N+
NSABP B-21 <sup>15</sup>	1,009	< 1	N-	L	Tamoxifen
Scottish <sup>16</sup>	556	< 4	N- or N+	WE	CMF or Tamoxifen N+
British <sup>17</sup>	399	≤ 5	N- or N+	WE	CMF or Tamoxifen
BASO II <sup>18</sup>	241	≤ 2	N-	WE	Tamoxifen
West Midlands <sup>19</sup>	707	≤ 4	Clin N-	WE	Tamoxifen

#### Abbreviations:

- 5FU: 5-fluorouracil
- CMF: Cyclophosphamide, Methotrexate, 5-fluorouracil
- L: Local excision
- Q: Quadrantectomy
- WE: Wide excision

**Table 5: Local Recurrence and survival in Prospective Randomized trails comparing conservative surgery with and without radiation therapy**

Trial	Breast Recurrence % (CS)	Breast Recurrence % (CS+RT)	Overall Survival % (CS)	Overall Survival % (CS+RT)	Interval Results Reported
Milan III	18	2	92	92	5-year actuarial
Swedish	24	9	78	78	10-year actuarial
Ontario	40	18	72	74	10-year actuarial



<b>NSABP B-06</b>	35	10	58	62	12-year actuarial
<b>NSABP B-21</b>	12	6	–	–	Crude 6.1-year mean
<b>Scottish</b>	28	6	85	88	5-year actuarial
• Positive ER	25	3	–	–	–
• Negative ER	44	14	–	–	–
<b>British</b>	35	13	–	–	5-year actuarial
<b>BASO II</b>	5	2	98	98	Crude 4-year median
<b>West Midlands</b>	13	4	–	–	Crude 2-year mean

NS: Not significant (p-value not significant)

EORTC: European Organization for Research and Treatment of Cancer

TABLE 6

Studies	Number of Patients	10-Year Survival
Stage I and II		
Fowble et al. <sup>21</sup>	697	83
Haffty et al. <sup>22</sup>	278	67
Leung et al. <sup>23</sup>	493	68
Mansfield et al. <sup>24</sup>	1,070	80†
Spitalier et al. <sup>25</sup>	1,133	80
Stotter et al. <sup>26</sup>	490	74
Kini et al. <sup>27</sup>	390	74
Stage I		
Dewar et al. <sup>*28</sup>	757	79
Veronesi et al. <sup>2</sup>	1,232	78
Perez et al. <sup>29</sup>	520	85†
Zafrani et al. <sup>*30</sup>	434	86
Kini et al. <sup>27</sup>	281	88

\*Includes small T2.

†Cause-specific.

Subset analyses within these trials have identified older women (greater than 55 years of age) with small primary infiltrating ductal tumors (less than 1 to 2 cm) and negative axillary nodes that lack an extensive intraductal component (EIC) or lymphatic invasion as having the lowest risk of a breast recurrence when radiation is omitted.<sup>10,12-14</sup> In the Swedish trial, the breast recurrence rate at ten years in this subset of patients was 11 percent after quadrantectomy alone, compared with 6 percent for quadrantectomy and radiation. Therefore, even in the lowest risk group, radiation decreased the risk of a breast recurrence. In a single-arm prospective study of 81 women (median age 66 years) with primary tumors less than or equal to 2 cm without an EIC or lymphatic invasion excised with negative margins greater than or

equal to 1 cm and with negative axillary nodes treated 282 without radiation, the crude breast recurrence rate was 23 percent (median follow-up of 7.2 years).<sup>20</sup> tamoxifen.<sup>15</sup> The NSABP B-21 addressed this question in axillary node-negative women with primary tumors less than or equal to 1 cm. Patients were randomized to tamoxifen alone, radiation, or radiation and tamoxifen. With a mean follow-up of 6.1 years, ipsilateral breast tumor recurrences were reported in 12 percent of the 336 patients who received tamoxifen, 6 percent in the 336 women treated with radiation, and 2 percent in the 337 women treated with radiation and There were no significant differences in overall or cause-specific survival. This study suggests that tamoxifen cannot replace radiation even in women with the most favorable tumors.

The British Association of Surgical Oncology (BASO) II trial randomized women with primary tumors less than 2 cm, histologic Grade 1, and negative axillary nodes to wide excision with or without tamoxifen or wide excision and radiation with or without tamoxifen. With a median follow-up of four years, the ipsilateral breast tumor recurrence rate in the 120 patients who did not receive radiation was five percent compared with two percent in the 121 women who received radiation.<sup>18</sup> Radiation, therefore, appears to benefit all women with early-stage invasive breast cancer, although the magnitude of this benefit varies depending on the selection of the patients.

#### Nonrandomized Studies

The results of multiple, non randomized retrospective studies further support the equivalence of breast



conservation treatment and mastectomy in appropriately selected patients (Tables 6 and 7).<sup>2,21-30</sup> At ten years, overall survival has ranged from 67 to 88 percent depending upon the stage of the disease (Table 6). Disease-free survival at ten years is approximately 70 percent. These series have also demonstrated excellent long-term control within the treated breast with primary tumors less than or equal to 5 cm in diameter. At ten years, local recurrence rates range from 8 to 19 percent. For patients with negative margins of resection, the ten-year actuarial risk of breast recurrence is 10 percent or less. The overall survival and local control rates in the breast reported by these retrospective series are comparable to the results of the six prospective randomized trials.

### PATIENT SELECTION AND EVALUATION

Because of the potential options for treatment of early-stage breast cancer, careful patient selection and a multidisciplinary approach are necessary. Four critical elements in patient selection for breast conservation treatment are

- History and physical examination.
- Mammography.
- Histological assessment of the resected breast specimen.
- Assessment of the patient's needs and expectations.

TABLE 7

Study	Number of Patients	Maximum Primary Tumor Size (cm)	Breast Recurrence at 10 Years (%)
Gage et al. <sup>31</sup>	1,628	5	13
Kurtz et al. <sup>32,33</sup>	1,593	5	14
Meric <sup>34</sup>	1,236	5	10
Veronesi et al. <sup>1</sup>	1,232	2	8
Clark et al. <sup>35</sup>	1,130	5	14
Mansfield et al. <sup>24</sup>	1,070	5	14
Dewar et al. <sup>26</sup>	757	3	8
Fowble et al. <sup>36</sup>	697	5	18
Fourquet et al. <sup>37</sup>	518	5	11
Halverson et al. <sup>38</sup>	511	5	14
Leung et al. <sup>23</sup>	493	5	10
Haffty et al. <sup>22</sup>	433	5	19
Kini et al. <sup>27</sup>	390	5	10

Study	Number of Patients	Maximum Primary Tumor Size (cm)	Breast Recurrence at 10 Years (%)
Gage et al. <sup>31</sup>	1,628	5	13

Kurtz et al. <sup>32,33</sup>	1,593	5	14
Meric <sup>34</sup>	1,236	5	10
Veronesi et al. <sup>1</sup>	1,232	2	8
Clark et al. <sup>35</sup>	1,130	5	14
Mansfield et al. <sup>24</sup>	1,070	5	14
Dewar et al. <sup>26</sup>	757	3	8
Fowble et al. <sup>36</sup>	697	5	18
Fourquet et al. <sup>37</sup>	518	5	11
Halverson et al. <sup>38</sup>	511	5	14
Leung et al. <sup>23</sup>	493	5	10
Haffty et al. <sup>22</sup>	433	5	19
Kini et al. <sup>27</sup>	390	5	10

### History and Physical Examination

Much of the information needed to determine a patient's suitability for breast conservation therapy can be obtained from a detailed history and physical examination. It is important to note that age per se, whether young or old, is not a contraindication to breast conservation. In the elderly, physiologic age and the presence of comorbid conditions should be the primary determinants of local therapy. The elements of the breast history and physical exam are listed in Tables 8 and 9. When evaluating the physical examination, it is important to note that skin, nipple, and breast parenchyma retraction are not signs of locally-advanced breast cancer and do not represent contraindications to breast conservation.

### Mammographic Evaluation

Recent preoperative mammographic evaluation is necessary to determine a patient's eligibility for breast conservation treatment. It should be performed with high-quality, dedicated mammographic equipment in a facility certified by the FDA under the Mammography Quality Standards Act.



Recent mammographic evaluation (usually within three months) prior to biopsy or definitive surgery plays an important role in establishing the appropriateness of breast conservation treatment by defining the extent of a patient's disease, the presence or absence of multicentricity, and other factors that might influence the treatment decision. It is important for evaluating the contralateral breast. Bilateral mammography is required for palpable lesions as well as non-palpable lesions that can be identified only radiographically. Non-palpable masses and microcalcifications comprise an increasing percentage of carcinomas treated with breast conservation.

The breast tumor should be measured in at least two dimensions on the mammographic views or from the sonogram during ultrasonography, if it is performed. The size of the tumor should be included in the mammographic report. If the tumor is a poorly marginated mass, approximate dimensions can be given from either the mammogram or the sonogram. The skin

of the breast in the area of a mass should be evaluated for thickening that might signify tumor involvement. If the mass is associated with microcalcifications, an assessment of the extent of the calcifications within and outside of the mass should be made, including the dimensions of the area in 284 disease.<sup>39,40</sup> which calcifications are located. If one or more clusters of microcalcifications are the only markers of the tumor, their location and distribution should be described. For evaluation of masses and microcalcifications, specialized views with positioning adapted to the location of the abnormality may be helpful. Magnification mammography and spot compression are important for characterizing microcalcifications and defining the margins of masses. Ipsilateral multifocality (in the same quadrant of the breast) or multicentricity (in different quadrants of the breast) may be present and influence the treatment selection. In every instance, when one abnormality is seen, all areas of each breast should be fully evaluated for the presence of additional disease.

TABLE 8

## Elements of the Breast Cancer-Specific History

- Family history: relatives with breast cancer (age at diagnosis, bilaterality), ovarian carcinoma.
- History of prior therapeutic irradiation involving breast region.
- History of collagen vascular disease: type, documentation of diagnosis.
- Presence of breast implants: submammary or subpectoral.
- Date of last menstrual period/possibility of pregnancy.
- Symptoms suggestive of metastasis.
- Nipple discharge: spontaneous versus induced, color.

TABLE 9

## Elements of the Breast Physical Exam

- Tumor size (measured) and location, if palpable.
- Fixation to skin.
- Ratio of breast size to tumor size.
- Evidence of multiple primary tumors.
- Axillary node status: size, mobility.
- Supraclavicular node size.
- Evidence of locally advanced cancer.
  - Skin ulceration, satellitosis (intradermal tumor nodules).
  - Peau d'orange.
  - Skin erythema, edema.
  - Fixed axillary nodes.
  - Lymphedema of the ipsilateral arm.
- Nipple changes.
- Appearance of the opposite breast and axilla.

Some studies have suggested that magnetic resonance imaging (MRI) is a useful adjunct to mammography and ultrasound for the identification of multifocal and multicentric. At this time, due to the lack of standardization of technique, high false positive rates, and difficulty in biopsying lesions seen only on MRI, this cannot be considered part of the standard evaluation of the breast cancer patient. Using magnification mammography and ultrasound, patients with tumors suitable for breast conservation can be identified with at least 95% certainty preoperatively.<sup>41</sup>

### Pathological Features Influencing Treatment Choice

A number of pathologic factors have been assessed for their ability to predict an increased risk of recurrence in the treated breast inpatients undergoing conservative surgery and radiation. These factors include histologic type and grade, the presence or absence of tumor necrosis, vascular or lymphatic invasion or an inflammatory infiltrate, the presence of DCIS in association with an invasive ductal carcinoma, margins of resection, and pathologic nodal status. The presence of vascular or lymphatic invasion, tumor necrosis, and an inflammatory infiltrate has been associated in a few studies with a some what increased risk of breast



recurrence. This risk is approximately 10 to 15 percent at five years.<sup>21,31,42,43</sup> Some series have also found an increased risk of breast recurrence in patients with high histologic-grade tumors compared with low-grade tumors,<sup>28,42,43</sup> although this has not been a consistent finding.<sup>21</sup> Histologic subtype other than invasive ductal carcinoma does not appear to be associated with an increased or decreased risk of breast recurrence.<sup>44,45</sup>

Patients with invasive lobular cancers are candidates for conservative surgery and radiation, provided that the tumor is not diffuse in the breast and that complete excision with negative margins can be achieved. Under these circumstances, there has been no increased risk of breast recurrence in patients with invasive lobular carcinomas treated with conservative surgery and radiation.<sup>44-46</sup> Patients with positive axillary nodes do not have an increased risk of breast recurrence when treated with conservative surgery and radiation.<sup>4-6,8,21,44,47</sup> This is in contrast to patients undergoing mastectomy where the number of positive axillary nodes correlates with the incidence of chest wall recurrence. The diminished risk of breast recurrence in node-positive patients may be related to the combined effects of chemotherapy and/or tamoxifen with radiation in these patients.

One histopathologic feature that formerly appeared to be associated with a high risk of breast recurrence following conservative surgery and radiation is the presence of an EIC. This entity was first described by the Joint Center for Radiation Therapy (JCRT) and, by its definition, consists of the simultaneous presence of DCIS comprising 25 percent or more of the primary invasive tumor and DCIS in the surrounding normal breast tissue. The definition also includes DCIS with focal areas of invasion. Approximately 20 percent of women with early-stage breast cancer undergoing conservative surgery and radiation for invasive ductal carcinoma have an EIC.

Several series have reported an increased risk of breast recurrence in women with EIC positive

tumors. The risk at ten years has ranged from 22 to 32 percent. The increased risk for breast recurrence in EIC-positive tumors appears to be related to the presence of a significant residual tumor burden following gross excision. However, a number of recent reports have confirmed that negative margins of resection diminish the risk of breast recurrence in EIC-positive tumors.<sup>48,49</sup>

Therefore, while the presence of an EIC is a pathologic indicator that the disease in the breast may be more extensive than what is clinically appreciated, it does not appear to be an independent risk factor for local

recurrence when the margin status is taken into consideration. Patients with EIC-positive tumors in whom the initial margins of resection are positive should undergo re-excision.

If the re-excision margins are negative, current information would suggest that these patients are appropriate candidates for conservative surgery and radiation. If there-excision margins remain positive and further re-excision is not possible, mastectomy is the preferred treatment.

The use of adjuvant systemic therapy has been shown to be an important factor associated with a reduced risk of recurrence in the breast when used in conjunction with conservative surgery and radiation therapy. This is most clearly demonstrated in three randomized clinical trials. In the NSABP B-13 trial, node-negative ER-negative patients were randomized to chemotherapy or to a no treatment control group. Among the 235 patients treated with conservative surgery and radiation therapy, the eight-year rate of recurrence in the ipsilateral breast was 13.4 percent without chemotherapy and only 2.6 percent with chemotherapy.<sup>50</sup> Similar results are seen with adjuvant tamoxifen. In NSABP trial B-14, node-negative ER-positive patients were randomized to tamoxifen or to a placebo. Among the 1,062 patients treated with conservative surgery and radiation therapy, the ten-year rate of recurrence in the ipsilateral breast was 14.7 percent without tamoxifen and only 4.3 percent with tamoxifen.<sup>51</sup> A similar result was seen in the Stockholm Breast Cancer Study Group among node-negative patients randomized to tamoxifen or to a placebo.<sup>52</sup> Among the 432 patients treated with conservative surgery and radiation therapy, the ten-year rate of recurrence in the ipsilateral breast was 12 percent without tamoxifen and only 3 percent with tamoxifen. The impact of the final resection margin on breast recurrence rates varies. Long-term data on the use of breast-conserving therapy in patients with positive margins is limited. In the majority of the reported series, positive margins of resection have been associated with an increased risk of breast recurrence, although the magnitude has varied considerably (Table). The variation in these results may be related to the extent of the surgical resection for the primary tumor, the presence or absence of an EIC, the definition of a positive margin, the number of margins that are positive, and the extent of the margin positivity. In the Milan II trial,<sup>10</sup> the breast recurrence rate for patients with positive margins was 12 percent for those undergoing a quadrantectomy compared with 17 percent for those whose primary surgical procedure was lumpectomy. At the JCRT, patients with positive margins had a considerably higher risk of breast recurrence than patients with negative margins. The eight-year crude rate



of breast recurrence was 18 percent for patients with positive margins. The increased rate of local recurrence seen with positive margins is illustrated in Table 10. Additional experience is needed to confirm this finding, and negative margins should be the goal of breast conserving therapy. A number of recent studies have begun to relate the expression of various biologic markers in the primary tumor to the risk of local recurrence. For example, overexpression of the HER2/neu oncoprotein and insulin like growth factor-1 receptor, and accumulation of the p53 protein have all been reported to be associated with an increased local recurrence risk following conservative 286 surgery and radiation therapy.<sup>54</sup> However, these results should be considered preliminary, and additional studies of this important question are needed. At the present time, it is premature to base recommendations regarding local therapy on the results of such biological marker studies.

#### Pathologic Evaluation

The excised tissue should be submitted for pathology examination with appropriate clinical history and anatomic site specifications including laterality (right or left breast) and quadrant. For wide excisions or segmental breast resections, the surgeon should orient the specimen (e.g., superior, medial, and lateral) for the pathologist with sutures or other markers. Gross

examination should document the type of surgical specimen (e.g., excisional biopsy, quadrantectomy), the size of the specimen, the measured size of the tumor, and the proximity of the tumor or biopsy site to the margins of excision. The presence or absence of tumor at the margins of excision is determined by marking them with India ink or another suitable technique. Frozen section preparation of tissue obtained from image-guided needle biopsies of nonpalpable lesions or tumors less than 1 cm is strongly discouraged.<sup>62</sup> Small foci of invasive carcinoma or microinvasive disease may be lost or rendered uninterpretable by freezing artifact. In general, frozen sections should be prepared only when there is sufficient tissue that the final diagnosis will not be compromised and when the information is necessary for immediate therapeutic decisions.<sup>62</sup> The use of compression devices for specimen radiography may be necessary to visualize the lesion in the specimen. However, these devices may result in falsely close margins, particularly in specimens consisting predominantly of fat. This is due to the compressibility of fat relative to the tumor, rather than to any alteration of the tumor. The pathologist includes certain basic data in each surgical pathology consultation report because they are of prognostic importance or are needed for staging or therapy.

TABLE 10

Recurrence Rates Following Conservative Surgery and Radiation Therapy by Margin Status					
Author (Institution)	Number of Patients (Median f/u)	Endpoint	Negative	Close	Positive
Borger et al. <sup>53</sup> (Netherlands)	1,026 (5.5 years)	5-year actuarial	2%	6%	16%
Dewar et al. <sup>48</sup> (Gustave-Roussy)	757 (9 years)	10-year actuarial	6%	—	14%
Freedman et al. <sup>54</sup> (Fox Chase)	1,262 (6.3 years)	10-year actuarial	7%	14%	12%
Park et al. <sup>55</sup> (JCRT)	533 (10.6 years)	8-year crude rate	7%	7%	14% *27%
Anscher et al. <sup>56</sup> (Duke)	259 (3.7 years)	5-year actuarial	2%	—	10%
Smitt et al. <sup>57</sup> (Stanford)	303 (6 years)	10-year actuarial	2%	16%	0% *9%
Peterson et al. <sup>58</sup> (U Penn)	1,021 (6.8 years)	8-year actuarial	9%	17%	11%
Wazer et al. <sup>59</sup> (Tufts)	498 (6 years)	10-year actuarial	2%	2%	15%
Pittinger et al. <sup>60</sup> (U Rochester)	211 (4.5 years)	Crude rate	3%	—	3% (f/u = 54)
Cowen et al. <sup>61</sup> (Marseille)	152 (6 years)	5-year actuarial	—	—	20%

\*Focally positive.  
f/u = Follow-up.



Features that should be included in the surgical pathology consultation report for invasive carcinoma include:

- How the specimen was received (e.g., number of pieces, fixative, orientation).
- The laterality and quadrant of the excised tissue and the type of procedure as specified by the surgeon.
- The measured size of the tumor (in three dimensions if possible), with verification by microscopic examination, particularly for pT1 lesions or those associated with an EIC.<sup>63,64</sup>
- Histologic type and grade.
- The presence or absence of coexistent DCIS or an EIC.
- The presence or absence of peritumoral vascular or lymphatic invasion.
- The presence or absence of gross or microscopic carcinoma (either invasive carcinoma or DCIS) at the margins of excision. If tumor is not at the margin, the distance of the tumor or biopsy site from the margin should be stated, and the location of the positive or close margin (superior, medial, etc.) identified.
- The presence and location of micro calcifications.
- Lymph node status. This should be recorded as the number of lymph nodes found in the specimen and the number of involved nodes, the size of the largest involved node, and the presence or absence of extension beyond the lymph node capsule.

The presence of a focus of tumor measuring two mm or less within a lymph node identified by routine histologic examination is defined as a micro metastasis and is classified as pN1a. The clinical significance of multiple micro metastatic foci is unknown; however, it is recommended that they also be classified as pN1a until further information becomes available.<sup>64</sup> The significance of individual cells or isolated cellular groups found exclusively by immune histochemistry, either in a lymph node removed by a routine lymph node dissection or in a sentinel node, is unclear. The College of American Pathologists currently recommends that these be classified as pN0.<sup>64</sup> It is important to specify the presence of any special histologic types of invasive breast cancer (e.g., tubular, mucinous, papillary), most of which are considered low grade. All ordinary invasive carcinomas (ductal, no special type [NST]) should be assigned a histologic grade; some authors recommend grading invasive lobular carcinoma as well. If a specific grading system is used, this should be stated in the pathology report. The most commonly used histologic grading system is the Elston modification of the Bloom-Richardson scheme. This system evaluates degree of

tubule formation, nuclear grade, and mitotic rate to determine an overall histologic score.<sup>65</sup> The assessment of surgical margins is arguably the most important aspect in the pathologic evaluation of breast tumor excisions in patients being considered for breast conservation. Although the definitions of “positive” and “negative” margins vary among institutions, microscopic margin involvement appears to be associated with an increased risk of local recurrence and, in most cases, indicates a need for further surgery, such as re-excision of the tumor site. Microscopic confirmation of the presence or absence of regional or distant metastasis must be done when appropriate tissue is submitted for examination. The AJCC/UICC\*\* pTNM classification is recommended for appropriate stage grouping. Determination of estrogen and progesterone receptors is standard for invasive breast carcinomas. This can be done either by the traditional ligand-binding assays performed on snap frozen tissue or by immunohistochemistry performed on routinely fixed tissue sections. The results of ancillary studies (such as steroid receptor analysis, DNA ploidy, proliferative rate, etc.) are usually reported in an addendum or supplement to the surgical pathology report.

### Patient Preferences

Perhaps the most difficult aspect of patient evaluation is the assessment of the patient’s needs and expectations regarding breast preservation. The patient and her physician must discuss the benefits and risks of mastectomy compared with breast conservation treatment in her individual case, with thoughtful consideration of each. Each woman must evaluate how her choice of treatment is likely to affect her sense of disease control, self-esteem, sexuality, physical functioning, and overall quality of life. A number of factors should be considered:

1. Long-term survival.
2. The possibility and consequences of local recurrence.
3. Psychological adjustment (including the fear of cancer recurrence), cosmetic outcome, sexual adaptation, and functional competence.

For most patients, the choice of mastectomy with or without reconstruction or breast conservation treatment does not impact on the likelihood of survival, but it may have a differential effect on the quality of life. Psychological research comparing patient adaptation following mastectomy and breast conservation treatment shows no significant differences in global measures of emotional distress. Research also does not reveal significant changes in sexual behavior and erotic feelings in the treated breast or nipple and areolar complex.



However, women whose breasts are preserved have more positive attitudes about their body image and experience fewer changes in their frequency of breast stimulation and feelings of sexual desirability.<sup>66,67</sup>

## Absolute and Relative Contraindications

In the selection of patients for breast conservation treatment with radiation, there are some absolute and relative contra indications.

### Absolute Contraindications

1. Pregnancy is an absolute contraindication to the use of breast irradiation. However, in many cases, it may be possible to perform breast-conserving surgery in the third trimester and treat the patient with irradiation after delivery.
2. Women with two or more primary tumors in separate quadrants of the breast or with diffuse malignant-appearing microcalcifications are not considered candidates for breast conservation treatment.
3. A history of prior therapeutic irradiation to the breast region that would require retreatment to an excessively high total radiation dose to a significant volume is another absolute contraindication.
4. Persistent positive margins after reasonable surgical attempts. The importance of a single focally positive microscopic margin needs further study and may not be an absolute contraindication.

### Relative Contraindications

1. A history of collagen vascular disease is a relative contraindication to breast conservation treatment because published reports indicate that such patients tolerate irradiation poorly.<sup>68,69</sup> Most radiation oncologists will not treat patients with scleroderma or active lupus erythematosus, considering it an absolute contraindication. In contrast, rheumatoid arthritis is not a relative or an absolute contraindication.
2. The presence of multiple gross tumors in the same quadrant and indeterminate calcifications must be carefully assessed for suitability because studies in this area are not definitive.
3. Tumor size is not an absolute contra indication to breast conservation treatment, although there is little published experience in treating patients with tumor sizes greater than four to five cm. However, a relative contraindication is the presence of a large tumor in a small breast in which an adequate resection would result in

significant cosmetic alteration. In this circumstance, preoperative chemotherapy should be considered.

4. Breast size can be a relative contra indication. Treatment by irradiation of women with large or pendulous breasts is feasible if reproducibility of patient set-up can be assured and the technical capability exists for greater than or equal to six MV photon beam irradiation to obtain adequate dose homogeneity.

### Non-mitigating Factors

There are certain clinical and pathologic features that should not prevent patients from being candidates for breast conservation treatment. These features include the presence of clinically suspicious and mobile axillary lymph nodes or microscopic tumor involvement in axillary nodes. In addition, it is important to emphasize that it is feasible to evaluate the breast for local recurrence. The changes associated with recurrence can be detected at an early stage through the use of physical examination and mammography. The delivery of irradiation in this setting does not result in a meaningful risk of second tumors in the treated area or in the untreated breast.

Tumor location is not a factor in treatment choice. Tumors in a superficial subareolar location may occasionally require the resection of the nipple/areolar complex to achieve negative margins, but this does not impact on outcome. Whether this is preferable to mastectomy needs to be assessed by the patient and her physician.

### Family History

A family history of breast cancer is not a contraindication to breast conservation. Several studies have shown that the rate of breast recurrence in patients with first- or second degree relatives with breast cancer is not different than that seen in patients without a family history of breast cancer. In patients with genetic breast cancer, it is not clear that the risk of ipsilateral breast tumor recurrence is increased. However, these patients appear to be at a substantially increased risk of new primary breast cancers in both the ipsilateral and contralateral breast over time, and this should be considered during the treatment counseling. A high risk of systemic relapse is not a contraindication for breast conservation, but a determinant of the need for adjuvant therapy.

### Preoperative Chemotherapy

Patients who are not candidates for breast conservation on the basis of a large tumor in a small breast should be considered for preoperative chemotherapy to reduce the tumor size. This approach is not appropriate for patients



with evidence of multicentricity on the initial mammogram. The NSABP has reported the results of a large randomized trial in which 1,523 patients with T1-3 N0-1 breast cancer were randomized to surgery followed by four cycles of adriamycin and cyclophosphamide (AC) or AC before surgery.<sup>72,73</sup> At five years of follow-up, no differences in disease-free or overall survival were seen. Breast conservation was able to be performed in 67.8 percent of patients having 290 preoperative chemotherapy versus 59.8 percent having initial surgery ( $p = 0.003$ ). Overall, no difference was seen in the incidence of breast recurrence between the preoperative (7.9 percent) and the postoperative (5.8 percent) groups. However, among patients able to undergo lumpectomy only after downstaging by chemotherapy, the local failure rate was 14.5 percent, compared with 6.9 percent in those believed to be candidates for breast conservation before chemotherapy ( $p = 0.04$ ). The increased risk was observed regardless of patient age or tumor size, and it emphasizes the need for careful attention to evaluation of the extent of disease and the technical details of resection in these patients. Percutaneous placement of tumor marker clips within the primary tumor is recommended for tumors less than five cm in size to provide a landmark for localization and excision should a clinical and radiographic complete response to chemotherapy occur.<sup>74</sup>

## TECHNICAL ASPECTS OF SURGICAL TREATMENT

When breast conservation treatment is appropriate, the goals of any surgical procedure on the breast are total removal of the suspicious or known malignant tissue with minimal cosmetic deformity. These goals apply to either a diagnostic biopsy or definitive local excision prior to radiation therapy. Failure to consider them at all stages may jeopardize conservation of the breast. In most cases, local anesthesia can be utilized for the biopsy. Frequently, local anesthesia also can be used for the definitive local excision, particularly when it is combined with intravenous sedation in selected patients.

### Skin Incision

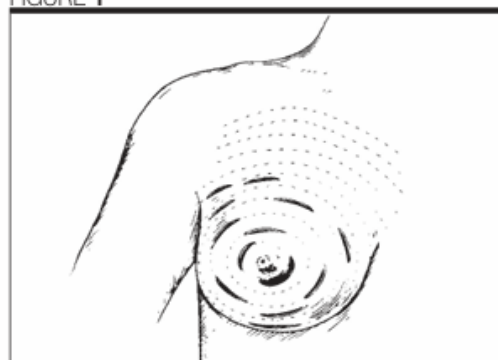
The placement and performance of the skin incision can be critical to the quality of cosmesis. Curvilinear skin incisions following Langer's lines (the natural lines of skin tension) generally achieve the best cosmetic result (Figure 1). However, at the three o'clock and nine o'clock positions and in the lower breast, a radial incision may provide a better result, particularly if skin removal is necessary.

The incision should be over or close to the tumor and of adequate size to allow the tumor to be removed in one piece. In the upper inner aspect of the breast, some

retraction of the skin may be necessary to avoid an incision that may be visible with clothing. Periareolar incisions for lesions in the periphery of the breast are inappropriate.

Excision of a segment of skin rarely is necessary and is undesirable because it may alter the position of the nipple or the inframammary crease. Preservation of the subcutaneous tissue with separate closure improves the cosmetic result. The skin should be closed with a subcuticular technique.

FIGURE 1



Recommended locations of incisions for performing breast biopsy. For larger lesions in the lower breast, particularly when skin must be excised, a radial incision often results in better cosmesis. Reprinted with permission from Bland KI, Copeland EM. *Indications and techniques for biopsy*. In: Bland KI, Copeland EM (eds). *The breast: Comprehensive management of benign and malignant diseases*. Philadelphia, PA: WB Saunders;1998:802-816.

Figure 1:

### Breast Tissue Management

The primary lesion should be excised with a rim of grossly normal tissue, avoiding excessive sacrifice of breast tissue. Very superficial tumors in the subareolar area may require excision of the nipple areolar complex to assure adequate tumor margins and to avoid devascularization. (Partial areolar excision with careful approximation for small lesions in the immediate subareolar area can provide adequate tissue removal and good cosmesis.) Closure of the breast tissue may reduce the occurrence of a saucer-like defect, but the overall cosmetic result with nipple areolar sacrifice will be less than optimal.

Lesions within the substance of the breast should be approached by incising the overlying breast tissue. A superior cosmetic effect is usually achieved when the breast is not reapproximated. Re-approximation that appears to be adequate with the patient relaxed and supine often results in distortion of the breast when the patient is upright and mobile.



Meticulous hemostasis is of critical importance. Hematoma formation produces changes that are difficult to interpret by physical examination. In addition, the evolving scar from a hematoma makes mammography interpretation difficult. These changes may be long lasting and lead to unnecessary biopsy because of the difficulty in evaluation. Drains in the breast should be avoided.

Specimen orientation by the surgeon with the use of sutures, clips, multi colored indelible ink, or another suitable technique is important. The specimen should not be sectioned before it is submitted to the pathologist, because this practice may compromise accurate evaluation of the surgical margins. The surgeon should examine the specimen for the determination of a grossly clear margin. If a clear margin is not evident, re-excision should be performed at that time. Routine frozen section evaluation of margins is optional and does not guarantee negative margins after a complete examination. Any uncertainty regarding orientation of the specimen should be clarified for the pathologist by the surgeon. In addition, clips outlining the breast defect may aid the planning and execution of radiation therapy and demarcate the tumor bed for future imaging studies.

### Image-directed Surgery

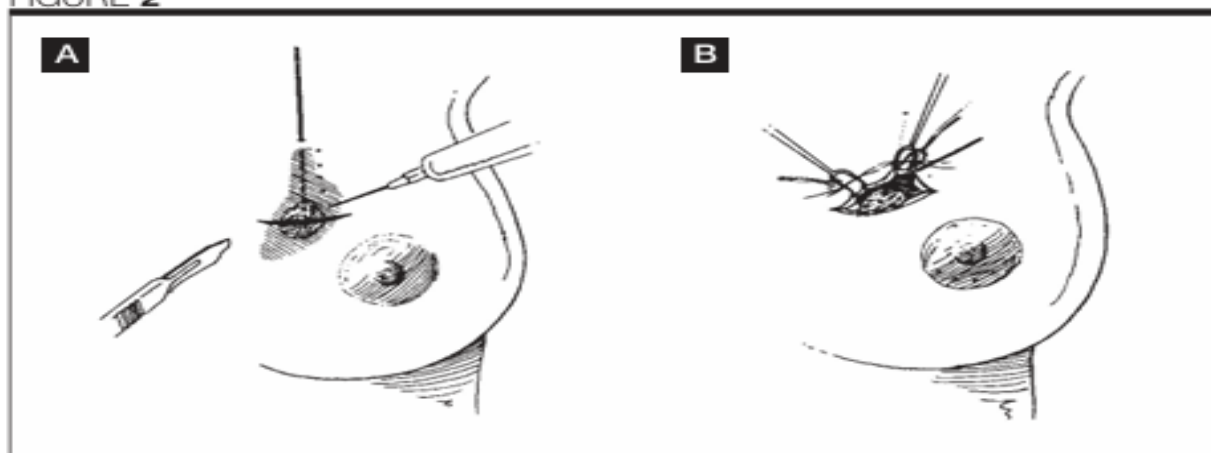
Nonpalpable carcinoma may be diagnosed by image-directed biopsy or needle localization and excision. If a patient has a nonpalpable carcinoma diagnosed by image

guided biopsy, then breast-conserving surgery should be conducted with presurgical localization with a guide such as guidewire. This will be facilitated by the placement of a marker clip when image-guided biopsy is done for small lesions, which are likely to be completely removed by the procedure.

Suspicious lesions detected by mammography require presurgical localization in order to assure accurate removal of the abnormal area and avoid excess sacrifice of breast tissue. The methods of localization may be by needle-hook wire, blue dye injection, or a combination of both. The localization should be precise. Labelled craniocaudal and lateral films that show the hook wire should be sent to the operating room for the surgeon's orientation. The surgeon usually should assess the exact location by triangulation based on the position, depth of penetration, and angle of the wire and place the incision closest to the tip of the wire in order to achieve the best cosmetic result. Tunneling should be avoided, and attempts should be made to make the skin incision as close to the lesion as possible (Figure 2). The same principles of skin incision and breast tissue management used for palpable cancers should be employed.

Localization titanium clips may be left in the excision cavity to aid in placement of irradiation boost volume and to ensure adequate coverage with tangential fields, especially for lateral and medial lesions.

FIGURE 2



A. Incision placement for needle localization biopsy should be over the lesion, not at the point of entry of the wire into the breast. Reprinted with permission from Silen W, Matory EJ Jr, Love S. Atlas of techniques in breast surgery. Philadelphia, PA: Lippincott-Raven;1996:53-54.

B. The breast tissue is dissected until the wire is identified within the parenchyma, and then the wire is stabilized distally and brought into the field. Traction on the wire should be avoided at all times. Reprinted with permission from Silen W, Matory EJ Jr, Love S. Atlas of techniques in breast surgery. Philadelphia, PA: Lippincott-Raven;1996:53-54.



## Specimen Radiograph

A radiograph of the specimen should be obtained, preferably in two dimensions (orthogonal projections). Magnification and compression of the specimen will increase the resolution of the radiograph. The specimen film should be correlated with a preoperative mammogram and interpreted without delay. The radiologist's report should indicate whether the mammographic abnormality (mass or calcifications) is seen in the specimen and if it has been removed completely, as far as can be determined. The proximity of the abnormality to the edge of the resected tissue should be noted. The radiologist should communicate these findings to the surgeon in the operating room before closure so that additional tissue can be removed if it is necessary. Subsequent specimens also should be radiographed. Specimen radiography may be useful in confirming removal of masses that are palpable intraoperatively to ensure that they correspond to the mass lesion seen mammographically.

## Re-excision of Biopsy Site

Re-excision of the previous biopsy site to assure negative margins of resection must be carefully performed in order to accomplish this goal, to avoid excess breast tissue removal and to achieve good cosmesis. Proper orientation of the original biopsy specimen (for example, short suture in the superior margin, long suture in the lateral margin) will allow identification of the individual margin surfaces involved with tumor. Re-excision can be limited to those areas. When the specimen has not been oriented, removal of a rim of tissue around the entire previous biopsy is necessary.

For larger biopsy cavities, shaving of each individual margin, with marking of the new margin surface with sutures, clips, or ink allows removal of residual tumor with preservation of a maximum amount of breast tissue. For very small cavities, removal of the entire biopsy site as an en bloc specimen is acceptable.

## Special Considerations in Patients Receiving Preoperative Chemotherapy

Additional breast imaging studies should be obtained following the planned course of chemotherapy to assess the patient's suitability for breast-conserving therapy. However, mammography does not reliably exclude persistent microscopic tumor; and architectural distortions and calcification do not always indicate residual disease. Breast MRI may be a more accurate method of assessing the extent of residual invasive tumor when expertise with this technique is available. 39,40

The initial surgical resection in these patients should include the removal of any clinically or radiographically

abnormal tissue. If viable tumor is present throughout the specimen even if it does not extend to the margin, a further re-excision should be considered. If additional viable tumor is present in the re-excised specimen, a re-evaluation of the patient's suitability for breast conservation is necessary.

## Management of the Axillary Nodes

Axillary dissection is the standard technique for management of the axillary nodes. A Level I and II axillary dissection will provide accurate staging information and maintain local control in the axilla. In the patient undergoing mastectomy, axillary dissection should be performed through the mastectomy ellipse. In the patient undergoing breast conservation, the breast incision and the axillary incision should be separate. A continuous incision from the breast to the axilla results in unnecessary deformity. Occasionally, a tumor in the axillary tail can be removed through the same incision used to remove the axillary nodes. A transverse incision in the low axilla from just posterior to the border of the pectoralis major to nearly the anterior border of the latissimus dorsi obtains an excellent cosmetic result and excellent exposure. Some surgeons prefer a vertical incision posterior and parallel to the border of the pectoralis major, which also provides good exposure and cosmetically good results. During dissection, the long thoracic nerve, the thoracodorsal nerve, and the medial pectoral nerve should be preserved. Preservation of the intercostal brachio-cutaneous nerve is desirable, as numbness of the posterior upper arm is less likely to occur with nerve preservation. At times, preservation of this nerve should not be performed because of grossly involved lymph nodes. Stripping of the axillary vein is unnecessary and should be condemned because it increases the incidence of lymphedema. Usually, closed suction drainage is advisable. Recently, an alternative to axillary dissection, a sentinel node biopsy or sentinel lymph node dissection, has become popular. This procedure has been extremely successful at a number of major institutions. However, its widespread applicability remains to be determined, and long-term follow-up on a significant number of women undergoing sentinel node biopsy alone is lacking. For these reasons, the technique should be considered investigational at most centers. Lymphatic mapping for sentinel lymph node dissection can be accomplished with one percent isosulfan blue dye or radiolabeled colloids. Usually, a combination of technetium sulfur colloid and dye is used. 75-78 Sentinel node dissection is indicated for small primary tumors with clinically negative axillary lymph nodes and no prior axillary surgery. Pregnancy or multicentric carcinomas are contraindications. Experience with the technique after neoadjuvant chemotherapy is limited and



the available studies suggest a high false-negative rate. Sentinel node dissection in this circumstance should be considered investigational and be performed only under investigational protocols.

For patients who require preoperative chemotherapy, sentinel node biopsy can be performed prior to the initiation of chemotherapy. In general, patients with metastases in sentinel nodes detected in hematoxylin and eosin-stained sections should undergo complete Level I and II axillary dissection. Immunohistochemistry should not be routinely performed, as the significance of metastases in sentinel nodes detected only by immunohistochemistry remains to be determined. Therapeutic decisions should be made on the basis of metastases identified by hematoxylin and eosin staining.

In experienced hands, this sentinel node dissection has been shown to be extremely accurate in predicting axillary status and is likely to replace axillary lymph node dissection for women with tumor-free sentinel nodes. Experience with this technique prior to abandoning axillary lymph node dissection is essential. Surgeons should perform both sentinel node biopsy and axillary lymph node dissection until they are confident that the procedure can be performed with identification of sentinel nodes in at least 90 percent of patients with a false-negative rate of 10 percent or less. For most surgeons, this requires 20 to 30 sentinel node biopsies followed by axillary dissections to determine an individual surgeon's technical accuracy.<sup>79,80</sup> Level I and II axillary lymph node dissection should be performed as standard therapy.

Sentinel node biopsy usually results in minimal morbidity; however, rehabilitation after axillary lymph node dissection or sentinel node biopsy is essential. Usually, patients after sentinel node biopsy require no formal exercise to return to full function. Patients after axillary dissection should be given formal exercise training to prevent a frozen shoulder. Use of shoulder immobilization and arm slings or 294 wraps should be avoided, as these contribute to a frozen shoulder. If a patient does not achieve early recovery of full shoulder function (by six to eight weeks), physical therapy should be instituted to avoid permanent dysfunction.

## TECHNIQUES OF IRRADIATION

A multidisciplinary approach is necessary for optimal breast conservation treatment. Radiation therapy should be delivered only after evaluation of the mammography findings, the pathology findings, and the surgical procedures performed on the patient. The optimal combination of surgery and irradiation to achieve the dual objectives of local tumor control and preservation of cosmetic appearance varies from patient to patient. The

optimal combination is determined by the extent, nature, and location of the tumor, the patient's breast size, and the patient's relative concerns about local recurrence and preservation of cosmetic appearance. Close cooperation between radiation oncologists and medical oncologists also is important because irradiation and adjuvant chemotherapy require integration if both treatment modalities are used.

## Elements in the Technique of Irradiation

There is a general consensus regarding some but not all of the elements in the technique of irradiation. Treatment facilities should conform to American College of Radiology standards for radiation oncology facilities. As soon as the patient has healed adequately from the surgical procedure, radiation therapy should begin. Therefore, irradiation usually can begin within two to four weeks of uncomplicated breast conserving surgery.

The radiation oncologist should use measures to assure reproducibility of patient set-up, treatment simulation, treatment planning, and choice of super voltage equipment to assure dose homogeneity. High energy photons ( $\geq 10$  MV) may be indicated for very large-breasted women or for patients with significant-dose inhomogeneity on treatment planning using lower energy photons.

The radiation oncologist can use sophisticated treatment planning that involves three- rather than two-dimensional dose distributions and accounts for the lower density of lung tissue in the treatment field. (In standard treatment planning, the lung is considered to have unit density.) However, the impact of this recent development on patient outcomes has not been demonstrated. Currently, three-dimensional dose distributions are not considered standard.

Each field should be treated on a daily basis, Monday through Friday. Bolus should not be used. In order to minimize the risk of radiation pneumonitis, not more than 3 to 3.5 cm of lung as projected on the beam radiograph at isocenter should ordinarily be treated, and a minimum of 1 to 1.5 cm of lung is required.<sup>81</sup> For left-sided lesions, efforts should be made to minimize the amount of heart in tangential Whole breast radiation therapy is delivered using opposed tangential fields to a dose of 4,500 to 5,000 cGy at 180 to 200 cGy per fraction.

Although controversy has existed concerning the need for delivering an additional boost dose to the primary site,<sup>85-87</sup> there is growing consensus about its utility.<sup>87,88</sup> Most recently, the EORTC has reported the favorable impact of boost on local failure rates.<sup>88</sup> Several considerations may be involved in the decision to use a



boost: histological studies show that residual cancer following resection of the primary cancer usually is in the vicinity of the primary site;<sup>89</sup> recurrences following treatment usually are seen at or near the primary site;<sup>90</sup> and boost treatment can be delivered without significant morbidity.<sup>91</sup> Although boost irradiation generally is used, the precise indications for its use are not well defined. However, research indicates that a boost should be used in patients with focally positive or close margins of resection.

Boost irradiation usually is delivered using electron beam or interstitial implantation. The total dose to the primary tumor site is increased to approximately 6,000 to 6,600 cGy. Selection of the boost dose and volume should be based on knowledge of the surgical procedure and the pathologic findings. In situations where an electron beam boost and an interstitial implant boost are judged to be equally effective, an electron beam is generally preferred because of considerations of cost, patient convenience, and cosmesis.<sup>92</sup>

A boost may not be required for patients who have been treated with more extensive breast resections and have margins of resection that are clearly negative.<sup>13</sup> If the breast boost is omitted in these patients, the only available data indicate that the standard whole breast radiation therapy dose is 5,000 cGy at 200 cGy per fraction.<sup>3,4,6,9,14</sup>

## Techniques To Be Avoided

Although there is a lack of consensus concerning the advisability of treating nodal areas with irradiation, there is agreement on the need to avoid certain radiation therapy techniques for the treatment of regional lymph nodes:

1. Axillary irradiation usually is unnecessary following a complete axillary dissection (Levels I to III). Irradiation of the supraclavicular fossa and contiguous apical region may be considered if extensive numbers of lymph nodes (e.g., greater than or equal to four) contain tumor. The benefit of radiation in patients with one to three positive nodes is unknown.
2. Overlap between adjacent fields should be avoided.
3. Techniques that result in cardiac irradiation should be avoided given the known increase in late cardiac mortality with inadvertent irradiation of the heart. The use of computed tomography (CT) simulation is encouraged for patients with left-sided breast cancer to aid in minimizing cardiac irradiation.

## FOLLOW-UP CARE

Follow-up assessment of the results of breast conservation treatment emphasizes the cosmetic outcome as well as the detection of local recurrence. Regular follow-up examination includes the following goals:

1. Early detection of recurrent or new cancer, allowing timely intervention.
2. Identification of any treatment sequelae and appropriate interventions where indicated.
3. Providing the individual practice with the database necessary to optimize treatment and compare outcomes against national standards.

Regular history and physical examination in conjunction with breast imaging are the cornerstones of effective follow-up care. Unfortunately, many patients perceive history and physical examination to be less important as reliable follow-up measures than sophisticated medical testing. A public education effort is needed to address this problem.

The following evaluations should be performed by the physician at cited intervals following the completion of treatment:

## Examinations and Mammography

### History and Physical Examination

Local failure occurs at a constant rate from years two through eight post-treatment; therefore, examination frequency should be based on risk factors for both local and distant recurrence.

### EXAMINATION FREQUENCY

- Every three to six months, years one to three. This will vary for patients receiving adjuvant chemotherapy who need more frequent assessment during the course of their active treatment.
- Every six months, years four and five. Some investigators prefer to continue semi-annual examinations through year eight because the rate of local recurrence is constant through that time interval.
- Annually after year five. More frequent follow-up for patients at exceptionally high risk may be needed.

## Mammography

A goal of follow-up imaging of the treated breast is the early recognition of tumor recurrence. To prevent unnecessary biopsy, it is important to know that postoperative and irradiation changes overlap with signs of malignancy on a mammogram. The changes include



masses (postoperative fluid collections and scarring), edema, skin thickening, and calcifications.<sup>95,96</sup>

At times, these changes may be impossible to distinguish. Post-surgical and radiation edema, skin thickening, and postoperative fluid collections will be most marked in the first six months. After the first six to 12 months, radiographic changes will slowly resolve and demonstrate stability within two years for most patients.<sup>95-100</sup>

In order to interpret mammograms accurately and assess the direction of change, the current mammogram must be compared in sequence with preceding studies. The diagnostic radiologist can tailor mammographic studies of the treated breast to the surgical site by using special mammographic views in addition to routine mediolateral oblique and craniocaudal views. Magnification and spot compression can be used with any view to increase detailed visualization of the site of tumor excision and other areas. Magnification mammography is useful to classify calcifications morphologically and quantitate them. In some cases, a view with the x-ray beam tangential to the scar and various other additional obliquities will be helpful to differentiate recurrent tumor from postprocedural changes.

Ultrasonography can characterize a postoperative mass, such as a seroma, as fluid filled rather than solid. As these masses resolve and scars form; a spiculated soft-tissue density that mimics tumor may be seen on the mammogram. Additional radiographic projections of the site of tumor removal will facilitate more confident radiographic interpretations.

## **SCHEDULE OF IMAGING OF THE TREATED BREAST**

1. Postoperative, pre-radiation therapy mammography is particularly important after malignant microcalcifications have been removed or if the adequacy of the resection is questioned. Magnification mammography can be useful in identifying or verifying possible residual malignant calcifications.
2. A baseline mammogram for comparison should be performed six to nine months after tumor excision and completion of all therapies.
3. At least annually thereafter or at more frequent intervals as warranted by clinical or radiographic findings.

## **SCHEDULE OF IMAGING OF THE CONTRALATERAL BREAST**

Mammography should be performed annually according to the guidelines endorsed by both the American College of Radiology and the American Cancer Society and with

synchronization of surveillance mammography of the treated breast. More frequent intervals may be warranted by clinical or radiographic findings. (The risk of cancer is approximately the same for both the treated and untreated breast.)

## **Other Tests**

Symptomatic patients are justifiably evaluated with other medical tests (e.g., radionuclide bone scan, chest radiography, CT scans, liver function tests) as indicated by the character of their medical problem. An annual chest x-ray in patients who smoke may be appropriate. Randomized, controlled trials have shown that routine use of these tests has provided no benefit for asymptomatic patients with Stage I or II breast carcinoma.

No survival benefits have been demonstrated, and the cost effectiveness of using such procedures in routine follow-up is seriously in question.

## **Evaluation of Sequelae**

At the time of the first follow-up examination and serially thereafter, the physician should evaluate the patient for any treatment-related toxicities. This evaluation should include:

1. Assessment of the overall cosmetic result. A four-point scoring system is recommended for assessing the cosmetic result (Appendix A).
2. Assessment of complications. Complications should be specified with regard to symptomatology and physical findings. The use of the Radiation Therapy Oncology Group (RTOG)/EORTC Radiation Toxicity Scoring Scheme is recommended for the grading of complications. In addition, the simple measurement of arm circumference at fixed distances above and below the olecranon is recommended for the evaluation and quantification of arm edema.
3. Patient evaluation of results. The patient's evaluation of treatment outcomes in terms of psychological, functional, and cosmetic consequences should be taken into account in the follow-up process.

## **REFERENCES**

1. Veronesi U, Banfi A, Del Vecchio M, *et al.* Comparison of Halsted mastectomy with quadrantectomy, axillary dissection, and radiotherapy in early breast cancer: Long-term results. *Eur J Cancer Clin Oncol* 1986;22:1085-1089.
2. Veronesi U, Salvadori B, Luini A, *et al.* Conservative treatment of early breast cancer.



- Long-term results of 1,232 cases treated with quadrantectomy, axillary dissection, and radiotherapy. *Ann Surg* 1990;211:250-259.
3. Arriagada R, Le MG, Rochard F, *et al.* Conservative treatment versus mastectomy in early breast cancer: Patterns of failure with 15 years of follow-up data. Institut Gustave-Roussy Breast Cancer Group. *J Clin Oncol* 1996;14:1558-1564.
  4. Fisher B, Anderson S, Redmond CK, *et al.* Reanalysis and results after 12 years of follow-up in a randomized clinical trial comparing total mastectomy with lumpectomy with or without irradiation in the treatment of breast cancer. *N Engl J Med* 1995;333:1456-1461.
  5. Fisher B, Redmond C, Poisson R, *et al.* Eight year results of a randomized clinical trial comparing total mastectomy and lumpectomy with or without irradiation in the treatment of breast cancer. *N Engl J Med* 1989;320:822-828.
  6. Jacobson JA, Danforth DN, Cowan KH, *et al.* Ten-year results of a comparison of conservation with mastectomy in the treatment of Stage I and II breast cancer. *N Engl J Med* 1995;332:907-911.
  7. van Dongen JA, Voogd AC, Fentiman IS, *et al.* Long-term results of a randomized trial comparing breast-conserving therapy with mastectomy: European Organization for Research and Treatment of Cancer 10801 trial. *J Natl Cancer Inst* 2000;92:1143-1150.
  8. van Dongen JA, Bartelink H, Fentiman IS, *et al.* Factors influencing local relapse and survival and results of salvage treatment after breast-conserving therapy in operable breast cancer: EORTC trial 10801, breast conservation compared with mastectomy in TNM Stage I and II breast cancer. *Eur J Cancer* 1992;28A:801-805.
  9. Blichert-Toft M, Rose C, Anderson JA, *et al.* Danish randomized trial comparing breast conservation therapy with mastectomy: Six years of life table analysis. Danish Breast Cancer Cooperative Group. *J Natl Cancer Inst Monogr* 1992;11: 19-25.
  10. Veronesi U, Luini A, Galimberti V, *et al.* Conservation approaches for the management of Stage I/II carcinoma of the breast: Milan Cancer Institute trials. *World J Surg* 1994;18:70-75.
  11. Early breast cancer trialists' collaborative group. Effects of radiotherapy and surgery in early breast cancer. An overview of the randomized trials. *N Engl J Med* 1995;333:1444-1455.
  12. Liljegren G, Holmberg L, Bergh J, *et al.* 10 year results after sector resection with or without postoperative radiotherapy for Stage I breast cancer: A randomized trial. *J Clin Oncol* 1999; 17:2326-2333.
  13. Veronesi U, Luini A, Del Vecchio M, *et al.* Radiotherapy after breast preserving surgery in women with localized cancer of the breast. *N Engl J Med* 1993;328:1587-1591.
  14. Clark RM, Whelan T, Levine M, *et al.* Randomized clinical trial of breast irradiation following lumpectomy and axillary dissection for node-negative breast cancer: An update. *J Natl Cancer Inst* 1996;88:1659-1664.
  15. Wolmark N, Dignam J, Margolese R, *et al.* The role of radiotherapy and tamoxifen in the management of node negative invasive breast cancer 1.0 cm treated with lumpectomy: Preliminary results of NSABP protocol B-21 (abstract). *Proc Am Soc Clin Oncol* 2000;19:70a.