



Evaluation of Two Expedient Techniques in Reducing Metal Artifacts in Cone Beam Computed Tomography (CBCT)

Dr. Lakshmisasi Poluri¹, Dr. Swathi Myla², Dr. Buddha Syam Deepthi³, Dr. Sahithi Ram Vatram⁴, Dr. Vyshnavi Durga Gandhi⁵, Dr. Bhanu Teja Pallagani⁶

¹Post Graduate Student, Department of Oral Medicine and Radiology, St. Joseph Dental College, Duggirala, Eluru, Andhra Pradesh, India (Corresponding Author)

²Reader, Department of Oral Medicine and Radiology, St. Joseph Dental College, Duggirala, Eluru, Andhra Pradesh, India

³Post Graduate Student, Department of Oral Medicine and Radiology, St. Joseph Dental College, Duggirala, Eluru, Andhra Pradesh, India

⁴Post Graduate Student, Department of Oral Medicine and Radiology, St. Joseph Dental College, Duggirala, Eluru, Andhra Pradesh, India

⁵Post Graduate Student, Department of Oral Medicine and Radiology, St. Joseph Dental College, Duggirala, Eluru, Andhra Pradesh, India

⁶Post Graduate Student, Department of Oral Medicine and Radiology, St. Joseph Dental College, Duggirala, Eluru, Andhra Pradesh, India

Corresponding Author: Dr. Lakshmisasi Poluri

(Received: 16 July 2025

Revised: 20 August 2025

Accepted: 20 September 2025)

KEYWORDS

Metal Artifacts,
Cone Beam
Computed
Tomography,
Implant,
Imaging,
Maxillofacial
Structures

ABSTRACT:

Cone Beam Computed Tomography (CBCT) has become an indispensable imaging modality in dentistry, providing high-resolution three-dimensional imaging of maxillofacial structures. However, the presence of metallic restorations and prostheses often produces artifacts, particularly beam hardening and streak artifacts, which may compromise diagnostic accuracy. This study evaluates two expedient techniques—the puffed-out technique and cotton roll placement—for their efficacy in reducing metal artifacts in CBCT scans. Fifty patients with metallic crowns and restorations were included and randomly assigned into two groups. Group A employed the puffed-out technique where patients puffed their cheeks during imaging, while Group B involved placement of cotton rolls buccally and lingually adjacent to crowns. Artifact severity was assessed using linear and angular measurements of streaks. The puffed-out technique showed minimal effect, with results statistically not significant ($p > 0.05$), while cotton roll placement demonstrated a statistically significant reduction in streak artifacts ($p \leq 0.05$). These findings suggest that cotton roll placement is a simple, inexpensive, and clinically effective method to reduce CBCT metal artifacts and improve diagnostic accuracy.

Introduction

Cone Beam Computed Tomography (CBCT) has revolutionized dental and maxillofacial imaging by providing high-resolution volumetric datasets with relatively low radiation dose compared to conventional computed tomography^{1,2}. CBCT is widely used for implant planning, evaluation of pathologies, orthodontic

assessment, endodontic diagnosis, and maxillofacial surgery. Despite its advantages, the modality is susceptible to image degradation in the presence of high-density materials such as metallic crowns, posts, and implants. These materials cause artifacts that manifest as streaks, beam hardening, cupping artifacts, and noise, which obscure anatomical structures and



complicate diagnosis^{3,4}. Beam hardening is the most common metal-induced artifact in CBCT. It occurs when low-energy X-ray photons are preferentially absorbed by dense materials, resulting in a hardened X-ray beam with higher mean energy. The differential absorption leads to streaks and dark bands adjacent to metallic objects. In clinical scenarios where patients have multiple metallic restorations, the severity of artifacts increases dramatically. Various correction methods have been proposed, including algorithmic reconstructions, advanced software corrections, and hardware-based approaches, but these are often expensive and not universally available⁵⁻⁶.

As an alternative, simple clinical techniques have been explored to reduce artifacts at the patient level. The puffed-out technique, which involves inflating the cheeks and lips during scanning, has been hypothesized to displace soft tissues and alter airspace distribution, thereby minimizing superimposition errors. Another approach is the placement of cotton rolls buccally and lingually near crowns, which alters the surrounding tissue-air interface and may reduce beam hardening effects. While these approaches are inexpensive and easily applicable, their efficacy in reducing metal artifacts in CBCT imaging has not been extensively validated^{7,8}.

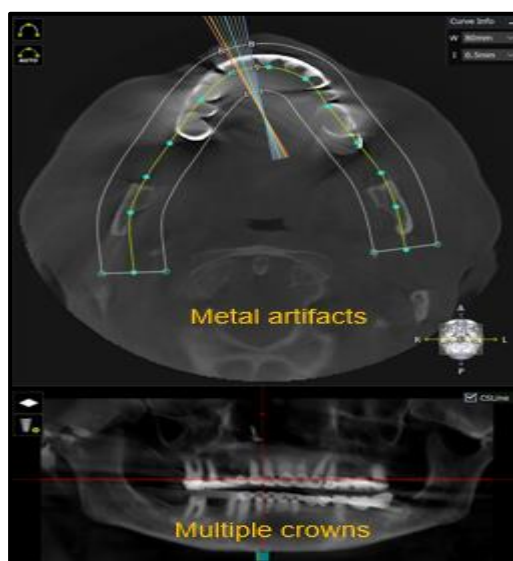


Figure 1. Axial CBCT slice and panoramic view showing metal-induced artifact streaks adjacent to crowns

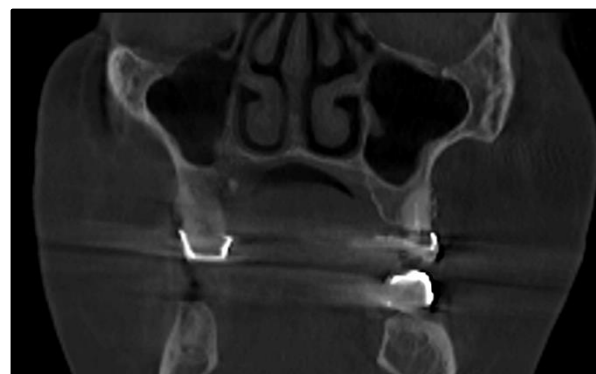

Figure 2. Sagittal CBCT slice showing metal-induced artifact streaks adjacent to crowns

Aim and Objectives

The aim of this study was to evaluate and compare the effectiveness of two clinical techniques—the puffed-out technique and cotton roll placement—in reducing metal artifacts in CBCT imaging of patients with metallic crowns and restorations. The objectives were:

1. To quantify and compare the number of streak artifacts produced in normal CBCT scans, puffed-out technique scans, and cotton roll placement scans.
2. To measure and compare linear and angular dimensions of streaks between the two techniques.
3. To assess the statistical significance of differences in artifact reduction between techniques.

Materials and Methods

The study received approval from the Institutional Ethical Committee of St. Joseph Dental College and Hospital. [IEC PROTOCOL NUMBER: SJDC/CEC/OMR/2025/009] A total of 50 patients presenting with metallic crowns and restorations were selected for this study using convenience sampling. Patients were randomly assigned into two groups: Group A (n=25), in which the puffed-out technique was employed, and Group B (n=25), in which cotton roll placement was used. The inclusion criteria included patients with single or multiple crowns or metallic restorations that required CBCT imaging for diagnostic or treatment planning purposes. Exclusion criteria included patients unable to cooperate with the procedures or those with contraindications to CBCT imaging. All scans were performed using the Rainbow



CT (Dentium Co. Ltd., South Korea) with standardized exposure parameters. For Group A, patients were instructed to puff out their cheeks and lips throughout the scan. For Group B, cotton rolls were placed buccally and lingually adjacent to metallic crowns to alter airspace and soft tissue positioning. Images were reconstructed and evaluated using the Rainbow 3D viewer (software version 1.1.0). Artifacts were assessed in axial sections of CBCT scans. The number of streak artifacts was recorded, and linear and angular measurements of streaks were obtained for quantitative analysis. Data were subjected to statistical analysis using the student's t-test, with p-values ≤ 0.05 considered statistically significant.

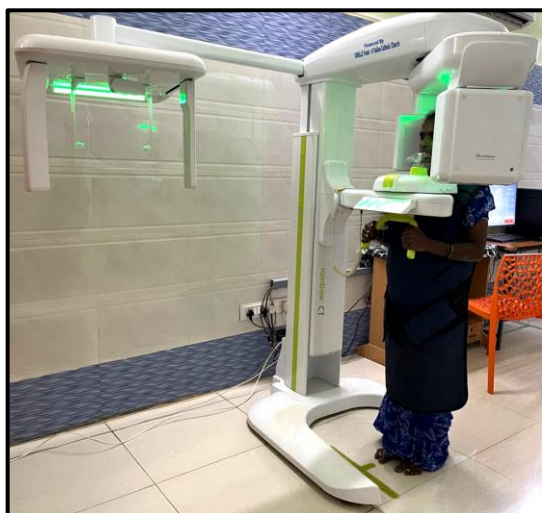

Figure 3. CBCT device setup showing the Rainbow CT system (Dentium Co. Ltd.) with a patient positioned for scan acquisition as used in this study

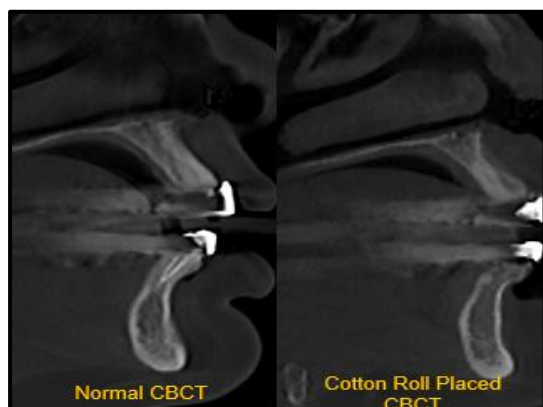


Figure 4. Comparison of normal CBCT (left) and cotton roll placed CBCT (right) illustrating artifact reduction using physical adjuncts

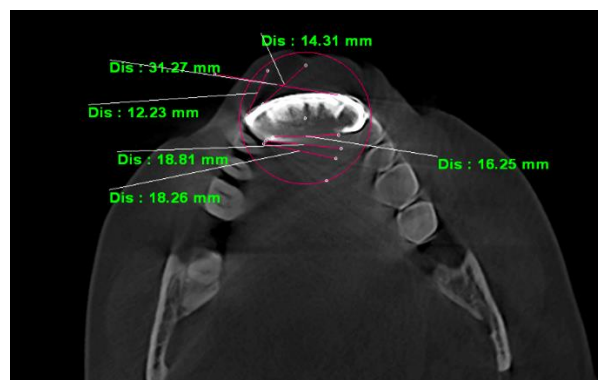


Figure 5. Measurement overlays on axial CBCT scan indicating linear distances of artifact streaks around metallic restorations used for quantitative artifact assessment.

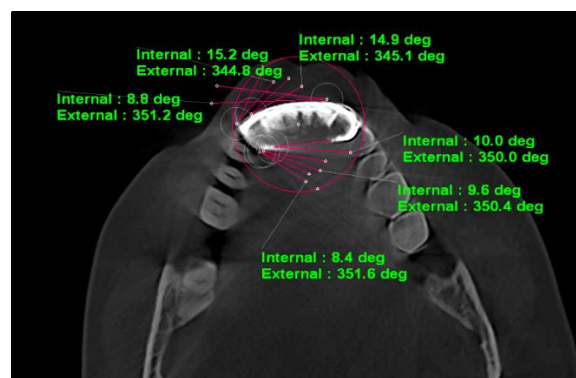


Figure 6. Angular measurements of artifact streaks marked on axial CBCT images displaying degrees of artifact spread around crowns

Results

The data obtained from the evaluation of streak artifacts in CBCT scans were subjected to statistical analysis. In the puffed-out technique group (Group A), there was no significant difference in the mean number of streak artifacts when compared with normal CBCT scans without artifact-reduction techniques. The student's t-test revealed that the differences in both the number of streaks and the linear and angular measurements of artifacts were statistically not significant ($p > 0.05$). This suggests that the puffed-out technique did not substantially reduce the severity of metal artifacts in patients with metallic crowns. In contrast, the cotton roll placement group (Group B) demonstrated a marked reduction in the number of streak artifacts. Quantitative assessment revealed a statistically significant decrease ($p \leq 0.05$) in both the



number of streaks and their linear and angular dimensions compared to normal CBCT scans. The cotton roll placement technique effectively minimized the beam hardening artifacts arising from metallic

crowns and restorations. Specifically, the reduction in streak artifacts was calculated to be approximately 70.77%, indicating a strong potential for clinical application of this simple technique⁹.

	GROUPS	Mean	Std. Deviation	t	p
STREAKS	NORMAL	6.3600	1.99750	-0.410	0.684*
	PUFFED OUT TECHNIQUE	6.6000	2.14087		
T test *Not Significant					

Table 1: Number Of Streaks in Normal and Puffed Out Technique Groups

	GROUPS	Mean	Std. Deviation	t	p
STREAKS	NORMAL	6.1600	1.86369	3.686	0.001*
	COTTON ROLLS PLACEMENT	4.3600	1.57797		
T test *Significant					

Table 2: Number of Streaks in Normal and Cotton Roll Placement Groups

	GROUPS	Mean	Std. Deviation	t	p
LINEAR	NORMAL	10.0855	5.33933	-0.747	0.455
	PUFFED OUT	10.4890	4.72577		
ANGULAR	NORMAL	21.9966	14.63365	-0.191	0.848
	PUFFED OUT	22.2790	12.87162		
T test *Not Significant					

Table 3: Linear & Angular Measurements in Normal and Puffed Out Technique Groups

	GROUPS	Mean	Std. Deviation	t	p
LINEAR	NORMAL	10.8601	4.63425	5.505	0.000
	COTTON ROLLS	7.5546	5.91550		
ANGULAR	NORMAL	24.4573	15.32995	3.094	0.002
	COTTON ROLLS	18.9033	16.41781		
T test *Significant					

Table 4: Linear & Angular Measurements in Normal and Cotton Roll Placement Groups



Discussion

The present study aimed to evaluate the effectiveness of two simple, clinically applicable methods—the puffed-out technique and cotton roll placement—for reducing metal artifacts in CBCT imaging. The findings demonstrate that while the puffed-out technique did not significantly impact artifact reduction, the cotton roll placement technique significantly minimized streak artifacts, thereby enhancing image quality. Artifacts in CBCT remain one of the primary limitations of this imaging modality. The generation of artifacts, particularly beam hardening, results from the interaction between X-ray photons and dense metallic objects, leading to differential attenuation and streak patterns in the reconstructed images. These artifacts can obscure critical anatomical details, thereby compromising diagnostic accuracy in endodontics, implantology, and oral pathology. As previous literature suggests (Schulze et al., 2011¹⁰; Queiroz et al., 2018¹¹), artifact severity increases with the number and density of metallic restorations. The puffed-out technique was hypothesized to reduce artifacts by creating an air-filled buffer zone around the crowns, potentially displacing soft tissues and minimizing superimposition errors. Yaser et al. (2018)¹² reported limited success with this method in isolated cases, particularly in anterior regions with fewer prosthetic elements. However, in the present study, patients struggled to maintain a consistent puffed-out posture throughout the scan duration, leading to motion artifacts that negated any potential benefits. This explains the lack of statistical significance observed with this technique. Conversely, cotton roll placement proved to be an effective strategy. By placing cotton rolls buccally and lingually adjacent to metallic restorations, the technique altered the surrounding airspace and reduced the abrupt differences in tissue density. Given that cotton has attenuation properties similar to air (approximately 1000 Hounsfield Units), it effectively minimized the beam hardening gradient, resulting in fewer and less severe streak artifacts. Furthermore, cotton rolls provided stability without introducing motion artifacts, unlike the puffed-out technique. The results of this study align with previous investigations that emphasize physical or patient-based interventions for artifact reduction. Safi et al. (2019)¹³ introduced a similar approach using anterior teeth and found significant artifact reduction. Moreover, studies

by Queiroz et al. (2018)¹¹ and Schulze et al. (2010)¹⁴ underscore that software corrections alone are insufficient in many clinical cases, thereby highlighting the importance of adjunctive physical methods. From a clinical perspective, the cotton roll placement technique offers several advantages: it is simple, cost-effective, requires no additional equipment, and can be applied universally across dental practices. The technique is particularly valuable in implant planning and evaluation of periapical pathology, where artifact-free visualization of the bone-implant interface and periapical structures is critical.

Nevertheless, limitations of this study should be acknowledged. The sample size was relatively small (n=50), and convenience sampling may introduce bias. Additionally, the study was limited to a single CBCT system (Rainbow CT, Dentium Co. Ltd.), and results may vary across different machines and exposure parameters. Future studies with larger cohorts, diverse CBCT systems, and advanced quantitative analysis are necessary to validate the reproducibility of these findings¹⁵⁻²⁰.

Conclusion

Within the limitations of this study, it can be concluded that cotton roll placement is a significantly effective technique for reducing metal artifacts in CBCT imaging. The method produced a 70.77% reduction in streak artifacts, thereby improving diagnostic accuracy and enhancing image interpretation in patients with metallic crowns and restorations. In contrast, the puffed-out technique was found to be ineffective, largely due to motion artifacts and patient difficulty in maintaining the posture during scanning. The incorporation of cotton roll placement as a routine adjunct during CBCT imaging of patients with multiple metallic restorations may be recommended for clinical practice. Further research is warranted to explore its application across various clinical settings and imaging systems.

References

1. Safi Y, Fazlyab M, Asgary S, Fazlalipour M. A novel technique for minimizing the metal artifacts on anterior teeth in cone-beam computed tomography. *Iran Endod J.* 2019;14(1):79-83.
2. Queiroz PM, Santaella GM, Groppo FC, Freitas DQ. Metal artifact production and reduction in



- CBCT with different numbers of basis images. *Imaging Sci Dent.* 2018;48(1):41-44.
- Syam T, Shilpa, Maheswari T. Artifacts in cone beam computed tomography – A retrospective study. *VJIM.* 2019.
 - Madhavi V, Mishra A, Srivastava S, Sinha P, Chaurasia A. Understanding artifacts in cone beam computed tomography. *J Clin Diagn Res.* 2020.
 - Schulze R, Heil U, Gross D, Bruellmann DD, Dranischnikow E, Schwanecke U, Schoemer E. Artefacts in CBCT: a review. *Dentomaxillofac Radiol.* 2011;40(5):265-73.
 - Schulze RK, Berndt D, d'Hoedt B. On cone-beam computed tomography artifacts induced by titanium implants. *Clin Oral Implants Res.* 2010;21(1):100-7.
 - Bechara B, Moore WS, McMahan CA, Noujeim M. Metal artifact reduction with cone beam CT: An in vitro study. *Dentomaxillofac Radiol.* 2012;41(3):248-253.
 - Katsumata A, Hirukawa A, Okumura S, Naitoh M, Fujishita M, Arijji E, et al. Effects of image artifacts on gray-value distribution in limited-volume cone-beam computerized tomography. *Oral Surg Oral Med Oral Pathol Oral Radiol Endod.* 2007;104(6):829-836.
 - Pauwels R, Beinsberger J, Collaert B, Theodorakou C, Rogers J, Walker A, et al. Effective dose range for dental cone beam computed tomography scanners. *Eur J Radiol.* 2012;81(2):267-271.
 - Barrett JF, Keat N. Artifacts in CT: Recognition and avoidance. *Radiographics.* 2004;24(6):1679-1691.
 - Scarfe WC, Farman AG, Sukovic P. Clinical applications of cone-beam computed tomography in dental practice. *J Can Dent Assoc.* 2006;72(1):75-80.
 - Boas FE, Fleischmann D. CT artifacts: Causes and reduction techniques. *Imaging Med.* 2012;4(2):229-240.
 - Nascimento EH, Fontenele RC, Santaella GM, Freitas DQ. Influence of metallic artifacts on the diagnosis of vertical root fractures in CBCT images. *DentomaxillofacRadiol.* 2017;46(1):20160107.
 - Watanabe H, Honda E, Kurabayashi T. Modulation transfer function evaluation of cone beam computed tomography for dental use with the oversampling method. *DentomaxillofacRadiol.* 2010;39(1):28-32.
 - Bryant JA, Drage NA, Richmond S. Study of the scan uniformity from an i-CAT cone beam computed tomography dental imaging system. *DentomaxillofacRadiol.* 2008;37(7):365-374.
 - Schulze R, Berndt D, d'Hoedt B. Artefacts in CBCT: Improved understanding and potential solutions. *DentomaxillofacRadiol.* 2011;40(5):265-73.
 - Pauwels R, Araki K, Siewerdsen JH, Thongvigitmanee SS. Technical aspects of dental CBCT: State of the art. *DentomaxillofacRadiol.* 2015;44(1):20140224.
 - Katsumata A, Hirukawa A, Okumura S, Naitoh M, Fujishita M, Arijji E. Image artifacts in dental cone-beam CT. *Oral Radiol.* 2006;22(1):6-10.
 - Schulze R, d'Hoedt B. Potential strategies to reduce metal artifacts in cone beam CT. *Clin Oral Implants Res.* 2009;20(11):1136-1143.
 - Hatcher DC. Operational principles for cone-beam computed tomography. *J Am Dent Assoc.* 2010;141(Suppl 3):3S-6S.