



Imaging the Unborn Face: A New Era in Cleft Diagnosis

(A Glimpse Before Life)

Dr.C.Chrishantha Joybell M.D.S^{1*}

¹ Reader, Department of Pedodontics and Preventive dentistry, Rajas Dental college and hospital, Tamilnadu Dr.M.G.R Medical university

CORRESPONDING AUTHOR WITH CONTACT DETAILS*:

Dr.C.Chrishantha Joybell ^{1*} M.D.S.,

4/8 Dhanasekaran nagar 2nd street, Tuticorin 628002

(Received: 25 August 2025 Revised: 27 September 2025 Accepted: 07 November 2025)

Keywords:

Cleft lip; Cleft palate; Prenatal diagnosis; 3D ultrasound; Fetal MRI; Prenatal surgery

ABSTRACT:

Cleft lip and palate are among the most common congenital craniofacial anomalies. Early prenatal diagnosis is crucial for genetic evaluation, parental counselling, and treatment planning. This review summarises current imaging modalities for prenatal detection and assessment of cleft lip and palate. Two-dimensional ultrasound remains the primary screening tool, while three- and four-dimensional ultrasonography enhance visualisation of the lip, alveolus, and palate, improving diagnostic accuracy.

Fetal magnetic resonance imaging (MRI) serves as a valuable adjunct, particularly in defining posterior palatal involvement and associated anomalies. Recent experimental advances in fetoscopic surgery highlight potential benefits such as scarless healing and improved maxillary growth, although clinical validation is still lacking. The integration of advanced imaging and emerging prenatal interventions holds promise for earlier and more precise management of orofacial clefts.

INTRODUCTION

Facial clefts are among the most common congenital anomalies, with a point prevalence of approximately 1 in 500 to 1 in 1000 live births.¹ Prenatal detection and diagnosis have been recognized as valuable tools for facilitating prenatal counselling, assessing genetic risks, and preparing parents psychologically to accept and plan for neonatal surgical intervention after birth. To improve the evaluation of these defects, particularly those involving the palate, three- and four-dimensional ultrasonography (3D/4D US) have been widely introduced as complementary techniques to conventional two-dimensional ultrasonography (2D US). Clinically, it is important to differentiate between the various types of orofacial clefts due to their differing implications for fetal prognosis.²

The genetic risks are believed to increase when the alveolus, the palate, or both are involved in the facial cleft.³ More complex clefts are often associated with additional malformations and chromosomal abnormalities, as clefting forms part of the phenotype in many syndromic conditions.⁴ While isolated clefts generally have low perinatal mortality and morbidity, presenting primarily functional and aesthetic challenges after birth, complicated clefts are associated with a poorer prognosis. Moreover, children with cleft lip and palate usually require multiple surgical procedures and long-term follow-up involving orthodontic and speech therapy compared with those affected by cleft lip alone.⁵

Therefore, when a cleft lip is detected during 2D ultrasonographic screening, precise evaluation of the palatal anatomy is essential to provide appropriate



genetic, surgical, and functional counselling to parents. In recent years, several advanced 3D ultrasonographic techniques have been developed to improve visualization of the hard and soft palate, and magnetic resonance imaging (MRI) has also been advocated as an adjunctive diagnostic tool.⁶

Prenatal diagnosis of cleft lip and palate is primarily achieved through ultrasound, most commonly during the 20-week anatomy scan. While cleft lip is often readily detected, cleft palate, particularly submucous or soft palate clefts, can be more challenging to identify. When an anomaly is suspected or when additional abnormalities are noted, genetic counselling, chromosomal analysis, and advanced imaging such as 3D/4D ultrasound may be recommended to provide comprehensive information to the parents.

METHODS FOR PRENATAL DIAGNOSIS

- **Routine Ultrasound:** The standard scan between 18–22 weeks remains the primary screening tool, with diagnosis possible as early as 12 weeks.
- **Advanced Ultrasound:** 3D and 4D imaging enhance visualization of the fetal face and palate, improving detection accuracy, especially for the secondary palate.
- **Genetic Testing:** If associated anomalies are found, chromosome microarray or related tests help identify underlying chromosomal abnormalities.

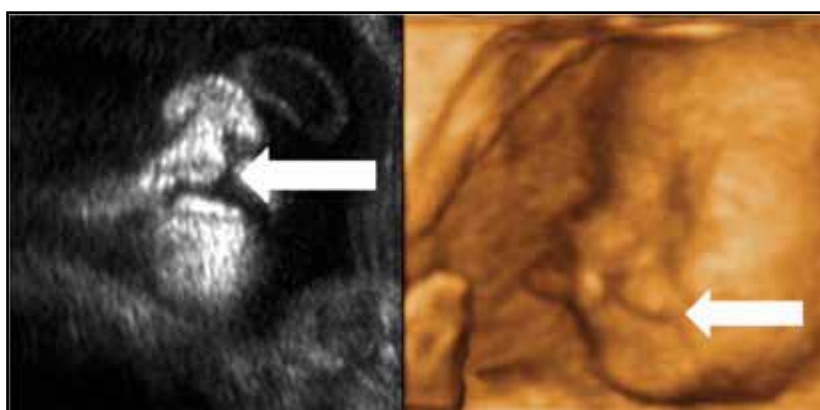
- **Amniocentesis:** May be performed to obtain fetal karyotyping when chromosomal disorders are suspected.
- **Risk Factors:** Family history, maternal diabetes, advanced maternal age, or exposure to certain medications are also considered during evaluation.

WHAT TO EXPECT

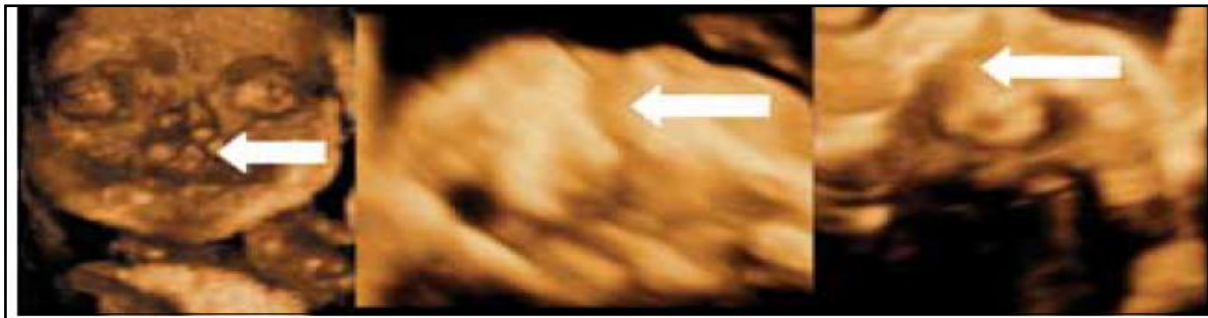- **Cleft Lip:** Usually visible and detectable during the 20-week scan.
- **Cleft Palate:** More difficult to diagnose, particularly in submucous or isolated soft palate cases, which may go unrecognized until after birth.
- **Associated Conditions:** Additional abnormalities may warrant further diagnostic testing and multidisciplinary counselling.
- **Parental Support:** Early detection allows for psychological preparation, counselling, and coordinated postnatal surgical planning, helping families prepare for optimal outcomes.

ACCURACY OF PRENATAL DIAGNOSIS OF THE DIFFERENT TYPES OF CLEFTS

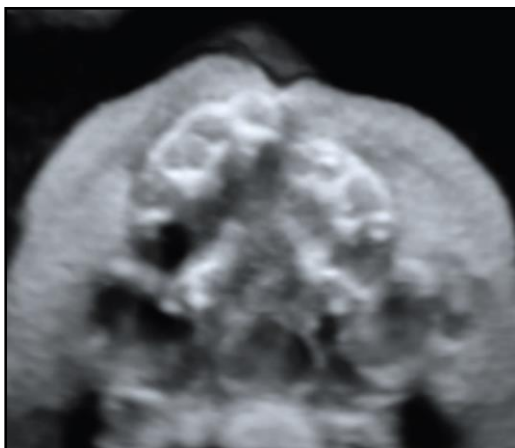
The accuracy of antenatal ultrasound diagnosis of cleft lip and palate was evaluated in a series of 96 cases, with a mean gestational age at examination of approximately 28 weeks. The sonographic findings—cleft lip, cleft lip with alveolar involvement, and cleft lip with cleft palate—were subsequently confirmed in 88% of cases.⁷



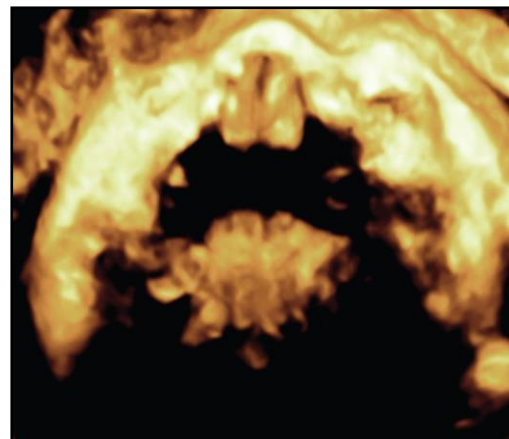
Cleft lip as visualised by two and three dimensional ultrasound



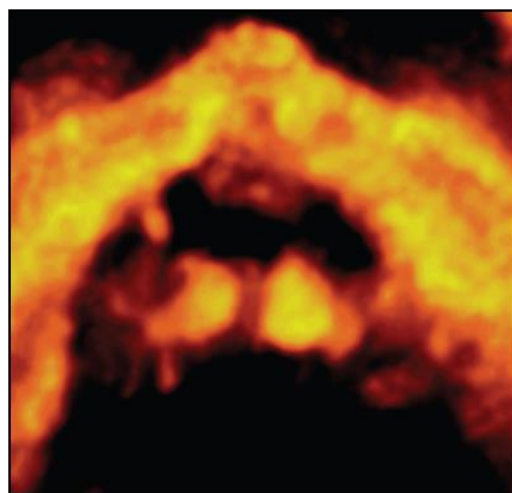
Cleft palate seen in coronal plane reverse face view; cleft alveolar and palate in axial plane visualised by flipped face view; and cleft alveolar and palate in axial plane as visualised by oblique face view



Three-dimensional ultrasound of cleft lip and palate at 29 weeks of gestation.



Three-dimensional ultrasound of the soft palate at 32 weeks of gestation.



Three-dimensional ultrasound of the cleft soft palate at 29 weeks of gestation.

FETAL MAGNETIC RESONANCE IMAGING

To evaluate the role of foetal magnetic resonance imaging (MRI) as a complement to ultrasonography

(US) in the assessment of cleft lip and palate—whether isolated or associated with syndromic conditions—a study was conducted on 27 fetuses with US-diagnosed



cleft lip or cleft lip with palate involvement. Fetal MRI examinations were performed at a mean gestational age of 24 weeks to assess the facial skeleton, central nervous system, and overall fetal anatomy. The diagnosis of cleft lip and palate was confirmed in 16 of the 25 evaluable fetuses, with MRI providing additional information regarding the extent of the cleft and the degree of involvement of the anterior and posterior palate in eight of these cases. In one fetus, MRI excluded the diagnosis of cleft lip/palate initially suggested by US.

The study concluded that MRI offered superior diagnostic accuracy in delineating the posterior palate and determining the lateral extent of the cleft compared with US. Furthermore, MRI enabled comprehensive evaluation of the fetal head, facial bone biometry, and associated craniofacial structures, facilitating early detection of potential syndromic conditions.⁸

PRENATAL SURGERY

Advancements in video-endoscopic technology have led to the development of minimally invasive techniques for fetoscopic surgery, which has demonstrated reduced invasiveness compared with traditional open fetal procedures. Experimental intrauterine correction of cleft lip and palate has recently been performed using these approaches. The proposed advantages of prenatal surgery for this non-life-threatening condition include scarless fetal wound and bone healing, which may promote improved maxillary bone growth and superior cosmetic outcomes by correcting the primary deformity in utero.⁹

Scarless fetal lip and palate repair could potentially prevent the cascade of postnatal scarring and its consequent dentoalveolar and midfacial growth disturbances, thereby reducing the number of reconstructive surgeries required after birth. However, these advantages remain theoretical, as clinical data validating the safety, feasibility, and long-term outcomes of prenatal cleft repair are not yet available in the current literature.¹⁰

REFERENCES

1. Cash C, Set P, Coleman N. The accuracy of antenatal ultrasound in the detection of facial clefts in a low-risk screening population. *Ultrasound Obstet Gynecol.* 2001;18:432–6.
2. Tonni G, Centini G, Rosignoli L. Prenatal screening for fetal face and clefting in a prospective study on low-risk population: can 3- and 4-dimensional ultrasound enhance visualization and detection rate? *Oral Surg Oral Med Oral Pathol Oral Radiol Endod.* 2005;100:420–6.
3. Bergé SJ, Plath H, Van de Vondel PT, et al. Facial cleft lip and palate: sonographic diagnosis, chromosomal abnormalities, associated anomalies and postnatal outcome in 70 fetuses. *Ultrasound Obstet Gynecol.* 2001;18:422–31.
4. Maarse W, Bergé SJ, Pistorius L, et al. Diagnostic accuracy of transabdominal ultrasound in detecting prenatal cleft lip and palate: a systematic review. *Ultrasound Obstet Gynecol.* 2010;35:495–502.
5. Heinrich A, Proff P, Michel T, Ruhland F, Kirbschus A, Gedrange T. Prenatal diagnostics of cleft deformities and its significance for parental and infant care. *J Craniomaxillofac Surg.* 2006;34 Suppl 2:14S–16S.
6. Oosterkamp BC, Dijkstra PU, Rimmelink HJ, et al. Satisfaction with treatment outcome in bilateral cleft lip and palate patients. *Int J Oral Maxillofac Surg.* 2007;36:890–5.
7. Rotten D, Levallant JM. Two- and three-dimensional sonographic assessment of the fetal face. 2. Analysis of cleft lip, alveolus and palate. *Ultrasound Obstet Gynecol.* 2004;24:402–11.
8. Manganaro L, Tomei A, Fierro F, et al. Fetal MRI as a complement to US in the evaluation of cleft lip and palate. *Radiol Med.* 2011;116:1134–48.
9. Papadopulos NA, Papadopoulos MA, Kovacs L, et al. Foetal surgery and cleft lip and palate: current status and new perspectives. *Br J Plast Surg.* 2005;58:593–607.
10. Lorenz HP, Longaker MT. In utero surgery for cleft lip/palate: minimizing the “ripple effect” of scarring. *J Craniofac Surg.* 2003;14:504–11.