



Pleomorphic adenoma of the upper lip: Case Report and Insights from Literature

1. Dr. Yugandhara Kale

Lecturer, Department of Oral Pathology & Microbiology, Yogita Dental College and Hospital, Khed, Ratnagiri.

2. Dr. Pavan Kumar Gujjar

Professor & HOD, Department of Oral Pathology & Microbiology, Yogita Dental College and Hospital, Khed, Ratnagiri.

3. Dr. Mugdha Khond

Lecturer, Department of Public Health Dentistry, Yogita Dental College and Hospital, Khed, Ratnagiri.

4. Dr. Shylaja MD

Professor & HOD, Department of Oral Pathology & Microbiology, Narsinhbhai Patel Dental College and Hospital, Visnagar, Gujarat.

(Received: 27 September 2025 Revised: 05 October 2025 Accepted: 10 November 2025)

KEYWORDS

Pleomorphic adenoma,
Minor salivary gland tumor,
Benign neoplasm,
Histopathology

ABSTRACT:

Pleomorphic adenoma (PA) is the most common benign tumor of the salivary glands, accounting for a significant proportion of both major and minor salivary gland neoplasms. While it typically presents in the parotid gland and the palate, PA of the upper lip is relatively rare, with few documented cases. This case report details the presentation, diagnosis, and management of a 30-year-old female who presented with a painless, gradually increasing swelling in the right upper lip. The clinical examination revealed a well-circumscribed, firm, and non-tender swelling, while histopathological analysis confirmed a diagnosis of pleomorphic adenoma. Histologically, PA is characterized by a mixture of epithelial and myoepithelial cells within a chondromyxoid stroma. Despite the rarity of PA in the lips, it should be considered in the differential diagnosis of lip swellings, which can also include cystic, benign, and malignant tumors. Treatment of choice is surgical excision with clear margins to minimize recurrence, as capsular rupture during excision can result in local recurrence. Though the case was successfully managed with complete excision and no recurrence after one year of follow-up, long-term monitoring remains essential due to the potential for late recurrence. This case highlights the need for awareness of this rare but important lesion in the upper lip and emphasizes the importance of surgical intervention and follow-up for optimal outcomes.

1. Introduction:

Pleomorphic adenoma (PA) being the most common benign neoplasm salivary gland tumors represent 3% of head and neck tumors. [1,2] Minor salivary gland typically affects the soft and hard palates, reflecting the higher embryological distribution of minor salivary glands typically affect the soft and hard palates when compared to lips, making upper lip involvement a rare occurrence. [3] Pleomorphic adenoma (PA), or mixed tumor, is the most common benign tumor of the salivary glands. In the head and neck area, it comprises about 3%-10% of all head and neck tumors and 50% of the major

and minor salivary gland neoplasms. [4] PA of the minor salivary glands occurs in the palate (67.5%), lips (10%), cheeks (5%), tongue (2.5%), and other sites (15%); PA in a lip is relatively rare. The most common site of predilection is hard palate (42.8%-68.8%), followed by the upper lip (15%-20%), cheek (5.5%), throat (2.5%), and retromolar region (0.7%). [5] PA rarely affects the cheek mucosa, lip, and tongue. PA can also occur in ectopic sites such as the floor of the mouth and alveolar mucosa, Stenson's duct, accessory parotid tissue, mandible, tonsillar tissue, lower neck, middle ear, sternoclavicular joint, thyroglossal duct, and



parapharyngeal space. [6] Histologically, it is characterized by a large variety of tissues consisting of epithelial cells arranged in a cord-like cell pattern, together with areas of squamous differentiation or with plasmacytoid appearance myoepithelial cells which are responsible for the production of abundant extracellular matrix with chondroid, collagenous, mucoid, and osseous stroma. [7]

2. Case report:

A 30-year-old female patient reported to our dental outpatient department with complaints of a painless swelling in the upper lip in the past 3 years of duration which had gradually started increasing from past 6 months. There was no history of trauma or any other medical history of significance. Extra oral examination revealed a swelling on the right side of the upper lip with normal overlying skin. On palpation, the swelling was firm in consistency but non tender. On intraoral examination, a solitary well-circumscribed swelling about 1cmx1cm firm in consistency, mobile but non tender was noted in the upper lip on the right side of the midline (Fig.1). The overlying mucosa was smooth without any ulceration. The systemic examination was normal and there was no regional lymphadenopathy. The histopathological section showed well-encapsulated soft-tissue mass consisting of epithelial and myoepithelial cell proliferation lining the ducts and chondromyxoid stroma with the final diagnosis of PA of the upper lip (Fig 2a & 2b).

3. Discussion:

PA is the most frequently encountered benign mixed tumor of the salivary gland and usually presents in the parotid, tumors originating from the minor salivary gland are uncommon, but PAs account for nearly 40% of the benign tumors here. [8] Similar to other tumors in the minor salivary glands, PA most commonly occurs in the palate. [4] In our case, PA occurred in the upper lip. The peak incidence of PA of the lips has also been reported to occur in the third to fourth decades of life, age of our patient was 30 years. The onset of PA in the minor salivary glands of the lips is at an earlier age than other sites. Previous studies have demonstrated that the prevalence of PA on upper lips is remarkably higher than that on lower lips, with a ratio of 6:1. [9] Further, there is a propensity for benign tumors to occur on the upper lip,

whereas malignant lesions predominantly occur on the lower lip. This contrast is possibly because of differences in embryonic development between the upper and lower lips. Lip lesions are found inside the mouth, where they present as a well-circumscribed, nodular, mobile, sessile, rubbery mass. [10] For preoperative diagnostic assistance, ultrasonography and magnetic resonance are useful. No imaging was used in our case. An excisional biopsy was performed in our case and a histopathology examination confirmed the diagnosis as PA. Histopathology features of PA of the lip are similar to those of PA from other sites in that they comprise epithelial and mesenchymal cells arranged in diverse patterns and embedded in the mucopolysaccharide stroma. [11] The clinical differential diagnosis of swelling of the lips is inclusive of cystic diseases (mucocele, dermoid cyst, and epidermoid cyst), benign tumors (fibroma, hemangioma, lipoma, and schwannoma) and malignant tumors (squamous cell carcinoma, mucoepidermoid carcinoma, and adenoid cystic carcinoma), foreign body, infection, orofacial granulomatosis, Quincke's edema, tuberculosis, and actinomycosis. [12] The surgical treatment for PA is a complete wide surgical excision with adequate safety margins. An inadequate resection or rupture of the capsule or tumor spillage during excision can lead to local recurrence. [5] Carcinoma ex PA arises from untreated PA. However, they have rarely been reported in the lips, perhaps as it is in a conspicuous area where esthetics is compromised, the patient might hasten to present for treatment. Despite being benign, PA demands close follow-up due to the risk of recurrence from capsular rupture during surgery. Although no recurrences were noted in the reviewed cases with one-year follow up, longer monitoring is necessary to rule out late recurrence. [13]

4. Conclusion:

In conclusion, this rare presentation highlights that the differential diagnosis for upper lip swellings should include PA. Complete surgical excision may result in a good outcome, but close follow up is recommended to monitor for any signs of recurrence.

References:

1. Kazikdas, K. C.; Yalcinozan, E. T.; Dirik, M. A. Pleomorphic adenoma of the upper lip. *Natl. J. Maxillofac. Surg.* 2020, 11, 110–112.



2. Salih, A. M.; Kakamad, F. H.; Ali, S. M.; et al. Giant pleomorphic adenoma of the parotid gland extending to the parapharyngeal space: A rare case report. *Int. J. Case Rep. Images* 2018, 9.
3. Gelidan, A. G.; Arab, K. Rare upper lip pleomorphic adenoma presents as cutaneous skin lesion: Case report. *Int. J. Surg. Case Rep.* 2021, 85, 106142.
4. Sharma, N. K.; Singh, A. K.; Pandey, A.; Verma, V. Pleomorphic adenoma involving soft tissue overlying the anterior border of ramus of the mandible: A rare ectopic presentation. *J. Oral Biol. Craniofac. Res.* 2016, 6, S62–S64.
5. Singh, A. K.; Kumar, N.; Sharma, P.; Singh, S. Pleomorphic adenoma involving minor salivary glands of upper lip: A rare phenomenon. *J. Cancer Res. Ther.* 2015, 11, 1025.
6. Vegari, S.; Naderpour, M.; Hemmati, A.; Baybordi, H. Pleomorphic adenoma of the cervical heterotopic salivary gland: A case report. *Case Rep. Otolaryngol.* 2012, 106142.
7. Lotufo, M. A.; Júnior, C. A.; Mattos, J. P.; França, C. M. Pleomorphic adenoma of the upper lip in a child. *J. Oral Sci.* 2008, 50, 225–228.
8. Buchner, A.; Merrell, P. W.; Carpenter, W. M. Relative frequency of intra-oral minor salivary gland tumors: A study of 380 cases from Northern California and comparison to reports from other parts of the world. *J. Oral Pathol. Med.* 2007, 36, 207–214.
9. Shrestha, A.; Reddy, N. S.; Ganguly, S. N. Pleomorphic adenoma of the upper lip: A case report. *Nepal Med. Coll. J.* 2010, 6, 51–53.
10. Gelidan, A. G.; Arab, K. Rare upper lip pleomorphic adenoma presents as cutaneous skin lesion: Case report. *Int. J. Surg. Case Rep.* 2021, 85, 106142.
11. Umemori, K.; Ono, K.; Kanemoto, H.; Obata, K.; Kawai, H.; Nakamura, T.; Nakano, K.; Ibaragi, S.; Nagatsuka, H.; Sasaki, A. Lip pleomorphic adenomas: Case series and literature review. *Gland Surg.* 2022, 11, 1730–1740.
12. Jaber, M. A. Intraoral minor salivary gland tumors: A review of 75 cases in a Libyan population. *Int. J. Oral Maxillofac. Surg.* 2006, 35, 150–154.
13. Ali, R. M.; Ali, R. M.; Qaradakhly, A. J.; Hiwa, D. S.; Abdullah, A. M.; Omar, D. A.; Hassan, S. H.

Qadir, A. A.; Salih, A. M.; Kakamad, F. H. Pleomorphic adenoma of the lip: A case report and literature review. *J. Surg. Case Rep.* 2025, 311.

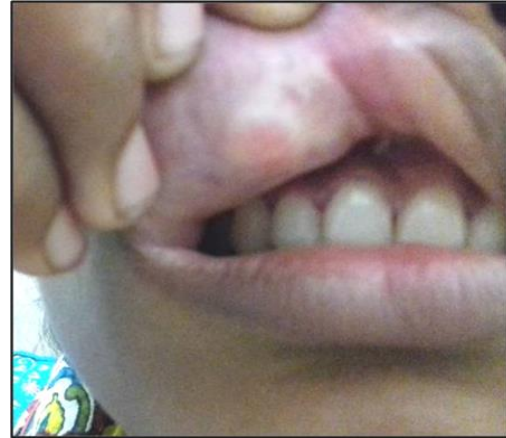

Figure 1: Intraoral clinical photograph

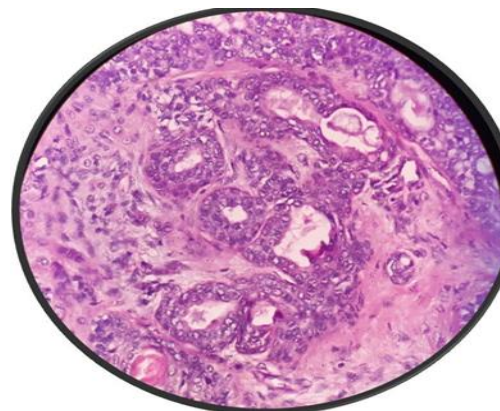


Figure 2b: Photomicrograph of specimen at 40x

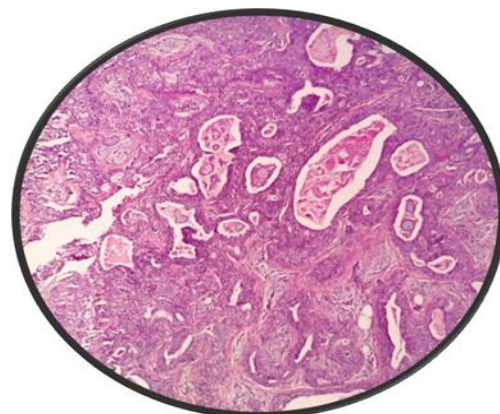


Figure 2a: Photomicrograph of specimen at 10X