



Mucocele – Case Report

Dr. Parikshit S Kadam¹, Dr. Pranali Kadu², Dr. Piyush Kalsaria³, Dr. Dinesh Khandare⁴, Dr Sandeep Dande⁵, Dr. Minal Patil⁶

¹Reader, Department of Pediatric & Preventive Dentistry, Saraswati Dhanwantari Dental College and Hospital, Parbhani

²Senior Lecturer, Department of Pediatric & Preventive Dentistry, Dr R R Kamble Dental College, Akola

³Senior Lecturer, Department of Pediatric & Preventive Dentistry, Darshan Dental College, Udaipur

⁴Senior Lecturer, Department of Pediatric & Preventive Dentistry, Saraswati Dhanwantari Dental College, and Hospital, Parbhani

⁵Reader, Department of Pediatric & Preventive Dentistry, Saraswati Dhanwantari Dental College and Hospital, Parbhani

⁶Senior Lecturer, Department of Pediatric & Preventive Dentistry, Saraswati Dhanwantari Dental College and Hospital, Parbhani

Corresponding Author:

Dr. Pranali Kadu, Senior Lecturer, Department of Pediatric & Preventive Dentistry, Dr R R Kamble Dental College, Akola

(Received: 07 October 2025

Revised: 15 November 2025

Accepted: 02 December 2025)

KEYWORDS:

Mucocele;
Benign Soft
Tissue Lesions,
Oral Cavity;
Mucous
Retention Cysts;
Mucous
Extravasation
Cyst

ABSTRACT:

The term mucocele was derived from a Latin word, muco or mucus and coele or cavity. Mucoceles are nonneoplastic cystic lesions of major and minor salivary glands disease which result from the accumulation of mucus in cystic cavity. Mucocele is the 17th most common salivary gland lesions seen in the oral cavity. The two main etiological factors for mucoceles are obstruction of salivary gland ducts leading to the so-recognized true mucous retention cysts and traumatic injuries to the mucous carrying ducts leading to the creation of the so-called mucous extravasation cysts. Mucoceles are most commonly seen in the lower lip because of the lip-biting habit leading to the formation of mucous extravasation cysts.

Introduction

Mucocele (Muco-mucus and coele-cavity) are cavities filled with mucus. They are one of the most common benign soft tissue masses that occur in the oral cavity ⁽¹⁾. Two types of mucocele can appear in the oral cavity, namely, extravasation and retention type ⁽²⁾. Formation of mucus extravasation cyst is mainly due to mechanical trauma causing rupture of ductal system of salivary gland and mucin spills into adjacent soft tissues. Mucus retention cyst is formed markedly by obstruction of salivary ductal walls causing dilatation of ducts without spillage of mucin ⁽³⁾. The most common affected sites are the lip, tongue, palate, cheek, and floor

of the mouth ⁽⁴⁾. Mucocele clinically appear as an asymptomatic vesicle or bulla with a pink or bluish-color, and their size may vary from 1 mm to several centimeters and affect both genders in all age groups, ⁽⁵⁾. The histological difference between extravasation and retention cyst is that the mucous extravasation type (pseudocyst cyst) has no epithelial lining and is formed by a mucus pool surrounded by granulation tissue and the mucous retention cyst (true cyst) has an epithelial lining result from dilatation of duct epithelial cyst ⁽⁶⁾. Treatment options for mucoceles include surgical excision, marsupialization, micro marsupialization, electrocautery, intralesional steroid injection of



corticosteroid, cryosurgery, irradiation, laser vaporization, and laser excision⁽⁸⁾.

Hence the aim of this article is to describe a case report of mucocele on lower lip which was treated using electrocautery (high temperature electrocautery working on a power supply of 230V, 0.9A and 1.5-1.7MHz frequency) in Paediatric patients.⁽⁹⁾

Case report :

A 13-year-old female patient reported in the OPD of the department of oral medicine and radiology then send to the pediatric department. She had a chief complaint of an intra-oral swelling over right side of the lower lip for past 20 days. The history of presenting illness revealed similar lesions in the past that resolved on their own. On intraoral examination, on inspection small a solitary, well-circumscribed, oval-shaped swelling measurement was done by using university of north carolina (UNC 15) probe (LX B= 5x7mm) in its largest diameter (figure C&D) with a smooth, shiny surface and having a slightly bluish hue, was present in relation to the lower right labial mucosa. Swelling extending from distal surface 41 to mesial surface of 43 region. The swelling was painless and was reported to be initially small in size by the patient at the onset which gradually increased in size to attain the present size (Figure A&B).

On palpation, all the inspeactory findings were confirmed. The swelling was soft in consistency, Base of the swelling is sessile, non tender and fluctuant. The temperature of the overlying surface was normal and the associated lymph nodes of the region were non-palpable. The patient had no significant medical, dental, family history. Extra-oral examination revealed no remarkable findings. The patient reported accidental biting of the lower lip while having food about 4 months ago. Patient had a positive history of lip biting habit. There was no difficulty in speaking or chewing. No other oral anomalies were detected.

Based on above history and clinical examination of the patient, a provisional diagnosis of mucocele on right lower labial mucosa was arrived-at while the important differentials included a fibroma, lipoma and hemangioma. For making the differential, the relatively, well-known and simple, clinical slip sign for lipomas and diascopy procedure for lesions of vascular origins

including hemangiomas was performed and were found to be negative.

The patient was, thus, advised to excisional biopsy of the lesion along with the removal of the affected adjacent minor salivary gland tissue. The lab investigations like HB, TLC and DLC were conducted and the values were found to be normal. A written, informed consent was obtained from the patient's parents. Removal of the lesion was performed under local anesthesia by using electrocautery. Local anesthesia was administered around the lesion. In this case, local anesthesia of 1.8 ml Lidocaine with 1:100,000 epinephrine, was administrated through the local infiltration on the lower lip. Before infiltration, a topical anesthetic gel for 2 minutes was applied. The electrocautery that was used in this case was Bonart ART-E1 Electrosurgery Unit, with a Coagulant setting and with tip no T7.

The lip was then everted with digital pressure to increase the lesion's prominence. A The tip of eletrocautery was directed to the surface of the lip at the base of the lesion at an angle of 10 to 15°. Movements were performed around the base, while the mucocele was grabbed by HDT Tissue forceps Adson 1x2 12cm [TP42] used. (Figure E)

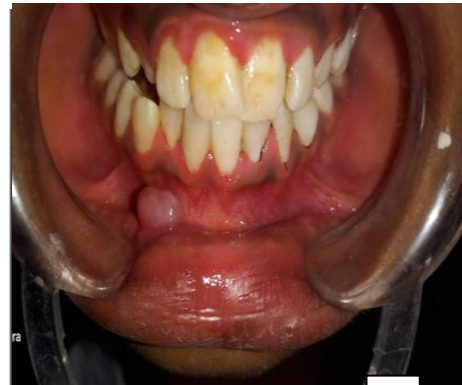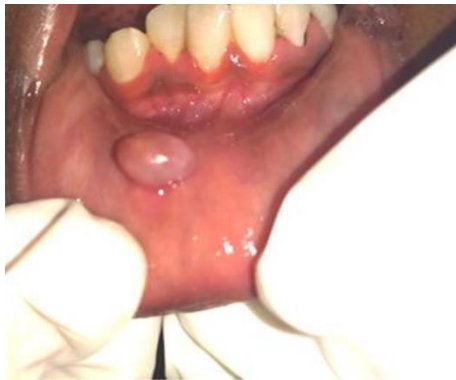The site was slowly and continuously mopped by sterile wet gauze to avoid tissues overheating. Care was taken also to always control the tip. If upon inspection, any damage or collection of debris was observed during treatment, the tip eletrocautery was cleaned with a sterile gauze.. The perfect way to oblige the lesion for minimally invasive treatment was by circular motion surrounding the lesion. Minor salivary glands around the lesion were also excised to prevent a recurrence (**Figure G**). The mucocele was totally removed in 5 minutes No bleeding was observed in the operative site and no sutures were necessary. An analgesic was prescribed and post-operative instruction was given. The patient was told not to bite her lips and if healing was not complete by 4 weeks or any recurrence appeared, she should return for further examination and treatment The excised tissue was submitted to the pathological investigations which confirmed the diagnosis and ruled out the minor salivary gland tumors. (**Figure F**).

The specimen was sent for histopathologic analysis which identified glandular like formation surrounded by



granulation tissue. Granulation tissue fragments contain epithelioid foamy histiocytes (muciphages) and neutrophil cells. Inflammatory cells of lymphocytes and some macrophages were found around the acini of the

salivary glands and dilated duct. A ruptured squamous epithelium was also found and confirmed the diagnosis as extravasation mucocele (**Figure H**). The patient was recalled after 1 week for suture removal.



[A&B] Solitary, well-circumscribed, oval-shaped swelling largest diameter with smooth, shiny surface and having a slightly bluish hue present in relation to the lower right labial mucosa.

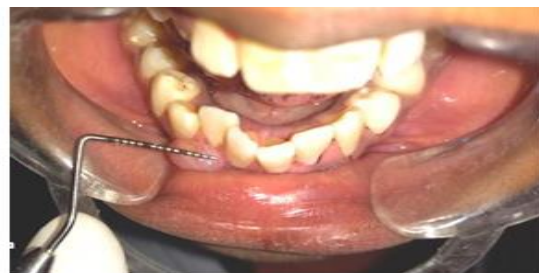
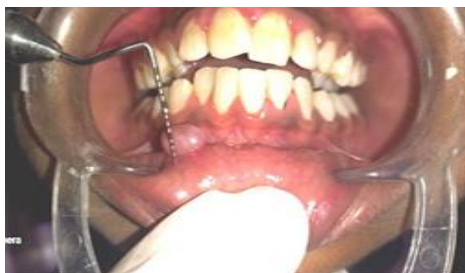
Fig C&D measurement was done by using University of north carolina (UNC 15) probe (LX 5x7mm)

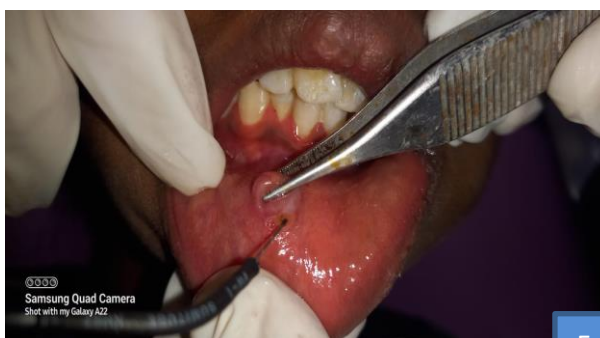


Fig (E) : Excision of the lesion using electrocautery (Bonart ART-E1 Electrosurgery Unit, with a Coagulant setting and with mucocele grabbed by HDT Tissue forceps Adson 1x2 12cm [TP42] used . Fig (F) : grossing it is a single bit tissue approx 0.5x0.7cm in size ovoid in shape reddish brown in colour with smooth in surface texture

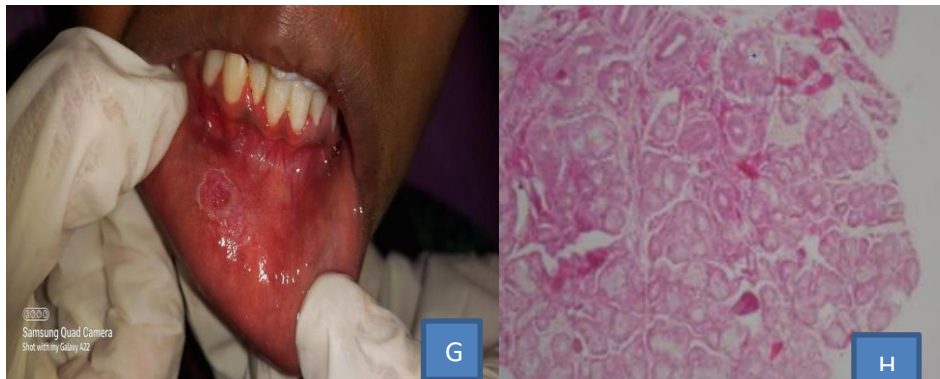


Fig G: Immediate postoperative view .

Fig H: Histopathological examination with H & E stained section revealing lesional tissue to be composed of minor salivary gland tissue with pooled mucinous areas and chronic inflammatory cell infiltration

DISCUSSION:

Mucocele is a benign cystic lesion of the oral cavity that has been ranked the seventeenth most common benign salivary gland lesion and the second most common benign soft tissue tumor occurring in the oral cavity. The incidence of mucocele is generally high, 2.5 per 1000 patients, frequently occurring in the second decade of life and rarely in children and infants under one year of age ^[1] . There is no gender predilection⁽²⁾ Mucoceles appear as dome-shaped mucosal swellings with the characteristic accumulation of mucin ⁽³⁾ . Etiologic factor of mucous cyst development in the lower lip may be caused by chronic trauma arising out of feeding and biting habit that can initiate inflammatory or hemorrhagic phenomena . Moreover, saliva secreted in the oral cavity by salivary glands through ducts. If these ducts are blocked or traumatized, the saliva is collected at the cut spot leading to swelling or a mucocele.⁽⁴⁾ Mucocele of the minor salivary gland are very rarely larger in diameter and moreover always superficial. Extravasation mucocele are caused by a leaking of fluid from ducts or acini to surrounding tissue. This type of mucocele is commonly found in the minor salivary glands. Physical trauma can cause a leakage of salivary secretion into surrounding submucosal tissue. ⁽⁵⁾ Mucus retention cysts occur in older individuals; the peak prevalence occurs in persons aged 50–60 years.⁽⁶⁾

Age and sex	More occur in younger patients because they more prone to trauma that induce mucin spillage. It is equal in both sexes.
site	Most common –inner aspect of lower lip Also occur –palate,cheek ,tongue,floor of mouth.
symptom	Patients may complain painless swelling which is frequently recurrent. Swelling may suddenly develop at meal time and may drain simultaneously at intervals.
size	Mucocele may be 1-2 cm in diameter [5-10 cm]
shape	Swelling is round or oval or dome shaped
appearance	Superficial cyst appear as bluish mass,as the thin overlying mucosa permits the pool of mucus fluid to absorb most of the visible wavelength of light.If inflamed, it is fluctuant ,soft ,nodular and dome shaped elevation. Deeper lesion have the color of normal mucosa



	and firmer.
--	-------------

Treatment for mucoceles include surgical excision, marsupialization, micro marsupialization, electrocautery, intralesional steroid injection of corticosteroid, cryosurgery, irradiation, laser vaporization, and laser excision⁽⁸⁾. The most common treatment is complete removal of the lesion and the salivary gland involved via surgical excision. Marsupialization had resulted in considerably higher recurrence rates.

Micro marsupialization had been suggested to have lower recurrence rates, although it was restricted to lesions with clinical characteristics that strongly suggested a diagnosis of mucocele, since histopathological examination was not possible. Cryosurgery yielded satisfactory results with no recurrence. Reported postoperative symptoms, however, included marked edema and irritation, as well as a prolonged healing time⁽⁸⁾.

REFERENCE

1. More CB, Bhavsar K, Varma S, Tailor M. Oral mucocele: a clinical and histopathological study. *Journal of oral and maxillofacial pathology: JOMFP*. 2014 Sep;18(Suppl 1):S72
2. Chaitanya P, Praveen D, Reddy M. Mucocele on lower lip: a case series. *Indian dermatology online journal*. 2017 May;8(3):205.
3. Ramkumar S, Ramkumar L, Malathi N, Suganya R. Excision of mucocele using diode laser in lower lip. *Case Reports in Dentistry*. 2016 Dec 21;2016.
4. Besbes A, Elelmi Y, Khanfir F, Belgacem R, Ghedira H. Recurrent Oral Mucocele Management with Diode Laser. *Case Reports in Dentistry*. 2020 Oct 3;2020.
5. Nallasivam KU, Sudha BR. Oral mucocele: Review of literature and a case report. *Journal of pharmacy & bioallied sciences*. 2015 Aug;7(Suppl 2):S731.
6. Senthilkumar B, Mahabob MN. Mucocele: An unusual presentation of the minor salivary gland lesion. *Journal of pharmacy & bioallied sciences*. 2012 Aug;4(Suppl 2):S180.
7. Re Cecconi D, Achilli A, Tarozzi M, Lodi G, Demarosi F, Sardella A, Carrassi A. Mucoceles of the oral cavity: a large case series (1994-2008) and a literature review.
8. Bhargava N, Agarwal P, Sharma N, Agrawal M, Sidiq M, Narain P. An unusual presentation of oral mucocele in infant and its review. *Case Reports in Dentistry*. 2014 Aug 26;2014
9. Gautam Y, Srivastava M. Mucocele in paediatric patients: A case series with review. *Int J Appl Dent Sci*. 2018;4(2):100-3.
10. Ewitrawati V, Tedjosasongko U, Wahluyo S, Saskianti T, Dewi AM, Bonardo B, Ayuningtyas P. Case report on management of oral mucocele in pediatric patient using electrocautery.
11. Ata-Ali J, Carrillo C, Bonet C, Balaguer J, Peñarrocha M, Peñarrocha M. Oral mucocele: review of the literature. *J Clin Exp Dent*. 2010 Feb;2(1):e18-21.
12. Sharma A S, Anand B A, Shahi C AK, Kumar B V. MUCOCELES OF THE ORAL CAVITY: A RETROSPECTIVE STUDY.
13. Foroughiasl P. Cautery versus laser excision of oral mucocele. *Journal of Pediatric Surgery Case Reports*. 2019 Aug 1;47:101251.
14. Pandey R, Pathakota KR, Koppolu P, Bolla V. Treatment of mucocele with diode laser. *Journal of dental lasers*. 2013 Jan 1;7(1):43.
15. Raj A, Hegde D, Gupta D, Nayak SU. Treatment of mucocele of the lower lip using diode laser in a pediatric patient: interdisciplinary case report. *HIV & AIDS Review. International Journal of HIV-Related Problems*. 2021;20(4):314-7.
16. Sinha R, Sarkar S, Khaitan T, Kabiraj A, Maji A. Nonsurgical management of oral mucocele by intralesional corticosteroid therapy. *International journal of dentistry*. 2016 Oct 16;2016.
17. Bagher SM, Sulimany AM, Kaplan M, Loo CY. Treating mucocele in pediatric patients using a diode laser: three case reports. *Dentistry Journal*. 2018 May 9;6(2):13.



18. Pedron IG, Galletta VC, Azevedo LH, Corrêa L. Treatment of mucocele of the lower lip with diode laser in pediatric patients: presentation of 2 clinical cases. *Pediatric dentistry*. 2010 Nov 15;32(7):539-41.