



---

## Complex Reconstruction Following Native Treatment of a Femoral Shaft Fracture: A Case Report

**Dr. M. Arulseivan<sup>1</sup>, Dr. T. Sundararajan<sup>2</sup>, Dr. S. Sathya<sup>3</sup>, Dr. M. Sundaramurthy<sup>4</sup>, Dr. F. Abdul Khader<sup>5</sup>, Dr. A. Jeevan kishor<sup>6</sup>, Dr. Sharan Sakthivel<sup>7</sup>, Dr. C. Tamizarasu<sup>8</sup>, Dr. B. Anantha Padmanabhan<sup>9</sup>**

<sup>1</sup>Junior Resident Year-1, Department of Orthopaedics, Shri Sathya Sai Medical College and Research Institute under Sri Balaji Vidyapeeth, Ammapettai, Chengalpattu District, Tamil Nadu, 603108 India.

<sup>2</sup>Professor, Department of Orthopaedics, Shri Sathya Sai Medical College & Research Institute, Ammapettai, Chengalpattu District, Tamil Nadu, 603108 India.

<sup>3</sup>Associate Professor, Department of Orthopaedics, Shri Sathya Sai Medical College and Research Institute under Sri Balaji Vidyapeeth, Ammapettai, Chengalpattu District, Tamil Nadu, 603108, India.

<sup>4</sup>Senior Resident, Department of Orthopaedics, Shri Sathya Sai Medical College & Research Institute, Ammapettai, Chengalpattu District, Tamil Nadu, 603108 India.

<sup>5</sup>Professor, Department of Orthopaedics, Shri Sathya Sai Medical College and Research Institute under Sri Balaji Vidyapeeth, Ammapettai, Chengalpattu District, Tamil Nadu, 603108, India.

<sup>6</sup>Senior Resident, Department of Orthopaedics, Shri Sathya Sai Medical College & Research Institute, Ammapettai, Chengalpattu District, Tamil Nadu, 603108 India.

<sup>7</sup>Senior Resident, Department of Orthopaedics, Shri Sathya Sai Medical College & Research Institute, Ammapettai, Chengalpattu District, Tamil Nadu, 603108 India.

<sup>8</sup>Senior Resident, Department of Orthopaedics, Shri Sathya Sai Medical College and Research Institute under Sri Balaji Vidyapeeth, Ammapettai, Chengalpattu District, Tamil Nadu, 603108, India

<sup>9</sup>Senior Resident, Department of Orthopaedics, Shri Sathya Sai Medical College and Research Institute under Sri Balaji Vidyapeeth, Ammapettai, Chengalpattu District, Tamil Nadu, 603108, India

**Corresponding Author:** Dr M. Sundaramurthy, Senior Resident, Department of Orthopaedics, Shri Sathya Sai Medical College and Research Institute under Sri Balaji Vidyapeeth, Ammapettai, Chengalpattu District, Tamil Nadu, 603108, India.

*Received Date: 15/09/2025*

*Revised Date: 16/10/2025*

*Accepted Date: 23/11/2025*

---

### KEYWORDS:

Complex Reconstruction, Native Treatment

### ABSTRACT:

Background: Native fracture management remains prevalent in certain regions and often results in delayed presentation with complex complications.

Case Presentation: We report a 31-year-old male with a neglected right femoral shaft fracture following four months of native management. The patient presented with pain, deformity, stiffness, and limb shortening. Radiographs revealed malalignment with early callus formation. Open reduction and internal fixation using an intramedullary interlocking (IMIL) nail was performed after meticulous excision of fibrous tissue, immature callus, and freshening of fracture ends. Postoperative management included structured rehabilitation and dynamization performed by removing the static interlocking bolt at one month.



Outcome: Preoperative shortening of 2 cm was fully corrected. Follow-up demonstrated radiological union, improved knee range of motion, and independent full weight-bearing mobility.

Conclusion: Chronic femoral fractures following native management pose significant surgical and rehabilitative challenges. Early orthopaedic intervention, precise reduction, and structured rehabilitation are essential for optimal outcomes.

---

## INTRODUCTION

Native fracture management, while culturally common in low-resource settings, often lacks aseptic technique and proper anatomical reduction. Consequences include malunion, nonunion, soft-tissue fibrosis, and delayed presentation. Femoral shaft fractures treated this way are particularly challenging due to abnormal callus formation and extensive scarring. This report highlights a case of chronic femoral fracture post-native management, focusing on surgical management and functional recovery.

## CASE PRESENTATION

Patient: 31-year-old male

### History of Presenting Illness:

Four months prior, the patient sustained a right femoral shaft fracture in a road traffic accident. Surgical fixation was advised, but the patient opted for native management, consisting of nine cycles (15 days each) of splinting, massage, and herbal applications. He remained non-ambulatory and presented with persistent deformity, stiffness, and limb shortening.

### Clinical Examination

- Deformity and swelling over the right thigh
- Restricted hip and knee motion
- Distal neurovascular status intact

### Limb-Length Assessment

- True length: Right – 92 cm; Left – 94 cm
- Apparent length: Right – 120 cm; Left – 123 cm
- Preoperative shortening: 2 cm

## Investigations

Radiographs (AP/lateral views of right femur, right knee, and bilateral hips with pelvis) demonstrated malaligned fracture with early callus formation and fibrotic bridging consistent with delayed union.

## Surigical Technique

### Procedure:

Open Reduction and Internal Fixation with IMIL Nailing.

Spinal anaesthesia; patient positioned in left lateral decubitus

10 cm lateral incision over mid-shaft femur

Reflection of vastus lateralis, excision of fibrous tissue and immature callus, and freshening of fracture ends

Fracture reduction confirmed under fluoroscopy

Proximal entry through piriform fossa; sequential reaming (8–12 mm)

IMIL nail (11 × 40 cm) insertion; proximal (38 mm, 44 mm) and distal (50 mm, 56 mm) locking screws under C-arm guidance

Gentle manipulation of the knee performed intraoperatively to achieve 90° flexion

Layered wound closure

Immediate Outcome: Preoperative 2 cm shortening corrected; postoperative period uneventful

## Hospital Course, Follow-Up, and Functional Outcome

Gradual progression from non-weight bearing to partial weight bearing with walker support under supervision. One month post-op: Dynamization performed by removing the static interlocking bolt, followed by



allowance of full weight-bearing with walker support. Structured rehabilitation included quadriceps and hamstring strengthening, knee mobilization, cryotherapy, and wound care

Serial radiographs demonstrated progressive callus formation and complete union

#### Functional Assessment (6 months post-op):

- KOOS: 84/100 (good functional recovery)
- Harris Hip Score: 90/100 (excellent hip function)
- The patient resumed independent daily activities and normal ambulation

#### DISCUSSION

Native fracture management in developing countries presents significant orthopaedic challenges. Complications include malalignment, nonunion, infection, and soft-tissue fibrosis. Delayed presentation leads to callus overgrowth and fibrosis, complicating reduction.

Late fixation of femoral shaft fractures requires careful planning due to periosteal thickening and callus deformity<sup>[2]</sup>. High complication rates associated with native fracture management highlight the importance of timely orthopaedic care and community education<sup>[3]</sup>.

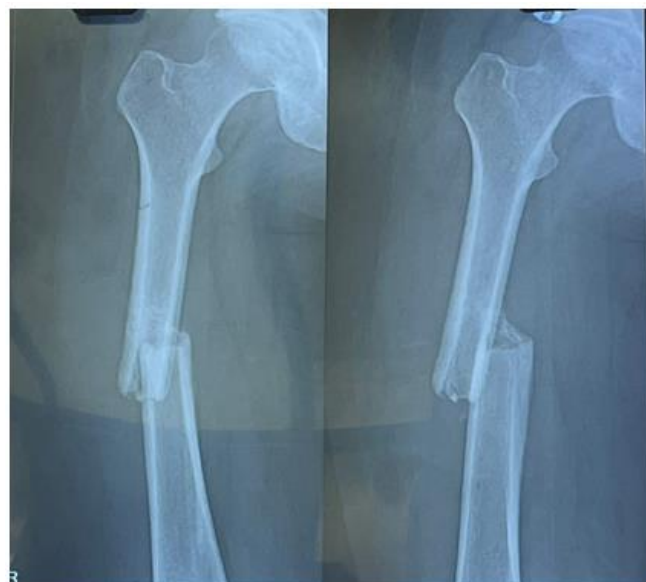Dynamization after IMIL nailing promotes axial micromotion, stimulating callus maturation. Structured rehabilitation contributed significantly to functional recovery. Public awareness and early access to orthopaedic care are crucial to prevent complications

#### CONCLUSION AND LEARNING POINTS

Chronic femoral fractures following native management are surgically and rehabilitatively challenging. Adequate exposure, excision of fibrous tissue, freshening of fracture ends, and stable fixation are critical for alignment and union. Postoperative dynamization and structured rehabilitation enhance healing and functional outcomes. Early orthopaedic consultation and patient education can prevent complications

#### Patient Consent

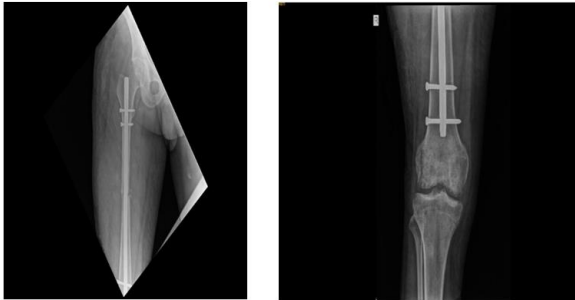
Written informed consent was obtained for participation and publication of this case report and associated clinical images



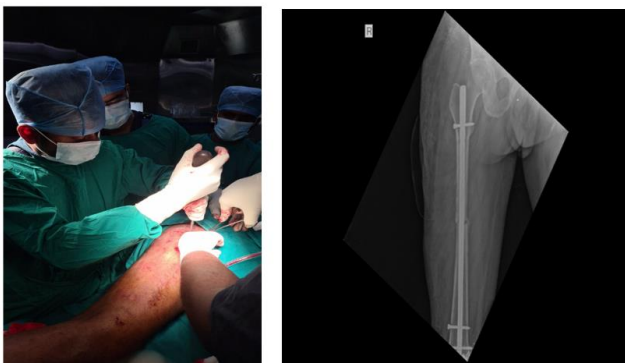
Figures 1: Preoperative X-ray (AP/Lateral Right Femur)

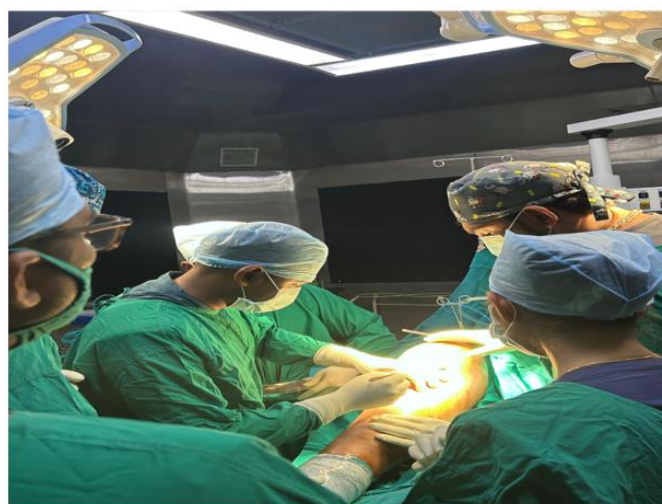

Figure 2: Intraoperative Photograph



**Figure 3: Immediate Postoperative X-ray (after IMIL Nailing)**



**Figure 4: Follow-up X-ray (after Dynamization)**

#### REFERENCES

1. Azar FM, Beaty JH, Canale ST. Campbell's Operative Orthopaedics. 14th ed. Philadelphia: Elsevier; 2020.
2. Giannoudis PV, Papakostidis C, Roberts C. Management of femoral shaft fractures. *J Bone Joint Surg Br.* 2009;91(1):15–22.
3. Oginni LM. Traditional bone setter practices in Nigeria: Complications and outcomes. *West Afr J Med.* 2004;23(2):144–147.