



## A Clinical Study on Prevalence of Apical Root Resorptions During Orthodontic Treatments: An Original Research Study

Dr. Gurpreet Kaur<sup>1</sup>, Dr. Anil Prashar<sup>2</sup>, Dr. Garima A Arya<sup>3</sup>, Dr. Shubham Jindal<sup>4</sup>, Dr. Anuradha Rajkuwar<sup>5</sup>, Dr. Shivani Deshmukh<sup>6</sup>

<sup>1</sup>Professor, Department of Orthodontics and Dentofacial Orthopaedics, Desh Bhagat Dental College, Mandi Gobindgarh, Fatehgarh Sahib, Punjab, India (Corresponding Author)

<sup>2</sup>Professor and Head, Department of Orthodontics and Dentofacial Orthopaedics, Desh Bhagat Dental College, Mandi Gobindgarh, Fatehgarh Sahib, Punjab, India

<sup>3</sup>Senior Lecturer, Department of Orthodontics and Dentofacial Orthopaedics, Mandi Gobindgarh, Fatehgarh Sahib, Punjab, India

<sup>4</sup>PG Student, Department of Orthodontics and Dentofacial Orthopaedics, Desh Bhagat Dental College, Mandi Gobindgarh, Fatehgarh Sahib, Punjab, India

<sup>5</sup>MDS Orthodontics, Private Practitioner, India

<sup>6</sup>MDS Orthodontics, Private Practitioner, India

**Corresponding Author:** Dr. Gurpreet Kaur

*(Received: 25 October 2025    Revised: 27 November 2025    Accepted: 04 December 2025)*

### KEYWORDS

Apical Root Resorption (ARR), Panoramic Radiographs, Mean Root Resorption Score (MRRS), Orthodontic Appliance, Orthodontic Treatment

### ABSTRACT:

**Aim:** This study aims to investigate the prevalence of apical root resorptions during orthodontic treatments.

**Materials and Methods:** This study examined the effects of fixed appliance orthodontic therapy on apical root resorption in 90 patients with various dental issues. Of these, 80 expressed interests in treatment, and only those who completed therapy were included. Participants were selected based on comprehensive dental records, including pre- and post-treatment panoramic X-rays. Exclusion criteria included prior orthognathic surgery, congenital anomalies, poor X-ray quality, systemic health conditions, previous dental trauma, and bruxism. Informed consent was obtained from all. We documented pre-treatment parameters, focusing on tooth extractions, and analysed pre- and post-treatment X-rays of 60 patients. Root lengths of maxillary and mandibular teeth were measured from the root apex to the incisal edge or cusp tip. Apical root resorption was assessed using the Levander and Malmgren classification, ranging from 0 (no changes) to 4 (severe resorption). The cohort was divided into two groups: Group I (40 patients with extractions) and Group II (40 patients without extractions), aiming to compare root resorption metrics and the impact of extractions on root stability.

**Statistical Analysis and Results:** This study examined the characteristics and treatment outcomes of 80 patients, aged 14 to 33, seeking orthodontic care, with a nearly equal gender distribution of 41 males and 39 females. Participants were divided into two groups: Group I, consisting of 40 patients who underwent tooth extractions, and Group II, comprising 40 patients treated with fixed appliances without extractions. In Group I, the baseline Mean Root Resorption Score (MRRS) for the upper anterior region was  $0.37 \pm 0.15$  before treatment. Post-treatment, this score increased to  $0.47 \pm 0.24$ , indicating significant root



resorption associated with extractions. In Group II, the pre-treatment MRRS was  $0.35 \pm 0.14$ , with a post-treatment score of  $0.41 \pm 0.17$ , reflecting less impact on root resorption. Statistical analyses, including the Mann-Whitney U test and Pearson Chi-Square test, were employed to evaluate gender differences and treatment effects, while Table 6 presents a comprehensive summary of root resorption across both groups using one-way ANOVA. Overall, the findings enhance understanding of the effects of extraction versus non-extraction orthodontic treatments on root structure, guiding best practices to balance effective outcomes with dental integrity.

**Conclusion:** This study concluded that ARR is common and is particularly pronounced in upper central incisors. Key contributing factors include extended treatment durations and specific orthodontic forces, especially during intrusive movements and torque applications. Younger patients are especially vulnerable to severe resorption, highlighting the need for careful treatment planning.

---

## Introduction

Apical Root Resorption (ARR) is a dental condition characterised by the irreversible reduction or loss of a tooth's root structure, particularly at the apex, which is the tip of the root. This phenomenon is often an unintended consequence of orthodontic treatment, where mechanical forces applied to the teeth can impact the surrounding bone and root structures.<sup>1,2</sup> However, various other factors can also contribute to the development of ARR, including dental trauma, bacterial infections, systemic health issues, and individual patient factors such as genetic predisposition and anatomical variations. If left unaddressed, ARR can significantly compromise the long-term health and viability of the affected tooth, leading to complications such as mobility, increased susceptibility to dental infections, and ultimately, the potential loss of the tooth. The progressive nature of ARR emphasises the importance of early diagnosis and intervention to preserve dental integrity.<sup>3,4</sup> The diagnosis of ARR commonly involves the use of dental radiographs, with panoramic radiographs (Orthopantomograms or OPGs) being frequently employed due to their availability and cost-effectiveness. OPGs provide a comprehensive view of the entire dental arch, which is beneficial for initial evaluations of dental health; however, they often lack the detail necessary to fully assess the extent and precise location of root resorption. In contrast, periapical (PA) X-rays are more effective for localised examinations as they offer a higher resolution view of the root structures and surrounding tissues, allowing for more accurate measurements of root length. For the

most detailed three-dimensional evaluation, Cone-Beam Computed Tomography (CBCT) is regarded as the gold standard. CBCT provides in-depth imaging of the root morphology, enabling clinicians to detect and analyse the complexities of ARR that traditional two-dimensional images might overlook.<sup>5-7</sup> When quantifying root length, a digital vernier calliper with an accuracy of 0.01 mm is widely accepted and utilised as a reliable measurement tool. This precision minimises human error and affords clinicians the accuracy needed to evaluate the degree of resorption effectively. However, it is essential to consider biological and intrinsic variables that may influence root structure and resorption patterns, including individual differences in dental anatomy, healing capabilities, and genetic factors that could predispose some patients to greater risks of ARR.<sup>8,10</sup> To quantitatively assess the severity of External Apical Root Resorption, the Levander and Malmgren scoring system is frequently employed, which ranges from 0 to 4. A score of 0 indicates no resorption, while a score of 4 signifies that more than one-third of the root has been lost. This scoring system provides a structured framework for evaluating resorption severity; however, practitioners should be aware that the reliance on 2D radiographs can potentially lead to an overestimation of resorption severity compared to the more precise evaluations that 3D imaging techniques offer.<sup>11-13</sup> The objective of this study is to investigate the prevalence and contributing factors associated with apical root resorption occurring during orthodontic treatment. By understanding the prevalence, risk factors, and implications of ARR,



dental professionals can develop more effective management strategies and mitigation plans to address the risks linked with orthodontic tooth movement, ultimately enhancing patient outcomes and preserving dental health.

## Materials and Methods

This study undertook a comprehensive investigation into the effects of fixed appliance orthodontic therapy on apical root resorption within a well-defined cohort of 90 patients, each presenting with a range of aesthetic, functional, and discomfort-related dental issues. Out of this broader population, 80 individuals expressed a clear interest in pursuing orthodontic intervention to address their concerns, prompting a focused analysis on this subgroup. Notably, all participants in this selected group had successfully completed their fixed appliance therapy prior to the study. To ensure the integrity, reliability, and validity of our findings, we meticulously selected participants based on their comprehensive dental records. These records included detailed pre- and post-treatment panoramic X-rays, which provided critical insights into the morphological changes in root structure. Additionally, only those individuals who did not display significant medical histories that could potentially confound the research outcomes were included in the study. The exclusion criteria were rigorously applied to eliminate potential biases and included individuals with a history of previous orthognathic surgery, congenital anomalies—such as cleft lip or palate—that could impact dental anatomy and treatment response, as well as those presenting with inadequate X-ray quality that might obscure root visibility. We also excluded patients with systemic health conditions, prior dental trauma, or impacted teeth, which could compromise the orthodontic process. Furthermore, individuals with parafunctional habits, such as bruxism, were excluded due to the risk of exacerbating root resorption. Lastly, patients with mental health disorders that could affect treatment compliance or understanding were not included in our study to maintain a focus on reliable participant behaviour and perception. Informed consent was obtained from all participants prior to inclusion in the study, ensuring that each individual was fully aware of the study's purpose, methodologies, and potential implications of their involvement. This thorough approach was designed to uphold ethical standards and

the reliability of the research outcomes. We rigorously documented pre-treatment parameters, with a specific focus on whether tooth extractions were necessary during orthodontic therapy. Out of the 80 participants, we analysed the pre- and post-treatment X-rays of 60 patients meeting our stringent criteria. Our measurement protocol involved assessing the root lengths of maxillary and mandibular teeth, specifically from the central incisors through to the first permanent molars. Tooth length was defined as the distance from the root apex to the midpoint of the incisal edge or cusp tip, allowing for precision in measurement. To quantify apical root resorption, we calculated the differences in tooth lengths pre- and post-treatment, specifically examining the left and right central incisors, lateral incisors, premolars, and first molars in both arches. External apical root resorption (EARR) was evaluated using the Levander and Malmgren classification system, which assigns scores ranging from 0 to 4: Score 0: No visible changes noted at the root apex, Score 1: Irregularities in the root contour without any significant resorption, Score 2: EARR measuring less than 2 mm, Score 3: EARR ranging from 2 mm to one-third of the total root length, Score 4: EARR surpassing one-third of the original root length. Post-scoring, the mean root resorption score (MRRS) was calculated for each patient, categorised into four distinct groups based on tooth location: upper anterior, upper posterior, lower anterior, and lower posterior. The study focused on an overall patient cohort of 80 individuals, who were systematically divided into two distinct groups for a thorough comparative analysis. Group I comprised 40 patients who underwent tooth extractions as part of their orthodontic treatment, while Group II included 40 patients treated without the need for extractions. The primary objective was to examine and compare the pre- and post-treatment metrics of root resorption, utilising panoramic X-rays as the diagnostic tool. This methodology allowed for an in-depth investigation into the prevalence and severity of apical root resorption linked to the use of fixed orthodontic appliances. The results of this research are expected to provide valuable insights into the potential complications associated with different orthodontic treatment modalities, specifically the impact of extractions on root stability. By understanding these outcomes, the study aims to inform orthodontic practice, ultimately leading to improved patient care, enhanced treatment strategies, and better



long-term outcomes for individuals undergoing orthodontic interventions.

## Statistical Analysis and Results

In this study, we utilised SPSS version 29.0 for our statistical analyses, leveraging its robust capabilities for handling social science data. We employed the chi-square test to assess differences in proportions across various cohorts. For comparing root resorption levels between genders and distinguishing between extraction and non-extraction cases, we applied the Mann-Whitney U test. We looked at how therapy type, treatment duration, overjet measurements, and post-treatment MRRS are related to each other by using Bivariate Correlation Analyses. Our multiple regression analysis, with MRRS as the dependent variable, integrated age, gender, and therapy type, overjet, and treatment duration as independent variables. This detailed analytical approach ensured a comprehensive understanding of the trends and relationships inherent in our dataset.

## Results

This study explored the characteristics and treatment outcomes of a diverse cohort of 80 patients who sought orthodontic care, ranging in age from 14 to 33 years. The participant demographic included 41 males and 39 females, highlighting a nearly equal gender distribution. A detailed breakdown of these demographics is presented in Table 1, while Graph 1 visually conveys key demographic factors, such as the distribution of ages and the proportions of each gender among the study participants. To enable a thorough comparative analysis of treatment outcomes, the patients were systematically categorized into two distinct groups based on their specific orthodontic needs. Group I comprised 40 patients whose treatment plans mandated tooth extractions due to various orthodontic issues, reflecting a range of complexities in their cases. In contrast, Group II included 40 patients who received orthodontic treatment via fixed appliances, successfully addressing their dental alignment issues without the necessity for extractions. This division allowed for a focused examination of the effectiveness and impacts of different orthodontic approaches. Table 2 presents the baseline Mean Root Resorption Score (MRRS) for Group I (n=40) prior to the initiation of orthodontic

treatment. To assess potential differences in root resorption between genders, a gender-based analysis was conducted using the Mann-Whitney U test. Additionally, the statistical significance of the findings was evaluated with the Pearson Chi-Square test. The results revealed that in Group I, the upper anterior region exhibited an average MRRS of  $0.37 \pm 0.15$ , indicating the initial levels of root resorption prior to the commencement of any orthodontic interventions. Following the completion of treatment, Table 3 details the post-treatment MRRS for the extraction group (n=40). The same robust statistical methodologies were employed to investigate any gender differences in root resorption among the orthodontic patients in this group. Notably, the upper anterior region demonstrated an average MRRS of  $0.47 \pm 0.24$  post-treatment, suggesting a significant increase in root resorption following extraction-related treatment. In contrast, Table 4 outlines the pre-treatment mean root resorption score for patients in Group II (n=40), who received fixed orthodontic appliances without the need for extractions. Applying the established gender-based statistical methodologies, the average MRRS for the upper anterior region was determined to be  $0.35 \pm 0.14$ , reflecting the baseline condition of root structure prior to the initiation of treatment in this non-extraction cohort. Table 5 further summarizes the post-treatment MRRS for Group II (n=40). Similar to the first group, gender differences in root resorption scores were analyzed using the Mann-Whitney U test and the Pearson Chi-Square test. The results revealed an upper anterior average of  $0.41 \pm 0.17$ , indicating a notable difference in the impact of traditional orthodontic treatment methods on root resorption when extractions are not performed. Finally, Table 6 consolidates the statistical analysis of root resorption across all groups through one-way ANOVA. This comprehensive statistical analysis provides valuable insights into the comparative effects of extraction versus non-extraction orthodontic treatments on root resorption scores, contributing to the understanding of orthodontic treatment implications on dental health and the preservation of root structure. The findings aim to inform best practices in orthodontics, ensuring a balance between effective treatment outcomes and the preservation of dental integrity.

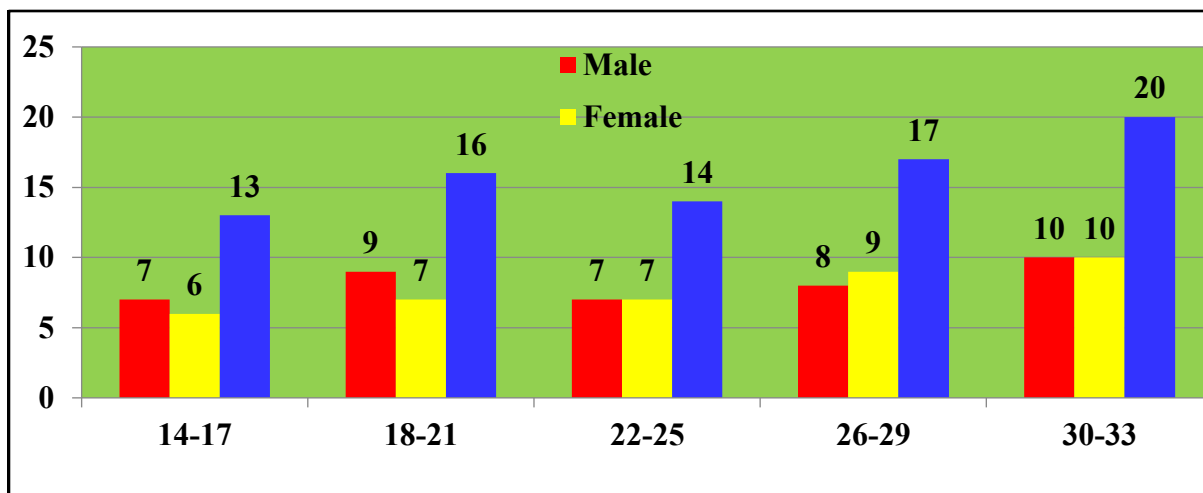


**Table 1:** Age & gender based statistical description of contributing patients

Age Group (Yrs)	Male	Female	Total	P value
14-17	7	6	13	0.03
18-21	9	7	16	0.60
22-25	7	7	14	0.01*
26-29	8	9	17	0.80
30-33	10	10	20	0.50
Total	41	39	80	*Significant

\*p<0.05 significant

**Graph 1:** Patients demographic distribution and associated details



**Table 2:** Group 1 (n=40) Patients who underwent fixed orthodontic treatment with extractions had their mean root resorption score (MRRS) assessed before treatment. Gender-based analysis of root resorption utilised the Mann-Whitney U test, while the Pearson Chi-Square test evaluated the significance of outcomes. This approach enhances understanding of gender differences in root resorption among orthodontic patients

Segment	Mean	Std. Dev.	Std. Error	95% CI	Pearson Chi-Square Value	df	p value
Upper Anterior	0.37±0.15	1.19	1.15	1.09	1.07	1.09	1.0
Upper Posterior	0.10±0.12	1.05	1.03	1.02	1.05	1.02	0.2*
Lower Anterior	0.19±0.17	1.11	1.14	1.08	1.07	1.08	0.01*



Lower Posterior	0.14±0.16	1.09	1.17	1.08	1.18	1.02	0.06
*p<0.05 significant							

**Table 3:** Group 1 (n=40) Patients who underwent fixed orthodontic treatment with extractions had their mean root resorption score (MRRS) assessed post-treatment. Gender-based analysis of root resorption utilised the Mann-Whitney U test, while the Pearson Chi-Square test evaluated the significance of outcomes. This approach enhances understanding of gender differences in root resorption among orthodontic patients

Segment	Mean	Std. Dev.	Std. Error	95% CI	Pearson Chi-Square Value	df	p value
Upper Anterior	0.47±0.24	2.30	2.17	2.19	2.07	2.19	1.0
Upper Posterior	0.22±0.19	2.25	2.23	2.12	1.21	2.12	0.2*
Lower Anterior	0.27±0.22	2.21	2.32	2.18	2.09	2.12	0.07
Lower Posterior	0.19±0.18	2.20	2.13	2.12	1.12	2.12	0.08
*p<0.05 significant							

**Table 4:** Group 2 (n=40): Patients who underwent fixed orthodontic treatment non-extraction had their mean root resorption score (MRRS) assessed before treatment. Gender-based analysis of root resorption utilised the Mann-Whitney U test, while the Pearson Chi-Square test evaluated the significance of outcomes. This approach enhances understanding of gender differences in root resorption among orthodontic patients

Segment	Mean	Std. Dev.	Std. Error	95% CI	Pearson Chi-Square Value	df	p value
Upper Anterior	0.35±0.14	1.15	1.19	1.09	1.05	1.01	0.01*
Upper Posterior	0.09±0.11	1.10	1.21	1.10	1.12	1.04	0.07
Lower Anterior	0.15±0.15	1.17	1.17	1.07	1.04	1.07	0.01*
Lower Posterior	0.03±0.14	1.03	1.20	1.05	1.09	1.02	0.06
*p<0.05 significant							



**Table 5:** Group 2 (n=40) Patients who underwent fixed orthodontic treatment with non-extractions had their mean root resorption score (MRRS) assessed post-treatment. Gender-based analysis of root resorption utilised the Mann-Whitney U test, while the Pearson Chi-Square test evaluated the significance of outcomes. This approach enhances understanding of gender differences in root resorption among orthodontic patients

Segment	Mean	Std. Dev.	Std. Error	95% CI	Pearson Chi-Square Value	df	p value
Upper Anterior	0.41±0.17	2.29	2.14	2.17	2.07	2.09	1.0
Upper Posterior	0.12±0.16	2.23	2.20	2.16	1.19	2.02	0.2*
Lower Anterior	0.25±0.27	2.20	2.19	2.15	2.19	2.08	0.07
Lower Posterior	0.07±0.10	2.17	2.16	2.14	1.19	2.07	0.06
*p<0.05 significant							

**Table 6:** Estimation amongst all studied groups using one-way ANOVA

Variables	Degree of Freedom	Sum of Squares $\Sigma$	Mean Sum of Squares $m\Sigma$	F	Level of Sig. (p)
Between Groups	6	2.530	2.457	1.9	0.01*
Within Groups	34	2.440	2.645		–
Cumulative	267.14	17.454	*p<0.05 significant		

## Discussion

Bartzela T et al reviewed in their study that apical root resorption (ARR) is a frequently encountered yet often challenging consequence of orthodontic treatment, distinguished by the irreversible loss of tooth structure specifically at the root apex. This condition can considerably affect the long-term health and stability of the tooth, as well as its functional capabilities. As a result, it plays a significant role in determining the overall success of orthodontic care. Despite the inherent challenges posed by ARR, proactive monitoring, timely interventions, and strategic management during the orthodontic process can often either prevent its occurrence or significantly reduce its impact on dental

health.<sup>14,15</sup> Villaman-Santacruz H et al showed in their study that the aetiology of ARR is complex and multifactorial. It encompasses a variety of factors, including genetic predispositions, systemic health conditions, previous dental history, and the specific orthodontic techniques employed during treatment. The application of orthodontic forces is particularly critical; extensive research has demonstrated a consistent correlation between higher force magnitudes and an increased risk of severe root resorption. In contrast, lighter, more precisely controlled applications of force have been associated with a lower incidence of ARR. This observation underscores the imperative need for individualised treatment plans where orthodontic forces are meticulously calibrated to align with each patient's



unique anatomical and biological characteristics.<sup>16,17</sup> Nieto-Nieto N et al included in their study that ARR commences when the mechanical pressures placed upon the cementum, the protective tissue surrounding the tooth roots, exceed its natural ability to self-repair. Such excessive pressure can result in the exposure of underlying dentin, thereby rendering the tooth roots susceptible to odontoclasts, which are specialised cells responsible for the resorption of bone and tooth structure. The resorption process is frequently exacerbated in areas containing necrotic tissue, as these compromised sites become targets for orthodontic forces, ultimately increasing the vulnerability of the root structures to resorption.<sup>18,19</sup> Parashos P et al reviewed in their study In clinical practices, panoramic radiography is commonly employed for the assessment of ARR, given its capability to provide a broad view of the jaw anatomy and the interrelationships between teeth. However, this imaging technique is not without its drawbacks; distortions and limitations in detail in specific areas can hinder accurate assessments. To achieve more precise measurements of apical resorption, dental professionals frequently utilise digital Vernier callipers, either on radiographs or directly on extracted teeth. This approach facilitates enhanced diagnostic accuracy and allows for more detailed evaluations of the extent of resorption.<sup>20</sup> Shukla NK et al reviewed in their study that while this scoring system is effective for classifying severity, it is important to note that it has been criticised for potentially leading to an overestimation of resorption levels when utilising traditional two-dimensional radiographic techniques. In response to these limitations, advancements in imaging technology, particularly with the advent of three-dimensional imaging modalities like cone-beam computed tomography (CBCT), have significantly improved the accuracy of assessments related to root morphology and resorption evaluations. CBCT offers enhanced visualisation of root structures, enabling a more precise characterisation of ARR. This underscores a progressive shift in the diagnostic landscape within orthodontics, emphasising the integration of advanced imaging techniques in clinical practice. Such advancements are crucial not only for improving patient safety but also for optimising treatment efficacy and ultimately enhancing the outcomes of orthodontic care.<sup>21,22</sup> Kaur J et al showed in their study that to systematically assess the severity of ARR, clinicians

often rely on the Levander and Malmgren scoring system, which categorises the severity of resorption on a scale from 0 to 4: Score 0: No observable signs of resorption, indicating a healthy root structure and no concerns for future complications. Score 1: Mild contour irregularities on the root surface are noted, suggesting the very early onset of resorption. Score 2: Less than 2 mm of root loss is observed, indicating a moderate level of concern that warrants careful monitoring. Score 3: A loss ranging from 2 mm to one-third of the root structure is present, reflecting significant structural compromise and a need for potential intervention. Score 4: Over one-third of the root has been resorbed, indicating severe structural compromise that may necessitate changes to treatment approach or heightened clinical vigilance.<sup>23</sup>

## Conclusion

In light of the limitations inherent in the study, findings indicated that ARR is a common occurrence in orthodontics, with a reported prevalence ranging from 20% to as high as 100%. Notably, this phenomenon is particularly pronounced in anterior teeth, with upper central incisors showing a heightened susceptibility. Several key factors contribute to the development of ARR, including extended treatment durations and specific orthodontic force mechanics, notably those associated with intrusive movements and torque applications. Younger patients appear to be particularly vulnerable to experiencing severe resorption, raising important considerations for treatment planning and patient management within this demographic. Given these insights, future studies could benefit from a comparative analysis of ARR across various orthodontic appliance types, such as fixed appliances versus clear aligners. This research could further evaluate the impact of specific tooth movements, including both intrusion and extrusion, on the likelihood of developing ARR. Additionally; it would be valuable to investigate potential risk factors that may predispose individuals to ARR, including genetic predispositions and inflammatory responses. Employing advanced radiographic imaging techniques, such as panoramic radiography, could enhance the accuracy of diagnoses and facilitate a more thorough understanding of the condition. Moreover, research needs to focus on the intricate interactions between different types of orthodontic forces, specifically those related to intrusion



and torque, treatment duration, and the application of newer techniques such as aligners. By utilising panoramic radiographic imaging for precise measurements, researchers can better uncover the underlying mechanisms that contribute to ARR. These findings underscore the urgent need for ongoing research to further elucidate the complex interplay of factors associated with ARR and to refine clinical practices within the orthodontic and periodontal fields. This understanding is vital for developing strategies aimed at preventing ARR and ensuring more favourable outcomes for patients undergoing orthodontic treatment.

## References

1. Weltman B, Vig KW, Fields HW, Shanker S, Kaizar EE. Root resorption associated with orthodontic tooth movement: A systematic review. *Am J Orthod Dentofacial Orthop.* 2010;137(4):462–76.
2. Iber-Diaz P, Senen-Carramolino R, Otero-Pregigueiro A, Palma-Fernandez JC, Iglesias-Linares A. External apical root resorption assessment revisited: a scoping review. *Angle Orthod.* 2025 Jul 11;95,6:670-682.
3. Sameshima GT, Iglesias-Linares A. Orthodontic root resorption. *J World Fed Orthod.* 2021 Dec;10,4:135-143.
4. Yassir YA, McIntyre GT, Bearn DR. Orthodontic treatment and root resorption: an overview of systematic reviews. *Eur J Orthod.* 2021 Aug 3;43,4:442-456.
5. Iglesias-Linares A, Hartsfield JK Jr. Cellular and Molecular Pathways Leading to External Root Resorption. *J Dent Res.* 2017 Feb;96,2:145-152.
6. Marzadori M, Stefanini M, Sangiorgi M, Mounssif I, Monaco C, Zucchelli G. Crown lengthening and restorative procedures in the esthetic zone. *Periodontol 2000.* 2018 Jun;77,1:84-92.
7. Pinheiro LHM, Guimarães LS, Antunes LS, Kuchler EC, Kirschneck C, Antunes LAA. Genetic variation involved in the risk to external apical root resorption in orthodontic patients: a systematic review. *Clin Oral Investig.* 2021 Oct;25(10):5613-5627.
8. Kanas RJ, Kanas SJ. Localised idiopathic apical root resorption: a report of five cases with emphasis on differential diagnosis. *Compend Contin Educ Dent.* 2012 Mar;33,3:184-6, 188, 190-5.
9. Peralta-Mamani M, Rubira CM, López-López J, Honório HM, Rubira-Bullen IR. CBCT vs panoramic radiography in assessment of impacted upper canine and root resorption of the adjacent teeth: A systematic review and meta-analysis. *J Clin Exp Dent.* 2024 Feb 1;16,2:e198-e222.
10. Adarsh K, Sharma P, Juneja A. Accuracy and reliability of tooth length measurements on conventional and CBCT images: An *in vitro* comparative study. *J Orthod Sci.* 2018 Sep 6;7:17.
11. Melo, Giordana & Martelli, Karine & Freitas, Karina Maria & Valarelli, Fabrício & Cançado, Rodrigo. Influence of Asthma on the Degree of Apical Root Resorption in Orthodontically Treated Patients. *Iranian Journal of Orthodontics.* 2017;5:6-60.
12. Handem, Roberta & Janson, Guilherme & Matias, Murilo & Freitas, Karina Maria & Lima, Darwin & Garib, Daniela & Freitas, Marcos. External root resorption with the self-ligating Damon system—a retrospective study. *Progress in Orthodontics.* 2016;7:12-18.
13. Futyma-Gąbka K, Różyło-Kalinowska I, Piskórz M, Bis E, Borek W. Evaluation of root resorption in maxillary anterior teeth during orthodontic treatment with a fixed appliance based on panoramic radiographs. *Pol J Radiol.* 2022 Oct 5;87:545-548.
14. Bartzela T, Turp JC, Motschall E, Maltha JC. Medication effects on the rate of orthodontic tooth movement: A systematic literature review. *Am J Orthod Dentofacial Orthop.* 2009;135(1):16–26.
15. Pandis N, Pandis BD, Pandis V, Eliades T. Occupational hazards in orthodontics: A review of risks and associated pathology. *Am J Orthod Dentofacial Orthop.* 2007;132,3:280–92.
16. Villaman-Santacruz H, Torres-Rosas R, Acevedo-Mascarúa AE, Argueta-Figueroa L. Root resorption factors associated with orthodontic treatment with fixed appliances: A systematic review and meta-analysis. *Dent Med Probl.* 2022 Jul-Sep;59,3:437-450.
17. Kalra S, Gupta P, Tripathi T, Rai P. External apical root resorption in orthodontic patients: molecular and genetic basis. *J Family Med Prim Care.* 2020 Aug 25;9,8:3872-3882.



18. Nieto-Nieto N, Solano JE, Yañez-Vico R. External apical root resorption concurrent with orthodontic forces: the genetic influence. *Acta Odontol Scand.* 2017 May;75(4):280-287.
19. Feller L, Khammissa RA, Thomadakis G, Fourie J, Lemmer J. Apical External Root Resorption and Repair in Orthodontic Tooth Movement: Biological Events. *Biomed Res Int.* 2016;2016:4864195.
20. Parashos P. Endodontic-orthodontic interactions: a review and treatment recommendations. *Aust Dent J.* 2023 Jun;68 Suppl 1:S66-S81.
21. Shukla NK, Sharma VK, Chaturvedi TP, Parihar AV, Chugh VK. Prediction of spontaneous eruption of palatally displaced canine based on variables measurements in panoramic radiograph: A systematic review. *J Oral Biol Craniofac Res.* 2021 Apr-Jun;11(2):344-353.
22. Masthoff M, Gerwing M, Masthoff M, Timme M, Kleinheinz J, Berninger M, Heindel W, Wildgruber M, Schülke C. *Dental Imaging - A basic guide for the radiologist.* *Rofo.* 2019 Mar;191(3):192-198. English, German.
23. Kaur J, Shetty D, Sharma P, Kumar P, Juneja A. Evaluation of root resorption after orthodontic treatment: A clinical study of contributory factors [Internet]. *J Dent Spec.* 2025;8(1):3-8.