



A Case Series on Branchial Cleft Cyst in Young Adults

¹Dr. Rajeshwari Nachiyar, ²Dr. M. K. Rajasekar

¹Department of ENT, Sree Balaji Medical College and Hospital, Chrompet, Chennai – 600044

(Received: 07 January 2024

Revised: 12 February 2024

Accepted: 06 March 2024)

KEYWORDS

Branchial Cleft cyst, Excision

ABSTRACT:

Branchial cleft cysts constitute about 3% of surgical swellings of neck. The current study's objective was to investigate the clinical signs, diagnosis, and surgical treatment of branchial cleft cyst in a significant patient population. At a 3-month follow-up, every patient had completely recovered and there had been no recurrence.

Introduction

Branchial cleft cysts occur as a result of failure of obliteration of second, third and fourth branchial cleft in the early prenatal period. One per million people is thought to be affected annually, according to estimates. [1,2] The patients are diagnosed on average when they are 20 years old. Between the initial presentation and appropriate treatment, 3.5 years pass. No blatant familial propensity can be found. The lateral neck region, namely below the external ear canals, above the hyoid bones, anterior to the sternocleidomastoid muscle, and posterior to the submandibular angles, is a common location for the anomalies. Cysts, sinuses, fistulas, and various combinations of these entities are all part of the spectrum of developmental disorders. [3] The fundamentals of management include early detection, managing the infection situation, and complete excision. The patients have a usually good prognosis.

Case report 1:

A young 25-year-old patient complained of swelling over the lateral aspect of the neck. On clinical examination, a 3x3 cm enlargement on the right lateral region of the neck was identified. The lump was close to the sternocleidomastoid muscle and lied anterior and deep to it. When palpated, it was soft in consistency. Right internal jugular vein and carotid artery were both strongly defined hypoechoic lesions on the USG of the neck, with characteristics that suggested a solid lymph node or neck sheath tumour. The anterior border of the sternocleidomastoid muscle at the level of the thyroid cartilage was shown to have a well-defined altered signal intensity lesion by cervical MRI. This lesion may have extended from the C4 vertebral body to the inferior plate

of the C5 vertebral body and appeared isointense on T1 weighted imaging, isointense to hypotense on T2 weighted imaging, with no evidence of diffusion or restriction, features likely suggestive of branchial cleft cyst. The results of FNAC revealed characteristics of a branchial cleft cyst. These observations led to the patient being operated on, and the cyst removed was examined. The gross discovery revealed that the tissue was 3 cm by 3 cm in size and that the excised sample was primarily brownish in colour. The cystic cavity of the specimen included mucoid material, and the cyst wall was quite thick and covered in papillary projections.

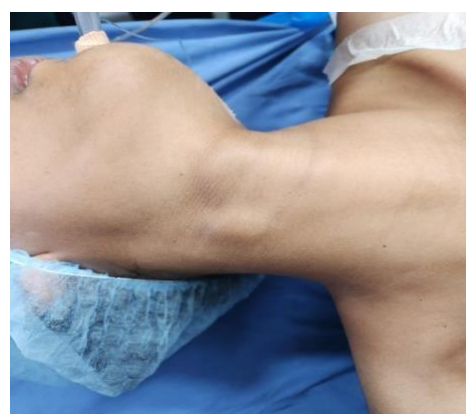

Fig:1 Preoperative presentation

The tissue underwent formalin fixation, processing, sectioning, and haematoxylin and eosin staining. According to histopathological results, the connective tissue beneath the cystic cavity had germinal centres. At various locations, the cystic epithelium was thrown into folds. Squamous epithelial strands that had been desquamated from the cystic epithelium could be seen in the cystic lumen. The connective tissue beneath revealed an abundance of lymphoid tissue with several germinal



centres. There were features of fibrous connective tissue with fibroblasts and blood vessels lined with endothelial cells. Ziehl-Neelsen stain was previously performed to rule out tuberculosis, and Koch bacilli were not seen. A final diagnosis of an infected branchial cyst was made in light of all these findings. By the end of a six-month follow-up, the patient had fully recovered and had no recurrence.




Fig 2a: Gross picture of the branchial cyst postoperatively.

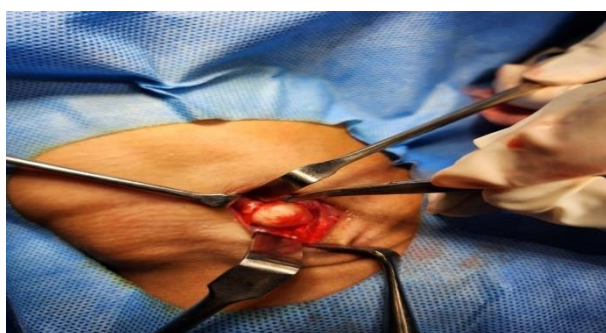

Fig 2b: Intraoperative excision of the branchial cleft cyst

Case report 2:

An upper neck swelling on the right side has been persistent for four months in a 22-year-old male patient. When palpated, the swelling was soft and non-tender. Upon inspection, a 4 × 4 cm swelling was discovered on the right side of neck, extending anteriorly from the mandibular angle to posteriorly deep to the sternocleidomastoid. A well-defined cystic lesion measuring 2.3 × 3.5 × 4.1 cm was seen on the right side of the neck by USG. A 47 × 36 × 30 mm cystic enlargement posterior to the right sternocleidomastoid that was barely contacting the carotid sheath was seen on a CT scan. On USG guided FNAC findings were consistent with a Branchial cyst because it included scattered neutrophils and proteinaceous debris but no atypical or cancerous cells. Careful dissection was used to separate the nerve from the cyst wall, and the cyst was

completely removed along with its tract. Postoperative period was uneventful.

Case report 3:

A 24-year-old woman came in with a painful and cystic swelling on the left side of the neck that had been present for 2 months. Several USGs of the patient's neck revealed edema and an infected cervical lymph node extending cephalad from the right common carotid artery's bifurcation on the lateral side from the submandibular region. She was treated for two months as a cervical lymph node abscess with several aspirations, one incision drainage treatment, and a recurrence of the edema occurred. According to Bailey classification a type II branchial cyst (2nd cleft) of around 3 × 3 × 2.5 cm was found beneath the platysma, posterior to the Lt sternocleidomastoid, and just next to the carotid sheath. Due to recurrent infections, the cyst had been affixed to the nearby tissues, including the submandibular gland, SCM, and carotid sheath with many lymph nodes. Branchial cyst has been tentatively diagnosed on left side. The cyst was excised under general anaesthesia.

Case report 4:

A 28-year-old man came with a right-sided neck tumour that had been growing gradually for the past 1 month. The patient was a non-smoker. The location of a mass was revealed by a CT scan. During the initial fine needle aspiration, many squamous cells and neutrophils were seen. Following surgery, it was discovered that a hard mass measuring 3 × 5 × 4.5 inches had grown anteriorly from the sternocleidomastoid muscle and was closely associated with cranial nerve 10. Squamous walled cyst with no indications of malignancy was seen in the intraoperative pathology findings. The surgical specimen's histological analysis revealed that the lump was a branchial cleft cyst. Postoperatively, patient was followed up and had no recurrence.

Case report 5:

A 27-year-old male patient who was referred to this institution came with complaints of swelling over left lateral aspect of neck for the past 15 days. Physical examination results revealed that the patient had a sore cystic enlargement in the left tonsil when they first came to our institution. A tiny cystic lesion that was contained within the left tonsil and was about 1.2 × 0.6 × 1.2 cm was visible on a neck CT scan. A fine-needle aspiration biopsy was confirmed with no aberrant cytological or microbiological results. Under the diagnosis of a second branchial cleft cyst that had developed in the tonsil, a left tonsillectomy and the excision of the cyst were carried out through the mouth. When the procedure was done, it was discovered that the cyst had grown inside the tonsil and was reaching towards the peritonsillar region. The



patient was identified as having a branchial cleft cyst following the surgery, per the results of the histological testing. The patient has been under observation in outpatient follow-up for the past two years, and there have been no indications of recurrence.

Discussion

In young adults, branchial cleft cysts often present with swelling as the only major complaint. They rarely present with pain. Clinical symptoms first appear in late childhood or early adulthood. It's critical to rule out lymphoma, TB, and metastatic lymphadenopathy in older persons with this presentation. [5]. Branchial cleft cyst's genesis is debatable. Branchial cysts have four main genesis ideas that have been proposed thus far. They include thymopharyngeal ductal origin, partial obliteration of branchial mucosa, persistence of pre-cervical sinus remnants, and cystic lymph node origin. [2,6] The structure most frequently thought to be the cause of branchial cyst is likely the branchial apparatus, which starts to form in the second week of foetal life and is finished by the sixth or seventh week. Branchial cleft cyst is thought to occur from insufficient obliteration of the branchial cleft mucosa, which remains latent until prompted to expand later in life, leading to cyst formation, according to Ascherson's theory from 1832. The postulated cause is specifically the absence of cervical sinus degeneration caused by the expansion of the second arch over the third and fourth arches. As a result, the second arch overlies the third and fourth arches, which remain as tiny pockets with their ectodermal epithelium. Normally, these pockets close up while the foetus is developing; but, if they don't, cysts, sinuses, and fistulas may form later. In contrast to pharyngeal clefts or pouches, his second idea contends that branchial fistulas are remnants of the cervical sinus. [4] Wenglowski proposed that the process by which lateral cervical cysts were produced was cystic degeneration of cervical lymph nodes. He also asserted that a lateral cervical cyst was caused by insufficient thymopharyngeal duct obliteration. According to Bhaskar and Bernier, entrapped epithelium stimulates the cystic modification of the cervical lymph node. They proposed the brachial cleft, pharyngeal pouch, and parotid gland as three potential origins of these epithelial inclusions. Immunohistochemistry is currently being used to examine, at the molecular level, the nature of the epithelial cells and their connection to other types of epitheliums elsewhere in the body in order to shed light on the origin of these cysts. [2,7] Radiologic examinations: A CT or MRI scan will depict a cyst that is filled with fluid and will highlight its size and anatomical connections. The branchial cyst's distinctive thick wall will also be visible on the CT scan.

Histopathology: Squamous stratified epithelium typically lines branchial cysts, but it can also occasionally be pseudostratified, columnar, and ciliated. Ulcers in the lining are possible. There is a lot of lymphoid tissue, which displays germinal centres, in the connective tissue wall [8]. Differential diagnosis: In this neck region, the possibility of metastatic squamous cell carcinoma may be taken into consideration as a differential diagnosis. The differential diagnosis may also include a thyroglossal tract cyst. Scrofula, lymphadenopathy associated with HIV and tuberculosis, cat scratch disease, sarcoidosis, and Hodgkin lymphoma are further differentials to be taken into account. [8,9,10]. Treatment and Prognosis: Excision of Branchial cyst under GA is the definitive treatment modality. During dissection, important structures such as hypoglossal nerve, glossopharyngeal nerve, carotids, spinal accessory nerve, and posterior belly of digastric muscle should be watched out for. Also, posterior pillar of tonsils lies medially to the cyst and should be kept in mind while dissecting. Patients usually recover Without any complications.

CONCLUSION:

Excision of Branchial cleft cyst along with the tract reduces the chances of recurrence.

REFERENCES:

1. Wei YK, Wang KJ, Jou YL, Chang YH, Chou CS. Type II first branchial cleft anomaly - A case report. *Tzu Chi Med J.* 2005;357-60. [Google Scholar]
2. Arndal H, Bonding P. First branchial cleft anomaly. *ClinOtolaryngol Allied Sci.* 1996;21:203-7. [PubMed][Google Scholar]
3. Frazer JE. The nomenclature of diseased states caused by certain vestigial structures in the neck. *Br J Surg.* 1923;11:131-6. [Google Scholar]
4. McClure MJ, McKinstry CS, Stewart R, Madden M. Late presentation of brachial cyst. *Ulster Med J.* 1998;67:129-31. [PMC free article][PubMed][Google Scholar]
5. Glosser JW, Pires CA, Feinberg SE. Branchial cleft or cervical lymphoepithelial cysts: Etiology and management. *J Am Dent Assoc.* 2003;134:81- [PubMed][Google Scholar]
6. Little JW, Rickles NH. The histogenesis of the brachial cyst. *Am J Pathol.* 1967;50:533-47. [PMC free article][PubMed][Google Scholar]
7. Marx RE, Stern D. 2nd edition. Illinois: Quintessence Publishing Co, Inc; 2012.
8. Oral and Maxillofacial Pathology A Rational for Diagnosis and Treatment. [GoogleScholar]
9. Thomaidis V, Seretis K, Tamiolakis D, Papadopoulos N, Tsamis I. Branchial cysts.



-
12. A report of 4 cases. ActaDermatovenerol Alp PanonicaAdriat. 2006; 15:85–
 13. [PubMed][Google Scholar]
 14. Chen MF, Ueng SH, Jung SM, Chen YL, Chang KP. A type ii first branchial cleft cyst masquerading as an infected parotid warthin's tumor. Chang Gung Med
 15. J. 2006; 29:435–9. [PubMed][Google Scholar]