



Nasal Deformation and Palatal Perforation Due to Excessive use of Opioid Pain Reliever Through Nasal Spray- A Case Report

Dr. Vinay Kakatkar¹, Dr. Monesh Sharma², Dr. Abhijit Tambe³, Dr. Sneha Sharma⁴, Dr. Ritu Sharma⁵, Dr. Sonesh Sharma⁶

¹Professor and HOD, Dept. of Prosthodontics, SMBT IDSR, Dhamangaon

²Associate Professor, Dept. of Prosthodontics, SMBT IDSR, Dhamangaon

³Associate Professor, Dept. of Prosthodontics, SMBT IDSR, Dhamangaon

⁴Assistant Professor, Dept. of Conservative dentistry and Endodontics, SMBT IDSR, Dhamangaon

⁵Assistant Professor, Dept. of Conservative dentistry and Endodontics, SMBT IDSR, Dhamangaon

⁶Postgraduate Student, Dept. of Public health Dentistry, Peoples' Dental Academy, Bhopal

(Received: 14 April 2024

Revised: 01 May 2024

Accepted: 18 June 2024)

KEYWORDS

Opioids,
Tapentadol, nasal
spray, nasal
deformity, palatal
perforation,
mucosal necrosis.

ABSTRACT:

Some undiagnosed idiopathic pains are source of constant irritability and impaired quality of life. Such patients are inadvertently prescribed opioid drugs by their physician for short duration of time. For faster pain relief, nasal spray is popular choice of drug delivery. Since opioid are addiction causing drug if used excessively without supervision, it has far reaching psychological and physical impact on patients. This case report presents a case of nasal deformation and palatal perforation found in young female referred from ENT Clinic to dental OPD with chief complaint of nasal regurgitation. Detailed history revealed aetiology to be chronic excessive use of narcotic pain reliever through nasal spray. Thus there is a need for awareness among patients and clinicians about etiopathogenesis of such deformity.

1. Introduction

International Association for study of pain defines pain as unpleasant sensory and emotional experience associated with, or resembling that associated with, actual or potential tissue damage (1). Idiopathic Chronic pain that lasts for months often is undiagnosed or misdiagnosed. Such type of pain is source constant irritation, impairs quality of life and can lead to depression and anxiety. Such patients are prescribed opioid as pain reliever for short duration of time. Amongst route of drug administration of opioid, nasal inhalation spray is popular choice. Since opioid are prescription only drug, their unsupervised use is strictly prohibited due to high risk of addiction. Chronic use of drugs through nasal inhalation causes progressive necrosis of nasal mucosa that extends to adjacent tissue like nasopharynx and palate. This case report presents a case of nasal deformation and palatal perforation found

in young female referred from ENT Clinic to dental OPD with chief complaint of nasal regurgitation. Detailed history revealed aetiology to be chronic excessive use of narcotic pain reliever through nasal spray.

2. Case Report-

A 30 year old female patients referred from ENT clinic reported to Dental OPD with chief complaint of nasal regurgitation. Past medical history shows chronic abdominal pain since one year for which she consulted various specialists and various investigations were carried out but without any diagnosis. She was prescribed opioid tapentadol (Fig.1) through nasal spray by her pain physician for short duration of time. Since stoppage of drug causes reappearance of pain, she kept repeating dose without supervision for months. After months of negligence towards ill effects of abuse of drug, she reported to ENT clinic with nasal cartilage



collapse causing nasal deformity (Fig.2) and palatal perforation (Fig.3) due to necrosis. Then she was referred to Dental OPD due to complaint of nasal regurgitation. Histopathological report of nasal biopsy showed necrotic material, inflammatory cells, and scant viable cartilage (Fig.4). She was counselled and palatal obturator was planned to cover up the defect. Impression was made with irreversible hydrocolloid. Interim acrylic obturator was fabricated. Obturator was inserted. Fit was checked and post-operative instructions were given. Definitive treatment was not planned as there was a possibility of continued use of drug. Upon delivery of the obturator, the patient's speech showed significant improvement. The patient was satisfied with the result and was scheduled for follow-up.

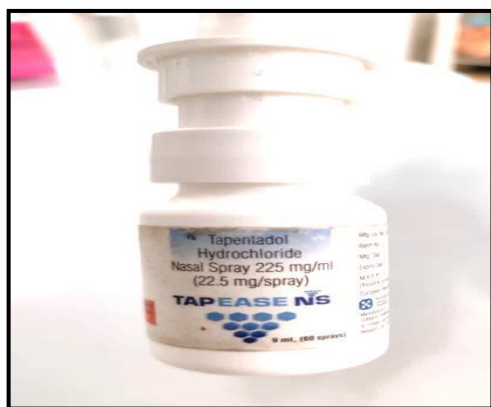


Figure- 1) Tapentadol nasal spray

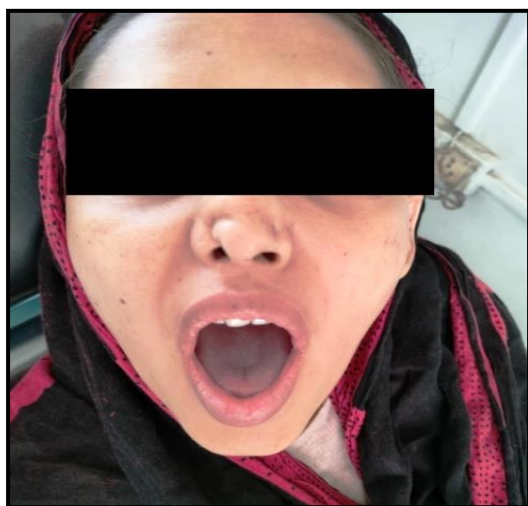

Figure-2) Nasal Deformity

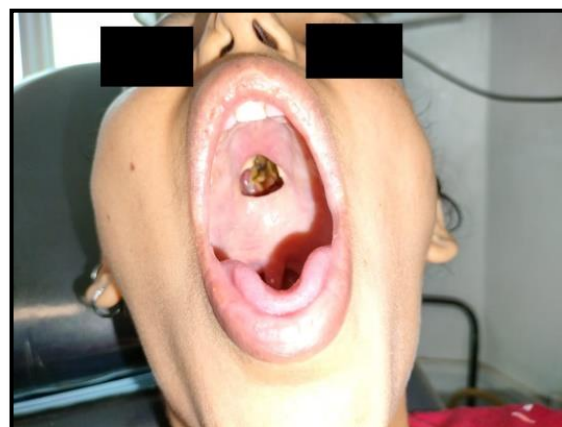

Figure- 3) Palatal Perforation

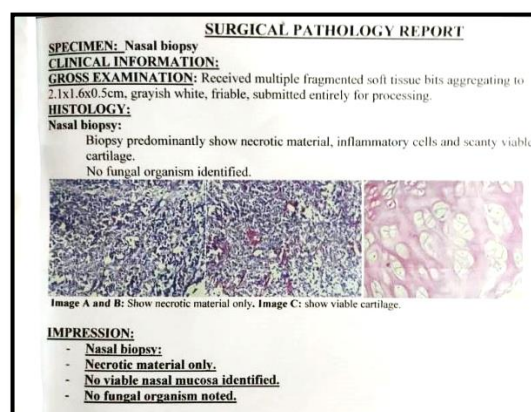


Figure-4) Histopathology report

3. Discussion

Management of pain is commonly done with help of opioid and NSAIDs. Opioid are very effective in pain control but has highest abuse potential due to addiction. Tapentadol is centrally acting opioid analgesic and has dual mode of action as agonist of μ -opioid receptor and as norepinephrine reuptake inhibitor (NRI). In India, unlike tramadol, packaging of multiple brands of tapentadol do not indicate that it is schedule H1 or X drug and thus they remain available over the counter. (2)

The etiopathogenesis of tissue necrosis with opioid abuse are unknown. Most common theory is injury might be due to immune reaction. Lymphocytes and macrophages are known to possess opioid receptors. Opioid drugs may exert immunosuppressive effects through the inhibition of cell mediated immunity,



allowing for the development of invasive bacterial or fungal infections (3).

Intranasal drug administration is well tolerated, non-invasive transmucosal route that avoid first pass metabolism in the liver. Nasal mucosa is highly vascularised with pseudo stratified ciliated epithelium. (4) Intranasal administration of drug has rapid onset of action (5). Mucosal damage is a most common effect of chemical injury induced by intranasal drug.

Case presented here shows classic signs and symptoms of opioid abuse with distinct psychological and physical manifestations. The possibility existed of continued drug abuse by the patient deters clinician to plan definitive treatment sans psychiatrist consult.

This case report presents a rare case of nasal and palatal defect due to drug abuse which should help clinician to be aware about etiopathogenesis and diagnosis.

4. Conclusion-

Use of addictive drugs like opioid through nasal spray mode of deliver without supervision in patients with chronic pain may be detrimental to psychological and physical health of patient. Awareness regarding same will be useful for both patients and clinicians.

5. Conflict of interest- None.

References

1. Raja SN, et al, The revised international association for the study of pain definition of pain: concepts, challenges and compromise, sept. 2020, pain 161(9):1976-1982.
2. Mukherjee D et al, Tapentadol abuse and dependence in india, Asian journal of Psychiatry, March 2020,49:101978.
3. Carr DJ, Rogers TJ, Weber RJ. The relevance of opioids and opioid receptors on immunocompetence and immune homeostasis. Proc Soc Exp Biol Med 1996;213:248-57.
4. Anez Simon C, Rull Bartomru, Rodriguez Perez, Intranasal opioid for acute pain, Rev Esp Anesthesiol Reanim, 2006, Dec; 53(10):643-52.
5. O. Dale, R. Hjortkjær And E. D. Kharasch Nasal administration of opioids for pain management in adults Acta Anaesthesiol Scand 2002; 46: 759–770]