



A Non-invasive Radiographic Method for Measurement of Interdental Papilla Height & its Correlation with the Distance between Contact Point & Bone Crest: A Pilot Study

Pallavi Sharma¹, Prateek Agrawal², Alankrita Chaudhary¹, Sheetal Sanikop³, Vilas Pattar⁴

¹. School of Dental Sciences, Sharda University, Greater Noida

². Private Practitioner, Dr. Anil Agrawal Dental Specialty Centre, Agra

³. Maratha Mandala Dental College, Belgaum

⁴. KLE VK Institute of Dental Sciences, Belgaum

(Received: 14 April 2024

Revised: 01 May 2024

Accepted: 18 June 2024)

KEYWORDS

Non-invasive radiographic method
Papilla height
Alveolar Bone Crest
Contact Point

ABSTRACT:

Introduction: Numerous surgical & non-surgical techniques have been established to achieve restoration of interdental papillae and to verify these papilla regeneration techniques, different methods of measuring the interdental papilla height have been proposed. Invasive methods like bone probing might cause discomfort to the patients and possibly damage the delicate gingival unit.

Objective: To validate a non-invasive method of measuring the interdental papilla height with radiovisiography (RVG) using a radiopaque material and to correlate the presence or absence of interproximal papilla with the distance between contact point and bone crest.

Methods: Study involved 109 sites in 35 patients diagnosed with chronic periodontitis scheduled for periodontal surgery. Radiographically, interdental papilla height was measured from the coronal part of bone crest to the radiopaque material placed on top of the papilla on RVG. Bone probing was performed prior to the surgery. The correlation analysis was performed between Radiographic length and Bone Probing Length. Also, the presence or absence of interproximal papilla was correlated with the distance between contact point and bone crest.

Result & Conclusion: RVG with a radiopaque material may be used for non-invasive measurement of interdental papilla height. Shorter the distance between the contact point to bone crest, more likely interdental papillae are present.

1. Introduction

The present era has witnessed a rapid increase in demand of aesthesia in dentistry. The aesthetic standards require restoration of the periodontal apparatus and teeth with a symmetrical gingival outline and an intact papilla especially in the interdental area of the maxillary anterior teeth [1,2].

The interdental area is comprised of the contact area, the interproximal embrasure, and the interdental gingiva/papilla [3].

Various factors that determine the shape of the interdental papilla includes the contact relationships between the teeth, the width of the approximal tooth

surfaces and the course of the cemento-enamel junction (CEJ) [4].

The availability of underlying osseous support is a determining factor that influence the presence of interdental papilla. The distance from the base of the contact area to the crest of bone is correlated with the presence or absence of the interproximal papilla (Tarnow 1992) [5].

The loss of interdental papilla can lead to open gingival embrasures or black triangles eventually resulting in aesthetic impairment, retention of food and phonetic problems [6].



Numerous surgical and nonsurgical methods have developed to provide optimal interdental papilla reconstruction. For verification of the results different methods to measure the length of the papilla have been established. Some methods include the use of clinical photographs (Olsson, Lindhe, Marinello 1992), some used an index for evaluating the contour of the proximal papillae (Jemt 1997, Nemcovsky 2000) and others measured papilla using a transgingival sounding under local anaesthesia (Tarnow, Fletcher 1992, Grunder 2000). The clinical photographs and index relied on subjective examination and could not evaluate the relationship of crestal bone and interdental papilla, and bone probing was an invasive technique which might cause patient discomfort and conceivably injure the delicate gingival unit, especially after regenerative surgical procedures [1].

Radiographic evaluation is a valuable and non-invasive assessment technique widely used in dentistry. Thus, the purpose of the present study was to validate a non-invasive method of measuring the interdental papilla height with radiovisiography (RVG) using a radiopaque material and to correlate the presence or absence of interproximal papilla with the distance between contact point and bone crest.

2. Methods

The study was conducted over a period of nine months. The Institutional Ethics Committee, KLE University, Belgaum, India, approved the study and a written informed consent was obtained from all participants prior to start of the study. The study was conducted in full accordance with ethical principles for research involving human subjects outlined in the World Medical Association Declaration of Helsinki.

Thirty-five patients (Nineteen males, sixteen females; aged 35 to 55 years), reporting to the outpatient section of the Department of Periodontology, KLE VK Institute of Dental Sciences, KLE University with well-aligned maxillary anterior teeth, diagnosed with moderate chronic periodontitis and scheduled for periodontal surgery were selected for this study. According to the case definition by the Centres for Disease Control and Prevention criteria, American Academy of Periodontology, moderate periodontitis was defined as ≥ 2 interproximal site with probing depth ≥ 5 mm or ≥ 2

interproximal sites with clinical attachment loss ≥ 4 mm not on the same tooth [7].

Participants with < 20 permanent teeth remaining, with a history of periodontal surgery in the anterior maxillary region within 6 months or maxillary central incisors with visibly open contacts, prosthesis, proximal or cervical abrasion or restorations, orthodontic appliances or hopeless teeth were excluded from the study. Participants with systemic diseases and conditions, or history of taking medications known to affect gingival hyperplasia or the periodontal soft tissue, smokers as well as pregnant and lactating females were excluded from the study

Demographic characteristics, such as age, gender, dental and medical history, were recorded. All the patients underwent initial therapy including oral hygiene instruction and ultrasonic scaling of the entire dentition. Patients with residual plaque accumulation were excluded and re-instructed on appropriate oral hygiene. Thus, patients included in this study were devoid of supragingival plaque accumulation. The tested sites were confined to the anterior maxillary teeth. A trained periodontist made all observation and measurements.

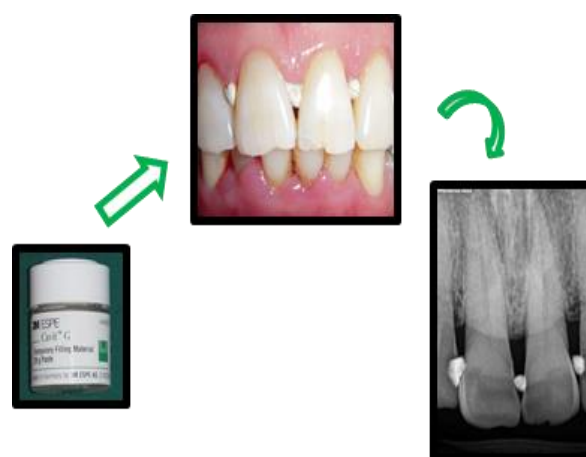


Fig 1. Application of radiopaque material (temporary filling material) on top of the interdental papilla.

If no space was visible apical to the contact area, the papilla was recorded as being present. If a space was visible apical to the contact area, it was recorded as papilla absent. To measure the radiographic papilla height, minimal amounts radiopaque temporary filling material (3M™ Cavit™), was gently placed on the top of the papilla with the help of a probe (Fig. 1). Care was taken not to push the radiopaque material apically.



Digital radiographs were obtained using a paralleling technique with radiovisiography (RVG) imaging system using film holders. All measurements were made using the dental imaging software on the RVG.

The measurements made of the RVG were the Radiographic papilla height (PHr) – the length of a vertical line from the crest of the interdental bone to the apical margin of the temporary filling material was measures and Bone Crest – Contact Point (BCCPr) - length of a vertical line from the bone crest to the apical point of the contact area between the teeth (Fig. 2).

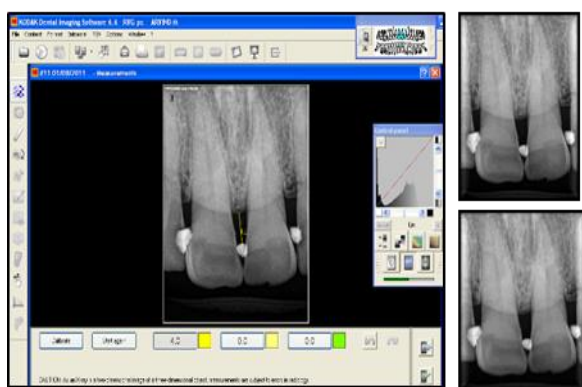


Fig 2. Radiographic measurement of Papilla Height and Bone Crest-Contact Point on RVG.

Prior to the scheduled periodontal surgery, after local anaesthesia, bone sounding was done to record the deepest depth at which the probe met strong resistance from the top of the papilla (PH) and from the contact point between the teeth (BCCP).

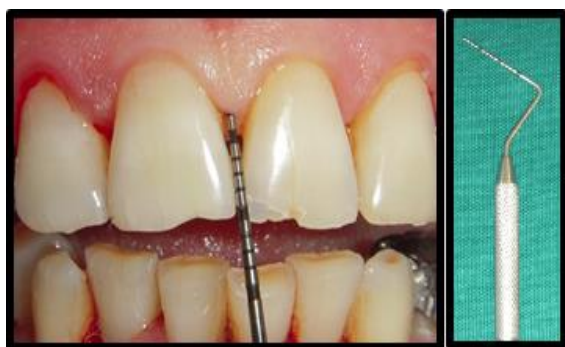

Fig 3. Clinical measurement of Papilla Height and Bone Crest-Contact Point on RVG.

All measurements were made using a graduated University of North Carolina-15 probe and were rounded off to the nearest 0.5 mm (Fig. 3).

3. Results

In total, 109 interproximal papillae in thirty-five patients were investigated in this study. The mean age of the participants were 39.62 ± 2.18 years. The mean radiographic papilla height (PHr) was 4.91 ± 1.42 mm, and the mean bone probing papilla height (PH) was 4.78 ± 1.37 mm. There was no statistically significant difference between the two measurements ($p > 0.05$). The correlation coefficient between PHr and PH was 0.956, showing statistically significant correlation between the two measurements ($p < 0.001$). (Table 1)

Table 1. Mean value \pm SD for interdental papilla height (Actual and RVG) and bone crest- contact point (Actual and RVG) (in mm).

*Non-Significant difference in the measurement between BPH & BPHr and between BCCP & BCCPr

**Correlation is highly significant at the $P < 0.001$ level (2-tailed), Pearson’s correlation.

BPH	PHr	P Value	γ (BPH: PHr)
4.8 ± 1.4	4.9 ± 1.4	0.56*	0.956**
BCCP	BCCPr	-	γ (BCCP: BCCPr)
6.4 ± 1.8	6.6 ± 1.7	0.70*	0.994**

The mean distance between the Bone Crest to Contact Point (BCCPr) on RVG was 6.56 ± 1.78 mm, and on bone probing (BCCP) was 6.38 ± 1.80 mm. There was no statistically significant difference between the two measurements ($p > 0.05$). The correlation coefficient between BCCPr and BCCP was 0.994, showing statistically significant correlation between the two measurements ($p < 0.001$) (Table 1).



For the correlation between the incidence of papillary presence or absence with the distance between the contact point and the crest of bone, the measurements were rounded off to the nearest mm. The results are summarised in Table 2.

BC-CP Distance (in mm)	Papillary Presence (%)	
	Yes	No
3	100	0
4	100	0
5	93	7
6	43	57
7	17	83
8	11	89
9	0	100
10	0	100

When the mean distance between the Bone Crest to Contact Point was 3-4mm the papilla was present 100% of the time, with 5mm distance the incidence of papillary presence was 93%. As the distance between the contact point and the crest of bone increased, the incidence of papillary presence decrease, with papilla being absent 100% of the time with 9-10 mm of the distance.

4. Discussion

The complete or partial loss of the interdental papilla leads to aesthetic and functional impairment in individuals, affecting societal relationships. Various surgical, non-surgical and minimally invasive techniques have been used for reconstruction of the lost papillae [8,9].

Bone probing is a valid method for reporting the interdental papilla height, however it is an invasive method which requires administration of local anaesthesia may cause pain and discomfort to the patient, plausibly damaging the delicate gingival unit especially post-surgery.

Radiography is a non-invasive valuable diagnostic technique used extensively in dentistry, however due to

its inherent penetration in soft tissues, it's diagnostic efficacy in the measurement of the interdental papilla height is lessened.

The detection of both hard and soft tissue in a single radiograph was made possible by using a radiopaque object [1].

The study demonstrated statistically significant correlation between the clinical measurements and the measurements on the RVG. Thus, the study establishes that interdental papilla height can be measured non-invasively by using a radiopaque material in the RVG.

Also, our study corroborated the findings of Tarnow and Fletcher, 1992, which mentions as the distance between the bone crest and the contact point increases, the incidence of the interdental papilla presence decreases.

The proposed method in the study is non-invasive, acceptable to the patient, accurate and reliable, can also help in the prognosis of methods used for regeneration of papilla and can be used in implant dentistry.

Thus, this study helps to conclude that RVG with a radiopaque material can be used for non-invasive measurement of interdental papilla height and shorter the distance between the contact point to bone crest, more likely interdental papillae are present.

References

1. Lee DW, Kim CK, Park KH, Cho KS, Moon IS. Non-invasive method to measure the length of soft tissue from the top of the papilla to the crestal bone. *J Periodontol* 2005; 76(8): 1311-4.
2. Chang LC. Assessment of parameters affecting the presence of the central papilla using a non-invasive radiographic method. *J Periodontol* 2008; 79(4): 603-9.
3. Takei HH. The interdental space. *Dent Clin North Am* 1980; 24: 169-76.
4. Lindhe J, Karring T. Anatomy of the periodontium. In: Lindhe J, Karring T, Lang NP, eds. *Clinical Periodontology and Implant Dentistry*, 3rd ed. Copenhagen: Munksgaard; 1998: 19-68.
5. Wahi S, Chhina K, Chhabra V, Bhatnagar R. Invasive versus non-invasive method of assessment of distance between the tip of papilla to the crest of interdental bone. *Eur J Gen Dent* 2013; 2: 37-41



-
6. Tanwar N, Narula SC, Sharma RK, Tewari S. Papillary Height and its Relation with Interproximal Distances and Cementoenamel Junction in Subjects with Chronic Periodontitis. A Cross-Sectional Study. *J Clin Diagn Res* 2016; 10(4): ZC53-6
 7. Page RC, Eke PI. Case definitions for use in population-based surveillance of periodontitis. *J Periodontol* 2007; 78 (7 Suppl): 1387-99
 8. Castro-Calderón A, Rocuzzo A, Ferrillo M, Gada S, González-Serrano J, Fonseca M, Molinero-Mourelle P. Hyaluronic acid injection to restore the lost interproximal papilla: a systematic review. *Acta Odontol Scand* 2022; 80(4): 295-307
 9. Chen MC, Liao YF, Chan CP, Ku YC, Pan WL, Tu YK. Factors influencing the presence of interproximal dental papillae between maxillary anterior teeth. *J Periodontol* 2010; 81(2): 318-24