



Perception of Orthodontists, General Dentists and Laypersons to Altered Dental Esthetics by Substitution of Impacted Maxillary Canines: A Photographic Study

Dr. F Lalhmangaihsangi¹, Dr. Dinesh Kumar Bagga², Dr. Poonam Agrawal^{3*}, Dr. Sameer Ahmad⁴, Dr. Nishtha Yadav⁵, Dr. Sweta Sharma⁶

¹MDS 3rd Year School of Dental Sciences, Sharda University, Knowledge park-III Greater Noida U.P.- 201310

²Professor and Head, School of Dental Sciences, Sharda University, Knowledge park-III Greater Noida U.P.- 201310

³Professor, School of dental sciences, Sharda University Knowledge park-III Greater Noida U.P.- 201310

⁴Private Practitioner

⁵MDS 2nd Year School of Dental Sciences, Sharda University, Knowledge park-III Greater Noida U.P.- 201310

⁶MDS 1st Year School of Dental Sciences, Sharda University, Knowledge park-III Greater Noida U.P.- 201310

*Corresponding Author: **Dr. Poonam Agrawal**

(Received: 14 April 2024

Revised: 1 May 2024

Accepted: 18 June 2024)

KEYWORDS

Orthodontists,
Impacted
Maxillary

ABSTRACT:

Aims and Objectives: To evaluate the potential post-orthodontic smile aesthetics of the aligned canine/prosthetic replacement, substituted premolars, deciduous canines as a treatment options for impacted maxillary canines as perceived by Orthodontists, General Dentists and Laypersons. and to make comparative analysis between the groups.

Design: A Cross Sectional Study

Materials and Methods: A study involving 153 raters from three groups (Orthodontists, General Dentists, and Laypersons) assessed smile attractiveness using six digitally manipulated images representing various treatments for impacted maxillary canines: prosthetic replacement, substituted premolars, retained deciduous canines, and different combinations thereof. Each group of raters (n=51, 25 males and 26 females) evaluated the images randomly and rated them using a Visual Analog Scale (VAS) for attractiveness. Statistical analysis used one-way ANOVA for pairwise comparisons of mean VAS scores, with a significance level set at $P < 0.05$.

Results and Conclusions: Orthodontists, General Dentists, and Laypersons showed consistent perceptions of smile attractiveness in cases where canines were unilaterally aligned with either substituted first premolars or retained deciduous canines. This consistency in perception was evident across various treatment scenarios, including prosthetic canine replacement on both sides, bilateral premolar substitution, bilateral retention of deciduous canines, and unilateral treatments like retaining a deciduous canine on one side and substituting a premolar on the other, or aligning a canine on one side while either substituting a premolar or retaining a deciduous canine on the opposite side.

Introduction: The maxillary canine, often termed the "Cornerstone" of the upper dental arch, occupies its corners and stands out as the longest tooth in this region. Wheeler emphasized their pivotal role in maintaining natural facial expressions, highlighting their dual importance—both aesthetically and functionally due to

their lengthy root, which is the longest among human teeth. Impaction of the maxillary canine is common, with prevalence rates ranging from 0.2% to 2.8%, making it the second most frequently impacted tooth after third molars.



In cases of impacted canines, which can disrupt dental alignment and smile aesthetics, various treatment options such as orthodontic procedures, exposure and bonding, surgical extraction and replacement, and orthognathic surgery are essential to explore. Each case is unique, emphasizing the necessity for patients to consult skilled dental professionals to devise personalized treatment plans that best meet their specific needs and desires for enhancing smile aesthetics. Therefore, this study aimed to evaluate changes in perceived smile aesthetics resulting from orthodontic treatments for impacted maxillary canines, assessed by Orthodontists, General Dentists, and Laypersons within the North Indian population.

Materials And Methods: This study, conducted at the Department of Orthodontics and Dentofacial Orthopaedics, School of Dental Sciences, Sharda University, involved 153 participants seeking orthodontic treatment at the Dental Hospital. Participants were randomly assigned to three groups: Orthodontists, General Dentists, and Laypersons, with each group comprising 26 males and 26 females. They were tasked with evaluating smile attractiveness.

GROUP I: 51 Orthodontists, including hospital consultants and specialist Orthodontic practitioners listed on the Indian Dental Council specialist registry.

GROUP II: 51 General Dentists, including hospital consultants and specialist Orthodontic practitioners listed on the Indian Dental Council specialist registry.

GROUP III: 51 Laypersons selected from patients and guardians visiting the Dental Hospital for dental treatment in Greater Noida, reflecting the North Indian population aged between 13 and 40 years.

A photographic image (post treatment) of the patient with natural and attractive smile were taken using Digital SLR camera.

The images were cropped displaying only the lip, teeth and gingiva and was digitally manipulated using computer software (Adobe Photoshop software) to imitate 6 different treatment options for impacted maxillary canines including-

Prosthetic replacement of the impacted maxillary canine

Substituted premolars on both side

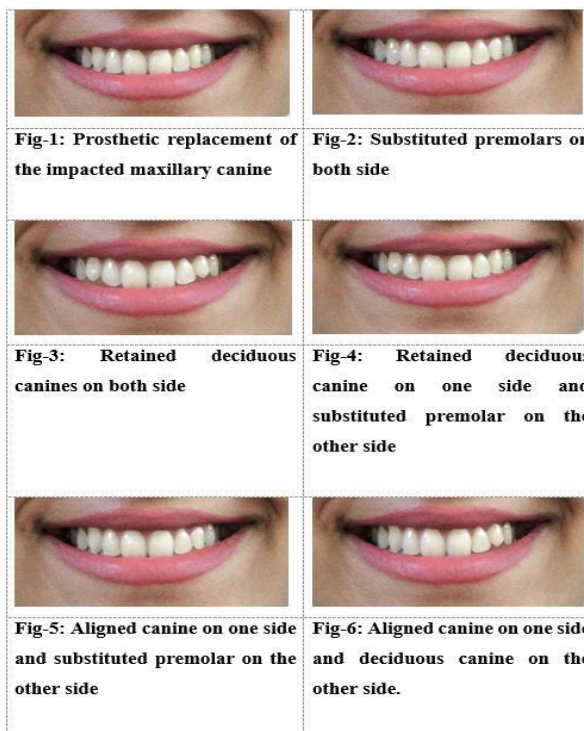
Retained deciduous canines on both side

Retained deciduous canine on one side and substituted premolar on the other side

Aligned canine on one side and substituted premolar on the other side

Aligned canine on one side and deciduous canine on the other side.

Raters were divided into three groups: Group 1 (n=51, 25 males, 26 females). They viewed images on an HP 13.5-inch laptop in widescreen mode using a PowerPoint presentation. Each image (13.33 x 7.5 inches) was displayed for 10 seconds in random order. Raters used the page down button to navigate and rated smile attractiveness using a 100 mm Visual Analog Scale (VAS) labeled 'VERY UNATTRACTIVE' on the left to 'VERY ATTRACTIVE' on the right. Each participant marked the scale according to their perception. An assessment sheet was provided for recording scores. Perception of smile aesthetics was quantitatively measured by the distance from the left end of the VAS to the mark using a Digital Caliper. Pilot data was analyzed using a mixed-effects model in SPSS, starting from a Microsoft Excel spreadsheet.





Inclusion Criteria: The baseline photographic image where the impacted canine had been aligned

Ideal smile aesthetics and a class I occlusion obtained at the end of the treatment.

Cropped baseline photograph which display only the teeth, gingiva and lip.

Digitally manipulated images with symmetrical right and left photographic images

Results: Questionnaires were collected from 153 participants, divided evenly among three groups:

Orthodontists, General Dentists, and Laypersons, with each group comprising 51 individuals.

Table 1-12 displays descriptive statistics, including the average Visual Analog Scale (VAS) scores, for each treatment option within each group. Additionally, one-way analysis of variance (ANOVA) was employed to compare mean VAS scores across treatment groups and raters. A significance level of $P < 0.05$ indicated statistical significance.

Table1. Mean, median and mode of Visual Analog Scale scores perceived by three groups for potential post-orthodontic smile aesthetics of Prosthetic canine replacement on both side

	Mean	Std. Deviation	Median	Mode	95% Confidence Interval for Mean		F value	p value
					Lower Bound	Upper Bound		
Lay Person	4.19	0.91	4.0	4.0	3.939	4.445	18.480	<0.01*
General Dentist	3.60	0.87	4.0	4.0	3.354	3.838		
Orthodontist	4.56	0.64	5.0	5.0	4.380	4.736		

Table2. Pair wise comparison of mean VAS scores perceived by three groups for potential post-orthodontic smile aesthetics of Prosthetic replacement on both side

Groups	Mean Difference	p value	
Lay person	General Dentist	-0.5	.001
Lay person	Orthodontist	.04	.060
General Dentist	Orthodontist	0.9	.000

Table3. Mean, median and mode of VAS scores perceived by three groups for potential post-orthodontic smile aesthetics of Substituted Premolar on both side

	Mean	Std. Deviation	Median	Mode	95% Confidence Interval for Mean		F value	p value
					Lower Bound	Upper Bound		
Lay Person	3.96	0.93	4.0	4.0	3.703	4.220	14.798	<0.01*
General Dentist	3.92	0.74	4.0	4.0	3.718	4.128		
Orthodontist	3.06	1.16	3.0	4.0	2.734	3.381		



Table4. Pair wise comparison of mean VAS scores perceived by three groups for potential post-orthodontic smile aesthetics of Substituted Premolar on both side

Groups		Mean Difference	p value
Lay person	General Dentist	0.38	.001
Lay person	Orthodontist	0.90	.060
Orthodontist	Orthodontist	-0.86	.000

Table5. Mean, median and mode of VAS scores perceived by three groups for potential post-orthodontic smile aesthetics of Retained Deciduous Canine on both side

	Mean	Std. Deviation	Median	Mode	95% Confidence Interval for Mean		F value	p value
					Lower Bound	Upper Bound		
Lay Person	3.17	1.00	3.0	3.0	2.893	3.453	6.852	0.01*
General Dentist	3.23	1.23	3.0	4.0	2.888	3.573		
Orthodontist	2.50	1.11	2.0	2.0	2.191	2.809		

Table6. Pair wise comparison of mean VAS scores perceived by three groups for potential post-orthodontic smile aesthetics of Retained Deciduous Canine on both side

Groups		Mean Difference	p value
Lay person	General Dentist	0.06	.963
Lay person	Orthodontist	-0.67	.007
General Dentist	Orthodontist	-0.73	.003

Table7. Mean, median and mode VAS scores perceived by three groups for potential post-orthodontic smile aesthetics of Retained Deciduous Canine. and Substituted Premolar.

	Mean	Std. Deviation	Median	Mode	95% Confidence Interval for Mean		F value	p value
					Lower Bound	Upper Bound		
Lay Person	3.69	0.96	4.0	4.0	3.425	3.960	4.911	0.009*
General Dentist	3.17	1.00	3.0	3.0	2.893	3.453		
Orthodontist	3.69	0.96	4.0	4.0	3.425	3.960		



Table8. Pair wise comparison of mean VAS scores perceived by three groups for potential post-orthodontic smile aesthetics of Retained Deciduous Canine and Substituted Premolar.

Groups		Mean Difference	p value
Lay person	General Dentist	-0.52	.020
Lay person	Orthodontist	0	1.000
General Dentist	Orthodontist	0.52	.020

Table9. Mean, median and mode of VAS scores perceived by three groups for potential post-orthodontic smile aesthetics of Aligned Canine Substituted Premolar.

	Mean	Std. Deviation	Median	Mode	95% Confidence Interval for Mean		F value	p value
					Lower Bound	Upper Bound		
Lay Person	3.83	0.86	4.0	4.0	3.588	4.065	0.010	0.990
General Dentist	3.81	0.66	4.0	4.0	3.625	3.991		
Orthodontist	3.83	0.86	4.0	4.0	3.588	4.065		

Table10. Pair wise comparison of mean VAS scores perceived by three groups for potential post-orthodontic smile aesthetics of Aligned Canine Substituted Premolar.

Groups		Mean Difference	p value
Lay person	General Dentist	0.19	.020
Lay person	Orthodontist	0.00	1.000
General Dentist	Orthodontist	0.19	.020

Table11. Mean, median and mode VAS scores perceived by three groups for potential post-orthodontic smile aesthetics of Aligned Canine and Retained Deciduous Canine.

	Mean	Std. Deviation	Median	Mode	95% Confidence Interval for Mean		F value	p value
					Lower Bound	Upper Bound		
Lay Person	3.87	0.99	4.0	4.0	3.590	4.141	0.771	0.464
General Dentist	3.65	1.03	4.0	4.0	3.368	3.940		
Orthodontist	3.87	0.99	4.0	4.0	3.590	4.141		



Table 12. Pair wise comparison of mean VAS scores perceived by three groups for potential post-orthodontic smile aesthetics of Aligned Canine and Retained Deciduous Canine.

Groups		Mean Difference	p value
Lay person	General Dentist	0.21	.020
Lay person	Orthodontist	0.00	1.000
General Dentist	Orthodontist	0.21	.020

Discussion: Smile aesthetics are crucial for patients and orthodontists, influencing orthodontic care seeking behaviors (Thiruvengkatachari et al)²³ Defining the "ideal smile" is complex due to its variability across cultures, ages, and individuals. The prevalence of impacted canines ranges from 0.2% to 2.8%, with a higher incidence in females than males (Seager et al.,)¹

Shaw's study³⁰ highlights significant variability in patient satisfaction criteria, crucial for treatment planning, especially with multiple options available.

In Rosa et al.'s study²⁵, only computer-simulated ideal smile images were used. Our study, however, used digitally altered images of actual teeth, focusing on the canine region. This approach enhances validity over purely computer-generated images and standardizes real-life variables that may affect perceptions of smile attractiveness.

This study aimed to evaluate aesthetic outcomes of post-orthodontic treatments for impacted maxillary canines as judged by orthodontists, general dentists, and laypersons. Images were digitally altered using Adobe Photoshop to simulate six treatments:

Prosthetic canine replacement

Premolar substitution on both sides

Retention of deciduous canines on both sides

Retention of a deciduous canine on one side and premolar substitution on the other

Alignment of a canine on one side with premolar substitution on the other

Alignment of a canine on one side with retention of a deciduous canine on the other

Participants rated these treatments using a Visual Analog Scale (VAS), providing continuous ratings rather than categorical choices. VAS scales are known for reliability in epidemiological studies (Howells and Shaw)³¹

When assessing smile aesthetics after treatment with Retained Deciduous Canines on one side and Substituted Premolars on the other, Orthodontists and Laypersons rated significantly higher than General Dentists. Aligning Canines on one side with Substituted Premolars showed no significant differences among raters. Similarly, for Aligned Canines with Retained Deciduous Canines, all groups had identical ratings.

For Prosthetic Replacement on both sides, Orthodontists rated higher than General Dentists and Laypersons, who rated it 'attractive.' Orthodontists' ratings significantly differed. Other studies noted dental professionals' critical viewpoints^{5,9,15,16}

Substituted premolars on both sides were rated similarly high by all groups, with no significant differences, consistent with Seager et al¹ Thiruvengkatachari et al.²³ found differences between orthodontists and general dentists.

For Retaining Deciduous Canines on both sides, significant differences were noted: General Dentists found it 'attractive,' Laypersons 'neither attractive nor unattractive,' and Orthodontists 'unattractive.' Familiarity with close-up tooth examination influenced perceptions (Thiruvengkatachari et al.)²³

Retaining a deciduous canine on one side and substituting a premolar on the other was rated 'attractive' by orthodontists and laypersons but 'neither attractive nor unattractive' by general dentists.

No significant differences were found in smile aesthetics between treatments like aligning a canine with either a



substituted premolar or a retained deciduous canine on the opposite side. Thiruvengkatahari et al.²³ reported similar findings with asymmetric images.

Across different treatments—bilateral prosthetic canine replacement, bilateral premolar substitution, bilateral retention of deciduous canines, and unilateral options—perceived smile attractiveness was consistent among Orthodontists, General Dentists, and Laypersons. Kokich et al.¹⁴ highlighted symmetry's importance in smile aesthetics, noting perceptions of asymmetry as less attractive.

Critical Appraisal: The study did not document the ethnic backgrounds of the raters, potentially affecting how broadly applicable the results may be. Additionally, there is a risk that some respondents may have disregarded parts of the VAS scale or assessed it inconsistently, potentially leading to misinterpretations of perceived attractiveness.

Another limitation is that the study solely relied on frontal views of smiles, which may restrict the comprehensiveness of the findings.

Conclusion: From this study, the following conclusions were drawn:

1. Prosthetic replacement of canines on both sides was rated 'very attractive' by orthodontists, while general dentists and laypersons rated it as 'attractive' based on median VAS scores.
2. Substituting premolars on both sides was unanimously rated as "attractive" by orthodontists, general dentists, and laypersons, with consistent scores on the VAS.
3. Retaining deciduous canines on both sides showed varying perceptions among raters: General dentists rated it 'attractive', laypersons rated it 'neither attractive nor unattractive', and orthodontists rated it 'unattractive' based on median VAS scores.
4. Retaining a deciduous canine on one side and substituting a premolar on the other was rated 'attractive' by orthodontists and laypersons, but 'neither attractive nor unattractive' by general dentists, according to median VAS scores.
5. Aligning a canine on one side and either substituting a premolar or retaining a deciduous canine on the other

side received similar 'attractive' ratings across all three groups based on median VAS scores.

6. Orthodontists generally rated all treatment options favourably (either 'very attractive' or 'attractive'), except for retaining deciduous canines on both sides, which they found 'unattractive' based on median VAS scores.

7. General dentists and laypersons mostly agreed on treatment options, except for cases involving retaining a deciduous canine on one side and substituting a premolar on the other. Here, general dentists rated it 'neither attractive nor unattractive' while laypersons rated it 'attractive'. Laypersons rated retaining deciduous canines on both sides as 'neither attractive nor unattractive', whereas general dentists' rating was less negative.

8. Unilateral cases with an aligned canine and either a substituted premolar or a retained deciduous canine were consistently rated as 'attractive' by all raters.

9. In different treatment scenarios—like replacing both canines prosthetically, substituting premolars bilaterally, retaining deciduous canines bilaterally, and unilateral cases such as retaining a deciduous canine on one side and substituting a premolar on the other, or aligning one canine while substituting a premolar or retaining a deciduous canine on the opposite side—there were no notable variations in perceived smile attractiveness across orthodontists, general dentists, and laypersons.

References:

1. Leonie Seager, Jinesh Shah, Trevor Burke and Balvinder Khambay (2021) Smile aesthetic perception among dental professionals, patients and parents towards impacted maxillary canine treatment options. *Journal of Orthodontics*.48 (3):250-259
2. Altman J, Arnold H and Spector P (1979) Substituting maxillary first premolars for maxillary impacted canines in cases requiring the extraction of dental units as part of orthodontic correction. *American Journal of Orthodontics* 75: 618 629.
3. Becker A and Chaushu S (2015) Etiology of maxillary canine impaction: A review. *American Journal of Orthodontics and Dentofacial Orthopaedics* 148: 557–567
4. Cooper G, Tredwin C, Cooper N, Petrie A and Gill D (2012) the influence of maxillary central incisor



- height-to-width ratio on perceived smile aesthetics. *British Dental Journal* 212: 589–599.
5. Correa B, Bittencourt V and Machado A (2014) Influence of maxillary canine gingival margin asymmetries on the perception of smile aesthetics among orthodontists and laypersons. *American Journal of Orthodontics and Dentofacial Orthopaedics* 145: 55–63.
 6. Cotrim E, Vasconcelos J, Haddad A and Reis A (2015) Perception of adults' smile aesthetics among orthodontists, clinicians and laypeople. *Dental Press Journal of Orthodontics* 20: 40–44
 7. Figueiredo B, Ribeiro J and Machado AW (2020) Does the presence of unilateral gingival recession on maxillary canines influence smile esthetics? *Dental Press Journal of Orthodontics* 25: 56–63.
 8. Foulger T, Tredwin C, Gill D and Moles R (2010) the influence of varying maxillary incisal edge embrasure space and interproximal contact area dimensions on perceived smile aesthetics. *British Dental Journal* 209: E4
 9. Hussain A, Louca C, Leung A and Sharma P (2016) the influence of varying maxillary incisor shape on perceived smile aesthetics. *Journal of Dentistry* 50: 12–20.
 10. Ioi H, Kang S, Shimomura T, Kim SS, Park SB, Son WS, et al. (2013) Effects of vertical positions of anterior teeth on smile esthetics in Japanese and Korean orthodontists and orthodontic patients. *Journal of Esthetic and Restorative Dentistry* 25: 274–282
 11. Heravi F, Rashed R and Abachizadeh H (2011) Esthetic preferences for the shape of anterior teeth in a posed smile. *American Journal of Orthodontics and Dentofacial Orthopedics* 139: 806–814.
 12. Johnston C, Burden D and Stevenson M (1999) the influence of dental to facial midline discrepancies on dental attractiveness ratings. *European Journal of Orthodontics* 21: 517–522.
 13. Kaya B and Uyar R (2016) the impact of occlusal plane can't along with gingival display on smile attractiveness. *Orthodontics and Craniofacial Research* 19: 93–101.
 14. Kokich V, Kokich V and Kiyak H (2006) Perceptions of dental professionals and laypersons to altered dental esthetics: Asymmetric and symmetric situations. *American Journal of Orthodontics and Dentofacial Orthopaedics* 130: 141–151.
 15. Kokich V, Kiyak H and Shapiro P (1999) Comparing the perception of dentists and lay people to altered dental esthetics. *Journal of Esthetic Dentistry* 11: 311–324
 16. Machado A, Moon W, Campos E and Gandini L (2013) Influence of spacing in the upper lateral incisor area on the perception of smile esthetics among orthodontists and laypersons. *Journal of the World Federation of Orthodontists* 2: 169–174.
 17. Machado R, Assad Duarte M, Jardim da Motta A, Mucha J and Motta A (2016) Variations between maxillary central and lateral incisal edges and smile attractiveness. *American Journal of Orthodontics and Dentofacial Orthopaedics* 150: 425–435.
 18. Mirabella D, Giunta G and Lombardo L (2013) Substitution of impacted canines by maxillary first premolars: a valid alternative to traditional orthodontic treatment. *American Journal of Orthodontics and Dentofacial Orthopedics* 143: 125–133
 19. Nascimento D, Santos E, Machado A and Bittencourt M (2012) Influence of buccal corridor dimension on smile esthetics. *Dental Press Journal of Orthodontics* 17: 45–50.
 20. Nomura M, Motegi E, Hatch J, Gakunga P, Ng'ang'a P, Rugh J, et al. (2009) Esthetic preferences of European American, Hispanic American, Japanese, and African judges for soft-tissue profiles. *American Journal of Orthodontics and Dentofacial Orthopaedics* 135: S87–95
 21. Parekh S, Fields H, Beck M and Rosentiel S (2006) Attractiveness of variations in the smile arc and buccal corridor space as judged by orthodontists and laymen. *Angle Orthodontist* 76: 557–563.
 22. Suzuki L, Machado A and Bittencourt M (2009) Perceptions of gingival display aesthetics among orthodontists, maxillofacial surgeons and laypersons. *Journal of Dental Science* 24: 367–371.
 23. Thiruvengkatachari B, Javidi H, Griffiths S, Shah A and Sandler J (2017) Extraction of maxillary canines: Esthetic perceptions of patient smiles among dental professionals and laypeople. *American Journal of Orthodontics and Dentofacial Orthopaedics* 152: 509–515.



24. Xu H, Han X, Wang Y, Shu R, Jing Y, Tian Y, et al. (2015) Effect of buccolingual inclinations of maxillary canines and premolars on perceived smile attractiveness. *American Journal of Orthodontics and Dentofacial Orthopedics* 147: 182–189.
25. Rosa M, Olimpo A, Fastuca R and Caprioglio A (2013) Perceptions of dental professions and laypeople to altered dental aesthetics in cases with congenitally missing maxillary lateral incisors. *Progress in Orthodontics* 14: 34.
26. Sadrhaghighi A, Zarghami A, Sadrhaghighi S, Mohammadi A and Eskandarinezhad M (2017) Esthetic preferences of laypersons of different cultures and races with regard to smile attractiveness. *Indian Journal of Dental Research* 28: 156–161.
27. Sampaziotis D, Tsolakis IA, Bitsanis E and Tsolakis AI (2017) Open versus closed surgical exposure of palatally impacted maxillary canines: Comparison of the different treatment outcomes—A systematic review. *European Journal of Orthodontics* 40: 11–22.
28. Paiva T, Machado RM, Motta AT and Mattos CT (2018) Influence of canine vertical position on smile esthetic perceptions by orthodontists and laypersons. *American Journal of Orthodontics and Dentofacial Orthopaedics* 153: 371–376
29. Sharma P and Sharma P (2012) Dental smile esthetics: The assessment and creation of the ideal smile. *Seminars in Orthodontics* 18:193–201.
30. Shaw W (1981) Factors influencing the desire for orthodontic treatment. *European Journal of Orthodontics* 3: 151–162.
31. Howells D and Shaw W (1985) The validity and reliability of ratings of dental and facial attractiveness for epidemiologic use. *American Journal of Orthodontics* 88: 402–408.