



Androgen Insensitivity Syndrome: A Case Report of Clinical Intricacies

Dr.R. Sahasra Serisha^{1*}, Dr. Ganesh Guru²

¹Department of general surgery , Sree balaji medical college and hospital ,chennai

²Department of general surgery , Sree balaji medical college and hospital ,chennai

Corresponding Author : Dr.R.Sahasra serisha

Email id: sahasraserisha25@gmail.com

(Received: 14 June 2024

Revised: 01 July 2024

Accepted: 18 August 2024)

KEYWORDS

Androgen ,
Feminization,
Insensitivity,
Testosterone

ABSTRACT:

Testicular Feminisation Syndrome, commonly termed as Androgen Insensitivity Syndrome (AIS), is a very uncommon genetic disorder. Although AIS patients are genetically male (46, XY), they may have all or some of the physical characteristics of females because of different X chromosome abnormalities. Resistance to androgen hormones causes the condition, which leads to the development of feminine traits. This report describes a 30-year-old woman who was diagnosed with total androgen insensitivity syndrome in addition to primary amenorrhea. To improve knowledge of AIS, we plan to include information from this case, an extensive literature analysis, and our study findings.

1. Introduction

Introduction:

Testicular Feminization Syndrome, commonly known as Androgen Insensitivity Syndrome (AIS), is a very uncommon genetic disorder. Although AIS patients are genetically male (46, XY), they may have all or some of the physical characteristics of females because of different X chromosome abnormalities. We hereby discuss this case of a 30-year-old woman whom was diagnosed with total androgen insensitivity syndrome in addition to primary amenorrhea. This report describes our treatment strategy and covers the case's clinical and pathological characteristics.

Clinical History & Findings:

The gynecology department accepted this 30-year-old woman, who had initial complaints of primary amenorrhea. A female phenotype with adequate breast development, underdeveloped labia, and with conspicuous lack of pubic hair & axillary hair was identified during the initial clinical evaluation. An intact hymen and a very tiny, 2 cm vaginal introitus were seen during a per-vaginal examination (Figure 1). The uterus was absent.

Progesterone was measured at 6.89 nmol/L, estradiol at 58 pmol/L, FSH at 6.64 mUI/ml, and LH at 26.65 mUI/ml, all of which were within normal ranges according to the

hormonal assessment. But at 58.61 ng/mL, testosterone was elevated—higher than normal for a female her age.

A male genotype (46, XY) was established by karyotype analysis. The lack of androgen receptors made more genetic anomaly research and an androgen binding-test on genital skin fibroblasts impractical. Intraabdominal testes, a hypo-plastic vagina, and the lack/absence of the uterus and b/l ovaries were all discovered during a pelvic MRI. The testes, which are found in the abdominal cavity, were then taken out and cut open (Figure 2). The testes' histopathological analysis revealed atrophic seminiferous tubules that solely contained Leydig and Sertoli cells.

Thankfully, there were no signs of testicular cancer found (Figure 3). Following surgery, the patient recovered without incident and was released the next day. Since the patient self-identified as female, it was necessary to proceed with caution while sharing the diagnosis. As a result, we set up a system of psychological help & support, she was directed to the department of endocrinology so that she could receive estrogen replacement therapy.

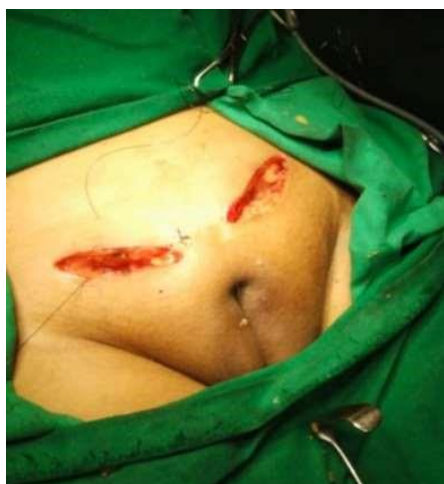

Figure 1: Showing clinical aspect of vagina

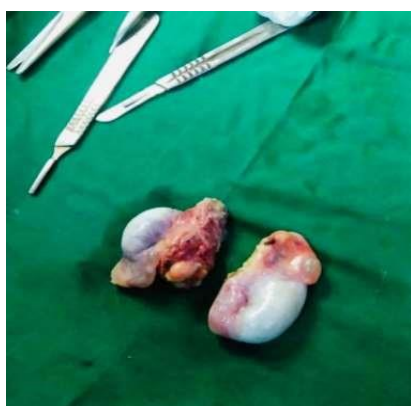

Figure 2: Showing excised non functional testis

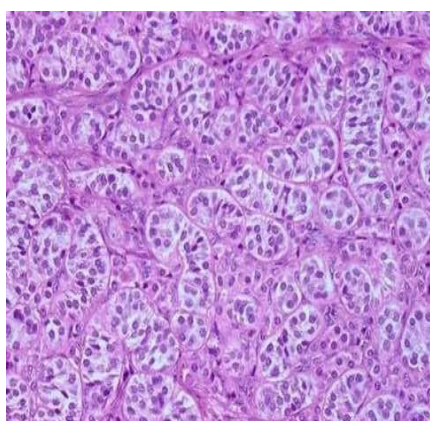


Figure 3: Testis shows seminiferous tubules with small abortive lumens with Sertoli cells only.

Discussion:

The SRY gene, on the Y chromosome is the main factor influencing the differentiation of male embryonic testes, which starts in the sixth week of development. Testicular

descent into the scrotum and other male sexual traits occur because by the end of the eighth week, Leydig cells begin to produce testosterone. The development of Müllerian ducts into the uterus & other Müllerian structures is inhibited by the Anti-Müllerian hormone which was secreted by Sertoli cells. Wolffian ducts, which regulate the male reproductive organs, degenerate and Müllerian ducts arise when gonadal hormone production is absent.

The Xq11-Xq12 region of the X chromosome encodes nuclear receptors unique to androgens, which are how testosterone works [1]. The androgen receptor protein has several functional sections, including the hinge region, transactivation domain, DNA-binding domain, and steroid-binding domain. Not all mutations lead to malfunctioning androgen receptors. When cells are unable to detect and use testosterone, the condition known as androgen insensitivity syndrome (AIS) develops [2].

Nevertheless, other uncommon reasons, such as mutations in the steroidogenic factor-1 protein or issues with the transactivation signal transfer from the androgen receptor's N-terminal region to the cell's basal transcription machinery, can also result in testicular feminization without the presence of an altered androgen receptor gene [3].

Complete AIS diagnosis is complicated, frequently confusing, and necessitates a number of unusual testing [4]. As in our instance, complete AIS is usually detected around puberty when primary amenorrhea is described, exhibiting a female phenotype. Though rare, it can occasionally be identified prenatally by amniotic fluid karyotyping and ultrasound confirmation of genetic sex. It is recommended to evaluate blood levels of different sex hormones after primary amenorrhea is identified. Increased testosterone levels may offer helpful hints for diagnosis. Diagnostic imaging methods like CT, MRI, and ultrasonography can corroborate clinical findings such as a small vagina and absence of uterus. In situations like ours, pelvic MRI can identify intra-abdominal undescended testes. To differentiate AIS from other genetic disorders including tetragametic chimerism (46XX/46XY), mixed gonadal dysgenesis (45XO/46XY), Klinefelter syndrome (46XXY), and Turner syndrome (45XO), karyotyping is necessary. Additionally, a mutant androgen receptor gene might exist [5].

Gender assignment is quite difficult, particularly when there is variable sexual ambiguity and partial androgen sensitivity. The majority of patients, like ours, continue to



identify as female, and complete AIS is uncommon [6]. Orchiectomy is advised in order to reduce the risk of cancer in un-descended intraabdominal testes (3.6% at age 25 and 33% at age 50, according to several studies) [7]. The laparoscopic method was chosen in our instance because of its low morbidity and minimally intrusive character. We were referred to the endocrinology department because hormone replacement therapy was recommended because the testes naturally make estrogens by aromatizing testosterone.

Whether to tell the patient about the entire pathology is the last issue to consider. Our patient, a heterosexual woman who self-identified, was not informed about the disease in order to avoid psychological anguish. She decided not to disclose her condition to her family as a result.

Since talking about sex is still frowned upon in Moroccan culture, the family did not offer psychological help. In order to assist our patient in managing the consequences of her disease, it was essential to provide her with the necessary psychological assistance [8].

Conclusion:

Gynecologists, endocrinologists, and psychologists need to collaborate closely in order to treat complete insensitivity syndrome androgen. Castration is necessary because gonad degeneration is a possibility. Estrogen replacement therapy is almost always used as part of a hormonal therapy to maintain normal sexual activity & to avoid the further regression of the secondary sexual traits & the effects of oestrogen deficiency. Finally, it is still essential to provide family-centered psychological care in collaboration with medical and psychiatric specialists.

Acknowledgement:

Without the involvement and support of several people, many of whose names may not be listed, this project would not have been able to be completed. We sincerely thank them for their contributions and acknowledge them.

REFERENCES:

1. Wilson, J.D., Griffin, J.E., Russell, D.W. (1993). Steroid 5 alpha-reductase 2 deficiency Endocrine Reviews, 14(5), 577-593.
2. Sultan, C., Lumbroso, S., Paris, F., et al. (1999). Disorders of androgen action. Seminars in Reproductive Medicine, 17(4), 207-218.
3. Sultan, C., Paris, F., Terouanne, B., et al. (2001). Disorders linked to insufficient androgen action in male children. Human Reproduction Update, 7(3), 314-322.
4. Hughes, I.A., Davies, J.D., Bunch, T.I., et al. (2012). Androgen insensitivity syndrome. The Lancet, 380(9851), 1419-1428.
5. Hiort, O. (2013). The differential diagnosis and treatment of androgen insensitivity syndrome. Pediatric Endocrinology Reviews, 10(2), 338-341.
6. Ahmed, S.F., Achermann, J.C., Arlt, W., et al. (2016). Society for Endocrinology UK guidance on the initial evaluation of a suspected difference or disorder of sex development (Revised 2015). Clinical Endocrinology, 84(5), 771-788.
7. Mouriquand, P.D., Gorduza, D.B., Gay, C.L., et al. (2016). Surgery in disorders of sex development (DSD) with a gender issue: If (why), when, and how? Journal of Pediatric Urology, 12(3), 139-149.
8. Schober, J., Meyer-Bahlburg, H.F., Ransley, P.G. (2004). Self-assessment of gender identity in children with genital anomalies. Journal of Urology, 171(4), 1691-1695.