



Skeletal Trauma Evaluation and its Implications in Forensic Anthropology: A Systematic Review

Ajmal Bin Latheef¹, Divya N Pai^{2*}

¹ Department of Forensic Medicine and Toxicology, K. S Hegde Medical Academy, NITTE (Deemed to be University), Mangalore, India

^{2*} Department of Anatomy, K.S Hegde Medical Academy, NITTE (Deemed to be University), Mangalore, India

(Received: 16 January 2025

Revised: 20 February 2025

Accepted: 31 March 2025)

KEYWORDS

Skeletal trauma,
forensic
anthropology,
injuries, tool,
medicolegal

ABSTRACT:

Introduction: To diagnose skeletal trauma is very important to understand the cause and time of death. The proofs obtained from the crime spot would help in the legal procedures. Forensic anthropology plays a substantial role in medico-legal investigations. Forensic anthropology uses a number of tools to evaluate the trauma and varieties of procedures followed to evaluate the skeletal trauma add on to the knowledge of different trauma patterns.

Methods: This systematic review focuses on bridging the research gap and further focus on the future advancements required for more investigations. This review was conducted using the published original article and systematic reviews. The key words used to obtain the articles from different database were 'skeletal trauma', 'trauma analysis', 'tool analysis' and 'techniques used in skeletal trauma analysis'.

Results: After a thorough literature search, a total of 36 articles were obtained. Only 12 articles were used for the present systematic review as it met the inclusion criteria.

Conclusions: This review further shed the light on the importance, limitations and advancements of different techniques that has a vital role in forensic anthropology. The research gaps were identified that will add upon the precision of medicolegal investigation.

1. Introduction

The word 'skeletal trauma' refers to an injury or damage that is caused to the bones due different forces like compression or trauma. The diagnosis of skeletal trauma is important to know the cause of death, the incidents that has led to the trauma and the proofs obtained would contribute for the legal procedures [1]. The analysis of the skeletal injuries forms the integral part of forensic anthropology helping in the medicolegal investigations. Forensic anthropology uses a number of tools to evaluate the trauma and varieties of procedures followed to evaluate the skeletal trauma add on to the knowledge of different trauma patterns [2]. Thus, the forensic anthropologist provide the vital information like blunt force trauma, fracture patterns, analysis of the type of tools, ballistic defects that sheds light on how the crime has occurred, the conditions the body underwent while facing the trauma, nature of injuries etc that plays a vital

role in crime investigation [3]. The collaborative efforts of forensic anthropologist, radiologist, pathologist and other specialists on understanding the skeletal trauma would help to understand and interpret the case more accurately [4].

This review aims to deliver a thorough evaluation of present state of understanding the forensic anthropology, knowledge to fill the research gaps and suggest opportunities for future advancements required for more investigations.

2. Types of skeletal trauma:

Tool mark analysis refers to examining the marks that is left on the bone and understanding the characteristics of the tool like shape and size of the tool, the type of weapon used. The tool mark analysis also throws light on type of force, minimum number of strikes on the victim by carefully reconstructing the broken



fragments of bone. The tools used by the forensic anthropologist include crime scene investigation tool, forensic anthropology tools, Forensic DNA analysis tools, toxicology tools, ballistic analysis tool, photography equipment, entomology and odontology tools, digital and imaging tools. Each tool used in the forensic investigation contributes valuable information to predict the crime scene [5].

The types of skeletal trauma include blunt force trauma (BFT), Sharp force trauma (SFT), Thermal trauma and High velocity projectile trauma (HVPT). BFT is a type of skeletal fracture that happens when a blunt surface or object impacts or approaches the body at a low velocity causing different fracture patterns, tool impressions or bone flakes [6]. When a sharp object like glass piece, saw or blade comes in contact with the body the type of injury it causes results in the SFT. Symes et al., has studied the morphology of saw marks in the human bones that resulted in SFT [7]. Thermal trauma involves the injuries caused due to fire or extreme environmental conditions that includes the burns of the skin involving the bones. Due to the exposure to high temperature of heat, the bones become brittle as the collagen matrix within the bone becomes weak. The forensic anthropologist's role is to identify and distinguish the burnt human remains from other animals that begins in the crime scene itself. Due to the exposure to heat, there is change in the colour, texture, water content is completely lost contributing to the bone deformation. To identify such deformations and to estimate the biological profile of the person, there are morphoscopic techniques that can be applied accurately [8, 9]. The complexity of thermal trauma requires multidisciplinary approach. When the injury is caused due to high-speed force or velocity on a small surface area by using a bullet or shrapnel. The damage or injury caused because of HVPT is more severe than the low velocity trauma. The injury caused by HVPT is complex involving combination of bone fracture and tissue damage [1].

3. Tools used in the skeletal trauma analysis:

At first the bone injuries are assessed by the forensic anthropologists by visual inspection at the crime scene. Further the tools and techniques that can be followed are cutting edge analytical tool, physical tools, macroscopic analysis, imaging techniques and biological

tests to understand the cause, time and severity of the death [4]. Among the different techniques that are mentioned, the most conventional method used to examine a skeletal trauma is visual inspection and macroscopic examination. The visual inspection is a simple process of examining the bone carefully and looking for any kind of traumatic lesions like fracture, cuts or aberrations [10]. Vital information obtained from visual and macroscopic examination needs the finer detailed information, which is provided by the cutting-edge imaging techniques. The imaging tools like X-rays, CT scans and magnetic resonance imaging (MRI) help to visualise the internal structure of the bone and reveal the details [11].

The conventional method in imaging technique is X-rays that gives the details of the type of fracture and internal structure of the bone. While the CT scan adds on to the evaluation of the skeletal trauma. The MRI application is rare in the forensic anthropology as it mainly deals with the details of the soft tissue surrounding the bone fractures [12]. With the advancement of technology, the forensic imaging software is used for 3D reconstruction and for further detailed analysis of the fractured bone. With the help of this software, a detailed visualization and digital model of the skeletal remains is possible [13]. Thus, the complete analysis of the skeletal trauma relies on both physical examination and also the imaging techniques. The details revealed by each tool and technique adds unique and valuable information pertaining to the circumstances of trauma and death.

4. Importance of DNA analysis in Forensic anthropology:

DNA analysis is useful in the evaluation of skeletal trauma by providing the useful and essential information into both identification and assessment of trauma analysis. The advancement in DNA profiling and the biomarkers can be very useful to achieve precise identification of individuals [14].

The primary applications of DNA analysis in evaluation of skeletal trauma are identification of individuals. Especially, when it is challenging in forensic contexts such as mass disasters, criminal cases, and situations involving severely degraded remains. Traditional identification methods—such as dental records or visual recognition—are often ineffective when



only skeletal remains are available. DNA profiling has brought a great revolution in the field of skeletal trauma analysis. The advances in the DNA extraction procedures have further added on to the recovery of genetic material even from the small or degraded samples. This is particularly significant in scenarios like mass graves, where commingled remains require precise genetic analysis to differentiate individuals [15].

5. Medicolegal aspect:

Forensic experts are very critical in the courtrooms. The expert's testimony bridges complex scientific findings with legal interpretations. The forensic experts deliver objectives and scientifically grounded assessments that ensure the credibility. The empirical data and rigorous scientific methodologies support the conclusions made by them. Without this foundation, expert testimony risks losing its influence and reliability in legal contexts [16]. Standards like the Daubert criteria, which require that procedures be experimentally validated, peer-reviewed, and generally accepted by the scientific community, regulate the admissibility of forensic evidence. The absence of established approaches, especially in trauma analysis, presents difficulties, nevertheless. To ensure that their methods endure trial challenges and satisfy strict evidentiary criteria, forensic experts must be prepared to defend their methodology under legal examination [17]. The way skeletal injuries are interpreted has a significant impact on how criminal cases turn out. Trauma analysis is made more complex by variables including the force and angle of impact, the person's age, sex, and health. To guarantee fair verdicts, it is essential to accurately determine the time and cause of injuries (ante-, peri-, or post-mortem). Erroneous convictions or acquittals could result from misinterpreting the evidence, highlighting the significance of careful examination and truthful reporting in forensic anthropology. The outcomes of criminal cases are greatly influenced by how skeletal injuries are interpreted. Complexity in trauma analysis is increased by variables including the force and angle of impact, the individual's age, sex, and health. Ensuring fair verdicts requires precise determination of the time and cause of injuries. Correct reporting and in-depth analysis are crucial in forensic anthropology since misinterpreted evidence may result in erroneous convictions or acquittals [18, 19]. Very precise and meticulous documentation, strict adherence to the

methodologies by the forensic anthropologists will solve the medico-legal issues in the area.

6. Methodology:

This review was conducted using the published original article and systematic reviews. The eligibility criteria for the articles - it must be written in English language and should discuss about the any of the types of skeletal trauma were included for the systematic review.

The key words used to obtain the articles from different database were 'skeletal trauma', 'trauma analysis', 'tool analysis' and 'techniques used in skeletal trauma analysis'. Different databases were used to obtain the articles by using the key words. The study selection and data extraction were done by two independent investigators. The study was carried in K.S Hegde Medical College, Mangalore, India from August 2024 to December 2024. The duplicate articles were excluded. The full text article that included title, abstract and key words were taken for the systematic review. After a thorough literature search, a total of 36 articles were obtained. Only 12 articles were used for the present systematic review as it met the inclusion criteria. The remaining 24 articles excluded from the review due to duplication, non-availability of full text articles. This is represented in the Prisma flow chart.

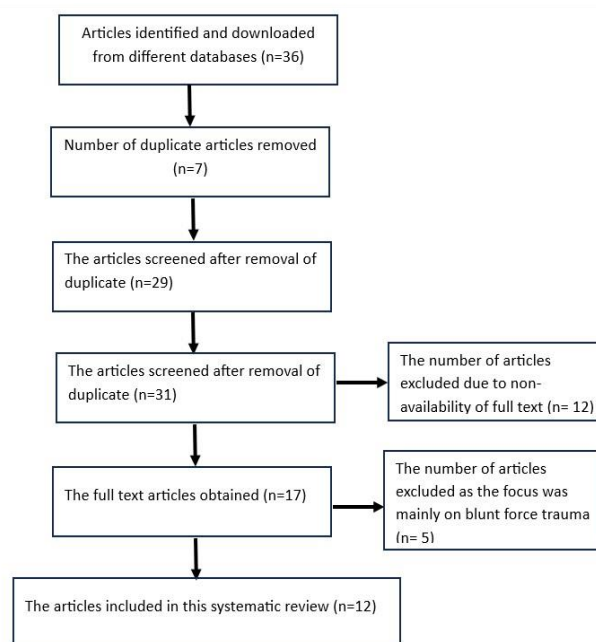


Figure 1: Prisma flow chart

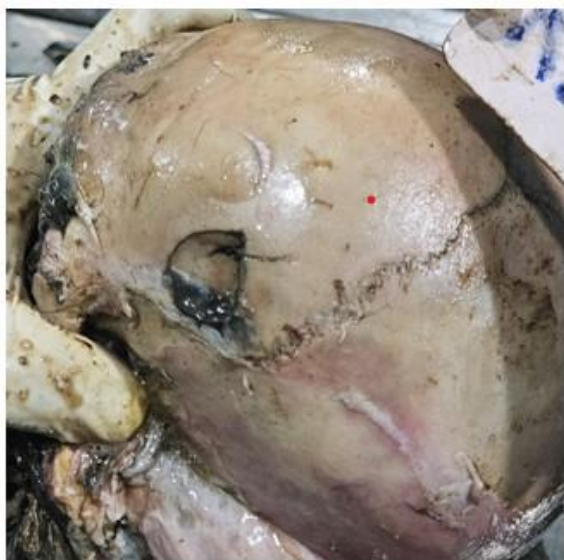

Figure 2: Showing the blunt force trauma injury in the left frontal region of cranial vault

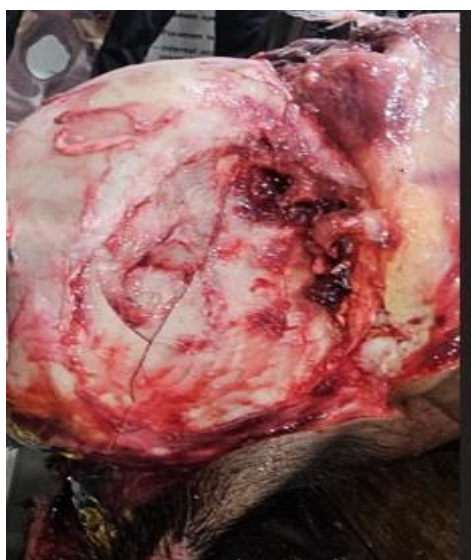

Figure 3: Showing the blunt force trauma injury in the right parietal region of cranial vault

7. Results:

After a through literature search for this systematic review, the shift from traditional to modern approaches in evaluating the skeletal trauma for medicolegal investigation is highlighted. This review further shed the light on the importance, limitations and advancements of different techniques that has a vital role in forensic

anthropology. The research gaps were identified that will add upon the precision of medicolegal investigation.

8. Discussion:

The evaluation of skeletal trauma is very crucial in the medicolegal investigations. Analysis of skeletal trauma by using different techniques is very much necessary to determine the cause of death, manner of death, the situation or the circumstances that has led to death. This information will provide a proof in legal proceedings [20]. Bone is more resilient to compressive stress than tensile stress which is directly proportional to its density. Bone is composed of organic component which is elastic in nature. This makes the bone to withstand both the compressive and tensile forces. If the applied force is slow and continuous then the damage caused to the bone is loss in its structure like temporary bending due to elastic fibres deformation. But if the applied force is rapid, it results in complete or partial breakage of the bone thus associated with high projectile skeletal trauma [16]. Ressel et al., has stressed upon the importance of relative movement of the body and the object [21]. There are some studies that focuses on the relationship between the force implemented with that of skeletal trauma caused [22]. By using different techniques more realistic image could be obtained as of how the soft tissue has impacted the skeletal trauma [23]. The advanced technologies like CT scans and 3D imaging would provide the minute details and virtual reconstruction helping in evaluating the skeletal trauma.

9. Conclusion:

It is utmost important for a Forensic anthropologist to understand the patterns of skeletal trauma and the response of the bone to the trauma. The different tools and techniques used in the skeletal trauma analysis would help to analyse the wound patterns, reconstruction of fragmented bones, the impact of tools on the skeletal trauma. The accurate details obtained may help to draw the conclusion to the manner of death and related circumstances.

Conflict of Interest: There is no conflict of interest

Source of funding: None

Ethical Clearance: Not Applicable

**References:**

- [1] Christensen AM, Passalacqua NV, Bartelink EJ. Analysis of skeletal trauma. *Forensic Anthropology*. 2014; Academic Press, San Diego. 347-377.
- [2] Tripathi SK, Singh S, Singh RR, Yadav PK. Evaluating Skeletal Trauma and Forensic Anthropology for Medicolegal Investigations: A Systematic Review. *Indian Journal of Forensic Medicine*. 2023; 17(3): 115-120.
- [3] Crowder CM, Wiersema JM, Adams BJ, et al. The utility of forensic anthropology in the medical examiner's office. *Acad Forensic Pathol*. 2016; 6(3):349-60.
- [4] Symes SA, Labbe EN, Chapman EN, Wolff I, Dirkmaat DC. Interpreting traumatic injury to bone in medicolegal investigations. A companion to forensic anthropology. 2012:340-89.
- [5] Love JC, Wiersema JM. Skeletal Trauma: An Anthropological Review. *Acad Forensic Pathol*. 2016; 6(3):463 -477. doi: 10.23907/2016.047.
- [6] Hipp JA, Haues WC. Skeletal trauma: fractures, dislocations, ligamentous injuries. Philadelphia: Saunders Company. Biomechanics of fractures; 1998.
- [7] Symes SA. Morphology of saw marks in human bone: identification of class characteristics. The University of Tennessee; 1992. http://trace.tennessee.edu/cgi/viewcontent.cgi?article=2578&context=utk_graddiss.
- [8] Blau S, Briggs CA. The role of forensic anthropology in disaster victim identification (DVI). *Forensic Sci Int*. 2011; 205(1-3):29-35. Doi: 10.1016/j.forsciint.2010.07.038.
- [9] Fairgrieve SI. Forensic cremation: recovery and analysis. Boca Raton: CRC Press; 2008. Doi: 10.1201/9781420008746.
- [10] Stübinger S, Ghanaati S, Saldamli B, Kirkpatrick CJ, Sader R. Er: YAG laser osteotomy: preliminary clinical and histological results of a new technique for contactfree bone surgery. *European Surgical Research*. 2009;42(3):150-6. Doi: 10.1159/000197216.
- [11] Beckwith JB, Palmer NF. Histopathology and prognosis of Wilms tumors: results from the First National Wilms' Tumor Study. *Cancer*. 1978 May;41(5):1937-48. doi: 10.1002/1097-0142(197805)41:5<1937::aid-cncr2820410538>3.0.co;2-u.
- [12] Mamabolo B, Alblas A, Brits D. Modern imaging modalities in forensic anthropology and the potential of low-dose X-rays. *Forensic Imaging*. 2020;23:200406. Doi: 10.1016/j.fri.2020.200406.
- [13] Garvin HM, Stock MK. The Utility of Advanced Imaging in Forensic Anthropology. *Acad Forensic Pathol*. 2016;6(3):499-516. doi: 10.23907/2016.050.
- [14] Latham KE, Miller JJ. DNA recovery and analysis from skeletal material in modern forensic contexts. *Forensic Sci Res*. 2018;4(1):51-59. doi: 10.1080/20961790.2018.1515594.
- [15] Butler JM. The future of forensic DNA analysis. *Philos Trans R Soc Lond B Biol Sci*. 2015;370(1674):20140252. doi: 10.1098/rstb.2014.0252.
- [16] Dempsey N, Blau S. Evaluating the evidentiary value of the analysis of skeletal trauma in forensic research: A review of research and practice. *Forensic science international*. 2020; 307: 110140. Doi: 10.1016/j.forsciint.2020.110140.
- [17] Miller CM. A survey of prosecutors and investigators using digital evidence: A starting point. *Forensic Science International: Synergy*. 2023;6:1-22. Doi:10.1016/j.fsisyn.2022.100296.
- [18] Iscan MY, Steyn M. The human skeleton in forensic medicine. Charles C Thomas Publisher; 2013.
- [19] Indest GF. Medicolegal issues in detecting and proving the sexual abuse of children. *Journal of Sex & Marital Therapy*. 1989;15(2):141-60.
- [20] Tripathi SK, Singh S, Singh SS, Yadav PK. Evaluating skeletal trauma and forensic anthropology for medicolegal investigations: A systematic review. *Indian Journal of Forensic Medicine*. 2023; 17(3): 115-120. doi:<https://doi.org/10.37506/ijfmt.v17i3.19499>
- [21] Ressel L, Hetzel U, Ricci E. Blunt Force Trauma in Veterinary Forensic Pathology. *Veterinary Pathology*. 2016;53(5):941-961. doi:10.1177/0300985816653988.
- [22] Porta DJ. The anatomy and biomechanics of experimentally traumatized human cadaver lower extremity components. University of Louisville; 1996.
- [23] Roberts P. Paradigms of forensic science and legal process: a critical diagnosis. *Philos Trans R Soc Lond B Biol Sci*. 2015;370(1674):20140256. doi: 10.1098/rstb.2014.0256.