



Morphometric Measurements of Proximal and Distal End of Adult Dry Femur with Its Clinical Correlation in South Indian Population

Divya N Pai¹, Chaitra D^{2*}, Dion Arnold Patrao³, Mayur Ragnath⁴

^{1&2*} Department of Anatomy, K.S Hegde Medical Academy, NITTE (Deemed to be University) Mangalore, Karnataka, India.

^{3&4} 2nd year MBBS, K.S Hegde Medical Academy, NITTE (Deemed to be University) Mangalore, Karnataka, India.

(Received: 16 March 2025

Revised: 20 April 2025

Accepted: 15 June 2025)

KEYWORDS

Femur,
knee joint
prosthesis,
hip
arthroplasties,
anthropometri
c
measurements
,
orthopaedic
surgeries

ABSTRACT:

Introduction: The use of prehensile hands and bipedal locomotion makes the human unique among other animals. Femur, being the longest and strongest bone of human body not just provides attachments to flexor, extensor and gluteal muscles but is also involved in the articulation of hip and knee joint. The morphometry of femur varies among the population of compared region wise and also between the neighbouring countries.

Objective: Was to provide a morphometric data on proximal and distal parts of right and left femur in South Indian population

Materials and method: 32 right side and 42 left side femur were used for the morphometric measurements obtained from the department of Anatomy, K.S Hegde Medical Academy, Mangalore, India.

Statistical analysis: The mean and standard deviation of the parameters were calculated by using SPSS version 23.0 software.

Conclusion: Based on the observations, we have come to a conclusion that the morphometric measurements of femur vary according to the body proportions Understanding the anatomy of femur and knowing the variations in the morphometric measurements is important orthopaedic implant surgeries and designing hip or knee joint prosthesis.

1. Introduction

The Femur, the longest and strongest bone of the thigh in the human body, provides attachments to the flexor, extensor, adductor, and even gluteal muscles. The attachments of these muscles help to maintain the erect posture and locomotion in Homo sapiens. The upper end of the femur bears a head that articulates with the acetabular cavity of the hip bone to form the hip joint, an elongated neck, and greater and lesser trochanters. The lower end of the femur is modified to form the medial and lateral condyles, the inferior surface of which articulates with the upper surface of the condyles of the tibia, and the anterior surface of the femoral condyles articulates with the patella to form the knee joint [1].

The bipedal locomotion and use of prehensile hands makes the humans unique among the other animals. The ability to move on two feet and use their hands efficiently and compliantly is the primary characteristic of humans [2]. The neck of the femur has undergone the structural modification that plays a role in the erect bipedal locomotion and posture. The femur's neck, which spans about 5 cm and typically joins the head and shaft at a 125° angle [3]. In addition to providing assistance during hip joint motions, the neck shaft angle serves as a lever for the muscles around the hip joint. By lowering the horizontal bending pressures felt at the pelvic girdle and consequently lowering bone tensile stress, the angles at the proximal femur enable



biomechanically favourable erect postures during motion. In clinical orthopaedics, the neck-shaft angle, also known as the inclination angle and angle of torsion, is a crucial anatomic indication. A neck shaft angle, also known as an inclination angle, is the angle formed between the diaphyseal and femoral neck axes [4].

Identification of deceased individuals is a significant challenge for physical anthropologists and forensic pathologists when dealing with severely disfigured skeletal remains [5]. Osteometry is most useful in medicolegal investigations when evaluating height, which is necessary to estimate sex, race, ancestry, ethnicity, stature, body weight, body build, and age of death. Amputation, fractures, ankylosis, deformities, and bone diseases are individualizing traits. If the reason for death is apparent in the skeletal remains, it is also crucial to determine the identity of the deceased person [6].

The study aimed to provide a morphometric data on proximal and distal parts of right and left femur in South Indian population.

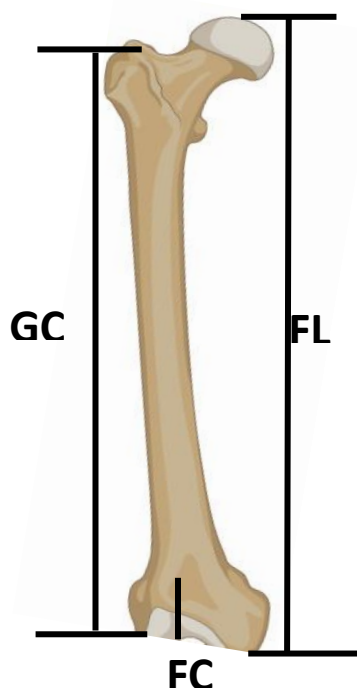


Figure 1: Parameters measured by taking vertical length of the femur and the osteometric board used in the measurement of femur length

2. Materials and method:

In the present study, 32 right side and 42 left side femurs obtained from the Department of Anatomy, K.S Hegde Medical Academy, Mangalore, Karnataka, India were used for the morphometric measurements. Damaged or malformed femur were excluded from the study. The ethics committee approval was not required for the present study, as the bones used for the study were for the osteology practical classes for the first year MBBS undergraduate classes. To take the measurements, Osteometric board and digital Vernier Calliper was used. All the measurements were repeated twice.

The vertical parameters measured were femoral shaft length (FL), length of the femoral condyles (FCL), distance between superior border of greater trochanter to the femoral condyles (GC). Measurements taken at the upper end of femur were and the parameters included were maximum vertical diameter on the femur head, femoral neck diameter, distance between tip of lesser trochanter to the tip of greater trochanter, distance between tip of lesser trochanter to the inferior aspect of greater trochanter, diameter of femur shaft at the proximal segment, distance between head of femur to the tip of greater trochanter, distance between head of femur to the tip of lesser trochanter, length of intertrochanteric line, width of greater trochanter, width of lesser trochanter, length of neck of femur, length of greater trochanter. Measurements taken at the lower end of femur were and the parameters included were diameter of femoral shaft at the distal segment, width of supracondylar line taken horizontally, length of patellar articular surface, width of patellar articular surface,



width of medial posterior condyle, width of lateral posterior condyle, height of medial posterior condyle, height of lateral posterior condyle, width of tibial articular surface, antero-posterior length of medial tibial articular surface, antero-posterior length of lateral tibial articular surface, width of intercondylar notch, height of intercondylar notch. Table 1 shows the parameters measured on entire femur. Table 2 shows the parameters measured on the proximal end of femur. Table 3 shows the parameters measured at the distal end of femur.

After taking the measurements, the data were entered in excel sheet. The measurements were repeated twice by two individuals to ensure if the correct measurement.

3. Statistical analysis:

All the analysis was performed by using SPSS version 23.0 software. Mean and standard deviation of the parameters were calculated.

4. Results:

The measurement with respect to the femur length is given in table 4. The measurements of upper and lower end of femur is given in table 5 and table 6 respectively. All the measurements are expressed in millimetres (mm).

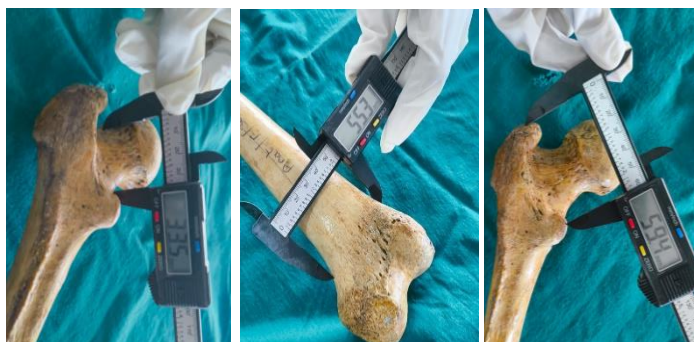

Figure 2: The parameters length of femur neck, diameter of femur shaft at distal end and distance between tip of greater trochanter to tip of lesser trochanter of femur.

Table 1: Parameters measured on the femur length

Parameter description	Parameter
Entire femur length	FL
Length of femoral condyles	FCL
Distance between upper end of greater trochanter to femoral condyles	GC

Table 2: Parameters measured on the upper end of femur

Parameter description	Parameter
Maximum vertical diameter on femur head	U1
Femoral neck diameter	U2
Length of neck of femur	U3
Distance between tip of lesser trochanter to the tip of greater trochanter	U4
Distance between tip of lesser trochanter to the inferior aspect of greater trochanter	U5
Diameter of femur shaft at the proximal segment	U6
Distance between head of femur to the tip of greater trochanter	U7
Distance between head of femur to the tip of lesser trochanter	U8
Length of intertrochanteric line	U9
Length of greater trochanter	U10
Width of greater trochanter	U11
Width of lesser trochanter	U12

Table 3: Parameters measured on the lower end of femur

Parameter description	Parameter
Diameter of femoral shaft at the distal segment	L1
Width of supracondylar line taken horizontally	L2
Length of patellar articular surface	L3
Width of patellar articular surface	L4
Height of medial posterior condyle	L5
Height of lateral posterior condyle	L6
Width of medial posterior condyle	L7
Width of lateral posterior condyle	L8



Width of tibial articular surface	L9
Antero-posterior length of medial tibial articular surface	L10
Antero-posterior length of lateral tibial articular surface	L11
Height of intercondylar notch	L12
Width of intercondylar notch	L13

Table 4: Measurements of parameters of femur length (mm)

Parameters measured	Minimum	Maximum	Mean ± SD
FL	374.37	485.94	432.28 ± 26.11
FCL	30.26	52.19	41.35 ± 5.62
GC	315.74	447.81	381.77±25.54

Table 5: Measurements of parameters taken at upper end of femur (mm)

Parameters	Minimum	Maximum	Mean ± SD
U1	36.36	49.55	42.95 ± 5.62
U2	25.45	41.62	33.98 ± 4.11
U3	38.17	51.39	43.72 ± 4.12
U4	55.24	73.76	64.18 ± 5.61
U5	43.8	64.31	54.45 ± 4.43
U6	30.43	35.12	32.71 ± 2.51
U7	19.30	34.91	27.53 ± 3.47
U8	27.13	49.98	38.89 ± 7.23

U9	51.86	70.19	61.25 ± 6.75
U10	20.19	30.36	25.75 ± 4.71
U11	33.23	38.51	35.83 ± 4.11
U12	12.13	23.7	17.62 ± 2.33

Table 6: Measurements of parameters taken at the lower end of femur (mm)

Parameters	Minimum	Maximum	Mean ± SD
L1	35.47	50.38	43.12 ± 7.19
L2	55.73	72.39	63.85 ± 7.14
L3	18.37	24.61	21.83 ± 3.15
L4	27.6	44.4	36.38 ± 7.03
L5	26.73	40.28	34.21 ± 5.49
L6	25.8	43.1	34.89 ± 8.67
L7	21.8	31.73	26.96 ± 5.18
L8	19.8	29.5	25.4 ± 4.12
L9	52.8	69.2	61.94 ± 8.61
L10	47.83	59.73	53.96 ± 6.33
L11	50.28	63.27	57.12 ± 6.83
L12	19.06	30.3	25.11 ± 5.21



L13	12.4	25.83	20.42 ± 4.87
-----	------	-------	--------------

5. Discussion:

Femur being the longest bone in the human body is the widely studied bone due its applications in the orthopaedic surgeries. The morphometric measurements of the upper and lower end of femur are investigated by the many authors due to its importance in the forensic anthropometry. The findings or the measurements of the parameters vary in different populations and gender. Thus, a thorough understanding of morphometry of femur specially the features and the dimensions aid the clinicians to understand the degenerative changes, manage the traumatic injuries and surgical planning of femoral diseases [7].

Further, the Worldwide increase of total hip arthroplasties and hip joint surgeries in the past few years necessitates the anthropometric measurements of both proximal and distal end of femur a mandate and valuable tool for constructing femoral implants and prothesis. and the hip arthroplasties is said to increase by 174% by the year 2030 [8].

Many authors have measured the morphometry of femur including measurements on the proximal and distal end of the femur. The authors Siwach RC and Dahiya S have measured the morphometry of femur and also, they have compared the measurements with those of Chinese, Hong Kong and other western population [9]. The morphometric studies conducted among the various Chinese population, Asian population and Pakistani population stress on the fact that there exist regional differences contributing to the differences in the morphometry of the femur [10, 11, 12].

About 27% of the individual's stature is contributed by the length of the femur. In our study, the average length of the femur is 432.28 ± 26.11 mm.

In the hip arthroplasties, the length of femoral neck derives its importance as it adjusts the femur to the new biomechanics of the introduced prosthetic implant. Increased femur neck fractures in the adults is attributed to the wide femoral neck length in the aged. In the present study, the average femur neck length is 43.72 ± 4.12 mm. This is close to the average femur neck length which is

said to be 5 cm. El-Kaissai et al., conducted a retrospective study in the Caucasian postmenopausal women and suggested that hip fracture in these women have a longer femur neck length compared to the women without fracture [13].

Understanding the anatomy of femur and knowing the variations in the morphometric measurements is important orthopaedic implant surgeries and designing hip or knee joint prosthesis.

Conclusion:

Based on the observations mentioned above, we have come to a conclusion that the morphometric measurements of femur vary according to the body proportions. The measurements when compared with the studies done by the neighbouring countries is not same but shows distinct differences. Thus, region wise taking the morphometric measurements will gather required data which is useful for patient care and different treatment procedures and outcomes.

Conflict of Interest: None

References:

1. Manjunath TH, Santosh CS. Morphometric study of adult dry femur and its forensic importance. *Int J Acad Med Pharm* 2023; 5(5):1241-1244.
2. Terzidis I, Totlis T, Papathanasiou e, SIDERIDIS A, VLASIS K, NATSIS K (2012). Gender and side-to-side differences of femoral condyles morphology: osteometric data from 360 caucasian dried femori. *Anatomy Research International*, 2012: 679658.
3. Pathak SK, Maheshwari P, Ughareja P, Gadi D, Prashanth Raj M, Gour SK. Evaluation of femoral neck-shaft angle on plain radiographs and its clinical implications. *Int J Res Orthop*, 2016; 2:383-86.
4. Chaudhary PN, Shirol VS, Virupaxi RD..A morphometric study of femoral length, anterior neck length, and neck-shaft angle in dry femora: A cross-sectional study. *Indian J Health Sci Biomed Res*. 2017;10:331-34.
5. Verma L, Gupta S, Ghulyani T, Jaiswal P. A digital image analysis method for measuring



- femoral neck-shaft angle and anteversion angle: A pilot study. *Indian Journal of Clinical Anatomy and Physiology*. 2016; 3(3):362-69.
6. Eboh D, Jgbinedion E. Morphometry of the distal femur in a south-south nigerian population. *Mal J Med Health Sci*. 2021;16:197-201.
 7. Biswas A, Bhattacharya S. A morphometric and radiological study of the distal end of femur in West Bengal population. *J Anat Embryol*. 2017; 122:39-48.
 8. Kurtz S, Ong K, Lau E, Mowat F, Halpern M. Projections of primary and revision hip and knee arthroplasty in the United States from 2005 to 2030. *J Bone Joint Surg Am*. 2007; 89:780-785.
 9. Siwach RC, Dahiya S. Anthropometric study of proximal femur geometry and its clinical application. *Indian Journal of Orthopaedics*. 2003; 37(4):247-51.
 10. Baharuddin MY, Zulkifly AH, His M, Aziz AA. Three-dimensional morphometry of the femur to design the total hip Arthroplasty for Malay Population. *Advanced Science Letters*. 2013; 19(10):2982-87.
 11. Lin KJ, Wei HW, Lin KP, Tsai CL, Lee PY. Proximal femoral morphology and the relevance to design of Anatomically precontoured plates: A study of the Chinese population. *The Scientific World Journal*, 2014; 4:1-6.
 12. Umer M, Sepha A, Khan A. Morphology of the proximal femur in the Pakistan population. *J Orthop Surg*. 2010; 18:279-81.
 13. El KS, Pasco JA, Henry MJ, Panahi S, Nicholson JG, Nicholson GC, *et al*. Femoral neck geometry and hip fracture risk: the Geelong osteoporosis study. *Osteoporosis Int*, 2005; 16:1299-303.