



## “A Diaphyseal Fitting Modular Bipolar Prosthesis in Comminuted Trochanteric Femur Fracture in Elderly Patient - A Prospective Study”

1Dr . Harish Arunmozhidevan\* , 2Dr. Santosh S Nandi, 3Dr. \*Gireesh Khodnapur \* , 4Dr . Vijaykumar Patil\_ \* , 5Dr. Shreepad Kulkarni, 6Dr. Ravikumar Biradar,

1( Dept. Of Orthopaedics, B.L.D.E deemed to be University, Shri B.M. Patil medical college, Vijayapura, Karnataka, India ),MS Orthopaedics (Russia)

2(Professor & HOD, Dept. Of Orthopaedics, B.L.D.E deemed to be University, Shri B.M. Patil medical college, Vijayapura, Karnataka, India )

3(Associate professor, Dept. Of Orthopaedics, B.L.D.E deemed to be University, Shri B.M. Patil medical college, Vijayapura, Karnataka, India )

4(Assistant professor, Dept. Of Orthopaedics, B.L.D.E deemed to be University, Shri B.M. Patil medical college, Vijayapura, Karnataka, India )

5(Associate professor, Dept. Of Orthopaedics, B.L.D.E deemed to be University, Shri B.M. Patil medical college, Vijayapura, Karnataka, India )

6(Professor, Dept. Of Orthopaedics, B.L.D.E deemed to be University, Shri B.M. Patil medical college, Vijayapura, Karnataka, India )

Corresponding author

Dr . Harish Arunmozhidevan\* ( Dept. Of Orthopaedics, B.L.D.E deemed to be University, Shri B.M. Patil medical college, Vijayapura, Karnataka, India ),MS Orthopaedics (Russia)

*(Received: 16 March 2025*

*Revised: 20 April 2025*

*Accepted: 15 June 2025)*

### KEYWORDS

Comminuted Intertrochanteric Fracture Femur, Diaphyseal Fitting Modular Bipolar Hemiarthroplasty, Elderly Patients, Harris Hip Score, Long stem Hemiarthroplasty.

### ABSTRACT:

Introduction

The purpose of the study is to assess the management of comminuted trochanteric fractures of femur in elderly patients is tricky as there is challenge of difficult anatomical reduction in osteoporotic bones, need for prolonged immobilization after surgery and more chances of screw cut out in poor quality bone. Prolonged immobilization will lead into complications like bed sores, chest infections, deep vein thrombosis, dependency and psychosocial side effects, increasing both morbidity and mortality. The aim of our study was to evaluate the functional outcome of diaphyseal long stem bipolar prosthesis in comminuted trochanteric fractures of femur in elderly patients using Harris Hip Score

Methodology

This prospective study enrolled 31 patients with unstable intertrochanteric fractures (AO/OTA types 31-A2.2 and 31-A2.3) admitted to the apex trauma center of a tertiary care facility between March 2022 and March 2025. Inclusion criteria comprised treatment with cemented bipolar hemiarthroplasty and a minimum follow-up period of six month.

Results

According to the Harris Hip Score, at the end of 6 months, 7 patients (22.6%) had excellent results, 20 patients (64.5%) had good results, 4 patients (12.9%) had fair results. With cemented hemiarthroplasty, 87.7% of older patients with unstable intertrochanteric fractures were able to walk sooner, and the results were good.

At 6-month follow-up, Harris Hip Score outcomes demonstrated excellent functional results in 7 patients (22.6%), good results in 20 patients (64.5%), fair results in 4 patients (12.9%). The study



revealed that diaphyseal fitting modular bipolar hemiarthroplasty enabled early ambulation in 85.19 % of elderly patients with comminuted trochanteric fractures, with predominantly favorable outcomes overall.

### Conclusion

To summarize, employing a diaphyseal fitting modular bipolar prosthesis in older individuals with comminuted trochanteric femur fractures leads to favorable to outstanding functional results along with early mobilization, early weight bearing with rapid rehabilitation with decreased morbidity and mortality.

### Introduction

A proximal femur or hip fracture remains the most common reason for an elderly person to be admitted to an acute orthopedic ward. An estimated 2.1 million hip fractures occurred worldwide in 2021. Assuming there is no age-specific increase, this number is predicted to rise to 2.6 million by 2025 and 4.5 million by 2050. Estimations that include an age-specific increase give predicted values of between 7.3 and 21.3 million by 2050. Much of this increase will occur in the developing countries like India and for developing countries, the rise in age-specific rates now appears to have stopped, but the total numbers of hip fractures continue to increase as life expectancy continues to increase.

Almost half of these hip fractures will be extracapsular, that is, the fracture is mainly confined to the area of bone between the hip joint capsular attachments to a level of 5 cm distal to the lower border of the lesser trochanter. Extracapsular fractures can then be further divided into trochanteric and subtrochanteric fractures. Patients with an extracapsular fracture tend to be slightly older and frailer than those with an intracapsular fracture. The average age of these patients is progressively increasing to that of a mean of about 80 years in developing countries. Many of these patients will have associated medical conditions, some degree of impaired mobility, reduced mental capacity, and a history of previous falls.

### MATERIALS AND METHODS

#### SOURCE OF DATA:

Patients admitted in Department of Orthopedics in B.L.D.E. (DEEMED TO BE UNIVERSITY) Shri B.M.Patil Medical College, Hospital and Research Centre, Vijayapura with the diagnosis of comminuted trochanteric fracture (AO/OTA types 31-A2.2 and 31-

A2.3). Proper institutional ethics committee clearance (BLDE(DU)/IEC/982/2022-2023) have been obtained before the start of the study, the patients will be informed about the study in all respects and informed written consent would be obtained. Patient will be assessed post operatively at 6 weeks, 3 months, 6 months. The period of study will be from MARCH 2023- MARCH 2025.

#### INCLUSION CRITERIA

Trochanteric fracture classified as Comminuted fracture according to Boyd and Griffin classification (type II, III, IV) in osteoporosis.

Closed fractures.

Patients with pathological fracture

#### EXCLUSION CRITERIA

Compound trochanteric fracture

Poly trauma patient who cannot be mobilized

Active infection of hip joint

**OPERATIVE PROTOCOL:** As for antibiotics, one dose of injectable Cefuroxime 1.5 gm and Injection Amikacin 500 mg was administered the before surgery. This was followed by intravenous Injection Cefuroxime 750 mg every 8 hours and Injection Amikacin 500 mg intravenously every 12 hours. Both antibiotics were given for a duration of 3 to 5 days. Additionally, an oral 2nd generation cephalosporin was prescribed for a period of 7 to 10 days.

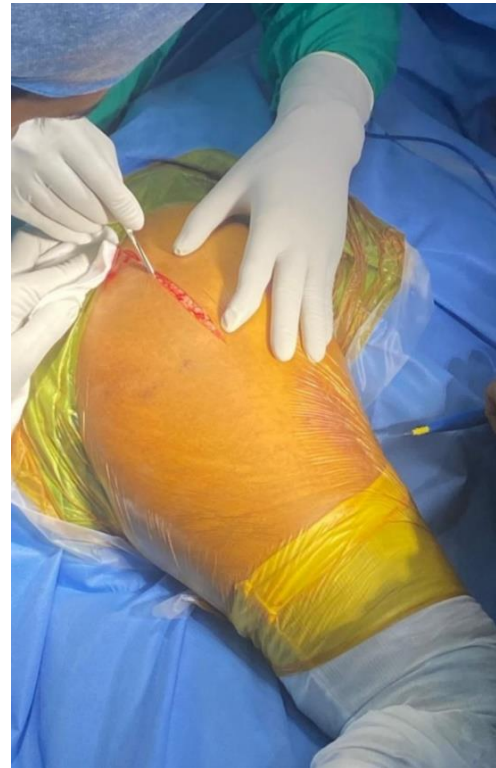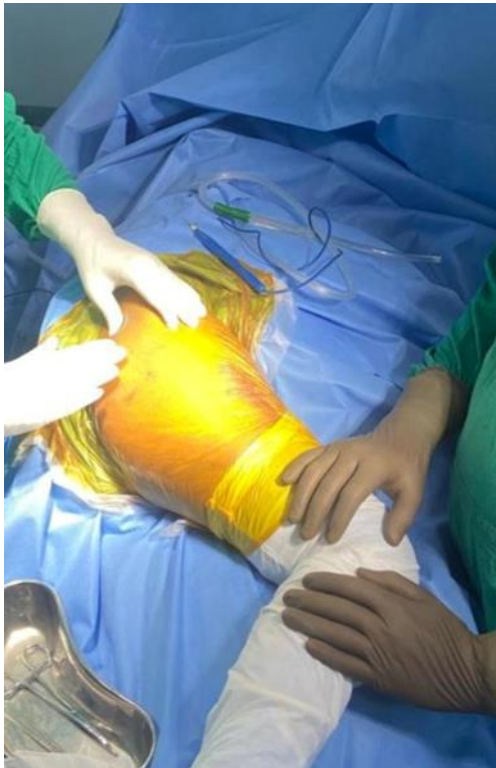**ANAESTHESIA:** Based on patient's overall health condition, either General or Spinal/Epidural anesthesia was administered.

**OPERATIVE TECHNIQUE:** All procedures were performed using the Moore approach.



All procedures were performed electively under strict aseptic conditions by a team of three senior orthopedic surgeons. Spinal anesthesia was administered in all

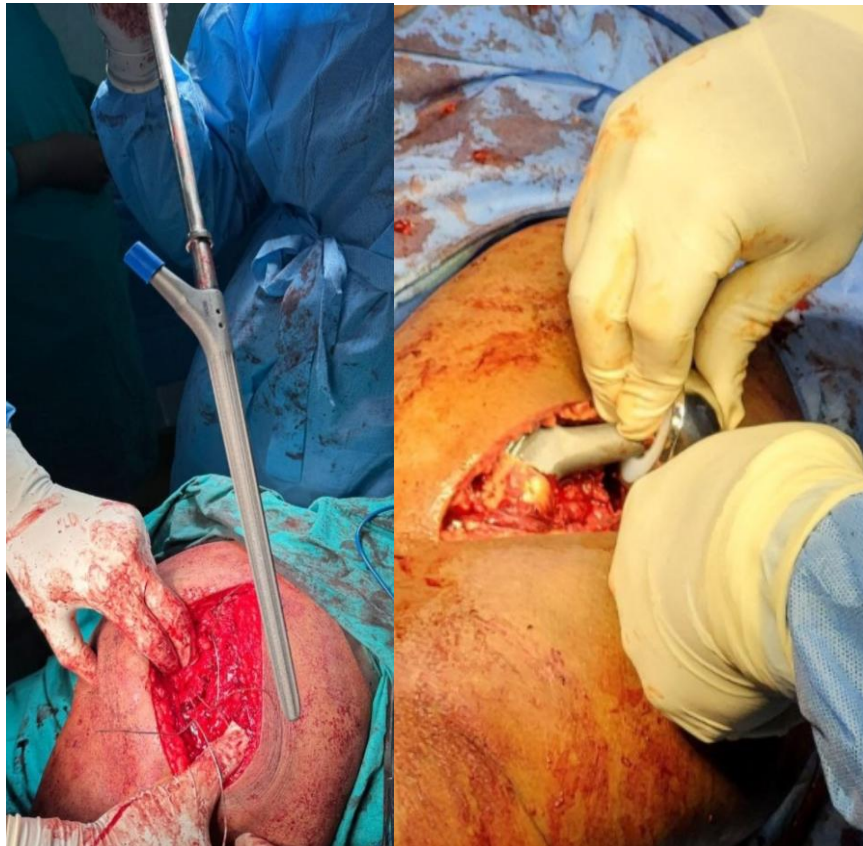
cases, with patients positioned laterally on their unaffected side. The hip joint was accessed through a standard posterior (Moore) approach.



**Lateral decubitus position of the patient and exposure of the hip by the Moore (posterior) approach.**

A longitudinal incision was created approximately 6–8 cm superior and posterior to the posterior border of the greater trochanter, aligned with the gluteus maximus muscle fibers. The external rotators were identified and secured with tagging sutures. Following exposure of the hip joint capsule, a capsulotomy was performed. The femoral head was resected and measured for sizing. The acetabulum was meticulously prepared, with complete excision of the ligamentum teres and debridement of

residual pulvinal soft tissue using a curette. Femoral canal preparation was carried out using sequential reaming and broaching to achieve optimal stem fit. Trochanteric reconstruction was performed utilizing stainless steel cerclage wires and ethibond sutures as necessary. Finally, the prosthetic stem was implanted to the predetermined depth, as marked preoperatively, to ensure accurate limb length restoration. wound closed in layers

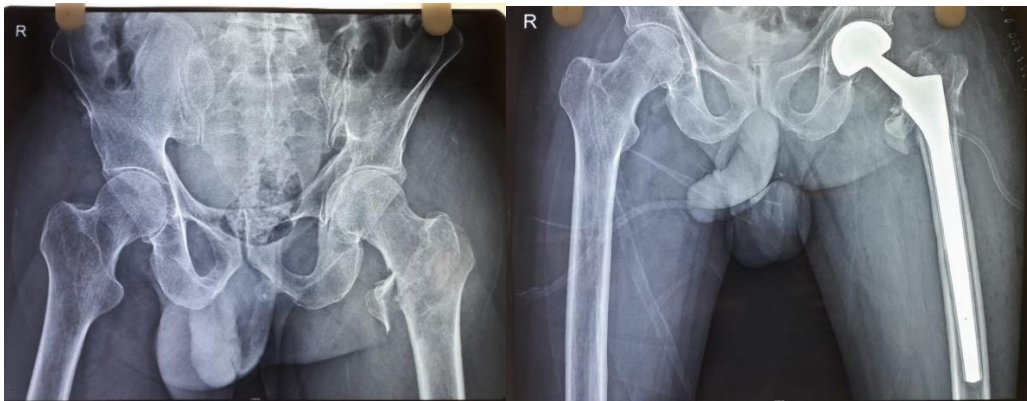

**Insertion Of Diaphyseal Fitting Femoral Stem With Bipolar Head And Reduction Done**

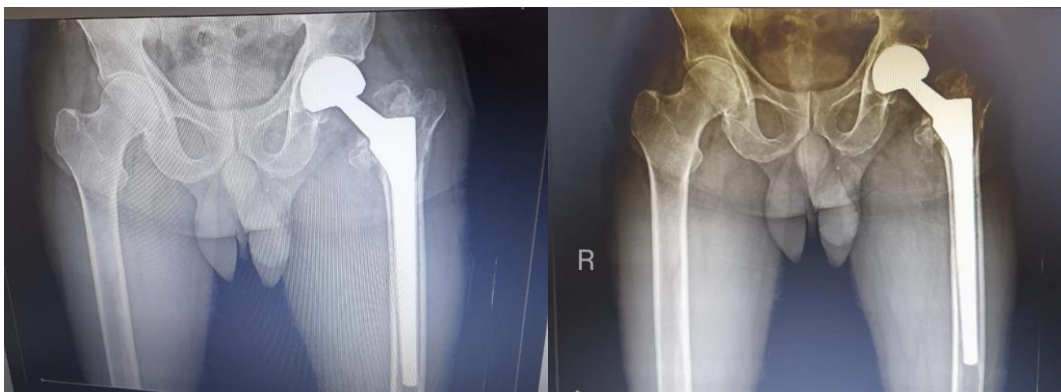
**POST-OPERATIVE PROTOCOL:**

X-rays of the operated patient were obtained in pelvic with both hip in anteroposterior views after the surgery. A hemogram and serum electrolytes were assessed immediately after the procedure and again 24 hours later. The limb is positioned in abduction with a pillow placed between to avoid adduction and internal rotation. Dressings were changed on day 2 during the drain removal and again on day 5. Supine static quadriceps exercises and ankle pumps were initiated on the day of surgery, while sitting quadriceps exercises commenced on the first postoperative day. Full weight-bearing was allowed starting on the first postoperative day. Suture

removal was done alternately and completely on the 10th and 12th days after surgery. Discharge took place on the 12th day following the operation. Postoperative follow-ups were conducted at 6 weeks, 3 months, and 6 months. At each follow-up appointment, the patients were assessed both radiologically and clinically. Functional outcomes were measured using the Harris hip score. Radiographs were taken at each follow-up to check for any signs of dislocation or loosening of the prosthesis. Rehabilitation lasted for up to 1 year and included lifestyle modifications like avoiding squatting, sitting cross-legged, or climbing high steps, along with gait training.



Preoperative and Postoperative X-Ray POD-1



Follow up X-Ray 6 Weeks and Follow up X-Ray 6 Months

### Statistical Analysis

The data obtained will be entered in a Microsoft Excel sheet, and statistical analysis will be performed using statistical package for the social sciences (Verson 20).

Results will be presented as Mean  $\pm$  SD, Median and interquartile range, frequency, percentages and diagrams.

### Results

The age distribution among study participants (n = 31) shows that a majority fall within the 61-80 years age range (71%), with the next largest group being those aged 81-90 years (22.6%). The smallest representation belongs to the 91-100 age group. The average age of participants is 75.81 years (SD=9.311), with ages ranging from 63 to 94 years. Baseline age data is crucial for understanding the context and generalizability of

this study, as it reflects a typical elderly population with femoral fractures.

In terms of sex distribution, female patients comprise 64.5% of the study population, while male patients account for 35.3%. The mode of injury and its distribution can be summarized, where self-falls constitute the majority of injuries (87.1%), compared to road traffic accidents (RTA) at 12.9%. Regarding the side of the injury, the distribution is fairly even, with 45.2% of injuries occurring on right (R) side and 54.8% on left (L).

The breakdown of patient outcomes indicates that the majority, 64.5%, had a "GOOD" outcome, 22.6% achieved an "EXCELLENT" outcome, and 12.9% experienced a "FAIR" outcome. The distribution of complications among patients shows that most patients, 87.1%, were uncomplicated. Other



complications included leg length discrepancy (LLD) at 9.7% and periprosthetic fracture (PPF).

**Table : Post operative complications**

Mortality rate	0
Pulmonary Complications	0
Urinary Tract Infections	0
Deep Vein Thrombosis	0
Cardiovascular Complications	0
Wound Infections	0
Pressure Sores	0
Leg Length Discrepancy	3
Periprosthetic Fracture	1

Post operative mortality and morbidities were nil.

## Discussion

Managing comminuted trochanteric femur fractures in elderly patients presents a challenging clinical dilemma, primarily due to the weakness of the bone, a heightened risk of complications, and the need for prompt mobilization to avert additional morbidity. This research assessed the effectiveness of employing a diaphyseal fitting modular bipolar prosthesis in elderly individuals with comminuted trochanteric femur fractures. The findings indicate that this surgical approach successfully results in good to excellent functional outcomes for most patients, accompanied by a low complication rate.

Average age of study cohort was 75.81 years (SD=9.311), which is consistent with the demographic profile of older people who had femur fractures. A significant portion of the patients (71%) fell within the 61 to 80-year age range, which is consistent with existing literature showing that the likelihood of hip fractures markedly rises with age, especially among the elderly (Çiloğlu et al., 2022; Kim et al., 2018). The gender distribution revealed a higher percentage of female patients (64.5%), aligning with the established higher prevalence of osteoporosis and hip fractures among postmenopausal women (Lee et al., 2011).

The predominant cause of injury in this research was self-fall (87.1%), corroborating findings from other studies that have identified falls as the primary cause of hip fractures in elderly (Zha et al., 2019; Biçen et al., 2021). Road traffic accidents (RTA) accounted for a lesser share of injuries (12.9%), which

is anticipated given the reduced mobility and lower exposure to high-energy trauma in this age demographic.

According to Harris Hip Score (HHS), functional outcomes were primarily classified as good (64.5%) or exceptional (22.6%), with just 12.9% of patients receiving a fair score. With an average HHS of 85.19 (SD=4.377), the majority of patients were able to resume hip function to a satisfactory degree. For unstable intertrochanteric fractures, these outcomes are similar to those of other trials that used modular bipolar prostheses. "In their mid-term follow-up of patients treated with cementless bipolar hemiarthroplasty, for example, Kim et al. (2018) showed similar functional results, with a mean HHS of 84.5. With a mean HHS of 86.2 in older patients with osteoporotic fractures, Lee et al. (2011) discovered that using a hydroxyapatite-coated long stem in cementless bipolar hemiarthroplasty allowed for satisfactory functional outcomes."

The complication rate found in this investigation was relatively low, with 87.1% of patients not experiencing any complications. The most frequently observed complication was leg length discrepancy (LLD) (9.7%), followed by periprosthetic fracture (PPF) (3.2%). These outcomes align with previous research that reported LLD and PPF as potential complications associated with modular bipolar hemiarthroplasty. For example, Zha et al. (2019) documented a 10.2% incidence of LLD in their study of cementless distal fixation modular stems for unstable intertrochanteric fractures. Similarly, Biçen et al. (2021) identified a 3.5% occurrence of PPF in their retrospective comparison of long-stem prostheses for intertrochanteric fractures. Notably, patients experiencing complications (LLD and PPF) exhibited poorer functional outcomes, with none reaching excellent or good results. This underscores the critical need for precise surgical techniques and diligent postoperative care to reduce complications and enhance outcomes.

The study's conclusions are consistent with those of prior investigations on the application of modular bipolar prosthesis in senior citizens with unstable intertrochanteric fractures. For example, Kim and colleagues (2018) documented mid-term survival rates of 92.3% after cementless bipolar hemiarthroplasty for unstable intertrochanteric



fractures. The use of a hydroxyapatite-coated long stem in cementless bipolar hemiarthroplasty also produced favorable functional results and low rates of complications in older patients with osteoporotic fractures, according to Lee et al. (2011). This was demonstrated by a mean HHS of 86.2 at an average follow-up of 5.2 years.

### Limitations of the study

Less Follow-up periods.

Low sample size.

### Conclusion

To summarize, employing a diaphyseal fitting modular bipolar prosthesis in older individuals with comminuted trochanteric femur fractures leads to favorable to outstanding functional results along with a minimal occurrence of complications like bed sores, deep vein thrombosis, dependency and psychosocial side effect, chest infections. The findings from this research endorse this surgical method as a practical choice for treating comminuted trochanteric femur fractures in elderly patients facilitate early mobilization, early weight bearing with rapid rehabilitation with decreased morbidity and mortality.

### Ethical Approval

All procedures performed in studies involving human participants were in accordance with the ethical standards of the institutional.

### Informed Consent

Informed consent was obtained from all individual participants included in the study. The experiments comply with the current laws of the Country in which they were performed.

### Declaration of Conflicting Interests

The author(s) declared no potential conflicts of interest with respect to the research, authorship, and/or publication of this article.

### References

1. Abrahamsen B, van Staa T, Ariely R, Olson M, Cooper C: Excess mortality following hip fracture: a systematic epidemiological review. *Osteoporos Int.* 2009, 20:1633-50. 10.1007/s00198-009-0920-3
2. Tsuboi M, Hasegawa Y, Suzuki S, Wingstrand H, Thorngren KG: Mortality and mobility after hip fracture in Japan: a ten-year follow-up. *J Bone Joint Surg Br.* 2007, 89:461-6. 10.1302/0301-620X.89B4.18552
3. Dahl E: Mortality and life expectancy after hip fractures. *Acta Orthop Scand.* 1980, 51:163-70. 10.3109/17453678008990781
4. Antapur P, Mahomed N, Gandhi R: Fractures in the elderly: when is hip replacement a necessity?. *Clin Interv Aging.* 2011, 6:1-7. 10.2147/CIA.S10204
5. Simunovic N, Devereaux PJ, Sprague S, Guyatt GH, Schemitsch E, Debeer J, Bhandari M: Effect of early surgery after hip fracture on mortality and complications: systematic review and meta-analysis. *CMAJ.* 2010, 182:1609-16. 10.1503/cmaj.092220
6. Song QC, Dang SJ, Zhao Y, Wei L, Duan DP, Wei WB: Comparison of clinical outcomes with proximal femoral nail anti-rotation versus bipolar hemiarthroplasty for the treatment of elderly unstable comminuted intertrochanteric fractures. *BMC Musculoskelet Disord.* 2022, 23:628. 10.1186/s12891-022-05583-4
7. Grau L, Summers S, Massel DH, Rosas S, Ong A, Hernandez VH: Operative trends in the treatment of hip fractures and the role of arthroplasty. *Geriatr Orthop Surg Rehabil.* 2018, 9:2151459318760634. 10.1177/2151459318760634
8. Kamel HK: Male osteoporosis: new trends in diagnosis and therapy. *Drugs Aging.* 2005, 22:741-8. 10.2165/00002512-200522090-00003
9. Kim SY, Kim YG, Hwang JK: Cementless calcar-replacement hemiarthroplasty compared with intramedullary fixation of unstable intertrochanteric fractures. A prospective, randomized study. *J Bone Joint Surg Am.* 2005, 87:2186-92.



10. Camurcu Y, Cobden A, Sofu H, Saklavci N, Kis M: What are the determinants of mortality after cemented bipolar hemiarthroplasty for unstable intertrochanteric fractures in elderly patients?. *J Arthroplasty*. 2017, 32:3038-43. 10.1016/j.arth.2017.04.042
11. Mansukhani SA, Tuteja SV, Kasodekar VB, Mukhi SR: A comparative study of the dynamic hip screw, the cemented bipolar hemiarthroplasty and the proximal femoral nail for the treatment of unstable intertrochanteric fractures. *J Clin Diagn Res*. 2017, 11:RC14-9. 10.7860/JCDR/2017/21435.9753
12. Bonneville P, Saragaglia D, Ehlinger M, Tonetti J, Maisse N, Adam P, Le Gall C: Trochanteric locking nail versus arthroplasty in unstable intertrochanteric fracture in patients aged over 75 years. *Orthop Traumatol Surg Res*. 2011, 97:S95-100. 10.1016/j.otsr.2011.06.009
13. Meinberg EG, Agel J, Roberts CS, Karam MD, Kellam JF: Fracture and Dislocation Classification Compendium—2018. *J Orthop Trauma*. 2018, 32:S1-S10. 10.1097/BOT.0000000000001063
14. Singh M, Nagrath AR, Maini PS: Changes in trabecular pattern of the upper end of the femur as an index of osteoporosis. *J Bone Joint Surg Am*. 1970, 52:457-67. 10.2106/00004623-197052030-00005
15. Hauschild O, Ghanem N, Oberst M, et al.: Evaluation of Singh index for assessment of osteoporosis using digital radiography. *Eur J Radiol*. 2009, 71:152-8. 10.1016/j.ejrad.2008.03.019
16. Harris WH: Traumatic arthritis of the hip after dislocation and acetabular fractures: treatment by mold arthroplasty. An end-result study using a new method of result evaluation. *J Bone Joint Surg Am*. 1969, 51:737-55.
17. Akıncı O, Akalın Y, Reisoğlu A, Kayalı C: Comparison of long-term results of dynamic hip screw and AO 130 degrees blade plate in adult trochanteric region fractures. *Acta Orthop Traumatol Turc*. 2010, 44:443-51. 10.3944/AOTT.2010.2356
18. Shah SN, Wainess RM, Karunakar MA: Hemiarthroplasty for femoral neck fracture in the elderly surgeon and hospital volume-related outcomes. *J Arthroplasty*. 2005, 20:503-8. 10.1016/j.arth.2004.03.025
19. Rawate P, Kale AR, Sonawane CS: Functional outcome of cemented bipolar hemiarthroplasty for unstable intertrochanteric fractures of femur in elderly: an Indian perspective. *Int J Sci Stud*. 2017, 5:48-53.
20. Rodop O, Kiral A, Kaplan H, Akmaz I: Primary bipolar hemiprosthesis for unstable intertrochanteric fractures. *Int Orthop*. 2002, 26:233-7. 10.1007/s00264-002-0358-0
21. Sancheti KH, Sancheti PK, Shyam AK, Patil S, Dhariwal Q, Joshi R: Primary hemiarthroplasty for unstable osteoporotic intertrochanteric fractures in the elderly: a retrospective case series. *Indian J Orthop*. 2010, 44:428-34. 10.4103/0019-5413.67122
22. Patil V, Nandi SS, Naik S, Vinaykumar B, Kulkarni S, Patel RK: Functional outcome of unstable comminuted intertrochanteric fractures in elderly treated with primary bipolar hemiarthroplasty. *Int J Orthop Sci*. 2019, 5:59-62. 10.22271/ortho.2019.v5.i1b.13
23. Kiran Kumar GN, Meena S, Kumar NV, Manjunath S, Vinay Raj MK: Bipolar hemiarthroplasty in unstable intertrochanteric fractures in elderly: a prospective study. *J Clin Diagn Res*. 2013, 7:1669-71. 10.7860/JCDR/2013/5486.3228
24. Sinno K, Sakr M, Girard J, Khatib H: The effectiveness of primary bipolar arthroplasty in treatment of unstable intertrochanteric fractures in elderly patients. *N Am J Med Sci*. 2010, 2:561-8.
25. Siwach R, Jain H, Singh R, Sangwan K: Role of hemiarthroplasty in intertrochanteric fractures in elderly osteoporotic patients: a case series. *Eur J Orthop Surg Traumatol*. 2012, 22:467-72. 10.1007/s00590-011-0870-2
26. Saoudy EE, Salama AM: Bipolar hemiarthroplasty for the treatment of unstable trochanteric fracture femur in the elderly. *Egypt Orthop J*. 2016, 51:313-8.



27. Elmorsy A, Saied M, Zaied M, Hafez M: Primary bipolar arthroplasty in unstable intertrochanteric fractures in elderly. *Open J Orthop.* 2012, 2:13-17. 10.4236/ojo.2012.21003
28. Hongku N, Woratanarat P, Nitiwarangkul L, Rattanasiri S, Thakkestian A: Fracture fixation versus hemiarthroplasty for unstable intertrochanteric fractures in elderly patients: a systematic review and network meta-analysis of randomized controlled trials. *Orthop Traumatol Surg Res.* 2022, 108:102838. 10.1016/j.otsr.2021.102838
29. Chowdhury AK, Townsend O, Edwards MR: A comparison of hemiarthroplasty versus dynamic hip screw fixation for intertrochanteric femoral fractures: a systematic review. *Hip Int.* 2022, 11207000221112579. 10.1177/11207000221112579
30. Fan L, Dang X, Wang K: Comparison between bipolar hemiarthroplasty and total hip arthroplasty for unstable intertrochanteric fractures in elderly osteoporotic patients. *PloS One.* 2012, 7:e39531. 10.1371/journal.pone.0039531ity and reliability of our assumptions.