



Juvenile Periodontitis Overshadowing Multiple Idiopathic Root Resorption - MIRR - A Rare Case Report

Dr. Aashritha. O.V, ¹ Dr Ravindra S.V ² , Dr. Bhuvaneshwari Kalmath³, Dr. Shaik Mobeen⁴, Dr Jayasri. Vanapalli ⁵

¹-PG Final Year Department of OMR, MNR Dental College And Hospital , Sangareddy.

²-Prof & H.O.D , Department of OMR, MNR Dental College And Hospital , Sangareddy.

³-Professor, Department of OMR, MNR Dental College And Hospital , Sangareddy.

⁴-Associate Professor, Department of OMR, MNR Dental College And Hospital , Sangareddy.

⁵-Assistant Professor, Department of OMR, MNR Dental College And Hospital , Sangareddy.

Corresponding Author: Dr. Shaik Mobeen Associate Professor, Department Of OMR, MNR Dental College And Hospital , Sangareddy.

(Received: 16 June 2025

Revised: 20 July 2025

Accepted: 04 August 2025)

KEYWORDS

Juvenile
Periodontitis,
Multiple
Idiopathic

ABSTRACT:

Multiple Idiopathic Root Resorption (MIRR) is an unknown origin, rare and aggressive illness that develops spontaneously in healthy people without systemic or local disorders. MIRR is a major problem for clinicians, frequently requiring invasive operations like tooth extractions. This paper highlights a case of MIRR and includes a comprehensive literature review using databases like PubMed, Embase, Web of Science, Cochrane Library, CNKI, WANFANG, and Google Scholar

Introduction

There is a dearth of research on numerous idiopathic external root resorption; the first report was released in 1930 [1]. By definition, "the term idiopathic is applied if an etiological factor for root resorption cannot be identified." There have been documented cases with one or more teeth, and they have been divided into cervical and apical types (Lydiatt et al., 1989; Yusof & Ghazali, 1989) [1, 2]. The apical region of several teeth in young people is affected in the majority of reported instances. The

research has only discovered a certain number of numerous idiopathic apical root resorption [1, 4, and 5].

CASE REPORT

A 29-year-old female presented to MNR Dental College & Hospital, Department of Oral Medicine and Radiology, with a chief complaint of for the past six months, I have been looking for a replacement for my loose teeth in the lower front and rear areas. In addition to sporadic pain and mild discomfort, the patient reported a gradual start of



movement that recently deteriorated, making it difficult to speak and chew.

ON CLINICAL EXAMINATION:

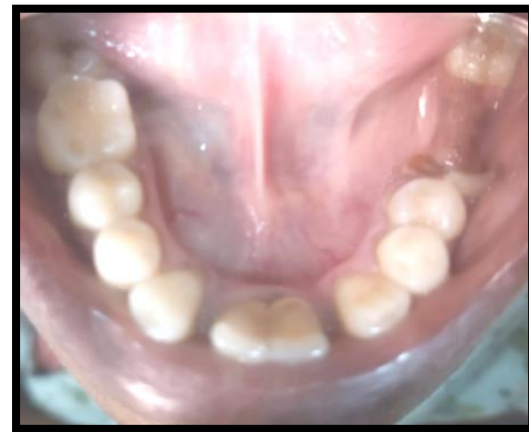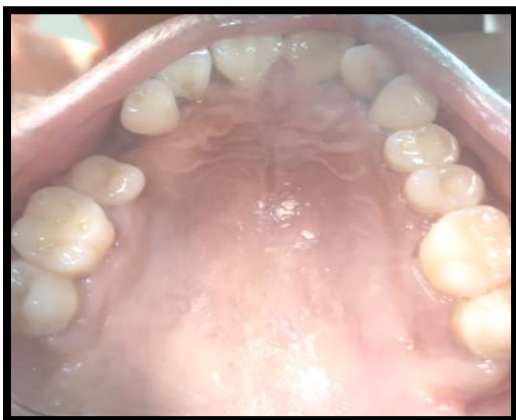Mobility is checked accordingly with one finger and metal probing instrument. The degree and ease of tooth movement are used to grade it

The mobility is evaluated based on Glickman's classification

- Grade III mobility in teeth 21, 31, 41, 42, 36, and 37.
- Grade II mobility in teeth 11, 12, 21, 22, 26, 16, and 17.
- Root stumps irt : 46
- Missing Teeth irt : 47 , 24
- Aggressive Periodontitis was the tentative diagnosis based on the clinical symptoms and case history.
- It is evident from the history that the teeth moved quickly.

One of the hallmarks of aggressive or juvenile periodontitis is the involvement of first molars and incisors.

Maxillary Arch [Fig 1]



Mandibular Arch [Fig 2]

Considering the case history and clinical findings, a provisional diagnosis of Aggressive Periodontitis was made.

Differential diagnosis

Orthodontic therapy-related resorption: The patient did not get orthodontic treatment.

Periodontal inflammation: A clinical examination reveals no visible inflammation, periodontal pockets, gingival recession, or furcation.

Hyperparathyroidism

Hyperparathyroidism

Hypophosphatemia

Hypophosphatemia

Gaucher's disease

Paget's disease of bone

Endocrine problems have been screened for using biomedical methods. There have been no noticeable alterations in the haematological state.

Goltz syndrome

Papillon-Lefèvre syndrome



Anachoresis

Turner's syndrome

Since no proper family history has been gathered, there is no evidence of familial or genetic inheritance.

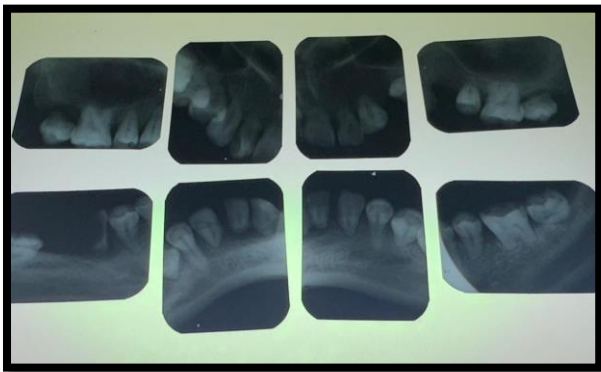


Fig: 3 (Full mouth intra oral periapical radiograph)

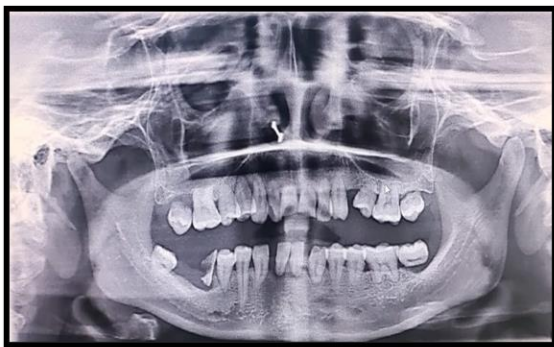

Fig: 4 (Panoramic Radiograph)

Radiographic Examination: Refer figure- 3 & 4

1. Normal Trabecular Bone Pattern;
2. Normal Alveolar Process Height;
3. Two-Thirds Root Resorption In Maxillary And Mandibular Anterior Teeth;
4. One-Third Root Resorption In Maxillary And Mandibular Premolars;
5. Full Root Resorption In Both Maxillary And Mandibular Molars;

6. Bilaterally Symmetrical Resorption Pattern;

7. Significantly Resorbed Roots Of Maxillary First Molars;

8. Greater Resorption Severity In Posterior Teeth

With the exception of mandibular second molars, all teeth with resorbed roots are crucial, according to electric pulp testing.

Because endocrine problems such hypophosphatemia, hyperparathyroidism, and hypothyroidism may contribute to multiple idiopathic resorption, the patient was recommended to have haematological and biochemical screening.

The patient had a typical medical history and family.

Biomedical and haematological test results were within normal limits.

Multiple idiopathic root resorption is the ultimate diagnosis following evaluation of the findings from the biomedical, haematological, and radiographic screenings.

DISCUSSION

Root resorption of the permanent dentition is a rare condition that can damage one or more teeth. The word "idiopathic" might be used when there is no logical explanation for the resorption. Only a few case reports are found when searching the literature for multiple idiopathic root resorption. [4, 5]

Types of Idiopathic Root Resorption [3]:

- Apical Root Resorption: This process causes the root to gradually shorten and round out as it begins apically and moves coronally.
- Cervical Root Resorption: This process begins in the cervical regions and moves on to the pulp.



The following are typical signs of multiple idiopathic root resorption: [6]

Normal clinical appearance of teeth and periodontal tissues; root resorption linked to endodontically treated or live teeth; absence of periapical or periodontal inflammation; and normal alveolar bone levels

- Lack of regional causative elements
- MIRR affects several teeth without a clear cause; patients do not exhibit any symptoms until very late in the pathological process, when increased tooth mobility occurs; and a bilaterally symmetrical Root resorption exhibits a symmetrical pattern. [7]
- Frequently discovered by chance using radiography results.

Young adults, mostly men, are commonly affected, with maxillary teeth being more commonly affected. Younger females are also more likely to experience multiple idiopathic root resorption.

Any excised soft tissue or bone examined histologically shows persistent, nonspecific inflammation, and the findings of other laboratory tests show no notable anomalies. [8]

Multiple Studies around Etiology of root resorption

Stafne and Slocumb [9] No clear correlations with systemic disease were found in a study of root resorption cases.

Gunraj [10]. The resorption of teeth and bone is significantly influenced by the activation of interleukin (IL)-1B.

Al-Qawasmi *et al.*, [11] indicated that root resorption etiology is influenced by IL-1 gene variants.

Urban *et al.*, [12] shown that the development of pathological root resorption is substantially more

likely to occur in individuals with IL-1 gene polymorphism.

Linares *et al.*, [13] further proposed that a predisposition to external apical root resorption is determined by changes in both the IL-1 receptor antagonist gene (rs419598) and the IL-1B gene.

Treatment: The degree and severity of root resorption, along with the symptoms that are present, are important factors in the treatment of multiple idiopathic root resorption because there are no known absolute etiological determinants. Since there isn't an established preventive or treatment strategy at this time, monitoring and periodontal maintenance are indicated.

The standard course of treatment involves extracting the tooth with a poor prognosis and employing radiography, periodontal measurements, and sensibility tests to assess the remaining dentition throughout time. Osseo-integrated implants, complete dentures, or fixed partial dentures can all be used to repair edentulous saddles. [15]

A well-established more intrusive method is endodontic treatment of the afflicted teeth, in which the preferred medication is a calcium hydroxide dressing. It might be proposed that ledermix is essential for teeth even after root resorption [14].

For repeated idiopathic root resorption, endodontic therapy is not recommended in the absence of pulpal complaints.

Conclusion: Based on the results of the biochemical screening, the haematological examinations, and the lack of periodontal or periapical infection, this case was classified as multiple idiopathic root resorption. A panoramic image coincidentally showed numerous idiopathic resorption while the patient was asymptomatic. It is envisaged that the identification of the cellular and molecular mechanism of root resorption may result in new



treatment approaches because the Etiology of numerous idiopathic root resorption is unknown.

REFERENCES

1. Pietro Di Domizio, Giovanna Orsin, Antonio Scarano, Adriano Piattelli, Idiopathic Root Resorption: Report of a Case, JOURNAL OF ENDODONTICS, VOL. 26, No. 5. MAY 2000
2. H Liang, EJ Burkes NL, Frederiksen , Multiple idiopathic cervical root resorption: systematic review and report of four cases, Dentomaxillofacial Radiology (2003) 32, 150–155
3. Shanon patel , navid saberi . The in's and out's of root resorption. British dental journal , VOLUME 224 NO. 9 ,MAY 11 2018.
4. Barkland LK ,Root resorption .Dent clin North Am .1992;36:491-507.[pubmed:1572510].
5. Newman WG . Possible etiologic factors in external root resorption .Am J Ortho.1975;67:522-39.[pubmed : 164774]
6. Choila SS, Wilson PH, Makdissi J . Multiple idiopathic external root resorption : report of four cases Dentomaxillfac radio. 2005;34:240-6.[pubmed:15961600].
7. Liang H, Burkes EJ, Frederiksen NL. Multiple idiopathic cervical root resorption: systematic review and report of four cases. Dentomaxillofac Radiol 2003; 32: 150–155.
8. Di Domizio P, Orsini G, Scarano A, Piattelli A. Idiopathic root resorption: Report of a case. *J Endod.* 2000;26:299–300.
9. Stafne EC, Slocumb CH. Idiopathic resorption of teeth. *Am J Orthod Oral Surg.* 1944;30:41–9.
10. Gunraj MN. Dental root resorption. *Oral Surg Oral Med Oral Pathol Oral Radiol Endod.* 1999;88:647–53.
11. Al-Qawasmi RA, Hartsfield JK, Jr, Everett ET, Flury L, Liu L, Foroud TM, et al. Genetic predisposition to external apical root resorption in orthodontic patients: Linkage of chromosome-18 marker. *J Dent Res.* 2003;82:356–60.
12. Urban D, Mincik J. Monozygotic twins with idiopathic internal root resorption: A case report. *Aust Endod J.* 2010 Aug;36:79–82.
13. Iglesias-Linares A, Yañez-Vico R, Ballesta-Mudarra S, Ortiz-Ariza E, Ortega-Rivera H, Mendoza-Mendoza A, et al. Postorthodontic external root resorption is associated with IL1 receptor antagonist gene variations. *Oral Diseases.* 2012;18:198–205.
14. Pierce An, Heithersay G, Lindskog S. Evidence for direct inhibition of dentinoclasts by a corticosteroid/antibiotic endodontic paste. *Endod Dent Traumatol.* 1988;4:44–5
15. Parul Bansal, Vineeta Nikhil, Sonali Kapur. Multiple idiopathic external apical root resorption: A rare case report. *J Conserv Dent.* 2015 Jan-Feb; 18(1): 70–72.