



Evaluation of Clinical Outcomes Following Er, Cr: YSGG Laser-Assisted Operculectomy in the Management of Pericoronitis: A Retrospective Study

Poulami Chakraborty¹, Subasree S^{2*}

¹Postgraduate, Department of Periodontology, Saveetha Dental College and Hospitals, Saveetha Institute of Medical and Technical Sciences, Saveetha University, Chennai, India.

²Assistant Professor, Department of Periodontology, Saveetha Dental College and Hospitals, Saveetha Institute of Medical and Technical Sciences, Saveetha University, Chennai, India.

(Received: 16 July 2025

Revised: 20 August 2025

Accepted: 02 September 2025)

KEYWORDS

Pericoronitis,
Er,Cr:YSGG laser,
operculectomy, laser
dentistry,
postoperative pain,
recurrence, wound
healing

ABSTRACT:

Background:

Pericoronitis is a common inflammatory condition associated with partially erupted mandibular third molars. Conventional scalpel-based operculectomy often results in postoperative discomfort, delayed healing, and a higher dependency on antibiotics. The Er,Cr:YSGG laser (2780 nm) offers precise, minimally invasive tissue ablation with improved healing and reduced morbidity.

Aim:

To investigate the therapeutic effectiveness of Er,Cr:YSGG laser operculectomy in comparison to traditional scalpel-based surgery for treating pericoronitis.

Materials

and

Methods:

This retrospective investigation involved 40 patients (age range: 18–40 years) diagnosed with pericoronitis. Twenty patients received Er,Cr:YSGG laser-assisted operculectomy, and twenty underwent conventional scalpel-based operculectomy. Parameters assessed included postoperative pain (VAS score), time for swelling resolution, antibiotic usage, and recurrence within 3–6 months. Statistical evaluation was carried out using independent t-tests and chi-square tests, with significance set at a p-value below 0.05.

Results:

The treatment group with the laser demonstrated notably reduced average pain scores (2.9 ± 0.71) compared to the conventional group (5.0 ± 1.08) ($p < 0.001$). Swelling resolved faster in the laser group (4.1 ± 0.85 days) than in the conventional group (4.85 ± 1.27 days) ($p = 0.02$). The need for antibiotics was markedly reduced in the laser-treated group (15%) in contrast to the conventional treatment group (60%) ($p = 0.004$). While the laser group showed a lower recurrence rate (10%) than the conventional group (25%), this difference did not reach statistical significance ($p = 0.20$).

Conclusion:

Er,Cr:YSGG laser-assisted operculectomy offers significant advantages over conventional techniques in managing pericoronitis. It results in reduced postoperative pain, faster healing, and lower antibiotic usage, supporting its integration into routine clinical practice for soft tissue management.



1. Introduction

Pericoronitis is a prevalent and often painful inflammation of the soft tissues around a partially erupted lower third molar, commonly known as the wisdom tooth. This condition mainly occurs in young adults aged 18 to 30 and is more frequently observed in the lower jaw, where third molars are often impacted or only partially erupted [1,2]. The pathogenesis of pericoronitis involves the trapping of plaque and food remnants under the soft tissue flap, leading to bacterial colonization and subsequent inflammation [3]. Clinical signs include localized pain, swelling, erythema, and restricted mouth opening (trismus), often accompanied by regional lymphadenopathy or systemic symptoms such as fever [4].

Conventional treatment strategies for pericoronitis are primarily palliative and include local irrigation, mechanical debridement, the use of antiseptic mouth rinses, antibiotics, and in cases of recurrent infection, surgical removal of the operculum (operculectomy) or extraction of the involved tooth [5]. While effective, these conventional approaches—particularly scalpel-based operculectomy—are associated with several drawbacks such as intraoperative bleeding, risk of infection, significant postoperative discomfort, and delayed wound healing due to exposure of a raw surgical field [6].

The advent of laser-assisted dentistry has revolutionized the management of soft tissue pathologies, offering minimally invasive alternatives with improved clinical outcomes. One such technology is operating at a wavelength of 2780 nm, the Er,Cr:YSGG laser is composed of erbium and chromium-doped yttrium scandium gallium garnet. Its high affinity for water and hydroxyapatite enables effective use on both soft and hard oral tissues [7,8]. Its tissue interaction is fundamentally different from thermal lasers such as diodes or CO₂ lasers. The Er,Cr:YSGG laser induces tissue ablation primarily through a photomechanical effect mediated by water molecules, resulting in minimal thermal damage and carbonization of surrounding tissues [9].

In soft tissue procedures like operculectomy, the Er,Cr:YSGG laser provides precise, bloodless incisions with effective bacterial decontamination of the surgical site [10]. Several *in vitro* studies have confirmed its

ability to significantly reduce bacterial colonies, particularly gram-negative anaerobes that are commonly implicated in periodontal infections and pericoronitis [11,12]. Moreover, laser-treated wounds exhibit enhanced fibroblast proliferation, reduced inflammatory cell infiltration, and faster re-epithelialization—leading to accelerated healing and better patient comfort [13].

The Er,Cr:YSGG laser causes minimal post-operative pain and often reduces the need for drugs such as analgesics or antibiotics. In operculectomy procedures, this laser technique has shown clear benefits over traditional surgical methods, including minimized bleeding, accelerated tissue recovery, and reduced recurrence [14,15]. However, despite these advantages, there remains a relative paucity of clinical studies assessing the effectiveness of Er,Cr:YSGG laser in managing pericoronitis in real-world clinical settings.

This retrospective study was therefore undertaken to evaluate and compare the clinical outcomes of Er,Cr:YSGG laser-assisted operculectomy with conventional treatment modalities in patients diagnosed with pericoronitis. The parameters assessed included resolution of symptoms (pain, swelling, and trismus), number of follow-up visits, recurrence rates, post-operative complications, and patient-reported outcomes such as pain relief and perceived healing. This investigation aims to compare the clinical outcomes of Er,Cr:YSGG laser-assisted operculectomy with those of standard surgical methods in the treatment of pericoronitis.

2. Methods

This retrospective observational study was conducted in the Department of Periodontics at Saveetha Dental College and Hospital. This investigation focused on analyzing the clinical performance of the Er,Cr:YSGG laser-assisted operculectomy in comparison to conventional surgical operculectomy in the management of pericoronitis. Patient records from January 2020 to December 2024 were reviewed for inclusion.

A total of 40 patients diagnosed with pericoronitis associated with partially erupted mandibular third molars were recruited for the study. Based on the treatment provided, participants were allocated into two groups, each consisting of 20 individuals. Group A consisted of patients treated with conventional scalpel-based



operculectomy, while Group B received Er,Cr:YSGG laser-assisted operculectomy. The treatment allocation was retrospective and based on availability of treatment modality at the time of presentation.

Inclusion criteria were patients aged between 18 and 40 years, clinically diagnosed with pericoronitis, with a minimum of one follow-up visit, and complete documentation of preoperative signs and symptoms (including pain, swelling, and trismus), treatment details, and postoperative follow-up. Exclusion criteria included patients with underlying health conditions that may impair wound healing (such as uncontrolled diabetes or immunosuppression), immediate third molar extraction without conservative operculectomy, and incomplete clinical records or loss to follow-up.

For the conventional group, operculectomy was performed using a sterile scalpel blade under local anesthesia. The overlying soft tissue operculum was excised, and the area was irrigated with normal saline. Postoperative instructions were provided along with analgesics and antibiotics when necessary.

Treatment in the laser group involved the Er,Cr:YSGG laser (Waterlase iPlus, Biolase Inc., USA), applied at 2780 nm while adhering to routine safety measures. A MZ6 tip was used at 1.5 W power in soft tissue mode with a water:air spray ratio of 80:20. The operculum was excised using a sweeping motion in non-contact mode (Figure 1). Minimal bleeding was observed, and no sutures were required. Patients were given standard postoperative care with instructions, and antibiotics were prescribed only if deemed necessary.

Data were extracted from institution's digital record system - DIAS (Dental Information Archiving Software) which included demographic details (age and gender), treatment modality, clinical symptoms at presentation (pain, swelling, trismus), postoperative pain scores using the Visual Analogue Scale (VAS) on Day 1, Day 3, and Day 7, swelling resolution (yes/no), number of follow-up visits, need for antibiotics, recurrence of pericoronitis within 3 months, and any reported complications such as delayed healing or persistent pain.

Statistical analysis was performed using IBM SPSS version 26.0 (IBM Corp., Armonk, NY). Descriptive statistics were employed to present demographic and clinical data. Categorical variables, including recurrence

and antibiotic usage, were examined using the chi-square test. Continuous variables, including VAS pain scores, were analyzed using either independent t-tests or Mann-Whitney U tests, depending on the data distribution. A p-value below 0.05 was regarded as statistically significant.

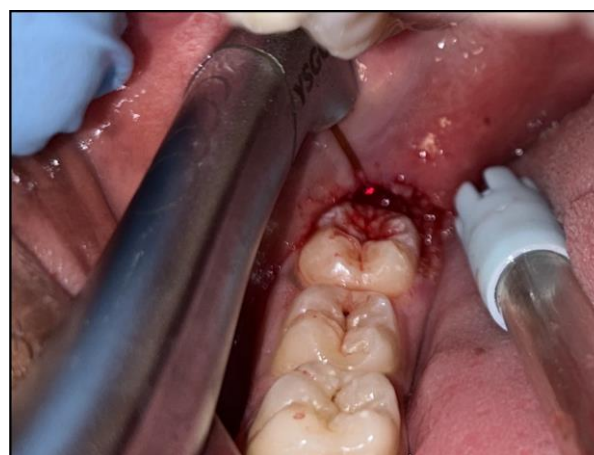

Figure 1 - Operculectomy using Er,Cr:YSGG laser

3. Results

This retrospective analysis included 40 patients diagnosed with pericoronitis, divided equally into two groups: one treated with Er,Cr:YSGG laser-assisted operculectomy and the other with a conventional scalpel technique. Postoperative pain was measured using the Visual Analogue Scale (VAS), revealing a significantly lower mean score in the laser group (2.9 ± 0.71) compared to the conventional group (5.0 ± 1.08), with the difference being statistically significant ($p < 0.001$). Swelling resolution occurred more rapidly in the laser group, with a mean duration of 4.1 ± 0.85 days, while the conventional group had a longer resolution time of 4.85 ± 1.27 days; this difference was also statistically significant ($p = 0.02$). The use of antibiotics was considerably higher in the conventional group (12 out of 20 patients) compared to the laser group (3 out of 20 patients), showing a statistically significant difference ($p = 0.004$). Additionally, recurrence of pericoronitis within 3 months occurred in 5 patients (25%) in the conventional group versus 2 patients (10%) in the laser group ($p = 0.20$), though this did not reach statistical significance. No major postoperative complications such as delayed healing or secondary infections were observed in either group. Overall, Er,Cr:YSGG laser-



assisted operculectomy resulted in significantly improved postoperative outcomes in terms of pain, healing time, and reduced antibiotic dependency compared to the conventional method as shown in Table 1, Figure 2 & 3.

Table 1 : Summary of Clinical Outcomes

Parameter	Conventional Group	Laser Group	P value
Mean Pain Score (VAS)	5.0 ± 1.08	2.9 ± 0.71	0.001*
Mean Days for Swelling Resolution	4.85 ± 1.27	4.1 ± 0.85	0.02*
Recurrence Cases (within 3–6 months)	5	2	0.20
Antibiotic Use (No. of Patients)	12	3	0.00*

*statistically significant

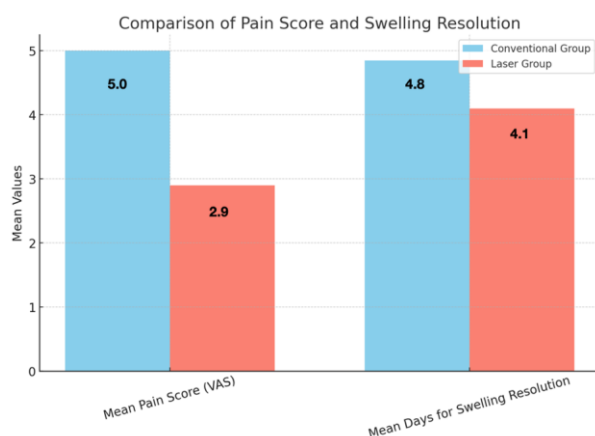


Figure 2 : Comparison of Postoperative Pain and Swelling Duration Between Conventional and Laser Groups. The visual analog scale (VAS) was used to quantify the average pain reported postoperatively, while the duration of swelling resolution was measured in days. Patients in the conventional group (represented in blue) reported a higher mean pain

score and longer swelling duration compared to those treated with laser-assisted techniques (represented in orange), indicating better postoperative comfort in the laser group.

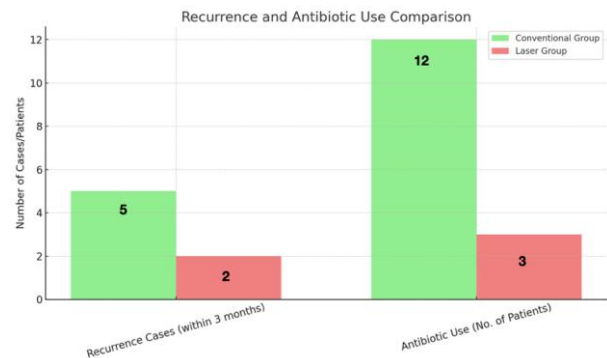


Figure 3 : Recurrence and Antibiotic Requirement in Conventional vs. Laser Groups. The conventional group (shown in light green) exhibited a higher number of recurrence cases and greater need for antibiotics, whereas the laser group (in light coral) demonstrated reduced recurrence and minimal antibiotic requirement. This highlights the potential advantages of laser therapy in minimizing postoperative complications and medication dependency.

4. Discussion

The present retrospective study evaluated and compared the clinical outcomes of Er,Cr:YSGG laser-assisted operculectomy and conventional scalpel-based operculectomy in the management of pericoronitis. The results demonstrated that laser-assisted procedures resulted in significantly lower pain scores, faster resolution of swelling, reduced antibiotic usage, and fewer recurrences, suggesting superior clinical efficacy and patient-centered outcomes.

Pericoronitis is a frequently encountered inflammatory condition in dental practice, often associated with the eruption of mandibular third molars. Its management is directed at reducing infection, alleviating symptoms, and preventing recurrence. Conventional operculectomy using a scalpel, though effective, is accompanied by several disadvantages such as intraoperative bleeding, post-operative pain, and a relatively longer healing period due to the open wound [1,5]. Laser-assisted surgeries, particularly using the Er,Cr:YSGG laser, offer



a promising alternative by addressing many of these limitations.

Patients who underwent treatment with the Er,Cr:YSGG laser in this study experienced a notably lower average pain score on the VAS scale (2.9) than those who received conventional treatment (5.0). These results align with previous research indicating that laser procedures lead to less post-operative discomfort, likely due to limited thermal injury and the laser's non-contact cutting mechanism. The photomechanical action of the Er,Cr:YSGG laser, facilitated by its affinity for water, allows for clean incisions with reduced inflammation and nociceptive stimulation [7,8,18].

Another key observation was the shorter mean duration for swelling resolution in the laser group (4.1 days) compared to the conventional group (4.85 days). The faster resolution of inflammation can be attributed to the laser's ability to decontaminate the surgical field and stimulate tissue healing [19]. Er,Cr:YSGG lasers have been shown to induce fibroblast proliferation, enhance vascularization, and reduce inflammatory infiltrates in soft tissues, all of which contribute to expedited wound healing [20].

Antibiotic prescription was notably reduced in the laser group, where only 3 patients required antibiotics compared to 12 in the conventional group. This finding is clinically significant, especially in the context of growing concerns over antibiotic resistance. Laser irradiation has demonstrated broad-spectrum bactericidal effects against oral pathogens including *Porphyromonas gingivalis*, *Prevotella intermedia*, and *Fusobacterium nucleatum*, which are commonly associated with pericoronitis [21,22]. Thus, the need for systemic antimicrobial therapy may be mitigated in laser-treated cases.

Importantly, recurrence rates were lower in the laser group, with only 2 cases experiencing pericoronitis within the follow-up period, compared to 5 in the conventional group. Although the sample size is limited, this difference suggests that the enhanced debridement and sterilization capabilities of the laser may contribute to a more definitive management of the condition. Previous studies have also reported reduced recurrence following laser operculectomy due to the thorough removal of inflamed tissue and microbial load [23].

Intraoperatively, laser procedures offer significant advantages such as minimal bleeding and excellent visibility due to the hemostatic effect of the laser. Additionally, the procedure can be performed without sutures, enhancing patient comfort and reducing chairside time [24]. These factors not only improve the clinical workflow but also lead to greater acceptance and satisfaction among patients.

Nevertheless, despite its advantages, laser therapy does require a learning curve, operator training, and significant investment in equipment, which may limit its immediate adoption in all clinical settings. Cost-effectiveness analyses and long-term comparative studies are warranted to better position Er,Cr:YSGG lasers in routine dental practice.

From a biological perspective, the Er,Cr:YSGG laser operates at 2780 nm, a wavelength that optimally exhibits strong affinity for water and hydroxyapatite. This makes it particularly effective for both soft and hard tissue applications. The laser's micro-explosive effect allows for precise tissue ablation while maintaining thermal control, unlike diode or CO₂ lasers, which operate primarily via thermal coagulation and carry a higher risk of collateral tissue damage [6,10,25].

The present study's retrospective nature does introduce certain limitations. The availability of VAS pain scores was dependent on proper documentation, and potential confounding variables such as individual healing response, oral hygiene, or compliance were not uniformly controlled. Furthermore, the sample size, although sufficient for preliminary comparison, could restrict the broader applicability of the findings. Further research involving larger sample sizes and well-designed prospective randomized controlled trials is necessary to confirm these results [26-28].

Despite these limitations, the current evidence indicates that Er,Cr:YSGG laser-assisted operculectomy is not only effective but may offer superior clinical benefits compared to traditional surgical approaches. Its ability to reduce pain, inflammation, and antibiotic use while promoting faster recovery aligns well with the principles of minimally invasive dentistry and patient-centered care.



5. Conclusion

Er,Cr:YSGG laser-assisted operculectomy appears to be a clinically effective and patient-friendly alternative to conventional scalpel surgery for the management of pericoronitis. This study demonstrated reduced postoperative pain, faster healing, decreased recurrence, and lower antibiotic dependency in the laser-treated group. While additional randomized trials are needed to confirm these findings, the present evidence supports the integration of Er,Cr:YSGG lasers into the treatment protocol for soft tissue management in pericoronitis.

References

- Mavrogiannis M, Ellis JS, Thomason JM, Seymour RA. The management of pericoronitis in primary care. *Br Dent J.* 2006;200(1):11–5.
- Peterson LJ. *Contemporary Oral and Maxillofacial Surgery.* 6th ed. Elsevier; 2013.
- Seymour RA, Heasman PA. Pathogenesis and clinical features of pericoronitis. *Br Dent J.* 1988;165(1):9–11.
- Yamalik N, Bozkaya S. Clinical evaluation of pericoronitis and oral hygiene status of third molar region. *J Nihon Univ Sch Dent.* 1996;38(2):93–100.
- Meechan JG, Seymour RA. The use of antibiotics in the management of pericoronitis. *Br Dent J.* 1993;175(6):213–6.
- Cobb CM. Clinical significance of non-surgical periodontal therapy: An evidence-based perspective. *J Clin Periodontol.* 2002;29 Suppl 2:6–16.
- Aoki A, Mizutani K, Schwarz F, et al. Periodontal and peri-implant wound healing following laser therapy. *Periodontol.* 2015;68(1):217–69.
- Gojkov-Vukelic M, Hadzic S, Pasic E. Application of Er,Cr:YSGG laser in soft tissue oral surgery: Clinical experience. *Acta Inform Med.* 2013;21(4):237–240.
- Rizoiu IM, Eversole LR, Kimmel AI. Effects of a superpulsed Er,Cr:YSGG laser on soft tissue oral pathology. *Oral Surg Oral Med Oral Pathol.* 1996;82(4):386–395.
- Keller U, Hibst R. Effects of Er:YAG laser in caries treatment: A clinical pilot study. *Lasers Surg Med.* 1997;20(1):32–38.
- Parker S. Introduction, history of lasers and laser light production. *Br Dent J.* 2007;202(1):21–31.
- Moritz A, Schoop U, Goharkhay K, et al. Treatment of periodontal pockets with a diode laser. *Lasers Surg Med.* 1998;22(5):302–311.
- Rossmann JA. Erbium lasers: technology, evidence, and clinical applications. *Compend Contin Educ Dent.* 2010;31(8):624–628.
- Romanos GE, Nentwig GH. Diode laser (980 nm) in oral and maxillofacial surgical procedures: Clinical observations. *J Clin Laser Med Surg.* 1999;17(5):193–197.
- Coleton S, Novak MJ. Application of Er,Cr:YSGG laser in soft tissue management. *J Periodontol.* 2006;77(3):393–400.
- Parker S. Clinical applications of lasers in periodontal therapy. *Br Dent J.* 2007;202(3):173–181.
- Romeo U, Libotte F, Palaia G, Tenore G, Galanakis A, Annibali S. Er:YAG and Er,Cr:YSGG lasers in oral soft tissue surgery: A 20-year literature review. *J Lasers Med Sci.* 2020;11(1):17–23.
- Hibst R, Keller U. Er:YAG laser for dentistry: The status of research and clinical application. *Int Dent J.* 1995;45(4 Suppl 1):323–333.
- Chou TH, Machida J, Yang LC. Effect of erbium lasers on wound healing. *J Biomed Opt.* 2011;16(8):088002.
- Li X, Liu X, Zhang L, et al. Laser therapy promotes collagen remodeling and reduces inflammation in healing of skin wounds. *Lasers Med Sci.* 2015;30(1):233–240.
- Euzebio Alves VT, et al. Antimicrobial effect of Er,Cr:YSGG laser on subgingival biofilm:



- Clinical and microbiological evaluation. *J Periodontol.* 2011;82(3):452–461.
22. Rizioiu IM, et al. Bactericidal effects of a superpulsed Er,Cr:YSGG laser on oral microorganisms. *J Periodontol.* 1998;69(11):1318–1322.
 23. Aras MH, Güngörmüş M. Comparison of the effects of conventional surgery and diode laser surgery in the treatment of pericoronitis. *Oral Surg Oral Med Oral Pathol Oral Radiol Endod.* 2009;107(5):e1–e5.
 24. Coluzzi DJ, Parker SP. Lasers in dentistry. *Dent Clin North Am.* 2011;55(1):1–xi.
 25. Bornstein ES, Miron RJ, Bosshardt DD. Evidence-based use of lasers in dentistry: A literature review. *J Oral Laser Appl.* 2020;20(2):1–14.
 26. Soundarajan S, Rajasekar A. Comparative evaluation of combined efficacy of methylene blue mediated antimicrobial photodynamic therapy (a-PDT) using 660 nm diode laser versus Erbium-chromium-yttrium-scandium-gallium-garnet (Er, Cr: YSGG) laser as an adjunct to scaling and root planing on clinical parameters in supportive periodontal therapy: A randomized split-mouth trial. *Photodiagnosis and photodynamic therapy.* 2022 Sep 1;39:102971.
 27. Shah MS, Kareem NA, Gopal MA. Quantification of operculectomy procedures performed using laser versus surgical method-an institutional based study. *Int J Pharm Res.* 2021 Jan 1;13(1):1596-600.
 28. Navya PD, Ramamurthy J. A Comparison of conventional and laser assisted desensitization techniques for treating dentinal hypersensitivity. *Journal of Advanced Pharmaceutical Technology & Research.* 2022 Nov 1;13