

Immunohistochemical Approach to the Study of Pulmonary Neuroendocrine Tumors

Sohail Anwar¹, Sheeba Ishtiaq², Rajia Liaqat³, Amna Rehman⁴, Nadeem Reyaz⁵, Sana Haseeb Khan⁶

¹Associate Professor, Department of Pulmonology, University of Lahore Teaching Hospital, Lahore, Pakistan

²Assistant Professor, Department of Histopathology, Gulab Devi Hospital, Lahore, Pakistan

³Professor, Department of Histopathology, Gulab Devi Hospital, Lahore, Pakistan

⁴Post graduate trainee, Department of Histopathology, Gulab Devi Hospital, Lahore, Pakistan

⁵Associate Professor, Department of Histopathology, Gulab Devi Hospital, Lahore, Pakistan

⁶Assistant Professor, Department of Pathology, Al Aleem Medical College, Lahore, Pakistan

ABSTRACT

Background: Tumors that arise from neuroendocrine cells can present throughout the body, most commonly in the gastrointestinal tract and pulmonary systems. Neuroendocrine tumors (NETs) of the lungs account for about 25% of primary lung cancers, as well as 20–25% of primary NETs

Objective: To analyze the immune-histochemical aspects of Neuro-endocrine Tumors and apprise the reactivity of various immune-histochemical markers.

Methodology: This cross-sectional study was conducted in Pathology Department of Gulab Devi Hospital Lahore from January 2021 to December 2021. Total 112 patients with pulmonary NETs cases diagnosed with medical records patients data, clinical features and radiologic images were obtained and both genders with CT scan findings of lung mass were included in the study. Data was entered and analyzed in SPSS. Gender, diagnosis, techniques etc. were presented as frequency and percentage. Age was presented as mean and SD.

Results: The mean age was 45.2±12.1 years. The age range between 20 to 60 years. There were 96(86%) male and 16(14%) female. Typical carcinoid was prevailing in young age group while small cell neuro-endocrine tumor was dominant in older patients. Most of the samples were collected using bronchial biopsy 86(77%), 18(16%) of the samples were collected by CT guided biopsy while 7(6%) were collected by ultrasound guided biopsy and 1(1%) by surgical resection. Patients were diagnosed as small cell lung carcinoma 96(86%), typical carcinoid was the second most common diagnosis 10(9%), large cell lung carcinoma was 4(3.0%) and atypical carcinoid tumor was seen in 2(2%) in cases.

Conclusion: SCLC was found to be the predominant pulmonary NET. Chromogranin is less sensitive than synaptophysin, raised Ki67 and TTF1 demarcates SCLC from carcinoid particularly in minute biopsy with obscure morphology.

Key words: Immunohistochemistry, Neuroendocrine carcinoma, Small cell lung carcinoma.

Authors' Contribution:

^{1,2}Conception; Literature research;

³manuscript design and drafting; ^{4,5}Critical analysis and manuscript review; ⁶Data analysis; Manuscript Editing.

Correspondence:

Sheeba Ishtiaq

Email: Sheeba_i@yahoo.com

Article info:

Received: September 15, 2022

Accepted: March 30, 2023

Cite this article. Anwar S, Ishtiaq S, Liaqat R, Rehman A, Reyaz N, Khan S H.

Immunohistochemical Approach to the Study of Pulmonary Neuroendocrine Tumors. J

Islamabad Med Dental Coll. 2023; 12(1):11-16

DOI: <https://doi.org/10.35787/jimdc.v12i1.907>

Funding Source: Nil

Conflict of Interest: Nil

Introduction

Tumors that arise from neuroendocrine cells can present throughout the body, most commonly in the

gastrointestinal tract and pulmonary systems. Neuroendocrine tumors (NETs) of the lung account for about 25% of primary lung cancers, as well as 20–25% of primary NETs.^{1,2} Approximately 20% of lung cancers are complimented by Pulmonary (NETs).³ The frequency of Pulmonary NETs in modern times has expanded significantly (6% per year) partially due to early diagnostic imaging most however are still discovered accidentally.⁴

Currently, NETs comprise between 0.5 and 2% of all malignancies.⁵ Both the incidence and prevalence of neuroendocrine tumors have increased linearly. NETs are considered rare tumours. Data collected over the past 20 years in several European countries and the USA estimated an incidence of 1–5 per 100,000 inhabitants, with an increasing tendency over the past years.⁶ The diagnosis of lung NETs remains challenging due to the variable presentation of patients. Depending on the location of the tumor, patients may be asymptomatic or have symptoms that are very non-specific, making a definitive diagnosis difficult.⁷ Currently, curative treatment depends on the tumour location and generally consists of the resection of the tumour and adjacent tissue that can be accompanied with adjuvant chemotherapy in intermediate and high grade NETs^{8,9} other treatment options for the control of symptoms are somatostatin analogues or the use of targeted therapies

Pulmonary neuroendocrine tumors encompass a wide array of cancers ranging from the well-demarcated typical carcinoid tumor, to the intermediate-grade atypical carcinoid tumor, to the high-grade neuroendocrine carcinomas comprised of large and small cell tumors.¹⁰ Diagnosis is fundamentally established on a cluster of distinct physical aspects such as cytological appearance, mitotic activity, necrosis and architecture.¹¹ Categorical diagnosis of large cell tumor and atypical carcinoid is exacting on minute biopsies. The growth in immunohistochemistry in the diagnosis is convenient and now regularly vital in the diagnosis of Pulmonary NETs. The discernment of large and

small cell tumor is critical, as they are in high-grade variety, as the treatment options of both these tumors bifurcate.⁵

The aim of the study was to find the immunohistochemical assessment of Neuroendocrine Tumors and to apprise the reactivity of various immunohistochemical markers used in our institute for diagnosis Pulmonary NETs.

Methodology

This cross-sectional study was conducted in Pathology and Pulmonary department of Gulab Devi Hospital, Lahore from January 2021 to December after approval from Institutional review board. Sample size was 112, which was calculated with 5% level of significance and 5% margin of error by taking expecting percentage of endocrine tumors

Inclusion Criteria: Pulmonary NETs cases diagnosed with medical records patients data, clinical features and radiologic images were obtained and both genders with CT scan findings of lung mass were included in the study.

Exclusion Criteria: Diffuse idiopathic pulmonary neuro-endocrine cell hyperplasia and tumor let were excluded in the study.

World Health Organization (WHO) classification of pulmonary NETs was the ground for classification of lung tumors. Fully automated immunostainer (Xmatrx Elite; Biogenex) was used for IHCs. CD 56, chromogranin, synaptophysin, thyroid transcription factor-1 (TTF-1), ki67, napsin-A and p-40 were the array of tumor markers used for IHC. Patterns of immune-histochemical stains were Membranous for CD56, cytoplasmic for synaptophysin and chromogranin, nuclear staining for TTF-1 plus p40 and granular staining for napsin-A. Ki67 labeling index of 2% and 10 % was considered demarcation for typical and atypical carcinoids, respectively.

Data were entered and analyzed in SPSS. Gender, Diagnosis, techniques etc. were presented as

frequency and percentage. Age was presented as mean and SD.

Results

Total 112 patients were included in the study. The mean age was 45.2+12.1 years. With age range between 20 to 60 years of age. There were 96(86%) male and 16(14%) female. Typical carcinoid was prevailing in young age group while small cell neuroendocrine tumor was dominant in older patients. Most of the samples were collected using bronchial biopsy 86(77%), 18(16%) of the samples were collected by CT guided biopsy while 7(6%) were collected by ultrasound guided biopsy and 1(1%) by surgical resection(Figure: 1) Patients were diagnosed as small cell lung carcinoma 96(86%), typical carcinoid was the second most common diagnosis 10(9%), large cell lung carcinoma was 4(3.0%) and atypical carcinoid tumor was 2(2%). (Table: 1)

Morphologically Small cell neuroendocrine tumor displayed sheets and nests of little oval-to-round cells with sparse cytoplasm, apoptotic remains, necrosis, recurring mitosis, nuclear molding, increased N:C ratio and exquisitely granular chromatin. The typical carcinoid largely had pseudoglandular, organoid and trabecular pattern. There were homogenous cells with subtle granular nuclear chromatin and inconspicuous nucleoli. Necrosis was not observed and mitosis was than 2 per HPF. There was similar growth pattern in typical and atypical carcinoids. They were demarcated by the existence of necrosis and/mitosis (2–10 per 10 HPF). Necrosis observed in 50% atypical carcinoid cases.

The typical carcinoid predominantly had organoid, trabecular, and pseudoglandular pattern. Spindling of the cells was noted in one case. The cells were uniform with finely granular nuclear chromatin and inconspicuous nucleoli. Mitosis was <2 per 10 HPF and necrosis were not seen. (Figure : 2)

The sensitivity of the various markers is shown in table 2. CD 56 was 91(94.8%) sensitive in small cell cancer followed by synaptophysin which was 87(90.6%) sensitive while 73(76.0%) sensitive was chromogranin and TTF1 was 58(60.4%) sensitive. For typical carcinoids CD56, Chromogranin, Synaptophysin were all 10(100%) sensitive while for atypical carcinoids CD56, Chromogranin, Synaptophysin and TTF 1 were all 4(100%) sensitive. (Table: 2)

		Frequency (%)
Age	Mean+SD	45.2+12.1
Gender	Male	96(86)
	Female	16(14)
Diagnosis of Biopsy	Small Cell Neuroendocrine	96(86)
	Typical Carcinoid Tumor	10(9.0)
	Atypical tumor	4(3.0)
	Large Cell Neuroendocrine	2(2.0)

Histopathology	IHC Marker	Frequency (%)
Small Cell Lung Carcinoma	CD56	91(94.8)
	CHROMOGRANIN	73(76.0)
	SYNAPTOPHYSIN	87(90.6)
	TTF 1	58(60.4)
Typical Carcinoid	CD56	10(100)
	CHROMOGRANIN	10(100)
	SYNAPTOPHYSIN	10(100)
Atypical Carcinoid	CD56	4(100)
	CHROMOGRANIN	4(100)
	SYNAPTOPHYSIN	4(100)
	TTF 1	4(100)
Large Cell Lung Carcinoma	CD56	2(100)
	CHROMOGRANIN	2(100%)

	SYNAPTOPHYSIN	2(100%)
	TTF 1	1(50%)

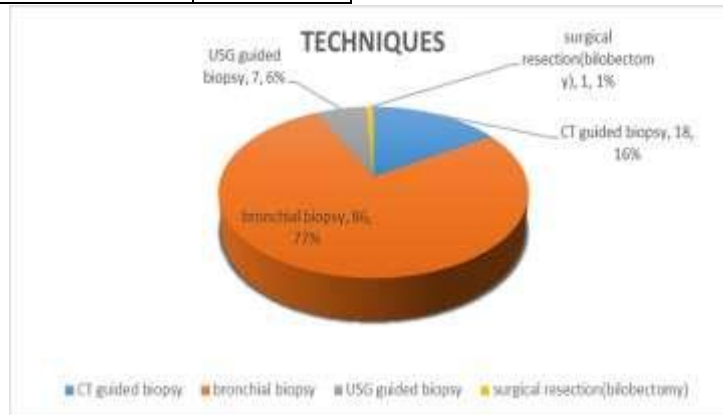


Figure:1 Techniques of Biopsies

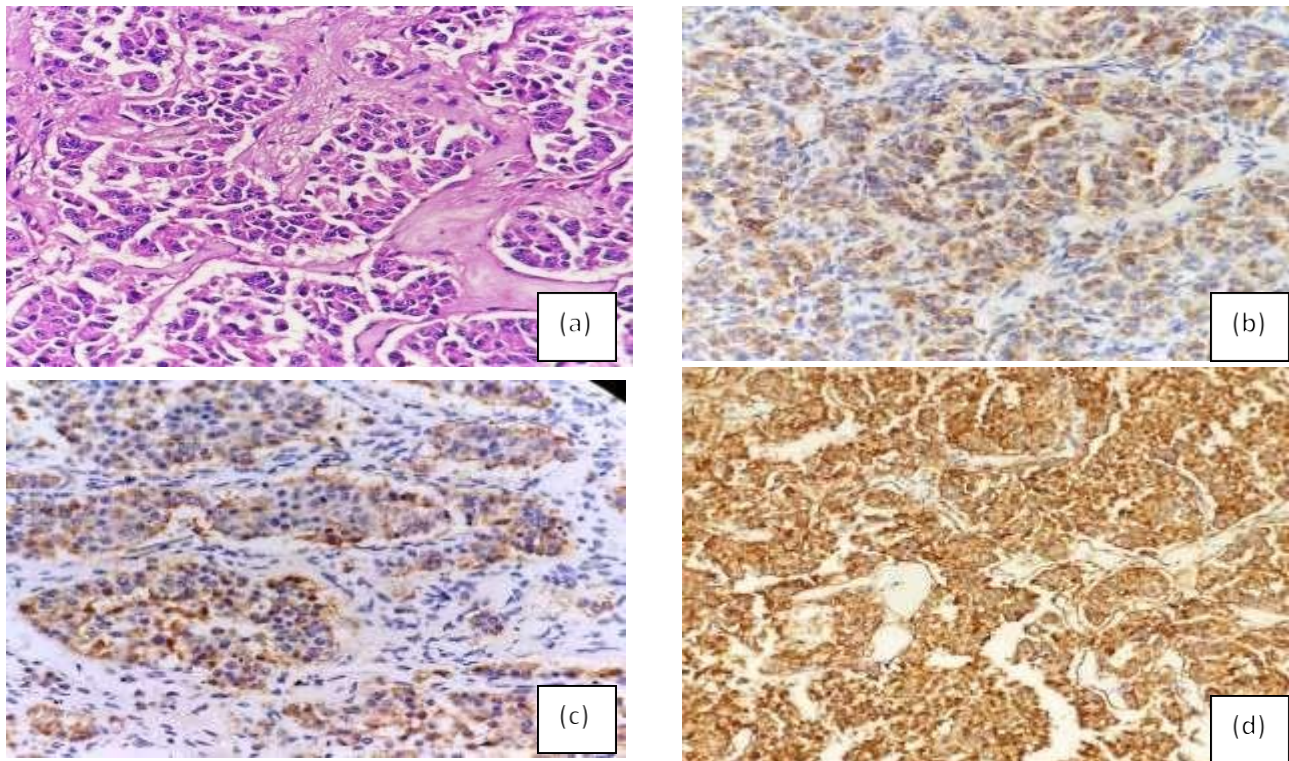


Figure 2: Typical Carcinoid **a.** Sheets of monomorphic cells with uniform nuclei and hyperchromatism showing positivity for **b.** Chromogranin **c.** Synaptophysin **d.** CD56

Discussion

Pulmonary neuro-endocrine tumors represent a morphologic spectrum of tumors from the well-differentiated typical carcinoid tumor, to the intermediate-grade atypical carcinoid tumor, to the

high-grade neuro-endocrine carcinomas comprising of small-cell carcinoma and large-cell neuroendocrine carcinoma. The addition of immunohistochemistry in diagnostics is helpful and often essential, especially in the classification of large-cell neuroendocrine carcinomas.¹² CD56 chromogranin and synaptophysin were 100%

affirmative in typical carcinoid and atypical carcinoid. In small cell cancer CD56, Chromogranin and Synaptophysin expression was 94.8%, 76.0% and 90.6% respectively. CD56 was more sensitive for small cell tumors in typical carcinoid, TTF-1 was negative in all cases. In atypical carcinoid 100 % cases were positive. TTF-1 positivity was 60% in SCLC. P-63 staining was done for all in all the 96.0 cases of SCLC, 14 were positive showing squamoid component. Napsin-A negativity ruled out adenocarcinoma in all cases.

Pulmonary neuro endocrine tumors constitute 25% of all neuro-endocrine cancers.¹³ There are 20% small cell neuro-endocrine tumors, 3.0% are large cell tumor, 2.0% and 0.2% are the carcinoids (typical and atypical) respectively.^{14,15} The first two delegated as poorly differentiated, and the last two grouped as well and intermediate differentiated cancers, respectively. Combined, these four deviations have been classified as a separate division under NETs in lung tumors classification of WHO 2015.¹⁶

Furthermore, both types of lung carcinoids are still cited as pulmonary carcinoid tumors, while elsewhere like gut, the term well-differentiated NETs is now being used for them. Studies have demonstrated an increasing frequency of carcinoid in this century while there is a fall in small cell lung cancers diagnosis.¹⁷ The carcinomas emerge from Kulchitzky cells occurring in the bronchial mucosa. There is a substantial predisposition in elderly and an increased risk in smokers in small cell and large cell tumors as compared to carcinoid tumors.¹⁵ The mean age in small cell neuro-endocrine tumors patients was a decade older with increased male prevalence in comparison to carcinoid in the present study. CD56, chromogranin and synaptophysin are used to certify the NET character. TTF-1 is compulsory to subtype variants of NET, it is fairly positive in 70%–90% of SCLC cases.^{3,12} Unlike pulmonary adenocarcinoma, it is not a site-specific marker as TTF-1 expression is 20%–80% in of extra

pulmonary small cell tumor such as gastrointestinal tract, cervix, prostate and bladder.¹⁸

Pasala et al identified a Ki67 index mean of 53.9% for SCLC, 6.6% for atypical and 1.4% for typical carcinoid which is in accordance with this study.¹⁹ Ki67 demarcates large and small cell tumors from carcinoid as small cell tumor shows an immense proliferative index. It is notably of considerable aid in minute biopsies with crushed appearance. It is not dependable in discriminating atypical from typical carcinoid in minute biopsies. In 2015, pulmonary NETs classification by WHO submitted advisement on Ki67 labeling index which includes 5% for typical, up to 20% for atypical carcinoid and 50 to 100% for SCLC.²⁰ Ki67 is not considered as a diagnostic benchmark in classification of lung NETs as there isn't sufficient evidence.²¹ However addition of Ki67 in IHC panel assists in individualizing treatment by oncologist.²²

Conclusion

SCLC was the predominant pulmonary NET. Chromogranin is less sensitive than synaptophysin, raised Ki67 and TTF1 demarcates SCLC from carcinoid particularly in minute biopsy with obscured morphology.

References

1. Xu Z, Wang L, Dai S, Chen M, Li F, Sun J, et al. Epidemiologic trends of and factors associated with overall survival for patients with gastroenteropancreatic neuroendocrine tumors in the United States. 2021;4(9):e2124750-e. doi: [10.1001/jamanetworkopen.2021.24750](https://doi.org/10.1001/jamanetworkopen.2021.24750)
2. Petursdottir A, Sigurdardottir J, Fridriksson BM, Johnsen A, Isaksson HJ, Hardardottir H, et al. Pulmonary carcinoid tumours: Incidence, histology, and surgical outcome. A population-based study. 2020;68:523-9. doi: [10.3892/ol.2020.11347](https://doi.org/10.3892/ol.2020.11347)
3. Uprety D, Halfdanarson TR, Molina JR, Leventakos KJ, et al. Pulmonary Neuroendocrine Tumors: Adjuvant and Systemic Treatments. 2020;21:1-19. PMC8394158

4. Cives M, Strosberg JRJ*Cacjfc*. Gastroenteropancreatic neuroendocrine tumors. 2018;68(6):471-87. . doi: 10.3322/caac.21493.
5. Darbà J, Marsà AJ*Bc*. Exploring the current status of neuroendocrine tumours: a population-based analysis of epidemiology, management and use of resources. 2019;19(1):1-7. doi: 10.1186/s12885-019-6412-8.
6. Hallet J, Law CHL, Cukier M, Saskin R, Liu N, Singh SJ*C*. Exploring the rising incidence of neuroendocrine tumors: a population-based analysis of epidemiology, metastatic presentation, and outcomes. 2015;121(4):589-97. doi: 10.1002/cncr.29099.
7. Tanaka H, Del Giglio AJ*e*. International trends in pulmonary neuroendocrine cancer studies: a scientometric study. 2022;20. doi: 10.31744/einstein_journal/2022RW0113. eCollection 2022.
8. Falconi M, Eriksson B, Kaltsas G, Bartsch D, Capdevila J, Caplin M, et al. ENETS consensus guidelines update for the management of patients with functional pancreatic neuroendocrine tumors and non-functional pancreatic neuroendocrine tumors. 2016;103(2):153-71. doi: 10.1159/000443171
9. O'Toole D, Kianmanesh R, Caplin MJ*N*. ENETS 2016 consensus guidelines for the management of patients with digestive neuroendocrine tumors: an update. 2016;103(2):117-8. doi: 10.1159/000443169.
10. Derks JL, Rijnsburger N, Hermans BC, Moonen L, Hillen LM, von der Thüsen JH, et al. Clinical-pathologic challenges in the classification of pulmonary neuroendocrine neoplasms and targets on the horizon for future clinical practice. 2021;16(10):1632-46. doi: 10.1016/j.jtho.2021.05.020.
11. Derks JL, Leblay N, Lantuejoul S, Dingemans A-MC, Speel E-JM, Fernandez-Cuesta LJ*JoTO*. New insights into the molecular characteristics of pulmonary carcinoids and large cell neuroendocrine carcinomas, and the impact on their clinical management. 2018;13(6):752-66. doi: 10.1016/j.jtho.2018.02.002.
12. Borczuk ACJ*Sp*. Pulmonary neuroendocrine tumors. 2020;13(1):35-55. doi: 10.1016/j.path.2019.10.002.
13. Volante M, Mete O, Pelosi G, Roden AC, Speel EJM, Uccella SJ*Ep*. Molecular pathology of well-differentiated pulmonary and thymic neuroendocrine tumors: what do pathologists need to know? 2021;32:154-68.
14. Wang J, Ye L, Cai H, Jin MJ*JoC*. Comparative study of large cell neuroendocrine carcinoma and small cell lung carcinoma in high-grade neuroendocrine tumors of the lung: a large population-based study. 2019;10(18):4226. DOI: 10.7150/jca.33367
15. Rekhtman NJMP. Lung neuroendocrine neoplasms: recent progress and persistent challenges. 2022;35(Suppl 1):36-50. doi: 10.1038/s41379-021-00943-2.
16. Metovic J, Barella M, Pelosi GJM-MoEMO. Neuroendocrine neoplasms of the lung: A pathology update. 2021;14(4):381-5. DOI:[10.1007/s12254-021-00681-w](https://doi.org/10.1007/s12254-021-00681-w)
17. Yoon JY, Sigel K, Martin J, Jordan R, Beasley MB, Smith C, et al. Evaluation of the prognostic significance of TNM staging guidelines in lung carcinoid tumors. 2019;14(2):184-92. doi: 10.1016/j.jtho.2018.10.166
18. Wu H, Du J, Li H, Li Y, Zhang W, Zhou W, et al. Aberrant expression of thyroid transcription factor-1 in meningeal solitary fibrous tumor/hemangiopericytoma. 2021;38:122-31. doi: 10.1007/s10014-021-00395-1
19. Pasala UJS, Hui M, Uppin SG, Kumar NN, Bhaskar K, Paramjyothi GJL*ooICS*. Clinicopathological and immunohistochemical study of pulmonary neuroendocrine tumors—A single-institute experience. 2021;38(2):134. doi: 10.4103/lungindia.lungindia_482_19.
20. Travis WD, Brambilla E, Burke AP, Marx A, Nicholson AGJ*JoTO*. Introduction to the 2015 World Health Organization classification of tumors of the lung, pleura, thymus, and heart. 2015;10(9):1240-2.
21. Pelosi G, Pattini L, Morana G, Fabbri A, Faccinnetto A, Fazio N, et al. Grading lung neuroendocrine tumors: controversies in search of a solution. 2017;32(3):223-41. DOI:[10.14670/HH-11-822](https://doi.org/10.14670/HH-11-822)
22. Naheed S, Holden C, Tanno L, Jaynes E, Cave J, Ottensmeier CH, et al. The utility of Ki-67 as a prognostic biomarker in pulmonary neuroendocrine tumours: protocol for a systematic review and meta-analysis. 2019;9(8):e031531. DOI:[10.1136/bmjopen-2019-031531](https://doi.org/10.1136/bmjopen-2019-031531)