

Management of Fixed Dislocation of the Patella

Casey M. Imbergamo¹; Ryan P. Coene, MS²; Matthew D. Milewski, MD²

¹Rutgers Robert Wood Johnson Medical School, New Brunswick, NJ; ²Division of Sports Medicine, Department of Orthopaedic Surgery, Boston Children's Hospital, Boston, MA

Abstract: Congenital dislocation of the patella is a rare disorder present at birth which manifests as a permanent and irreducible patella fixed on the lateral aspect of the femoral condyle. Congenital dislocation of the patella is frequently found in syndromic patients with a flexion contracture at the knee, genu valgum, foot deformity and external tibial torsion. Other syndromic patients with habitual or obligate dislocation may also develop a fixed position laterally with time. Surgical correction for fixed patella dislocation is the only definitive treatment for this condition and typically includes lateral release, medial stabilization, distal patellar tendon realignment, and proximal extensor lengthening if needed. Outcomes following surgical correction are generally satisfactory, with an improvement in function, range of motion, and quality of life for patients. The aim of this paper is to review the current understanding of fixed dislocation of the patella and provide an updated overview of the diagnosis and to outline a surgical strategy according to the different quadrants of knee pathology.

Key Concepts:

- Congenital dislocation is a fixed lateral dislocation of the patella noted at birth and is associated with various syndromes. Affected limbs can have genu valgum, flexion contracture at the knee, foot deformity, and external tibial torsion.
- Patients with habitual or obligate dislocation in which the patella dislocates and relocates spontaneously with flexion and extension of the knee may also become fixed with time.
- Imaging with plain radiographs, ultrasonography, or MRI can be essential in the diagnosis and preoperative planning for this condition.
- Surgical treatment typically involves lateral release to allow for centralization of the patella, medial tensioning for stability, distal medial realignment of the patellar tendon, and proximal lengthening of the extensors if needed.
- When implementing the appropriate surgical techniques, outcomes for this condition are typically satisfactory with improved function, range of motion, pain, and quality of life.

Introduction

Congenital dislocation of the patella is a rare condition presenting at birth in children with a wide variety of disorders and which manifests as a permanent and irreducible patella fixed on the lateral aspect of the femoral condyle. It is frequently associated with a

flexion contracture at the knee, genu valgum, foot deformity and external tibial torsion (Figure 1). This condition is to be contrasted with habitual dislocation, also referred to as obligate dislocation of the patella, in which the patella dislocates and relocates spontaneously

with flexion and extension of the knee. With time it can be difficult to reduce obligate dislocations of the patella and these can become fixed similar to those with congenital dislocations. The aim of this review is to provide an updated and comprehensive overview of the etiology, clinical presentation, pathophysiology, imaging, and treatment of fixed dislocation of the patella.

Etiology and Epidemiology

Congenital dislocation of the patella is an exceedingly rare condition and the prevalence is currently not known.¹ In this condition, the patella is fixed on the lateral femoral condyle at birth (cannot be centralized in the knee in extension) and is accompanied by severe lateral soft tissue tightness and flexion contracture. Habitual dislocation is a condition in which the patella dislocates from its normal position in the trochlear groove spontaneously with flexion (dislocated) and extension (reduced) of the knee and is associated with a lesser degree of lateral soft tissue tightness and quadriceps shortening. Habitual dislocation commonly presents after the child begins to walk and is typically a painless lateral dislocation. Some of these patients may develop a fixed lateral position of their patella with time.

Congenital dislocation of the patella is associated with arthrogryposis, chondrodysplasia punctata, dyschondrosteosis, chondro-osteodystrophy, thrombocytopenia-absent radius syndrome, fibular hemimelia, Larsen syndrome, and Williams-Beuren syndrome.^{1, 2, 3-12} Obligate dislocation is also associated with syndromes such as Down syndrome, Rubinstein-Taybi syndrome, nail-patella syndrome, Kabuki syndrome, and Ellis-Van Crevald syndrome. In these later syndromes, the patellar dislocation may occur after birth and can become permanent and irreducible during childhood.¹³ Regardless of the presence any one of these aforementioned syndromes, there should be suspicion for congenital dislocation of the patella if a patient's clinical presentation includes flexion contracture at the

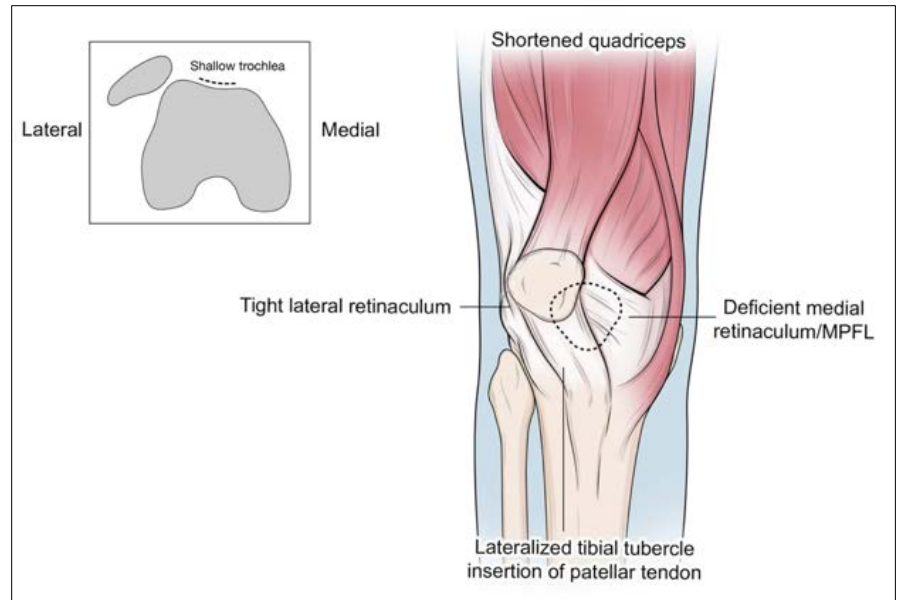


Figure 1. Depiction of the anatomic abnormalities which may be present in patients with fixed dislocation of the patella

knee, genu valgus, foot deformity, external tibial torsion, or delayed walking.^{2, 13} In apparently normal patients with congenital dislocation of the patella, it may be, at least in some cases reports, heritable. Given the pattern of the multi-generational history obtained in these case reports, it is likely that this condition is inherited in an autosomal dominant fashion.^{14, 15}

The etiology of congenital dislocation of the patella is due to a defect in embryonic development, with the severity of its structural defects being owed to its prenatal onset.¹⁶ Stanisavljevic et al. proposed that the pathogenesis of this condition is due to the malrotation of the quadriceps myotome during embryonic development, specifically between weeks 8 and 10. During normal development, the quadriceps begins laterally and sequentially rotates anteriorly, and the failure of this migration is thought to be the cause of congenital dislocation of the patella. This malrotation of the extensor apparatus, patella included, leads to a number of anatomical deformities.¹⁷ Ghanem et al. described the anatomical abnormalities present in congenital dislocation of the patella through a cadaveric study. It was found that the quadriceps muscle was short,

malformed, and laterally displaced, acting as a knee flexor. The patella was underdeveloped, dislocated superiorly and posteriorly, and adherent to the anterolateral aspect of the femur just above the lateral condyle. The vastus lateralis and rectus femoris were displaced on the lateral aspect of the femur, with the vastus lateralis adhered to the iliotibial (IT) band and tensor fascia lata. Additionally, the IT band was abnormal, with a thick tubular shape rather than its usual flat profile. A rotatory femorotibial displacement was also found, with proximal tibial epiphyseal metaphyseal lateral torsion.¹⁶

Clinical Presentation

Congenital dislocation of the patella is typically identified at birth; delayed diagnosis can occur and is due to low suspicion of the disorder, lack of patellar visibility on plain radiographs (normal ossification is at approximately three to five year), and difficulty in palpating the hypoplastic patella in the lateral position.^{2, 13} In some patients, the flexion contracture at the knee is so severe that extension is not possible as the quadriceps function as a knee flexor, preventing patients from walking independently.² However, in milder cases, patients are able to extend the knee and can ambulate with only a mild impairment in gait.¹³ It has been reported that it is possible for patients with this condition to be pain-free and have no limitations in daily life, which can lead to delayed diagnosis during adulthood.^{18, 19} Different types of foot pathology can be seen with this condition and include calcaneovalgus foot deformity, congenital vertical talus, and talipes equinovarus.¹³ Regarding the laterality of this condition, numerous authors have reported that it can present either unilaterally or bilaterally.^{2, 12, 19} Sever et al. reported that upon review of the literature, there were 36 reported cases of bilateral involvement and 45 cases of unilateral involvement.¹¹

When patellar dislocation occurs with each flexion-extension cycle of the knee, this is deemed habitual or obligate dislocation. The patella usually dislocates whenever the knee is flexed and spontaneously relocates

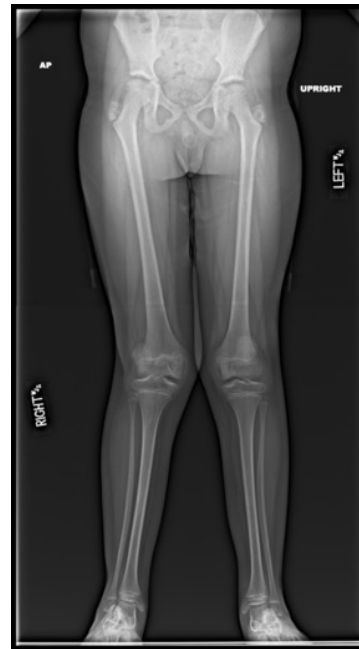

Figure 2. Anteroposterior standing hip to ankle X-ray in a patient with valgus deformity and right sided patellar dislocation.

with extension of the knee; however, the opposite can also occur.²⁰ An important physical finding of habitual dislocation is that if the patella is forcibly held in the midline, it is impossible to flex the knee more than 30–70°. Further flexion can only be attained if the patella is allowed to dislocate. This condition usually presents after the onset of ambulation and may manifest in children as dysfunction and instability of the knee, interfering with their ability to run. However, it is often times asymptomatic and may be noted incidentally on physical exam. When the diagnosis is delayed into adulthood, this condition may present as patellofemoral pain and weakness during running or climbing stairs, crepitus, and joint effusion.²⁰⁻²² When obligate contractures become fixed dislocation, lateral contractures, medial laxity, and genu valgum may also be present.^{13, 23} Increased knee valgus is due to excessive lateral quadriceps vector which leads to the patella being fixed laterally. The quadriceps gradually shorten as the knee loses relative length laterally when the knee assumes a valgus position and the patella becomes fixed.

Imaging

There are various imaging techniques to be implemented in the evaluation and management of fixed dislocation of the patella. Initial ossification of the patella typically

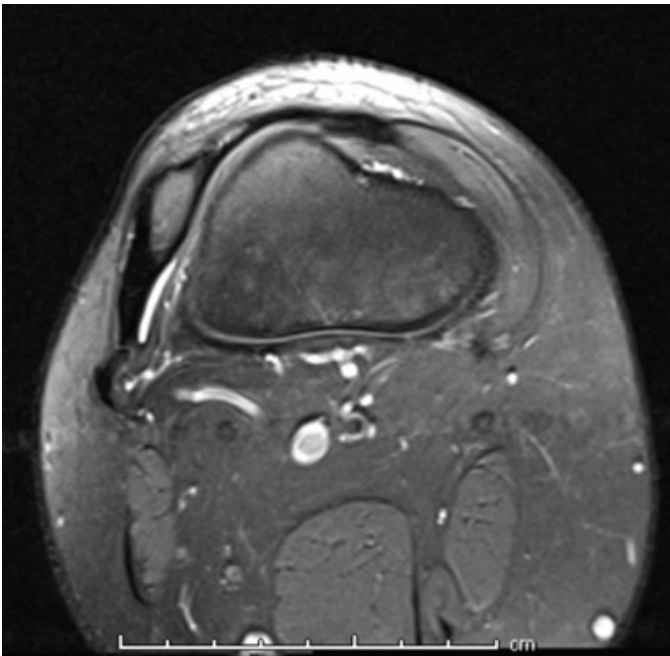


Figure 3. Axial T2 MRI of the right knee in a patient with a hypoplastic and fixed laterally displaced patella. Note the attenuated medial retinaculum and the thickened lateral retinaculum.

occurs between three and five years of age, however it has been noted that ossification is delayed in most cases of congenital dislocation.^{24, 25} In older children, lateral and skyline projections allow for visualization of the size, shape, and location of the patella. Skyline views are also used for evaluation of the condition of the trochlear groove and the degree of lateral femoral condyle dysplasia, which are important in preoperative planning and at follow-up. Anteroposterior radiographs can also be used to visualize the degree of lateral femoral condyle hypoplasia, as well as the severity of joint space narrowing and the position of the tibia relative to the femur.²⁵ An anteroposterior hips to ankle standing film should be ordered to assess the mechanical axis and angular deformities of the femur and tibia, as genu valgum is often associated with congenital dislocation of the patella²⁶ (Figure 2). Additionally, a bone age may be obtained to determine skeletal maturity of a patient.²⁷

In infants and young children, ultrasonography can be useful in evaluating the location of the non-ossified patella and to confirm the diagnosis of lateral

patellofemoral dislocation.¹³ On ultrasound, the congenitally dislocated patella appears as a homogenous, low echogenicity structure which has an elongated, somewhat rounded rectangular shape when viewed in the sagittal or coronal plane, and a rounded triangular shape in the transverse plane. Sonography can also be used to assess the overall anatomy of the knee joint, visualizing ligaments and their bony insertions. It can be implemented in dynamic examination, and the anatomic location of the patella in relation to the femur can be evaluated at various knee flexion angles.²⁵

Rarely, CT scan can be implemented for kinematic scanning in older children, in which the position of the patella in relation to the distal femur can be determined at varying degrees of knee flexion.^{28, 29} Of note, separating of cartilaginous structures from soft tissues and accurate definition of articular cartilage can be difficult without contrast. CT scan is not commonly implemented in cases of congenital dislocation of the patella as it uses ionizing radiation.²⁵

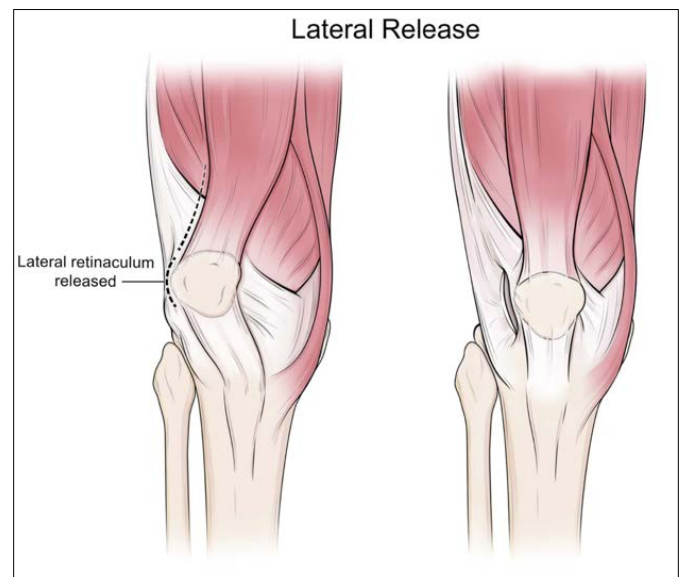

Figure 4. Depiction of lateral release of the patella in which the lateral retinaculum is incised

MRI is extremely valuable in the preoperative evaluation of patients with this condition, given its ability to image cartilage and joint structures with a high degree of accuracy.^{13, 30} It has been noted that T1-weighted proton

density, fast spin-echo T2-weighted images with fat saturation, and multiple planar gradient-recalled sequences have been utilized for evaluation of congenital dislocation of the patella (Figure 3). Thin sections should be used to avoid missing a hypoplastic patella and making a false diagnosis of patellar absence.²⁵ MRI can allow the surgeon to visualize the mal-rotated, thin and fibrotic quadriceps muscle with insertion of the patellar tendon, the hypoplastic dislocated patella, and the underdeveloped trochlea.^{13,25} Young children may require sedation in order to undergo MRI. However, the importance of MRI in preoperative evaluation can justify the use of sedation for this procedure.

Treatment

Definitive treatment of fixed dislocation of the patella requires surgical intervention in order to improve function and to prevent subsequent degenerative changes to the knee.^{13, 14, 19, 31} The strategies described below are used for congenital dislocations and habitual dislocators that are fixed. This approach is also used for the obligate dislocator that is not fixed. In the later instance, less extensive or fewer combinations of the procedures outlined below are usually sufficient.

The Quadrant Approach to Reconstruction: There have been several surgical techniques described to address this condition. These techniques include soft tissues procedures, bony procedures, or a combination of the two. It may be useful to approach the surgical management of this condition by categorizing the techniques into quadrants: medial, lateral, proximal, or distal to the patella. Each of these quadrants can be addressed in a variety of ways in order to realign and stabilize the patella. The overarching theme in the treatment of this condition involves lateral release to allow for centralization of the patella (Figures 4 and 5), medial plication or tensioning for stability, proximal lengthening of the extensors, and distal medial realignment of the patellar tendon. Additionally, guided growth or extra-physal osteotomies in skeletally immature patients and wedge or derotational

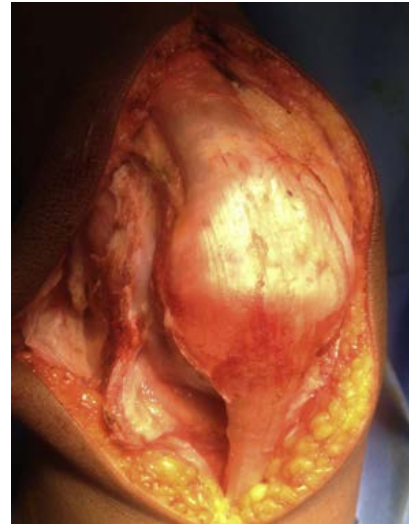

Figure 5. Lateral release to allow for centralization of the patella to its normal position in the trochlear groove

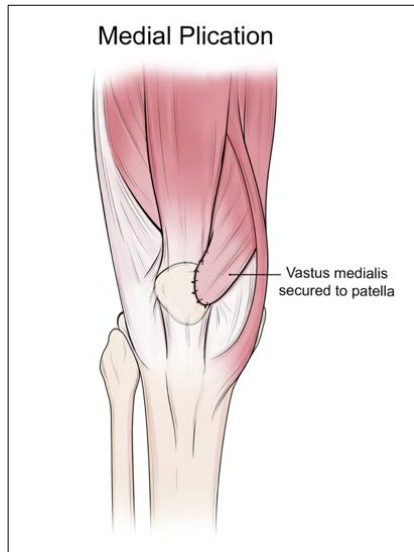
osteotomies, typically in skeletally mature patients, may be used to address valgus deformity or tibial torsion.

Lateral Quadrant

To address the lateral quadrant, there are a number of open techniques described in the literature (arthroscopic lateral release is not recommended in fixed or obligate dislocations). The procedure documented by Stanisavljevic et al. is one of the earliest described approaches to manage congenital dislocation of the patella and has been implemented and modified by many orthopaedists.¹⁷ Stanisavljevic et al. described an extensive lateral subperiosteal release in order to rotate the quadriceps and patella medially, placing them in an anatomic position.¹⁷ Lateral capsulotomy is a component of this procedure which appears to be almost universally implemented in order to allow for medialization of the patella, along with lateral retinaculum release.^{13, 20, 32-35} The same approach to the lateral quadrant has been documented by other surgeons with only minor modifications.^{11, 36} For example, Sever et al. described splitting the fascia lata rather than excising it as described in the original procedure, and Gordon et al. noted that the lateral dissection did not need to be extended as proximally as described by Stanisavljevic et al.^{11, 19, 36}

Other surgeons may also take slightly modified approaches for their lateral release. Ghanem et al. noted

Figure 6. Depiction of medial plication, utilized to apply tension medially and add stability to the patella



utilizing an extraperiosteal rather than subperiosteal release of the quadriceps from the femur, while dividing it from the lateral intramuscular septum to facilitate its medial rotation.³² A similar approach is reported by Wada et al., describing dividing the quadriceps from its fibrous adhesions to the iliotibial band and the lateral intermuscular septum, without stripping it extraperiosteally.¹⁴ The iliotibial band itself may also be released.^{35, 37} It has been noted that a complete release and realignment of the extensor mechanism is necessary for patients with congenital dislocation of the patella; however for patients with fixed or partial habitual dislocation, a less aggressive release can be utilized in order to realign the patella. The approach to surgical management must be individualized depending on the severity of the case.³⁷

In realigning the quadriceps and patella, a gap may be created on the lateral aspect of the realigned knee joint, which harvested fascia lata can be used to cover.¹⁷ Other surgeons have reported using grafts taken from the medial capsule to patch the lateral capsular defect and prevent synovial fluid leakage.¹³ Conversely, some surgeons reported that it was not necessary to close the lateral fascial window created by medialization of the patella.¹¹

Of note, arthroscopic lateral release is a technique which has been implemented in the treatment of patients with

recurrent patellar instability, in combination with procedures such as medial reefing, MPFL reconstruction, and distal realignment.^{38, 39} However, there have not been any documented cases in which arthroscopic lateral release has been implemented for congenital dislocation of the patella specifically. This is due to the extensive nature of the release required to centralize the patella in this condition and the small size of many of these pediatric knees. Open lateral release is preferred in the treatment of the fixed patellar dislocation.

Medial Quadrant

In the medial quadrant, the need to add stability to the realigned patella must be addressed. This can be done with medial plication or imbrication of the retinaculum, detachment and lateralization of the vastus medialis, or with the supplementation of a medial patello-femoral

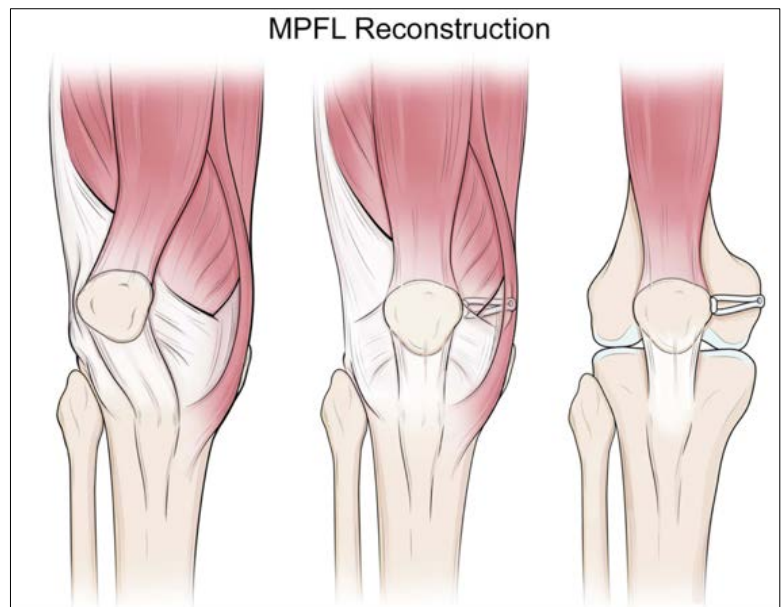


Figure 7. Depiction of an MPFL reconstruction (with and without muscular layers)

ligament (MPFL) reconstruction. A common approach described by many surgeons is one in which the medial capsule and retinaculum are incised, the patella is reduced, and the capsule, retinaculum, and part of the vastus medialis are pulled laterally and sutured anterolaterally to the patella^{11, 13, 36} (Figure 6).

Additionally, surgeons have reported tucking the patella under the thick capsule and suturing its medial border as far medially as possible. The capsule is then stretched laterally and sutured to cover the patella. This secures the patella after reduction to its anatomic position.^{17, 32}

Physicians have also described utilizing MPFL reconstruction as a supplement to the medial retinaculum imbrication and vastus medialis displacement in order to increase the strength of the medial constraint of the patella^{40, 41} (Figure 7). This procedure may be considered to offer greater stability than would be achieved with medial plication or imbrication alone. MPFL reconstruction techniques include reconstruction using either autologous or allograft.⁴² Gracilis or semitendinosus autograft or allograft may be used for MPFL reconstruction in congenital or fixed habitual dislocation of the patella.^{40, 41, 43, 44}

Semitendinosus tenodesis (sometimes referred to as the Galeazzi procedure) is another method which has been historically implemented in the treatment of recurrent dislocation of the patella.^{33, 34, 45} The semitendinosus tendon is divided at its musculocutaneous junction, the muscle belly is sutured to the semimembranosus, and the tendon is pulled through an obliquely drilled hole in the patella from medial to lateral. The patella is pulled medially and downward, and the tendon is sewn back onto itself. This helps to direct the quadriceps mechanism in line with the intercondylar notch of the femur.³³ This procedure has largely fallen out of favor for recurrent dislocation due to a high failure rate.⁴⁶

Proximal Quadrant

The extensor mechanism is generally shortened in congenital dislocation of the patella. This can limit full flexion of the knee after reduction of the patella, often requiring lengthening in the proximal quadrant. A common approach described is to perform an extensive release of the quadriceps, or to lengthen the quadriceps tendon by V-Y plasty^{13, 32} (Figure 8). This may alleviate the limitation of flexion and allow for better

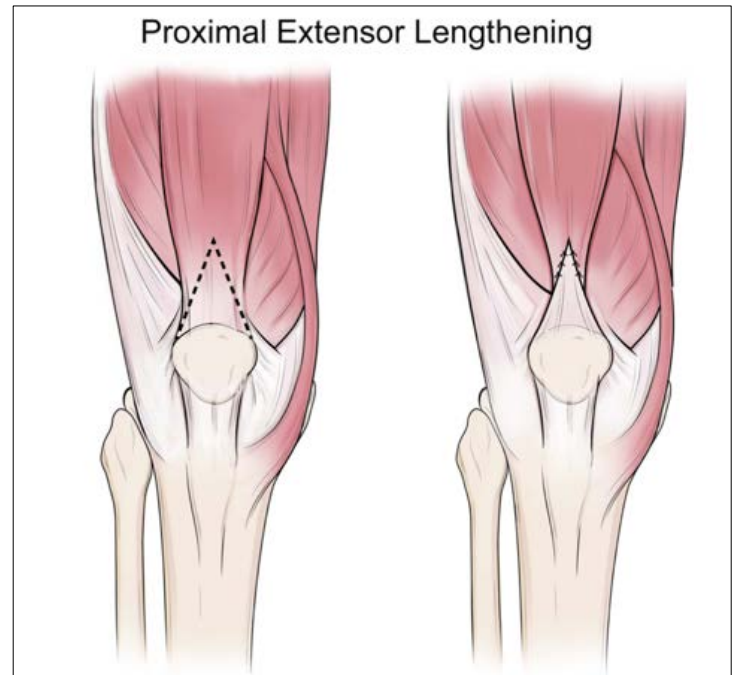


Figure 8. Depiction of V-Y quadriceps lengthening

centralization of the patella. Other surgeons have reported a different approach by releasing the vastus intermedius and lengthening the rectus femoris in order to achieve full flexion of the knee.³⁷ The degree of release and approach used for the proximal quadrant will vary depending on the severity of the limitation in flexion after the patella is reduced.

Distal Quadrant

In almost all cases of fixed dislocation of the patella, the location of the patellar tendon insertion is excessively lateral. This can be addressed by either Roux-Goldthwait transfer or complete medialization of the patellar tendon.^{13, 17, 41} With a Roux-Goldthwait procedure, the patellar tendon is incised longitudinally, and the lateral portion is carefully detached at its insertion from the cartilaginous tibial tuberosity and placed under the medial portion and reattached as medially as possible (Figure 9). It is also an option, as documented by Sever et al., to move the lateral aspect over, rather than under, the medial aspect. This was done to alleviate residual patellar tilt.¹¹ A Roux-Goldthwait transfer often helps to

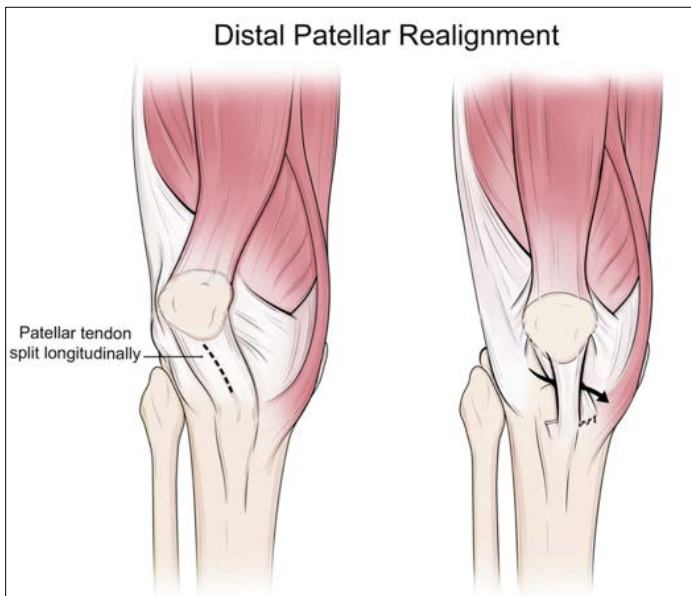


Figure 9. Depiction of a distal patellar tendon realignment (Roux-Goldthwait procedure), in which the patellar tendon is incised longitudinally, and the lateral aspect is transferred medially

improve continued lateral subluxation of the patella when other quadrants are addressed appropriately.¹³ Of note, Gordon et al. documented that instead of splitting the patellar tendon longitudinally, in skeletally immature patients the entire patellar tendon can be sharply detached and transferred medially.³⁶ In skeletally mature patients with a fixed dislocation, a tibial tubercle osteotomy is typically used to elevate the tibial tubercle with the attached patellar tendon from the remainder of the tibia. The osteotomized bone fragment is then transposed medially and secured with screws^{36,41} (Figure 10).

Posterior Procedures

In cases of severe knee flexion contracture, posterior release can be achieved by Z- or fractional lengthening of the hamstrings and semimembranosus and semitendinosus tendons.¹³ Other surgeons have described lengthening the biceps femoris tendon by Z-plasty in addition to releasing both heads of the gastrocnemius from the femoral condyles.⁴⁷ Posterior capsule release may be considered in order to achieve full extension as well.^{47, 48} These procedures may be

implemented in more severe cases to address limitation in extension at the surgeon's discretion.

Additional Bony Procedures:

Skeletally mature patients presenting with a significant valgus deformity of the knee, often defined as greater than 6° , can be treated with a medial closing-wedge or lateral opening-wedge distal femoral osteotomy. This procedure has been implemented in combination with soft tissue reconstruction and tibial tubercle transfer.^{41, 49} Performing a varus osteotomy can benefit patients with congenital dislocation of the patella as it decreases the lateral vector acting upon the patella in a valgus knee, increases stability of the knee, and helps minimize osteoarthritis.^{2, 50}

Congenital dislocation of the patella can also be associated with excessive external tibial torsion, described as greater than 30° ; which can be treated with derotational osteotomy of the tibia. Drexler et al. reported results from a subset of patients with preoperative external tibial torsion greater than 45° , successfully achieving an average rotational correction of 35° . These derotational osteotomies are typically done distally in conjunction with soft tissue procedures and tibial tubercle osteotomies.^{51, 52}

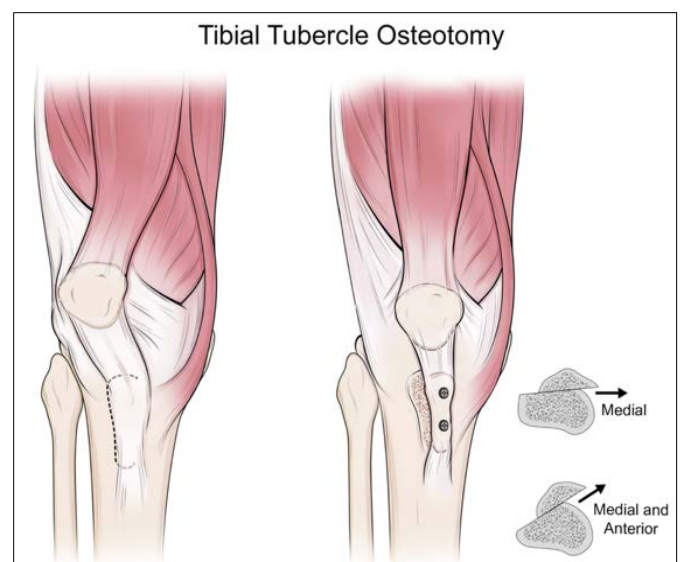
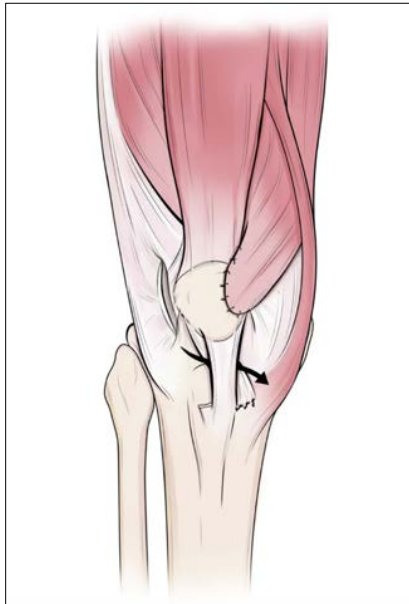

Figure 10. Depiction of a tibial tubercle osteotomy in which the tibial tubercle is transposed medially and secured with screws

Figure 11.
 Depiction of a
 combination of
 lateral release,
 medial plication,
 and distal patellar
 tendon transfer



Postoperative Care

Postoperatively, many surgeons documented immobilization of the leg in a long leg cast for 6 weeks, with flexion typically between 5 and 20 degrees. Most physicians reported keeping the patient's non-weight-bearing while in the cast, while others allowed weight-bearing as tolerated. Typically, after 6 weeks of immobilization, active and passive exercises are initiated to improve range of motion and strength.^{11, 13, 17, 32, 36, 37}

Outcomes

Given the variety of surgical techniques available to be implemented, combined, and modified to address the anatomical defects present with congenital dislocation of the patella, outcomes after surgical correction have been found to be successful overall. Table 1 summarizes the key studies described below. In general, outcomes for surgical intervention of congenital dislocation of the patella are satisfactory, with improved function, range of motion, pain, and quality of life. The previously outlined procedures can be implemented to allow for a multifaceted approach in addressing the numerous anatomic abnormalities that exist with this condition.

Summary

Despite its rarity, fixed dislocation of the patella is a condition that presents at birth with a laterally dislocated

patella, and with associated abnormalities including knee flexion contracture, genu valgum, external tibial torsion, and foot deformity. Habitual or obligate dislocations can also become fixed with time; the later pathology is usually not as severe as that encountered at birth. Imaging with plain radiographs, ultrasonography, or MRI is useful in the diagnosis and preoperative planning for this condition. Surgical correction is the only definitive treatment and should be approached in a stepwise fashion. Considering the different quadrants is a useful way to approach the disorder. This includes a combination of lateral release, medial stabilization, distal patellar tendon realignment, and proximal extensor lengthening (Figures 11 and 12). Each individual case of fixed dislocation or habitual dislocation will present unique challenges. The optimal surgical approach relies on the treating physician to utilize the most appropriate combination of surgical techniques to address each anatomical defect. When this approach is taken, surgical outcomes have been found to be successful.

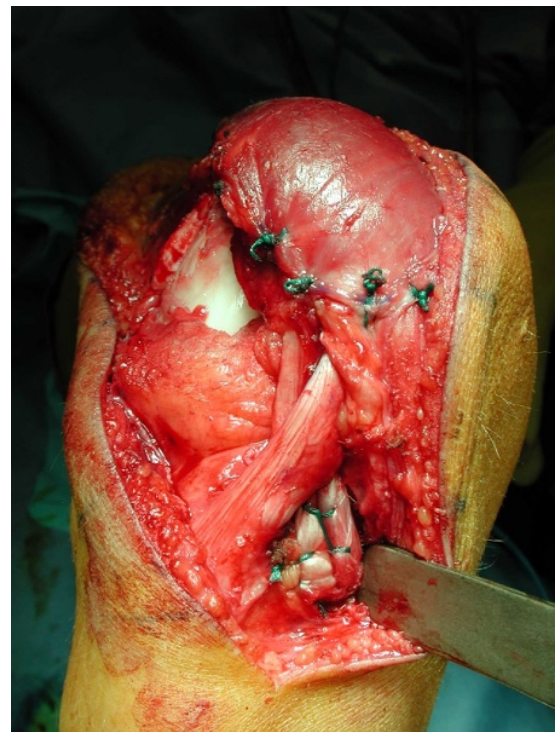


Figure 12. Intraoperative view after medial imbrication, open lateral release and Roux-Goldthwait procedure in the right knee of a patient with habitual patellar instability and Down's syndrome. Courtesy of Kenneth Noonan, MD

Table 1. Summary of Key Studies

Study Author	Patients	Associated Syndromes	Congenital versus Habitual Dislocation	Surgical Techniques
Stanisavljevic, et al. CORR 1976.	6 patients, 7 knees. Ages 5-14 years.	4 patients with Down syndrome.	Congenital dislocation exclusively.	Lateral: Extensive subperiosteal release and realignment Medial: Soft tissue plication Distal: Partial transfer of patellar tendon
Sever, et al. JPO 2019.	12 patients total. 6 patients, 8 knees with congenital dislocation, average age 7.6 years. (3.4-12.7) 6 patients, 7 knees with habitual dislocation, average age 7.2 years. (3.3-12.7)	6 patients with Down syndrome, 2 with Larsen syndrome, 1 with nail-patella syndrome.	6 patients with congenital dislocation, 6 with habitual dislocation.	Lateral: Extensive subperiosteal release and realignment Medial: Soft tissue plication Distal: Partial transfer of patellar tendon (lateral over medial, rather than under)
Gordon, et al. JPO 1999.	10 patients, 13 knees. Average age 7.7 years. (0.2-15)	4 patients, 1 each with nail-patella syndrome, Hecht syndrome, Down syndrome, proximal femoral focal deficiency.	Congenital dislocation exclusively.	Lateral: Release and realignment Medial: Soft tissue plication Distal: Patellar tendon detached and transferred medially in skeletally immature patients. Tibial tubercle osteotomy in mature patients.
Wada, et al. J Child Orthop. 2008.	6 patients, 7 knees. Average age 2.1 years. (0.6-3.9)	Syndromic patients were excluded.	Congenital dislocation exclusively.	Lateral: Release and realignment Medial: Soft tissue plication Distal: Partial transfer of patellar tendon Proximal: Quadriceps lengthening Posterior: Release of hamstrings
Ghanem, et al. JPO 2000.	5 patients, 8 knees. Average age 2.8 years. (4 days-6 years)	1 patient with chondrodysplasia punctata, 1 with arthrogryposis, 1 with multiple congenital anomalies.	Congenital dislocation exclusively.	Lateral: Extraperiosteal release and realignment Medial: Soft tissue plication Distal: Partial transfer of patellar tendon Proximal: Quadriceps lengthening
Gao, et al. JPO 1990.	35 patients total. 12 patients, 16 knees with congenital dislocation, average age 5 years. (0.5-8) 23 patients, 25 knees with habitual dislocation, average age 13.6 years. (4-22)	1 patient with Down syndrome, 1 with bilateral congenital dislocation of the hip.	12 patients with congenital dislocation, 23 with habitual dislocation.	Lateral: Release and realignment Medial: Soft tissue plication. Pes anserinus transferred to patellar tendon in select cases. Distal: Partial transfer of patellar tendon Proximal: Quadriceps lengthening

Additional Links

POSNA Study Guide: Congenital Dislocation of the Patella

<https://posna.org/Physician-Education/Study-Guide/Congenital-Dislocation-of-Patella>

AAOS Video Gallery: Medial Soft-Tissue Imbrication with Lateral Release for Pediatric Patellofemoral Instability

<https://www5.aaos.org/CustomTemplates/VideoGallery.aspx?id=6442471395&nav=320&page=1&ssopc=1>

AAOS Video Gallery: Medial Patellar Tendon Transfer with Proximal Realignment for Patellar Instability in the Skeletally Immature Knee

<https://www5.aaos.org/CustomTemplates/VideoGallery.aspx?id=4294972199&nav=320&ssopc=1>

Acknowledgements: The authors would like to thank Tasha McAbee, MS, CMI for her artwork and figure creation for this manuscript.

References

1. Wirth T. Congenital dislocation of the patella. Department of Orthopaedics, Olgahospital; Stuttgart: 2011.
2. Eilert RE. Congenital Dislocation of the Patella. *Clinical Orthopaedics and Related Research*. 2001; (389):22-29
3. Laville JM: Knee deformities in Larsen's syndrome. *J Pediatr Orthop*. 1994; 3:180–184.
4. Mayeux A, Dabezies EJ, MacEwen GD. Symptomatic recurrent patella dislocation in a patient with dyschondrosteosis (Leri-Weil syndrome). *Orthopedics*. 1995; 18:480–482.
5. Mehlman CT, Rubinstein JH, Roy DR. Instability of the patellofemoral joint in Rubinstein-Taybi syndrome. *Pediatr Orthop*. 1998; 18:508–511.
6. Moran R, Calthorpe D, McGoldrick D, et al. Congenital dislocation of the patella in Rubinstein-Taybi syndrome: A follow-up study. *Ir Med J*. 1993; 86:34–35
7. Dugdale TW, Renshaw TS: Instability of the patellofemoral joint in Down syndrome. *J Bone Joint Surg*. 1986; 68A:405–413.
8. Livingstone B, Hirst P: Orthopaedic disorders in school children with Down's syndrome with special reference to the incidence of joint laxity. *Clin Orthop*. 1986; 207:74–76.
9. Marumo K, Fujii K, Tanaka T, et al: Surgical management of congenital permanent dislocation of the patella in nail patella syndrome by Stanislavljevic procedure. *J Orthop Sci*. 1999; 4:446–449.
10. Mendez AA, Keret D, MacEwen GD: Treatment of patellofemoral instability in Down's syndrome. *Clin Orthop*. 1988; 234:148–158.
11. Sever R, Fishkin M, Hemo Y, Wientroub S, et al. Surgical Treatment of Congenital and Obligatory Dislocation of the Patella in Children. *J Pediatr Orthop* 2019;39:436-440.
12. Miguel sá P, Raposo F, Santos carvalho M, et al. Congenital dislocation of the patella - clinical case. *Rev Bras Ortop*. 2016;51(1):109-12.
13. Wada A, Fujii T, Takamura K, et al. Congenital dislocation of the patella. *J Child Orthop*. 2008;2(2):119-23.
14. Robinson AN, Aladin A, Green AJ, et al. Congenital dislocation of the patella - the genetics and conservative management. *The Knee* 5. 1998;5:3, 235-237
15. Mumford, EB. Congenital dislocation of the patella; case report with history of four generations. *J Bone Joint Surg Am*. 1947 Oct;29(4):1083-6.
16. Ghanem I, Wattincourt L, Seringe R. Congenital dislocation of the patella. Part I: pathologic anatomy. *J Pediatr Orthop*. 2000 Nov-Dec;20(6):812-6.
17. Stanislavljevic S. Congenital, irreducible, permanent lateral dislocation of the patella. *Clin Orthop Relat Res*. 1976 May;(116):190-9.
18. Yamanaka H, Kawamoto T, Tamai H, et al. Total knee arthroplasty in a patient with bilateral congenital dislocation of the patella treated with a different method in each knee. *Case Rep Orthop*. 2015;890315.

19. Bistolfi A, Massazza G, Backstein D, et al. Adult congenital permanent bilateral dislocation of the patella with full knee function: case report and literature review. *Case Rep Med*. 2012;182795.
20. Bergmann NR, Williams PF. Habitual dislocation of the patella in flexion. *J Bone Joint Surg Br*. 1988;70-B:415–419
21. Williams PF. Quadriceps contracture. *J Bone Joint Surg Br*. 1968;50:278–284.
22. Shen HC, Chao KH, Huang GS et al. Combined proximal and distal realignment procedures to treat the habitual dislocation of the patella in adults. *Am J Sports Med*. 2007;35:2101–2108.
23. Bakshi DP. Pes anserinus transposition for patellar dislocation. Long term follow up results. *J Bone Joint Surg Br*. 1993;75 B:305–310.
24. Ogden JA. Radiology of postnatal skeletal development. X. Patella and tibial tuberosity. *Skeletal Radiol*. 1984;11(4):246-57.
25. Koplewitz BZ, Babyn PS, and Cole WG. Congenital Dislocation of the Patella. *Am Journal of Roentgenology*. 2005 184:5, 1640-1646
26. Espandar R, Mortazavi SM, Baghdadi T. Angular deformities of the lower limb in children. *Asian J Sports Med*. 2010;1(1):46–53.
27. Greulich WW, Pyle SI. *Radiographic Atlas of Skeletal Development of the Hand and Wrist*. Second Edition. Stanford, California: Stanford University Press. 1959.
28. Ghelman B, Hodge JC. Imaging of the patellofemoral joint. *Orthop Clin North Am* 1992; 23:523 –543.
29. Muhle C, Brossmann J, Heller M. Kinematic CT and MR imaging of the patellofemoral joint. *Eur Radiol* 1999; 9:508 –518.
30. Recht M, Bobic V, Burstein D, et al. Magnetic resonance imaging of articular cartilage. *Clin Orthop Relat Res* 2001; 391:S379 –S396
31. Thabit G. Patellofemoral pain in the pediatric patient. *Orthop Clin North Am*. 1992;23(4):567–585.
32. Ghanem I, Wattincourt L, Seringe R. Congenital Dislocation of the Patella Part II: Orthopaedic Management. *Journal of Pediatric Orthopaedics*. 20:817–822. 2000.
33. Hall JE, Micheli LJ, Mcmanama GB. Semitendinosus tenodesis for recurrent subluxation or dislocation of the patella. *Clin Orthop Relat Res*. 1979;(144):31-5.
34. Letts RM, Davidson D, Beaulé P. Semitendinosus tenodesis for repair of recurrent dislocation of the patella in children. *J Pediatr Orthop*. 1999;19(6):742-7.
35. Bergquist PE, Baumann PA, Finn HA. Total knee arthroplasty in an adult with congenital dislocation of the patella. *J Arthroplasty*. 2001;16(3):384-8.
36. Gordon JE, Schoenecker PL. Surgical treatment of congenital dislocation of the patella. *J Pediatr Orthop*. 1999;19(2):260-4.
37. Gao GX, Lee EH, Bose K. Surgical management of congenital and habitual dislocation of the patella. *J Pediatr Orthop*. 1990;10(2):255-60.
38. Schorn D, Yang-Strathoff S, Gosheger G, et al. Long-term outcomes after combined arthroscopic medial reefing and lateral release in patients with recurrent patellar instability - a retrospective analysis. *BMC Musculoskelet Disord*. 2017;18(1):277.
39. Felli L, Lovisolo S, Capello AG, et al. Arthroscopic Lateral Retinacular Release and Modified Goldthwait Technique for Patellar Instability. *Arthrosc Tech*. 2019;8(11):e1295–e1299.
40. Maia rosa J, Carvalho AD, Coutinho LL, et al. Surgical Treatment for Congenital Dislocation of the Patella in a Young Adult: A Case Report. *JBJS Case Connect*. 2019;9(4):e0196.
41. Yoshvin S, Southern EP, Wang Y. Surgical treatment of congenital patellar dislocation in skeletally mature patients: surgical technique and case series. *Eur J Orthop Surg Traumatol*. 2015;25(6):1081-6.

42. Carmont MR, Maffulli N. Medial patellofemoral ligament reconstruction: a new technique. *BMC Musculoskelet Disord*. 2007;8:22.
43. Matsushita T, Kuroda R, Araki D, et al. Medial patellofemoral ligament reconstruction with lateral soft tissue release in adult patients with habitual patellar dislocation. *Knee Surg Sports Traumatol Arthrosc*. 2013;21(3):726-30.
44. Sandmeier RH, Burks RT, Bachus KN, et al. The effect of reconstruction of the medial patellofemoral ligament on patellar tracking. *Am J Sports Med*. 2000;28: 345-9.
45. Baker RH, Carroll N, Dewar FP, et al. The semitendinosus tenodesis for recurrent dislocation of the patella. *J Bone Joint Surg Br*. 1972;54(1):103-9.
46. Grannatt K, Heyworth BE, Ogunwole O, Micheli LJ, Kocher MS. Galeazzi semitendinosus tenodesis for patellofemoral instability in skeletally immature patients. *J Pediatr Orthop*. 2012;32(6):621-5.
47. Pradhan RL, Watanabe W, Itoi E, et al. Total knee arthroplasty in bilateral congenital dislocation of the patella-a case report. *Acta Orthop Scand*. 2001;72(4):422-4.
48. Bauer J, Martus J. Pediatric Orthopaedic Society of North America. Congenital Dislocation of the Patella Study Guide. Available at: <https://posna.org/Physician-Education/Study-Guide/Congenital-Dislocation-of-Patella>. Accessed April 1, 2020.
49. Chang CB, Shetty GM, Lee JS, et al. A Combined Closing Wedge Distal Femoral Osteotomy and Medial Reefing Procedure for Recurrent Patellar Dislocation with Genu Valgum. *Yonsei Med J*. 2017;58(4):878–883.
50. Bullek DD, Scuderi GR, Insall JN. Management of the chronic irreducible patellar dislocation in total knee arthroplasty. *J Arthroplasty*. 1996 11(3):339–345
51. Drexler M, Dwyer T, Dolkart O, et al. Tibial rotational osteotomy and distal tuberosity transfer for patella subluxation secondary to excessive external tibial torsion: surgical technique and clinical outcome. *Knee Surg Sports Traumatol Arthrosc*. 2014;22(11):2682-9.
52. Ramaswamy R, Kosashvili Y, Murnaghan JJ, et al. Bilateral rotational osteotomies of the proximal tibiae and tibial tuberosity distal transfers for the treatment of congenital lateral dislocations of patellae: a case report and literature review. *Knee*. 2009;16(6):507-11.