

Recurrent Pediatric Patellofemoral Instability-Beyond the MPFL

Kenneth M. Lin, MD¹; Alexandra T. Mackie, BA, PB-BS¹; Alexandra H. Aitchison, BS¹; Aristides I. Cruz Jr., MD, MBA²; Corinna C. Franklin, MD³; Joseph T. Molony Jr., PT, MS, SCS, CSCS⁴; Kevin G. Shea, MD⁵; Daniel W. Green, MD, MS, FACS¹; Peter D. Fabricant, MD, MPH¹

¹*Division of Pediatric Orthopedics, Hospital for Special Surgery, New York, NY;* ²*Department of Orthopaedic Surgery, Warren Alpert School of Medicine at Brown University, Providence, RI;* ³*Department of Orthopaedics, Shriners' Hospital for Children, Philadelphia, PA;* ⁴*Department of Pediatric Rehabilitation, Hospital for Special Surgery, New York, NY;* ⁵*Department of Pediatric Orthopaedic Surgery, Stanford University School of Medicine, Stanford, CA*

Abstract: Pediatric patellofemoral instability is a common and debilitating problem. In recent years, there has been an improvement in diagnostic capabilities and greater knowledge of unique pediatric patellofemoral anatomy and pathophysiology. The spectrum of disease varies from a single traumatic dislocation, sporadic recurrent dislocation, obligatory dislocation in flexion, or even fixed dislocation in severe or syndrome-associated cases. One must have a thorough understanding of common anatomic and pathophysiologic contributors to patellofemoral instability, such as coronal or axial plane malalignment, and concomitant osteochondral injury. When treating pediatric patellofemoral instability, it is important to understand the benefits and limitations of nonoperative management. We further recognize the challenges imparted by the anatomy of the skeletally immature knee, specifically with regards to the physis, when considering surgical treatment. The purpose of this paper is to review our approach to first time dislocations and non-fixed recurrent patella femoral instability.

Key Concepts:

- Nonoperative management of first-time patellofemoral dislocations consists of a regimented rehabilitation and return to play protocol.
- In the skeletally immature patient, medial patellofemoral ligament reconstruction requires close attention to the anatomic proximity of the medial distal femoral physis.
- Guided growth to correct genu valgum in isolation or in combination with other stabilizing procedures can treat patellofemoral instability in immature patients.
- Concomitant chondral or osteochondral injury must be recognized and may require surgical treatment.
- In severe cases of patellofemoral instability such as obligatory dislocation in flexion, an algorithmic treatment approach which considers individual patient factors as well as intraoperative findings should be implemented.

Introduction

Patellofemoral instability is a common and debilitating problem in the pediatric and adolescent population.¹ Patellofemoral dislocations are often painful and lead to further injury,^{2,3} such as recurrent instability, cartilage injury, and/or osteochondral fracture.^{3,4} Symptoms resulting from patellofemoral dislocations can be lifelong in severe cases, causing disability and potential acceleration of degenerative osteoarthritis.^{3,4} Skeletally immature athletes are at especially high risk of patellofemoral dislocation as the majority of patellofemoral dislocations occur during athletics.^{5,6} The overall injury rate for high school athletes is as high as 1.95 per 100,000 athlete-exposures.^{7,8} Patients under 20 years have the greatest incidence of patellofemoral dislocation,^{5,6,9} and those under 16 years are more likely to suffer from recurrent instability.¹⁰⁻¹² Pediatric patients who, depending on the severity of the injury, may have up to a 60% recurrence rate.^{9,10}

In order to appropriately apply the best treatment options for a pediatric patient with patellofemoral instability, it is important to obtain a thorough history, physical examination, and appropriate diagnostic imaging. Less severe and first-time cases may initially be treated nonoperatively, with bracing, and neuromuscular control and strengthening techniques. More severe and recurrent cases, such as obligatory patellofemoral dislocation in flexion, tend to require surgical treatment but must take into consideration unique pediatric anatomy.

Importantly, there are a number of morphologic abnormalities and concomitant injuries known to contribute to more severe patellofemoral instability, such as coronal plane malalignment (genu valgum), trochlear dysplasia, patella alta, and soft tissue laxity or disruption.^{1,13-15} Although medial patellofemoral ligament (MPFL) reconstruction is generally regarded as the gold standard procedure to treat recurrent lateral patellofemoral instability,^{7,16} these additional pathologies must also be considered. Furthermore, MPFL surgery must be modified in skeletally immature patients, and other surgical methods such as distal femoral or tibial tubercle osteotomy are usually

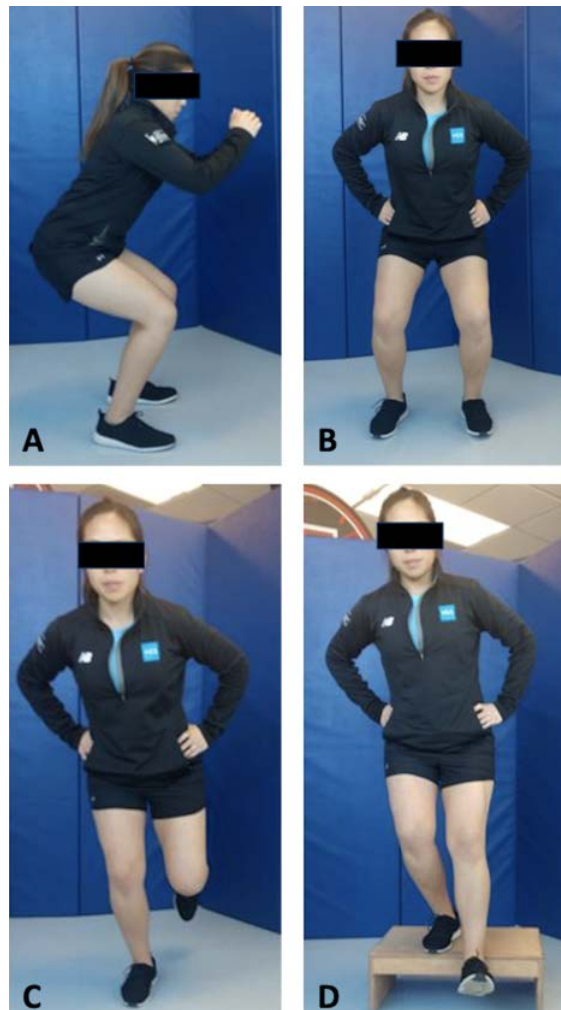

Figure 1. Example of hip strategy and proper lower extremity alignment with squats and forward step down. A), B) front and side views of two-legged squat; C) single-leg squat; D) single-leg step-down

contraindicated.¹⁷⁻²⁰ Young athletes both attempting nonoperative management or in the postoperative treatment phase also require dedicated rehabilitation protocols.^{10,21}

The purpose of this review is to outline and assess important considerations in the treatment of pediatric patellofemoral instability other than solely the MPFL, as discussed in the adult literature.²²⁻²⁵ In this manuscript, we discuss: a structured approach for nonoperative management of patients with a focus on milestone-based return to sports and activity, anatomic considerations for MPFL reconstruction in skeletally immature patients, the role of correcting genu valgum,

surgical treatment options for patients with concomitant chondral or osteochondral injury, and an algorithmic approach to treating severe cases of obligatory patellofemoral dislocation in flexion.

The Keys to Maximizing Success of Rehabilitation and Return to Play After First-Time Dislocators

Nonoperative treatment of a young athlete with a first-time patellofemoral dislocation aims to restore strength and function as rapidly as possible while ensuring patellofemoral stability and avoiding chronic patellofemoral pain. Progression through subsequent phases of treatment is criteria-based and it should be noted that timeframes are generalized. For all functional activities the patient must be pain free without patellar apprehension. In the later phases, it is integral that the patient consistently demonstrates proper lower extremity and trunk alignment and control as well as good force attenuation with impact activities even when fatigued. For treatment to be successful, development of a home exercise program is vital. The authors' recommendations to facilitate program adherence are to encourage "cornerstone exercises" (which are the highest priority for the patient's particular presentation), to keep the program short (as few as 3-4 exercises), and to collaborate with the patient and family on successful strategies rather than being punitive if they are not following the program.

For the first two weeks after the initial dislocation, it is important to protect the patellofemoral joint and medial soft tissue structures while minimizing edema and inflammation. The knee can be immobilized in extension or placed in a patellar stabilizing brace; the latter requires the patient to position the buttress properly at the lateral patella and adjust it throughout the day if the brace migrates. Neuromuscular electrical stimulation can be utilized but can be poorly tolerated in the youth population. Biofeedback may be a better option in this age group. Weight-bearing in the early phase can be protected, and standing and walking are limited to minimize pain and effusion which inhibit quadriceps activation.^{26, 27} To minimize edema, the patient should be

encouraged to elevate the leg above the level of the chest when at rest. A compressive wrap, tubular elastic stocking, or elasticized knee sleeve may be applied. Cold therapy with simultaneous compression can be applied using an automated unit. Exercises performed in the early phase include four-way straight leg raises as well as resistance band plantarflexion, with focus on establishing a hip strategy rather than a knee strategy. Stretching can be performed but caution should be taken if the patient is hyperflexible.

In the sub-acute phase, which is generally weeks 2-3 post-injury, weight-bearing can be progressed accordingly based on presence of concomitant injuries. If a hinged brace is used, it can be unlocked when the patient is able to perform a straight leg raise without a knee extension lag. Exercise program advancements include standing calf raises, clamshells, bridges, short crank stationary bike if able without pain, and foot intrinsic muscle exercises, such as towel crunches and marble pickups to assist with creating a stable base of support during eventual functional activities. Blood flow restriction is gaining popularity and can also be considered, as it loads the patellofemoral joint at a lower intensity than traditional exercise while potentially yielding similar strength gains.^{28, 29}

Weeks 3-6 are generally the transition to functional activity. At this point, straight leg raises can be advanced with ankle weights. The patient can progress to static single-leg activities such as single leg balance and can progress to forward step-ups, beginning as low as two inches if needed. Closed chain dynamic exercises such as double leg mini squats (Figures 1A and 1B) and short-range leg press can be performed. Depth can be progressed and loading advanced to single leg and eccentrics. The patient can be advanced to a standard stationary bike if appropriate per patient height and resistance can be added. Core strengthening can also be performed with exercises such as planks and side planks.

At 6 weeks, the patient can begin dynamic, non-impact functional activities such as sidestepping in a mini squat position, as well as proprioception and neuromuscular

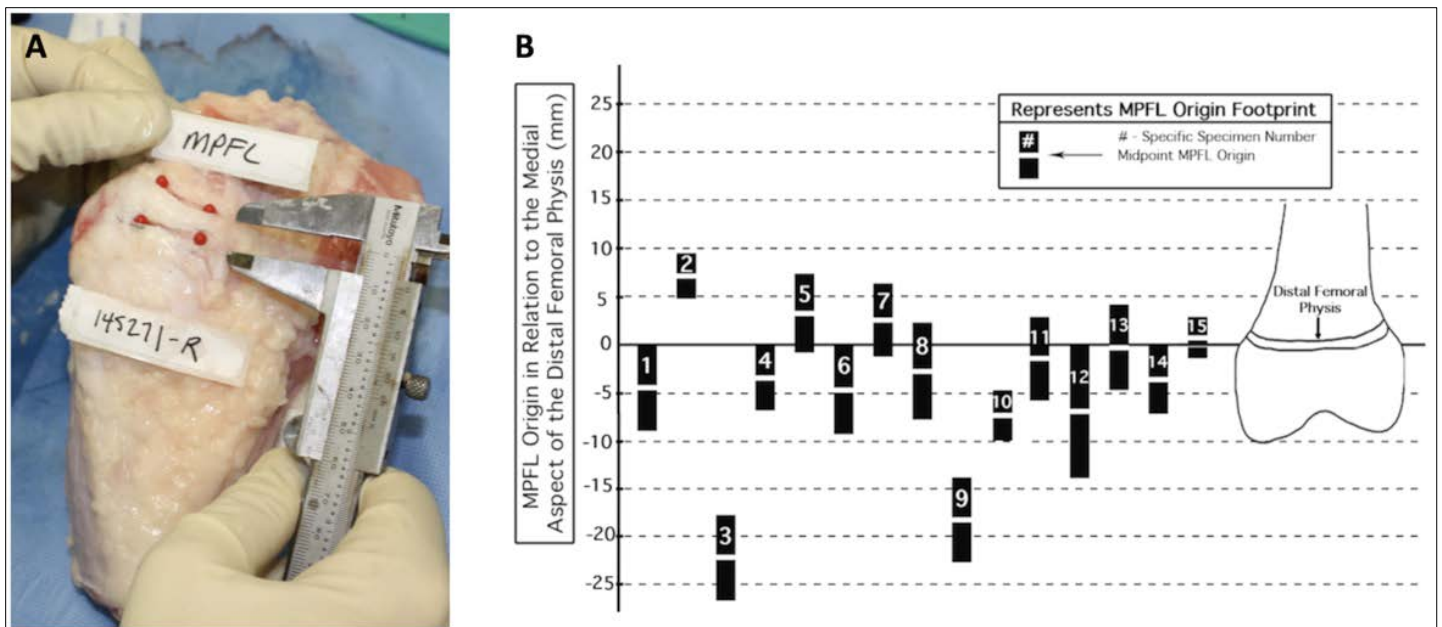


Figure 2. Relationship of MPFL femoral origin to the medial aspect of the distal femoral physis. A) Representative photograph demonstrating dissection of a skeletally immature cadaveric knee specimen. Red pins indicate extent of MPFL tissue. B) Data derived from a quantitative anatomic study using 15 cadaveric immature knee specimens, demonstrating the proximity of the MPFL femoral origin to the distal femoral physis. Figure adapted with permission from Shea et al.³⁷

facilitation through double and single leg activities (Figure 1C) on stable and unstable surfaces adding perturbations. It must be noted that in order to begin these types of activities, the patient must demonstrate good control in static single leg stance. Also in this phase, the patient can perform lunges and lunge walks, bike intervals for anaerobic conditioning and leg power development, add weight to functional tasks, and begin a step-down progression as low as two inches (Figure 1D).

After 10 weeks, the patient is transitioned to low impact and eventually high impact activity and can perform squat jumps, hop to opposite leg, and low intensity pre-programmed/feedforward agility such as forward jogging, backpedaling, and side shuffling without reacting to external stimuli. When the patient achieves a limb symmetry index⁷ of 85% with good force attenuation and proper alignment, he or she may be transitioned to higher impact activity. Tests such as single leg single hop for distance, triple hop for distance and crossover hop for distance can be utilized to make this determination. In this transition, feedforward

activities can be advanced to 100% effort including plyometrics. A progression of pivoting and reactive feedback drills can also be introduced, where the patient reacts to external stimuli such as verbal commands of visual prompts to change direction.

Criteria to begin progressive return to sports are 85-90% limb symmetry index, and ability to perform repeated full intensity running, cutting, and jumping, all with optimal mechanics. It is recommended that the parent, coach, and athlete are fully committed to the initial restrictions before allowing the athlete to begin training with the team. At practice, noncontact drills can be performed, such as dribbling in soccer without a defender. For return to full sports participation, criteria include a limb symmetry index as high as 95-100%, and the ability to complete full practices, followed by partial games or matches. It is imperative to establish an injury prevention program which should include a strength, conditioning, and neuromuscular training program to be followed throughout the year as well as consideration of continued use of a patellofemoral stabilizing brace.

Unique Anatomic Considerations for MPFL Reconstruction in Skeletally Immature Patients

MPFL reconstructions have shown good outcomes for recurrent patellofemoral instability in carefully selected adult and pediatric populations.^{22, 30} The surgical technique for adults and adolescents follows anatomic recommendations for graft placement.^{25, 31, 32} Graft placement on the patella has been consistent, with many groups recommending a broad attachment along the medial border of the patella.^{33, 34} Avoiding large patellar drill tunnels can reduce the risk of patella fracture.³⁵ There appear to many good graft choices, including autograft quadriceps and hamstring, as well as allograft choices.

Femoral graft placement for younger patients with significant growth remaining has been more controversial due to variation in imaging and anatomic studies of the MPFL origin with respect to the distal femoral physis. Some researchers have proposed that the MPFL origin is consistently below the femoral physis, where other imaging and anatomic studies have shown variation in MPFL origin with respect to the femoral physis.^{36, 37} While the midpoint of the MPFL may be at or below the physis in some subjects, the coronal plane of the MPFL may span above the distal femoral physis, and this may be more common in older patients.

Based on anatomic studies, the mean coronal width of the MPFL between ages 8-11 is 0.8cm, with a range of 0.43 to 1.28cm; the proximal limit of the MPFL is at or above the physis in some subjects (Figure 2).^{38, 39} In young patients with significant growth remaining, direct physeal injury can lead to physeal arrest and growth disturbance. It is generally accepted that due to the native anatomy of the midpoint of the femoral origin of the MPFL,^{33, 36, 37} and the fact that the direction of femoral growth is that the epiphysis grows away from the metaphysis, femoral fixation of an MPFL graft in the distal femoral epiphysis is appropriate while using modified techniques to avoid iatrogenic physeal injury.^{40, 41}

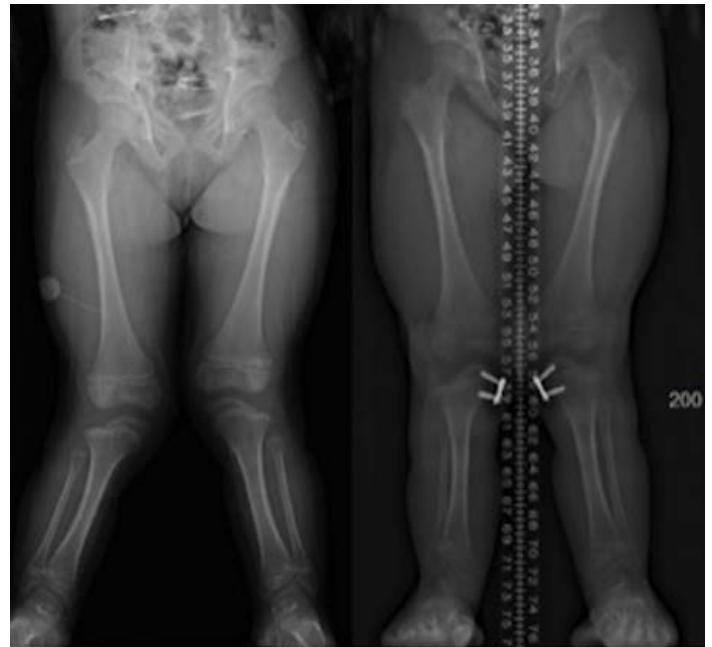


Figure 3. Example of patellofemoral instability in the setting of genu valgum. This skeletally immature patient with Ellis van Crevald syndrome and severe bilateral genu valgum had patellofemoral instability. Left and right panels are from before and after hemiepiphysiodesis, respectively. Correcting the valgus is required to treat patella instability.

Management of Coronal and Axial Plane Malalignment

Genu Valgum

Genu valgum is a potential contributor to patellofemoral instability. As the knee goes into valgus, the pull of the extensor mechanism moves lateral to the trochlear groove. This acts as a destabilizing force on the patella, tending to pull it laterally from the trochlea. Correcting this knee valgus in the skeletally immature may be done through guided growth of the medial distal femur and/or proximal tibia (Figure 3).³ This should be considered in patients with at least one year or more of growth remaining, and in the presence of greater than ten degrees of knee valgus, or when the treating surgeon feels that coronal plane deformity is contributing to patellofemoral instability.⁴² Patients with skeletal dysplasia often have diminished growth potential and valgus correction via guided growth may take longer.

There is little consensus on whether to perform patellar stabilizing procedures such as MPFL reconstruction concurrently, or to wait until the coronal axis is corrected. Parikh et al. reported a screw hemi-epiphysiodesis technique that allows for safe placement of MPFL anchoring implants, thus allowing for simultaneous growth modulation and MPFL reconstruction.⁴³ However, Tan et al. argued that sometimes further procedures are unnecessary after the alignment has been corrected. In their series of 20 patients with valgus knees and patellofemoral instability who underwent guided growth, 16 required no further surgery.⁴⁴ Additional study is needed to determine the ideal timing of these procedures. The authors' preference, particularly in younger children, is to first correct coronal plane angular deformity, and subsequently perform MPFL reconstruction at the time of guided growth implant removal if the patient continues to have instability despite anatomic limb alignment.

Correcting genu valgum in a patient who is skeletally mature requires more extensive surgery in the form of distal femoral osteotomy with plate osteosynthesis. Wilson et al. reported on a series of 10 patients who had varus-producing distal femoral osteotomies for patellofemoral instability, and noted improvement in both functional and radiographic parameters, with eight patients having no further instability.⁴⁵ Although they noted satisfactory outcomes, distal femoral osteotomy in skeletally mature patients is more invasive than implant-mediated guided growth in skeletally immature patients and introduces the possibility of additional complications, including nonunion.

Axial Malalignment: Rotational Mismatch

Excessive femoral anteversion coupled with external tibial torsion is sometimes referred to as "miserable malalignment" and also can contribute to patellofemoral instability, as the extensor mechanism tends to pull the patella laterally away from the trochlea. Several studies have suggested axial malalignment as a potential cause for poor outcomes or failure of patellar stabilization

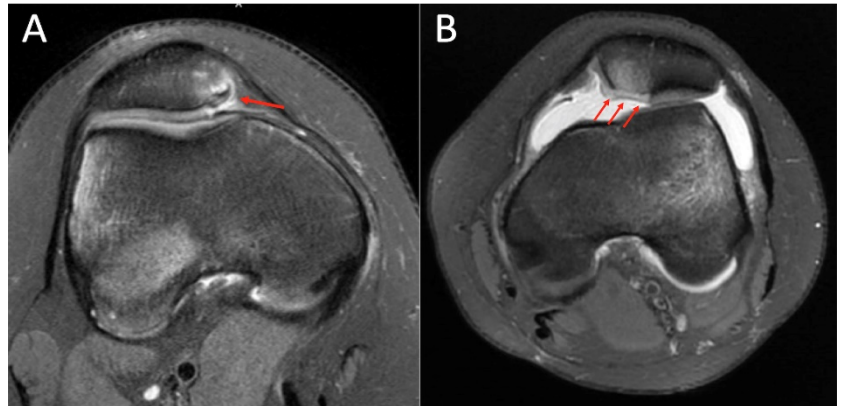


Figure 4. Axial MRI scans demonstrating two types of patella injury in the setting of patellofemoral instability. A) Medial avulsion fracture at MPFL patellar insertion; B) Full-thickness osteochondral fracture of weight-bearing portion of medial patellar facet

surgery. Franciozi et al. suggested that femoral anteversion correlated with a poor outcome for MPFL reconstruction with tibial tubercle osteotomy.⁴⁶ Other authors have reported that persistent external tibial torsion correlated with diminished outcomes in patellofemoral stabilization surgery.⁴⁷⁻⁴⁹ Others report better outcomes with femoral and/or tibial osteotomy in the setting of revisions for those failures.⁵⁰⁻⁵² In some cases it has been described as included in the index patellofemoral stabilizing procedure.⁵³⁻⁵⁵ However, some patients, families, or surgeons might find rotational plane osteotomies excessive in the treatment of a typical adolescent athlete in the absence of severe rotational malalignment. In a patient in whom axial malalignment is a concern, three-dimensional gait analysis may help to decide on the usefulness of a derotational osteotomy.

Osteochondral Injuries in the Setting of Acute Patellofemoral Instability

Concomitant chondral or osteochondral injury after acute lateral patellofemoral dislocation is relatively common. Seeley et al. retrospectively examined 122 pediatric patients (age 11-18 years) over a 10-year period and identified 46 (37.7%) who had an associated osteochondral injury confirmed on MRI.⁵⁶ Because of the nature of the injury mechanism (i.e., lateral patellofemoral dislocation followed by spontaneous or

Table 1. Factors that Influence Osteochondral Fracture Treatment

Treatment	Size	Injury location	Fracture fragment quality
<i>Loose body removal</i>	<1 cm	NWB	Poor – Cannot accept fixation
<i>Reduction/fixation</i>	>1 cm	WB	Good – Can accept fixation
<i>Salvage procedure</i>	>1 cm	WB	Poor – Cannot accept fixation

NWB = Non-weight bearing surface. WB = Weight bearing surface

manual relocation), the two most common locations of osteochondral injury are the lateral femoral condyle (LFC) and the medial patellar facet.^{2,57} In the series described by Seeley et al., 23.9% of patients had injury to the LFC, 76.1% of patients had injury to the medial patellar facet, and 6.5% of patients had injury to both. The depth of the osteochondral injuries varied and ranged from superficial, cartilaginous fissuring to deep, full-thickness fractures involving the subchondral bone. An osteochondral injury can also remain in situ or result in a displaced loose body.

In general, smaller (<1cm) osteochondral lesions can be treated either nonoperatively or with simple arthroscopic loose body removal. Surgical treatment should be considered for lesions that are larger than 1cm in size. Loose body removal remains an option for larger lesions, but consideration should be made to address the residual fracture bed in the patella or lateral femoral condyle with either osteochondral fragment reduction and fixation or some other method of chondral resurfacing.

For osteochondral injuries of the medial patella, it is important to distinguish between avulsion fractures of the MPFL insertion versus fractures of the weight-bearing portion of the medial patellar facet or inferior pole (Figure 4). Avulsion fractures of the MPFL patellar insertion do not need to be addressed surgically unless the surgeon thinks it will substantially influence the risk of future instability episodes. In contrast, surgical repair

of full-thickness osteochondral lesions of the medial patellar facet should be considered to minimize the risk of future patellofemoral arthrosis. Similarly, variability exists in lateral femoral condyle osteochondral lesions. These can occur either in a non-weight bearing or weight-bearing portion the lateral femoral condyle (Figure 5). Surgical repair is only indicated for those lesions that involve the weight-bearing surface.

The osteochondral fracture fragment as well as the fracture bed should be assessed for tissue quality as both these factors can influence ultimate treatment. This includes characterizing whether the fracture fragment consists mostly of cartilage or whether it consists of both cartilage and subchondral bone. The residual fracture bed in the medial patellar facet or lateral femoral condyle also should be similarly addressed for depth of injury. Chondral-only fractures will necessitate different fixation methods than fractures that involve a portion of bone. Similarly, superficial cartilage only lesions of the weight-bearing portion of the medial patellar facet or lateral femoral condyle will be treated differently than lesions that probe deep into the subchondral bone. Although in general, lesions with attached bone have improved healing potential, in pediatric patients the fixation of chondral-only fragments has been shown to be successful in select individuals.⁴¹

Surgical treatment is generally indicated for large osteochondral lesions that involve the articulating or weight-bearing portion of the medial patellar

facet/inferior pole or lateral femoral condyle, respectively. When considering fixation options, the osteochondral fracture must be of sufficient quality to accept fixation implants (e.g., no comminution or fragmentation) (Table 1). Additionally, the depth of the lesion will influence implant choice. For example, chondral-only fragments will not be able to accept traditional screw fixation and chondral specific implants may be necessary to provide adequate fixation.

Finally, in the case of osteochondral fractures that are unsalvageable due to poor tissue quality and in the setting of a large osteochondral fragment bed defect, articular resurfacing salvage options may be considered. Depending on the depth of the lesion, these salvage procedures include abrasion arthroplasty or microfracture, osteochondral autograft transplantation surgery (OATS), osteochondral allograft, autologous chondrocyte implantation (ACI), or resurfacing with particulated juvenile allograft cartilage. Discussion of the specifics of these resurfacing techniques are beyond the scope of this article but may be selected based on various factors and depending on the treating surgeon's preference and implant availability.

Severe Atypical Patellofemoral Instability: Syndromic Instability and Instability in Flexion

Obligatory dislocation occurs every time the patient flexes or extends the knee, and fixed lateral dislocation is when the patella is irreducible regardless of knee positioning.⁵⁸ Many of these patients have a syndromic association to their instability such as skeletal dysplasia, nail patella syndrome, Marfan disease, Ehlers-Danlos, cerebral palsy or Downs Syndrome. Patients with fixed and obligatory dislocations have a distinct, more severe manifestation of the disease, and require different treatment than patients with traumatic dislocations.

Obligatory patellofemoral dislocation occurs laterally every time the patient flexes the knee. The patella sits centered anteriorly in extension but dislocates into the lateral gutter as the knee is flexed. In most cases, the

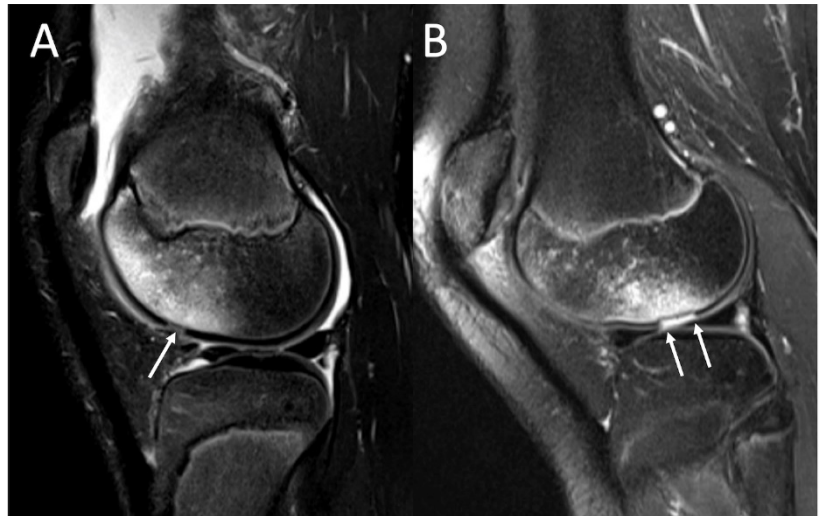


Figure 5. Sagittal MRI showing osteochondral injury to the lateral femoral condyle in the setting of patellofemoral instability. A) Lateral femoral condyle lesion, non-weight bearing; B) Lateral femoral condyle lesion, weight-bearing

patella is unable to be manipulated or reduced into the trochlea while in flexion but will spontaneously reduce upon full extension. Surgical treatment of obligatory patellofemoral dislocation in flexion involves a step-by-step approach based on patient factors and intraoperative assessment.^{9, 59}

First, it is important to understand that the pathophysiology of obligatory lateral patellofemoral dislocation is complex and multifactorial. These patients tend to have multiple anatomic abnormalities, including patella alta, trochlear dysplasia, soft tissue laxity or deficiency, and may also have concurrent rotational deformities to the lower extremity. The algorithmic approach aims to restore the normal force vector of the extensor mechanism while stabilizing the patella; it begins with bony realignment as needed, followed by soft tissue balancing, based on patient factors and intraoperative findings.

Bony deformity should be addressed, as outlined above. In patients with an abnormal tibial tubercle-trochlear groove (TT-TG) distance, distal realignment procedures should be considered. A tibial tubercle osteotomy to

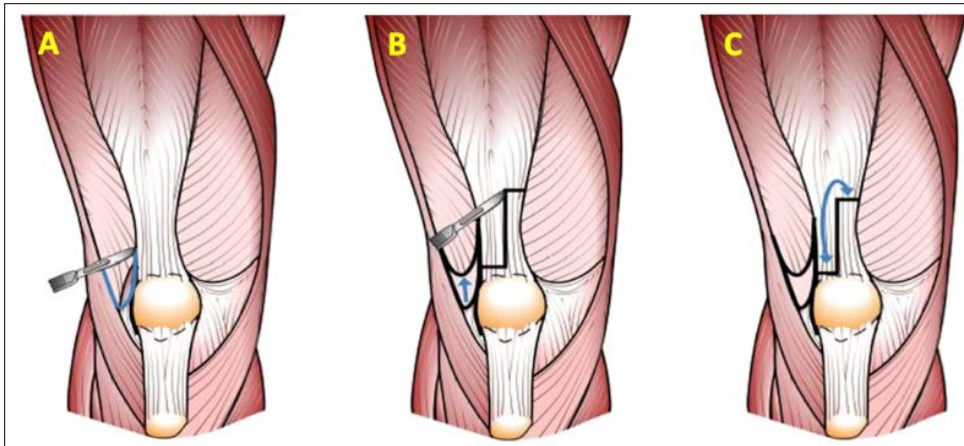


Figure 6. Management of the quadriceps during treatment of obligatory lateral dislocation in flexion. A) Release of the distal vastus lateralis tendon off of the patella; B) Z-cut of the rectus femoris tendon; C) Lengthening of the rectus tendon and reattachment of the vastus lateralis to the proximal portion of the lengthened rectus tendon, thereby redirecting the force vector of the vastus lateralis to a more centralized position

medialize the tibial tubercle and attached patellar tendon is recommended for skeletally mature patients. In the skeletally immature patients, we recommend a medial soft tissue patella tendon transfer, as previously described.^{60, 61} Although not performed in our practice, other procedures such as a Roux-Goldthwait and Nietosvaara techniques can also be used in patients with open physes.^{62, 63}

After bony alignment is corrected, a lateral release should be performed just lateral to the patella that extends distally to the joint line just lateral to the patella tendon, and proximally to the vastus lateralis tendon. A lateral lengthening of the retinaculum can be carried out by dissecting the central portion of the lateral retinaculum into two layers and then suturing the two layers back together at the conclusion of the case. In severe cases, a lateral retinacular lengthening is not always possible. If the vastus lateralis appears tight, it should be released from the patella and adjacent quadriceps tendon. The posterior fibers of the vastus lateralis muscle may also need to be released distally to decrease the lateral pull of the vastus lateralis. At the

conclusion of the case, the vastus lateralis tendon should be reattached 2-3cm proximally with the knee flexed at 60 degrees.

At this point, the knee should be taken through a full range of motion. Anecdotally, we find about half of these patients no longer dislocate in flexion after lateral release and vastus lateralis release. However, if the patella still spontaneously dislocates

in flexion, a formal quadriceps tendon lengthening should be performed. The distal rectus tendon should be Z-lengthened approximately 2cm and repaired with multiple interrupted sutures under tension with the knee in 70 degrees of flexion. The vastus lateralis release and quadriceps lengthening procedures are depicted in Figure 6 and Video 1.

After addressing the lateral structures and lengthening the quadriceps tendon (if indicated), the MPFL should be reconstructed. We recommend using a double limbed hamstring graft with either suture anchor fixation to the superior half of the patella or with the free ends fixed in two 4.5mm short sockets to minimize risk of patellar fracture that can be seen with full tunnels. In skeletally mature patients, the femoral attachment should be based on anatomic landmarks (the saddle between the adductor tubercle and medial epicondyle), and the radiographic location of Schlottle's point. In the skeletally immature patients, the attachment is just distal to the distal femoral physis as previously described.⁶⁴

In summary, obligatory dislocation in flexion is a severe type of patellofemoral instability that should be treated surgically in the pediatric population. An algorithmic approach to treatment that accounts for both individual patient factors and intraoperative findings should be implemented. Surgeons should be prepared to perform a combination of lateral release/lengthening, quadriceps lengthening, MPFL reconstruction, and distal realignment if necessary.

Conclusion

This paper has reviewed:

1. keys to nonoperative management of a first-time patellofemoral dislocator
2. anatomic considerations in MPFL reconstruction in the skeletally immature individual
3. coronal plane deformity correction as a stand-alone treatment or as an adjunct to other stabilizing procedures
4. surgical treatment options for patients with concomitant chondral or osteochondral injury
5. an algorithmic approach to treating severe cases of fixed dislocation or obligatory dislocation in flexion

Pediatric patellofemoral instability is an increasingly common problem that has an impact on function, quality of life, and future degenerative disease of the knee.

Treatment strategies and techniques continue to evolve as our knowledge of anatomy, pathophysiology, and biomechanics continues to improve. It is important to have a comprehensive and multidisciplinary foundational knowledge to treat these patients appropriately, as many procedures described in skeletally mature adolescents and adults may not be applicable to our youngest patients, and unique pediatric pathology must also be considered.

References

1. Haj-Mirzaian A, Thawait GK, Tanaka MJ, Demehri S. Diagnosis and Characterization of Patellofemoral Instability: Review of Available Imaging Modalities. *Sports Med Arthrosc.* 2017;25(2):64-71. doi:10.1097/JSA.000000000000148
2. Nomura E, Inoue M, Kurimura M. Chondral and osteochondral injuries associated with acute patellar dislocation. *Arthrosc - J Arthrosc Relat Surg.* 2003;19(7):717-721. doi:10.1016/S0749-8063(03)00401-8
3. Lin KM, Fabricant PD. CORR Synthesis. *Clin Orthop Relat Res.* Published online May 2020:1. doi:10.1097/corr.0000000000001311
4. Sanders TL, Pareek A, Johnson NR, Stuart MJ, Dahm DL, Krych AJ. Patellofemoral Arthritis After Lateral Patellar Dislocation: A Matched Population-Based Analysis. *Am J Sports Med.* 2017;45(5):1012-1017. doi:10.1177/0363546516680604
5. Waterman BR, Belmont PJ, Owens BD. Patellar Dislocation in the United States: Role of Sex, Age, Race, and Athletic Participation. *J Knee Surg.* 2011;25(1):51-58. doi:10.1055/s-0031-1286199
6. Fithian DC, Paxton EW, Stone M Lou, et al. Epidemiology and natural history of acute patellar dislocation. *Am J Sports Med.* 2004;32(5):1114-1121. doi:10.1177/0363546503260788
7. Saper MG, Fantozzi P, Bompadre V, Racicot M, Schmale GA. Return-to-Sport Testing After Medial Patellofemoral Ligament Reconstruction in Adolescent Athletes. *Orthop J Sport Med.* 2019;7(3). doi:10.1177/2325967119828953
8. Ménétreay J, Putman S, Gard S. Return to sport after patellar dislocation or following surgery for patellofemoral instability. *Knee Surgery, Sport Traumatol Arthrosc.* 2014;22(10):2320-2326. doi:10.1007/s00167-014-3172-5
9. Lewallen LW, McIntosh AL, Dahm DL. Predictors of recurrent instability after acute patellofemoral dislocation in pediatric and adolescent patients. *Am J Sports Med.* 2013;41(3):575-581. doi:10.1177/0363546512472873
10. Gao B, Dwivedi S, Fabricant PD, Cruz AI. Patterns in Outcomes Reporting of Operatively Managed Pediatric Patellofemoral Instability: A Systematic Review and Meta-analysis. *Am J Sports Med.* 2019;47(6):1516-1524. doi:10.1177/0363546518765152
11. Palmu S, Kallio PE, Donell ST, Helenius I, Nietosvaara Y. Acute patellar dislocation in children and adolescents: A randomized clinical trial. *J Bone Jt Surg - Ser A.* 2008;90(3):463-470. doi:10.2106/JBJS.G.00072
12. Moore B, Bothner J. Recognition and initial management of patellar dislocations. Uptodate.com. Published 2017. Accessed July 10, 2020. <https://www.uptodate.com/contents/recognition-and-initial-management-of-patellar-dislocations>

13. White BJ, Sherman OH. Patellofemoral instability. *undefined*. Published online 2009.
14. Henry JH, Craven PR. Surgical treatment of patellar instability: Indications and results. *Am J Sports Med*. 1981;9(2):82-85. doi:10.1177/036354658100900202
15. Colvin AC, West R V. Current Concepts Review: Patellar Instability. *J Bone Jt Surg*. 2008;90A(12):2751-2762. doi:10.2106/JBJS.H.00211
16. Boyle MJ, Butler RJ, Queen RM. Functional Movement Competency and Dynamic Balance After Anterior Cruciate Ligament Reconstruction in Adolescent Patients. *J Pediatr Orthop*. 2016;36(1):36-41. doi:10.1097/BPO.0000000000000402
17. Clark D, Metcalfe A, Wogan C, Mandalia V, Eldridge J. Adolescent Patellar Instability: Current Concepts Review. *Bone Joint J*. 2017;99-B(2):159-170. doi:10.1302/0301-620X.99B2.BJJ-2016-0256.R1
18. Harrison MHM. The results of a realignment operation for recurrent dislocation of the patella. *J Bone Joint Surg Br*. 1955;37 B(4):559-567.
19. Nelitz M, Theile M, Dornacher D, Wölfle J, Reichel H, Lippacher S. Analysis of failed surgery for patellar instability in children with open growth plates. *Knee Surgery, Sport Traumatol Arthrosc*. 2012;20(5):822-828.
20. Shubin Stein BE, Ahmad CS. The Management of Patellar Instability in the Skeletally Immature Patient. *Oper Tech Orthop*. 2007;17(4):250-256.
21. Yellin JL, Fabricant PD, Gornitzky A, et al. Rehabilitation following anterior cruciate ligament tears in children: A systematic review. *JBJS Rev*. 2016;4(1). doi:10.2106/JBJS.RVW.O.00001
22. Schneider DK, Grawe B, Magnussen RA, et al. Outcomes after Isolated Medial Patellofemoral Ligament Reconstruction for the Treatment of Recurrent Lateral Patellar Dislocations. *Am J Sports Med*. 2016;44(11):2993-3005. doi:10.1177/0363546515624673
23. Liu JN, Brady JM, Kalbian IL, et al. Clinical Outcomes After Isolated Medial Patellofemoral Ligament Reconstruction for Patellar Instability Among Patients With Trochlear Dysplasia. *Am J Sports Med*. 2018;46(4):883-889. doi:10.1177/0363546517745625
24. Erickson BJ, Nguyen J, Gasik K, Gruber S, Brady J, Shubin Stein BE. Isolated Medial Patellofemoral Ligament Reconstruction for Patellar Instability Regardless of Tibial Tubercle–Trochlear Groove Distance and Patellar Height: Outcomes at 1 and 2 Years. *Am J Sports Med*. 2019;47(6):1331-1337. doi:10.1177/0363546519835800
25. Schöttle PB, Schmeling A, Rosenstiel N, Weiler A. Radiographic landmarks for femoral tunnel placement in medial patellofemoral ligament reconstruction. *Am J Sports Med*. 2007;35(5):801-804. doi:10.1177/0363546506296415
26. Davi SM, Lepley AS, Denegar CR, DiStefano LJ, Edgar CM, Lepley LK. Quadriceps Inhibition After Naturally Occurring Patellar Tendon Damage and Pain. *J Athl Train*. 2020;55(6):000-000. doi:10.4085/1062-6050-27-19
27. Greuel H, Herrington L, Liu A, Jones RK. How does acute pain influence biomechanics and quadriceps function in individuals with patellofemoral pain? *Knee*. 2019;26(2):330-338. doi:10.1016/j.knee.2018.12.008
28. Giles L, Webster KE, McClelland J, Cook JL. Quadriceps strengthening with and without blood flow restriction in the treatment of patellofemoral pain: A double-blind randomised trial. *Br J Sports Med*. 2017;51(23):1688-1694. doi:10.1136/bjsports-2016-096329
29. Bowman EN, Elshaar R, Milligan H, et al. Proximal, Distal, and Contralateral Effects of Blood Flow Restriction Training on the Lower Extremities: A Randomized Controlled Trial. *Sports Health*. 2019;11(2):149-156. doi:10.1177/1941738118821929
30. Lind M, Enderlein D, Nielsen T, Christiansen SE, Faunø P. Clinical outcome after reconstruction of the medial patellofemoral ligament in paediatric patients

- with recurrent patella instability. *Knee Surgery, Sport Traumatol Arthrosc.* 2016;24(3):666-671. doi:10.1007/s00167-014-3439-x
31. Tanaka MJ, Chahla J, Farr J, et al. Recognition of evolving medial patellofemoral anatomy provides insight for reconstruction. *Knee Surgery, Sport Traumatol Arthrosc.* 2019;27(8):2537-2550. doi:10.1007/s00167-018-5266-y
32. Huston KL, Okoroafor UC, Kaar SG, Wentt CL, Saluan P, Farrow LD. Evaluation of the Schöttle Technique in the Pediatric Knee. *Orthop J Sport Med.* 2017;5(11). doi:10.1177/2325967117740078
33. Shea KG, Polousky JD, Jacobs JC, et al. The Patellar Insertion of the Medial Patellofemoral Ligament in Children: A Cadaveric Study. *J Pediatr Orthop.* 2015;35(4):e31-e35. doi:10.1097/BPO.0000000000000399
34. Ridley TJ, MacAlena JA, Arendt EA. Subspecialty procedures: Isolated medial patellofemoral ligament reconstruction with semitendinosus tendon allograft. *JBJS Essent Surg Tech.* 2018;8(1). doi:10.2106/JBJS.ST.17.00033
35. Schiphouwer L, Rood A, Tigchelaar S, Koëter S. Complications of medial patellofemoral ligament reconstruction using two transverse patellar tunnels. *Knee Surgery, Sport Traumatol Arthrosc.* 2017;25(1):245-250. doi:10.1007/s00167-016-4245-4
36. Shea KG, Martinson WD, Cannamela PC, et al. Variation in the Medial Patellofemoral Ligament Origin in the Skeletally Immature Knee: An Anatomic Study. *Am J Sports Med.* 2018;46(2):363-369. doi:10.1177/0363546517738002
37. Shea KG, Styhl AC, Jacobs JC, et al. The Relationship of the Femoral Physis and the Medial Patellofemoral Ligament in Children. *Am J Sports Med.* 2016;44(11):2833-2837. doi:10.1177/0363546516656366
38. Shea KG, Polousky JD, Jacobs JC, et al. The relationship of the femoral physis and the medial patellofemoral ligament in children: A cadaveric study. *J Pediatr Orthop.* 2014;34(8):808-813. doi:10.1097/BPO.0000000000000165
39. Farrow LD, Alentado VJ, Abdulnabi Z, Gilmore A, Liu RW. The relationship of the medial patellofemoral ligament attachment to the distal femoral physis. *Am J Sports Med.* 2014;42(9):2214-2218. doi:10.1177/0363546514539917
40. Uppstrom TJ, Price M, Black S, Gausden E, Haskel J, Green DW. Medial patellofemoral ligament (MPFL) reconstruction technique using an epiphyseal femoral socket with fluoroscopic guidance helps avoid physeal injury in skeletally immature patients. *Knee Surgery, Sport Traumatol Arthrosc.* 2019;27(11):3536-3542. doi:10.1007/s00167-019-05412-7
41. Spang RC, Tepolt FA, Paschos NK, Redler LH, Davis EA, Kocher MS. Combined reconstruction of the medial patellofemoral ligament (MPFL) and medial quadriceps tendon-femoral ligament (MQTFL) for patellar instability in children and adolescents: Surgical technique and outcomes. *J Pediatr Orthop.* 2019;39(1):e54-e61. doi:10.1097/BPO.0000000000001259
42. Weber AE, Nathani A, Dines JS, et al. An Algorithmic Approach to the Management of Recurrent Lateral Patellar Dislocation. *J Bone Jt Surg.* 2016;98(5):417-427. doi:10.2106/JBJS.O.00354
43. Parikh SN, Redman C, Gopinathan NR. Simultaneous treatment for patellar instability and genu valgum in skeletally immature patients. *J Pediatr Orthop B.* 2019;28(2):132-138. doi:10.1097/BPB.0000000000000546
44. Tan SHS, Tan LYH, Lim AKS, Hui JH. Hemiepiphysiodesis is a potentially effective surgical management for skeletally immature patients with patellofemoral instability associated with isolated genu valgum. *Knee Surgery, Sport Traumatol Arthrosc.* 2019;27(3):845-849. doi:10.1007/s00167-018-5127-8
45. Wilson PL, Black SR, Ellis HB, Podeszwa DA. Distal Femoral Valgus and Recurrent Traumatic Patellar

- Instability. *J Pediatr Orthop*. 2018;38(3):e162-e167. doi:10.1097/BPO.0000000000001128
46. Franciozi CE, Ambra LF, Albertoni LJB, et al. Increased Femoral Anteversion Influence Over Surgically Treated Recurrent Patellar Instability Patients. *Arthrosc J Arthrosc Relat Surg*. 2017;33(3):633-640. doi:10.1016/J.ARTHRO.2016.09.015
47. PM S, JM G, LA A, JB M, J N, JW K. Success of Torsional Correction Surgery After Failed Surgeries for Patellofemoral Pain and Instability. *Strateg trauma limb Reconstr*. 2014;9(1). doi:10.1007/S11751-013-0181-8
48. Server F, Miralles RC, Garcia E, Soler JM. Medial rotational tibial osteotomy for patellar instability secondary to lateral tibial torsion. *Int Orthop*. 1996;20(3):153-158. doi:10.1007/s002640050053
49. Cameron JC, Saha S. EXTERNAL TIBIAL TORSION. AN UNDERRECOGNIZED CAUSE OF RECURRENT PATELLAR DISLOCATION. *J Pediatr Orthop*. 1997;17(1):132. doi:10.1097/01241398-199701000-00036
50. Sanchis-Alfonso V, Montesinos-Berry E, Ramirez-Fuentes C, Leal-Blanquet J, Gelber PE, Monllau JC. Failed medial patellofemoral ligament reconstruction: Causes and surgical strategies. *World J Orthop*. 2017;8(2):115-129. doi:10.5312/wjo.v8.i2.115
51. Zhang ZJ, Zhang H, Song GY, Zheng T, Ni QK, Feng H. Increased femoral anteversion is associated with inferior clinical outcomes after MPFL reconstruction and combined tibial tubercle osteotomy for the treatment of recurrent patellar instability. *Knee Surgery, Sport Traumatol Arthrosc*. 2019;28(7). doi:10.1007/s00167-019-05818-3
52. Kaiser P, Schmoelz W, Schöttle PB, Heinrichs C, Zwierzina M, Attal R. Isolated medial patellofemoral ligament reconstruction for patella instability is insufficient for higher degrees of internal femoral torsion. *Knee Surgery, Sport Traumatol Arthrosc*. 2019;27(3):758-765. doi:10.1007/s00167-018-5065-5
53. Nelitz M, Dreyhaupt J, Williams SRM, Dornacher D. Combined supracondylar femoral derotation osteotomy and patellofemoral ligament reconstruction for recurrent patellar dislocation and severe femoral anteversion syndrome: surgical technique and clinical outcome. *Int Orthop*. 2015;39(12):2355-2362. doi:10.1007/s00264-015-2859-7
54. Robert A. Teitge M. Osteotomy in the Treatment of Patellofemoral Instability. *Tech Knee Surg*. 2006;5(1):2-18.
55. Drexler M, Dwyer T, Dolkart O, et al. Tibial rotational osteotomy and distal tuberosity transfer for patella subluxation secondary to excessive external tibial torsion: surgical technique and clinical outcome. *Knee Surgery, Sport Traumatol Arthrosc*. 2014;22(11):2682-2689. doi:10.1007/s00167-013-2561-5
56. Seeley MA, Knesek M, Vanderhave KL. Osteochondral injury after acute patellar dislocation in children and adolescents. *J Pediatr Orthop*. 2013;33(5):511-518. doi:10.1097/BPO.0b013e318288b7a0
57. Zheng L, Shi H, Feng Y, Sun BS, Ding HY, Zhang GY. Injury patterns of medial patellofemoral ligament and correlation analysis with articular cartilage lesions of the lateral femoral condyle after acute lateral patellar dislocation in children and adolescents: An MRI evaluation. *Injury*. 2015;46(6):1137-1144. doi:10.1016/j.injury.2015.02.001
58. Weeks KD, Fabricant PD, Ladenhauf HN, Green DW. Surgical options for patellar stabilization in the skeletally immature patient. *Sports Med Arthrosc*. 2012;20(3):194-202.
59. Arendt EA, Askenberger M, Agel J, Tompkins MA. Risk of Redislocation After Primary Patellar Dislocation: A Clinical Prediction Model Based on Magnetic Resonance Imaging Variables. *Am J Sports Med*. 2018;46(14):3385-3390. doi:10.1177/0363546518803936
60. Luhmann SJ, Schoenecker PL, Dobbs MB, Gordon JE. Arthroscopic Findings at the Time of Patellar Realignment Surgery in Adolescents. *J Pediatr Orthop*. 2007;27(5):493-498. doi:10.1097/BPO.0b013e318093f4d8

61. Garin C, Chaker M, Dohin B, Kohler R. Traitement chirurgical des luxations et instabilités patellaires chez l'enfant et l'adolescent par transfert ligamento-périosté: À propos d'une série de 35 patients (50 genoux). *Rev Chir Orthop Reparatrice Appar Mot.* 2007;93(7):690-700. doi:10.1016/S0035-1040(07)73254-3
62. Nietosvaara Y, Paukku R, Palmu S, Donell ST. Acute patellar dislocation in children and adolescents: Surgical technique. *J Bone Jt Surg - Ser A.* 2009;91(SUPPL. 2):139-145. doi:10.2106/JBJS.H.01289
63. Marsh JS, Daigneault JP, Sethi P, Polzhofer GK. Treatment of recurrent patellar instability with a modification of the Roux-Goldthwait technique. *J Pediatr Orthop.* 2006;26(4):461-465. doi:10.1097/01.bpo.0000217711.34492.48
64. Uppstrom TJ, Price M, Black S, Gausden E, Haskel J, Green DW. Medial patellofemoral ligament (MPFL) reconstruction technique using an epiphyseal femoral socket with fluoroscopic guidance helps avoid physeal injury in skeletally immature patients. *Knee Surgery, Sport Traumatol Arthrosc.* 2019;27(11):3536-3542. doi:10.1007/s00167-019-05412-7