

Surgical Technique: Power Pedicle Preparation and Screw Insertion in the Treatment of Pediatric Spinal Deformity

Kenneth David Illingworth, MD¹; Lindsay M. Andras, MD¹; Amy A. Claeson, PhD²; David L. Skaggs, MD, MMM¹

¹Children’s Hospital of Los Angeles, University of Southern California, Los Angeles, CA; ²Zimmer Biomet Spine, Westminster, CO

Introduction

Pedicle screw fixation has been shown to be a safe and effective treatment for spinal deformity ¹⁻⁶, and is the mainstay of posterior spinal instrumentation. Classically, pedicle preparation and screw insertion has been performed with manual tools and a manual technique. Studies have shown that surgeons are at significantly increased risks of developing musculoskeletal overuse injuries compared to the general public ⁷⁻¹⁰. The self-reported prevalence of a symptomatic cervical disc herniation is about 100 times higher in spinal deformity surgeons than the general population ⁷. A survey of members of the Pediatric Orthopedic Society of North America found a high incidence of musculoskeletal disorders and recommended the use of power tools instead of manual tools when applicable ⁸.

At our institution, power pedicle preparation and screw insertion has been used for the last 12 years with over 20,000 pedicle screws. Power pedicle preparation has the potential to decrease the force required for insertion on the patient, increase proprioception for the surgeon, increase accuracy, and possibly decreasing the incidence of overuse injuries for the spine surgeon. Preliminary data shows that manual pedicle preparation can result in electromyography activity far above that of power preparation (Figure 1) ¹¹.

In addition to decreased muscle exertion, there is less screw wobble with power insertion compared to manual techniques (Figure 2) ¹². A previous study of 4,542 screws placed with this technique found shorter fluoroscopy times, a lower revision rate, and a decrease in surgical time in idiopathic patients compared with using manual tools ¹³. In a recent unpublished multicenter collaboration, we analyzed 27,662 pedicle screws placed in 1712 patients performed by 6 fellowship-trained pediatric orthopaedic surgeons using

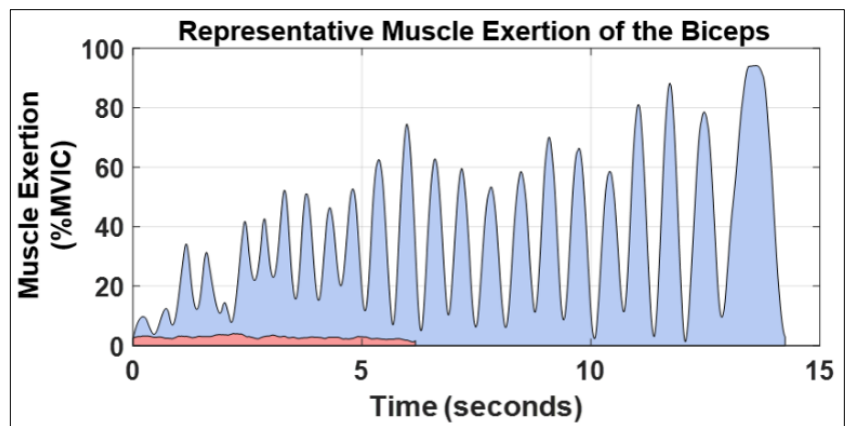


Figure 1. % Maximum voluntary isometric contraction (MVIC) of the biceps during power pedicle preparation utilizing both the power (red) and manual techniques (blue). In the biceps, MVC was consistently over 35% in the manual technique group, which is considered in the high exertion zone. All photos property of Children’s Orthopaedic Center, Children’s Hospital of Los Angeles.

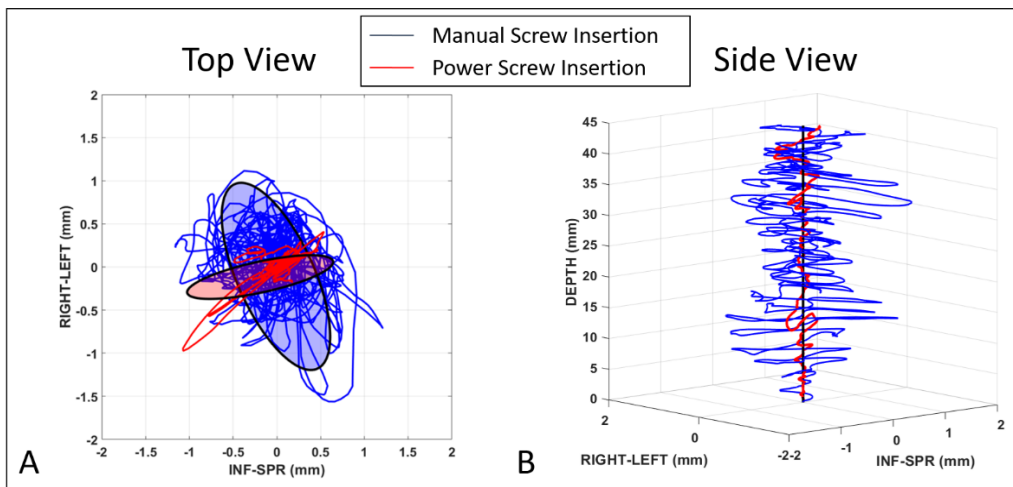


Figure 2. A) Top down view looking at screw wobble in the medial, lateral, cephalad and caudal directions during power screw insertion (red) and manual screw insertion (blue). There is less wobble in the power screw insertion, especially in the cephalad/caudal direction. B) Side view looking at screw wobble in the cephalad and caudal directions during power screw insertion (red) and manual screw insertion (blue).

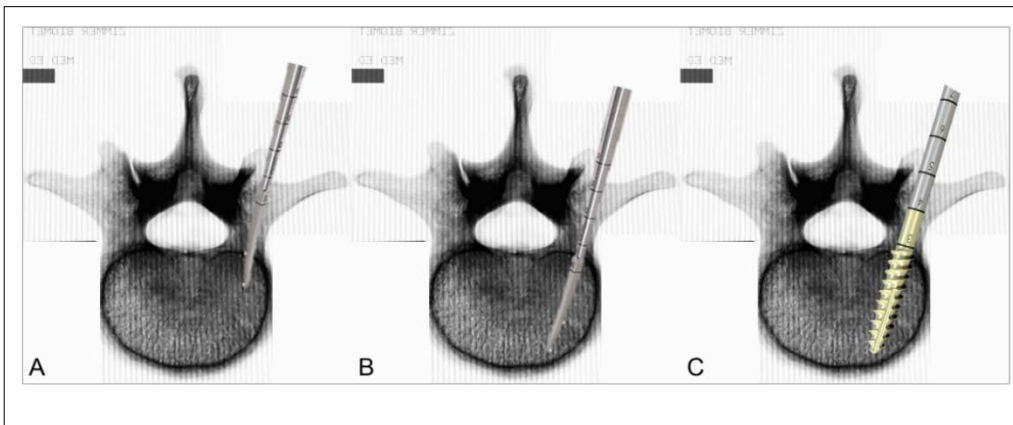


Figure 3: Technique for manual pedicle preparation. A) Curved thoracic probe is angled laterally to 20 mm. B) The curved probe is then angled medially past the canal and advanced to the required depth or until the anterior wall of the vertebral body is encountered. C) Traditional manual techniques describe tapping the pedicle prior to screw insertion.

power pedicle screw preparation and screw insertion, which confirmed its safety and efficacy. Similarly, another series reported that the use of power for percutaneous pedicle screw insertion vs. manual screw insertion results in equivalent safety with powered screws taking less than half the mean time per screw, but in this study the pedicle tract was developed manually for all screws¹⁴.

The purpose of this paper will be to briefly review the manual technique for pedicle preparation and screw insertion and provide a detailed description of the power technique that is utilized at our institution by all 3 authors.

Manual Techniques

Traditional pedicle preparation has been done with the use of a pedicle probe. Pedicle probes come in different shapes and sizes, but the most common type of probe used is a curved thoracic probe with a pointed tip. The traditional technique employs placing the curved pedicle probe through a starting burr hole with the curve probed directed laterally (Figure 3A). The probe is advanced in a back and forth twisting motion to approximately 20 mm. A 20 mm depth allows for passage past the spinal canal. The curved probe is removed, and a ball tip is inserted to assess for breaches. The curved probe is inserted back to a depth of 20 mm with the tip pointed laterally, the tip is then angled medially and advanced to the desired depth or until the anterior vertebral body is palpated (Figure 3B). The curved probe is

removed, and a ball tip is inserted again to assess for breaches. An appropriately sized screw is selected based on the pedicle probe depth. Depending on surgeon preference, the pedicle track can be tapped prior to screw insertion (Figure 3C). The screw is then inserted along the pedicle track with the use of a manual screwdriver, and imaging is confirmed.

Power Pedicle Preparation and Screw Insertion

For posterior spinal fusion and segmental instrumentation, the posterior midline surgical exposure is used. Dissection of the posterior elements of the spine is carried out with standard techniques. In the thoracic and lumbar spine, all soft tissue is meticulously dissected off the posterior elements for clear identification of all landmarks. In the thoracic and lumbar spine, the spinous process, lamina, facet joints, and transverse process are identified and cleared of all tissue (Figure 4A). Meticulous dissection allows for adequate visualization of surface landmarks for freehand placement of pedicle screws and also optimizes surface area for bone grafting and fusion. Wide facetectomies are performed throughout the thoracic and lumbar spine as dictated by the deformity (Figure 4B). We prefer the use of an ultrasonic harmonic bone scalpel for our facetectomies as it decreases blood loss per level compared to other techniques, and is less forceful than an osteotome and mallet¹⁵. In the thoracic spine, the midline of the superior articular process is identified, and just lateral to the midline is the starting point from a medial to lateral direction for creation of the burr hole

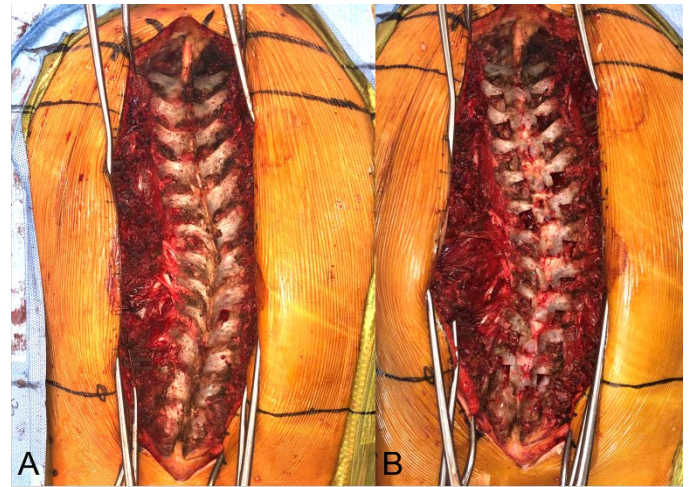


Figure 4. A) Posterior spinal dissection with identification and clearance of all soft tissue from the spinous process, lamina, facets and transverse process. B) Wide facetectomies are performed which gives clear visualization of the superior articular process.

for screw placement. Extreme care should be taken not to start medial to the midpoint of the superior articular process, as this can lead to canal breach and neurological injury. We use fluoroscopy for screw preparation and placement only as needed, such as in cases with challenging pedicle morphology or abnormal anatomical landmarks, such as in revision cases or congenital

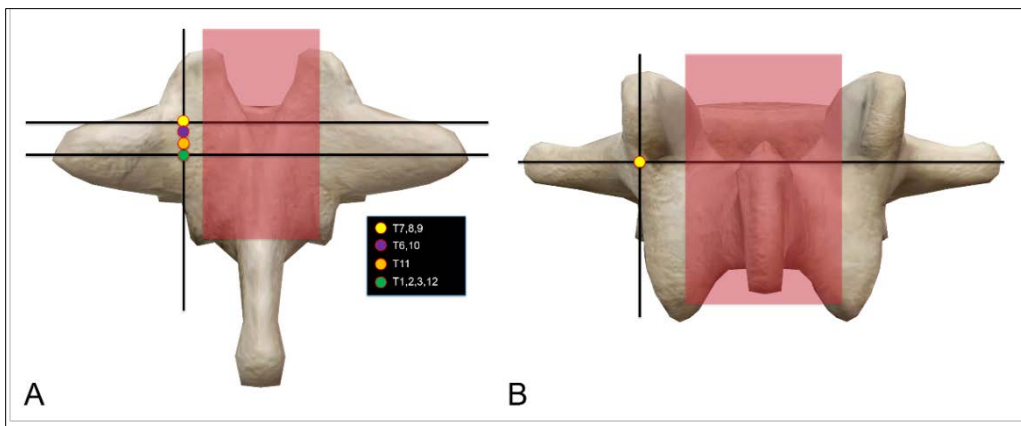


Figure 5: A) Burr hole starting point for thoracic pedicles. Cephalad to caudal starting point changes based on thoracic level. B) Starting point for lumbar pedicles, which is at the junction of the lateral border of the pars interarticularis and the midpoint of the transverse process.

curves. The cephalad and caudal placement of the starting point depends on the thoracic level (Figure 5A). An easy mnemonic to follow is “7,8,9 on the line,” where the pedicle starting point for thoracic vertebrae 7-9 is in line with the top of the transverse process. In the lumbar spine, the starting point for pedicle insertion is at the junction of the midpoint of the transverse process and the lateral border of the pars interarticularis (Figure 5B).

Power pedicle preparation and screw insertion should be a reliably low stress and efficient part of the spine fusion and instrumentation. A scrub technician who is

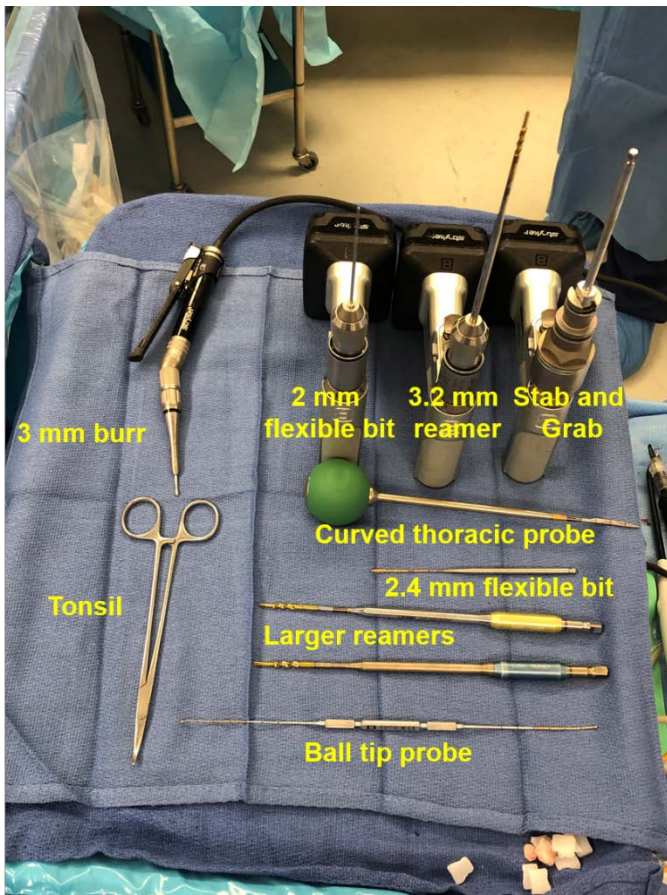


Figure 6. Tools needed/available during power pedicle preparation and screw insertion. Standard Mayo stand setup includes 3 mm burr, 2 mm or 2.4 mm flexible drill bit, 3.2 mm reamer, ball tip probe and stab/grab screw shaft. Having three intra-operative power drills available facilitates efficient screw preparation and insertion workflow. Larger reamers are available for bigger pedicles.

experienced in the power steps is invaluable. During screw tract preparation and insertion, the technician’s mayo stand should be optimized to facilitate a smooth transition of drills and instruments back and forth between the surgeon and technician with ease and minimal effort (Figure 6). A 3mm burr is used to create a hole in the posterior elements with a depth allowing passage through the cortex of the posterior elements as the entry point. A 2 mm flexible drill is inserted through the opening burr hole. A standard intraoperative power drill can be used safely as long as the speed of the drill

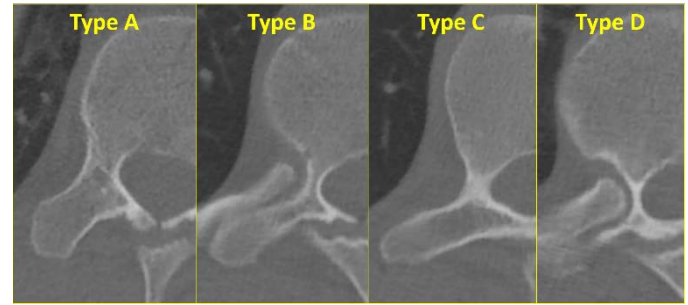


Figure 7. About 90% of pedicles are Type A (large cancellous channel) and B (small cancellous channel), and a slowly revolving flexible drill bit will deflect off the cortical walls and self-center in the cancellous center. For Type C (cortical channel) and D (slit/absent channel) pedicles; hammering a probe through the cortical pedicle and/or into the vertebral body has been suggested by some authors. We propose using a stiff drill with controlled force and excursion as an alternative.

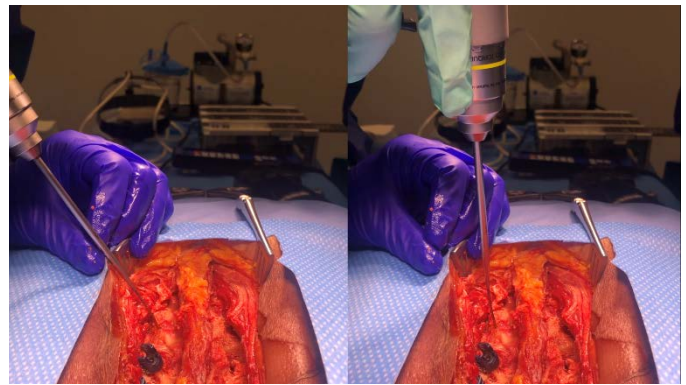


Figure 8. Example of the flexibility of the 2.4 mm drill bit.

can be easily varied, particularly to allow slow enough rotation, as needed based on pedicle morphology.

For 90% of pedicles with a cancellous center (Type A and B pedicles) (Figure 7) the drill bit should be rotated very slowly, as low as 1 revolution per second. A slowly rotating drill bit allows the surgeon to palpate the sharp ends of the drill bit, encountering the hard cancellous wall of the pedicle, then self-centering into the softer cancellous bone in the center of the pedicle. One should spin the drill slowly enough so that they can clearly visualize the grooves on the side of the bit. A

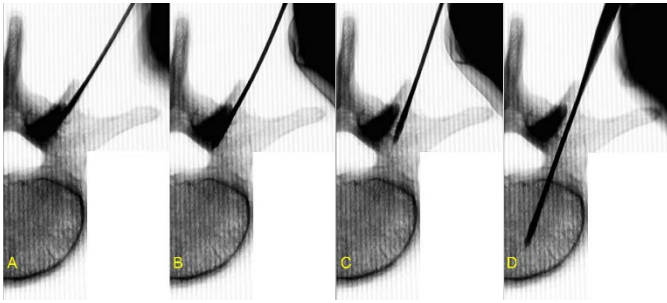


Figure 9. Axial fluoroscopic view demonstrating power pedicle preparation with the flexible drill. The medial cortex of the pedicle is often the densest part. Small angular corrections can direct the bit to “bounce” off the medial cortex and then down into the softer pedicle channel.

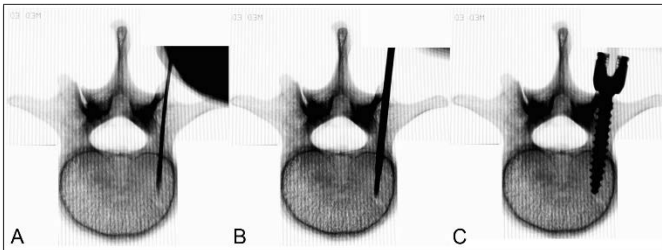


Figure 10. A) Flexible drill bit is inserted through the pedicle and just past the canal. B) The reamer is inserted and can be advanced to the required depth. The blunt tip of the reamer gives excellent feedback for when the anterior wall of the vertebral body is reached, which can maximize pedicle preparation length. C) An appropriately sized pedicle screw is selected and inserted down with the same trajectory as the reamer.

frequent pitfall when learning this technique is to rotate the drill bit too fast, as is the proper technique for drilling the cortex of long bones. Spinning the drill bit very fast decreases proprioceptive feedback and can lead to violation of the pedicle cortex. The flexibility of the specially designed 2 mm drill bit allows the drill to deflect off hard cortical channels of the pedicle and redirects to preferentially advance down the pedicle channel (Figure 8). At first, the 2mm drill should be spun very slowly, at approximately 1-3 revolutions per second. Often small angular adjustments are needed based on tactile feedback to redirect the drill bit (Figure 9). The technique should involve very little downward

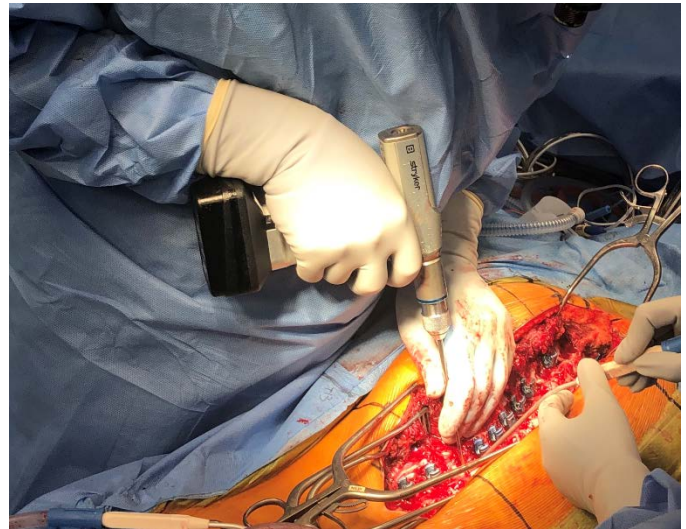


Figure 11. Use of the 3.2 mm reamer during thoracic power pedicle preparation. Notice the position of the hands: Right arm and hand are held close to the body for maximum control and accuracy while the left hand is guiding the reamer and is firmly planted on the patient for safety.

force. The weight of the cordless driver alone often provides enough force for advancement and excellent haptic feedback of the drill bit in larger pedicles. Once the pedicle channel is found, the threads of the drill bit will self-advance the drill bit. This presents a sensation of the drill bit being “pulled” into the pedicle and provides excellent feedback and confidence that the pedicle has been adequately found. The drill bit is advanced to a depth of ~20 mm (Figure 10A). A standard ball tip probe is used in order to verify position within the pedicle and confirmation of the intact medial, lateral, cephalad, caudal walls without breach.

A 3.2 mm blunt-tipped reamer is inserted into the pedicle channel to complete the pedicle cannulation/dilation (Figure 10B). Have “soft hands” when inserting the reamer to allow the reamer to self-center into the previously made tract (Figure 11). The speed of the reamer can be varied and allows for different haptic feedback with different tools. Slow spinning allows the threads to pull in the reamer. The blunt-tipped reamer allows for excellent proprioceptive

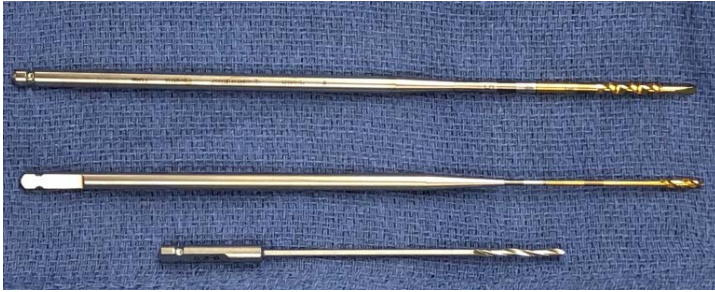

Figure 12: Close up view of the 3.2 mm blunt-tipped reamer (top) 2.4 mm flexible drill bit (middle) and the 2.0 standard flexible drill bit (bottom).

feedback of the anterior wall of the vertebral body, which helps maximize pedicle screw cannulation length and helps prevent anterior wall breach. One must be cautious in patients with poor bone quality, such as in neuromuscular scoliosis, as the anterior wall can still be breached with the blunt-tipped reamer, and damage to ventral structures can occur. Again, a standard ball tip probe is used in order to verify position within the pedicle and confirmation of the intact medial, lateral, cephalad, caudal walls. Smaller or larger reamers are also available for varying pedicle diameters. We do not routinely tap prior to screw insertion. Our goal is simply to dilate the pedicle and not cut threads. Over insertion or malposition of the tap can result in catastrophic damage to surrounding structures. If tapping is desired, we recommend using it with manual techniques, as a drill stuck in the “on” position for whatever reason can advance a tap much further than intended.

An alternative to the 2 mm flexible standard drill is a 2.4 mm flexible drill bit (Figure 12). This special drill bit allows for more flexibility of the shaft while having a slightly larger diameter thread that “pulls” the drill bit into the soft cancellous center of the pedicle more effectively than a standard 2mm drill bit. When using the 2.4mm drill bit, the pedicle tract is sufficiently large that pedicle screws with diameters up to 6.5 mm can usually be inserted without further reaming or dilating of the canal. If one is going to use only the 2.4 mm drill bit, and not use the 3.2 mm blunt tip reamer; extreme caution must be used not to violate the anterior cortex of

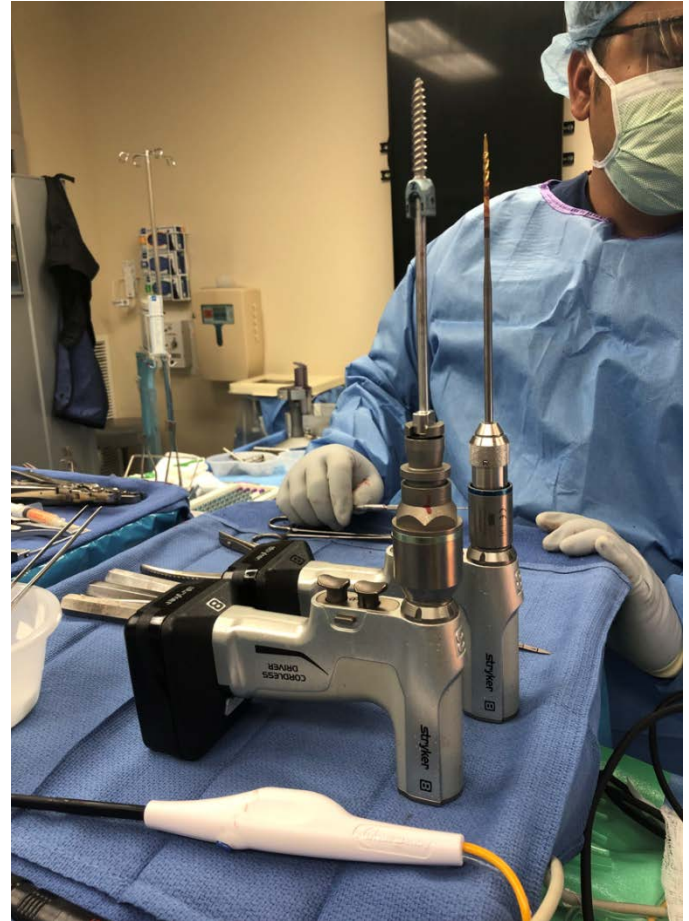

Figure 13. Stab and grab setup on the Mayo stand.

the vertebral body, as a sharp drill bit inserted into a vascular structure could be catastrophic.

A screw is selected 5 mm shorter than the depth of the pedicle tract as measured by the reamer as a margin of safety, and the length is verified by holding it against the length of the ball tip probe inserted at maximum depth. If the anterior cortex is not violated, a screw length the same length of the pedicle tract may be selected if a longer pedicle screw is desired. For power pedicle screw insertion, we prefer the “stab and grab” approach (Figure 13). There are commercially available power pedicle screwdrivers, however, we find the stab and grab approach to be quicker, more efficient, and safer under the proper technique. The pedicle screw attaches to the screwdriver shaft in a way that allows a few degrees of

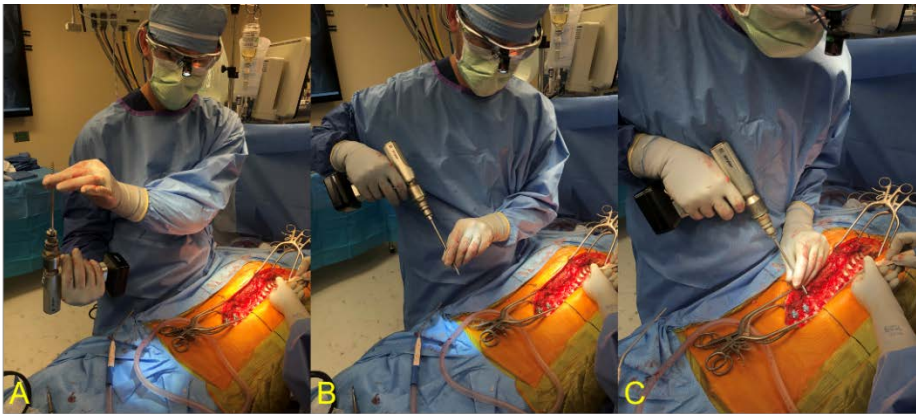


Figure 14. The pedicle screw is not full secured within the stab and grab screw shaft, as is with threaded insertion devices. Therefore, the screw must be controlled and secured during receiving and insertion. A) Passage from scrub technician to surgeon with grasping of the pedicle tulip. B) The tulip is firmly held, and drill orientated for insertion. Care must be taken at this point while over the spine, as the screw can fall if not handled appropriately which can result in neurological injury over an exposed spinal canal. C) Position for power screw insertion. As with the power reamer, the hands are in an ergonomically favorable and safe position.

freedom relative to the axis of the shaft, to allow the screw to self-center into the pedicle channel. The pedicle screw is not firmly attached to allow for rapid removal, and therefore care must be taken to control the pedicle screw at all times, especially when handling near exposed canal. The tulip of the pedicle screw should always be held to help control the pedicle screw during insertion (Figure 14). The pedicle screw is inserted to the desired depth, and the screwdriver shaft is removed. All pedicle screws are imaged with intraoperative AP fluoroscopy to assure good placement. Screws located at T6 and below are stimulated, and if the response is below acceptable thresholds, or a screw stimulates much lower than the other screws, the screw is investigated by removal and probing the tract and/or palpating or visualizing the pedicle from within the canal.

For small or challenging pedicle morphology, a similar technique can be implemented. In these situations, one must employ more patience with use of the small drill.

For type C pedicles, with a cortical channel, the drill bit must be spun fast enough to go through the cortical bone. Similar to using a pedicle probe, one should err laterally to avoid medial penetration into the canal. If adequately directed, the small flexible drill can be used in order to cannulate a small pedicle or pedicle, which is mostly cortical. For type D pedicles, a stiff drill bit is needed (Figure 7) ¹⁶. A standard 2.7 mm or 3.0

mm drill bit offers less flexibility but greater control in placing juxtapedicular screws. A flexible drill bit can skive off the hard pedicle and the vertebral body. A stiff, sharp drill bit can be used to palpate the lateral edge of the type D pedicle, then engage the vertebral body with firm but well controlled pressure, then drill into the vertebral body. Curved probes should be available and are used for salvaging of breached pedicles or reserved for more challenging pedicle morphology or locations, especially while surgeons are gaining familiarity with power pedicle tract preparation. For example, in patients with large body habitus, getting the appropriate angle for lower lumbar screws can be difficult as the upper aspect of the drill and reamer may get entrapped in soft tissue. In these situations, the use of a standard size or long curved probe can aid in pedicle cannulation.

Conclusion

Power pedicle preparation and screw insertion offers a safe and efficient alternative to manual techniques with the following potential advantages:

- less screw toggle, which is associated with stronger screw purchase
- less force applied to the patient's spine, which is intuitively desirable from a safety standpoint
- less muscle exertion for the surgeon, which could help prevent overuse injuries for which surgeons are at risk

[Link to surgical technique video](#)

References

1. Asghar J, Samdani AF, Pahys JM, et al. Computed tomography evaluation of rotation correction in adolescent idiopathic scoliosis: a comparison of an all pedicle screw construct versus a hook-rod system. *Spine (Phila Pa 1976)*. 2009;34(8):804-807.
2. Dobbs MB, Lenke LG, Kim YJ, Kamath G, Peelle MW, Bridwell KH. Selective posterior thoracic fusions for adolescent idiopathic scoliosis: comparison of hooks versus pedicle screws. *Spine (Phila Pa 1976)*. 2006;31(20):2400-2404.
3. Liljenqvist U, Lepsien U, Hackenberg L, Niemeyer T, Halm H. Comparative analysis of pedicle screw and hook instrumentation in posterior correction and fusion of idiopathic thoracic scoliosis. *Eur Spine J*. 2002;11(4):336-343.
4. Wu X, Yang S, Xu W, et al. Comparative intermediate and long-term results of pedicle screw and hook instrumentation in posterior correction and fusion of idiopathic thoracic scoliosis. *J Spinal Disord Tech*. 2010;23(7):467-473.
5. Yilmaz G, Borkhuu B, Dhawale AA, et al. Comparative analysis of hook, hybrid, and pedicle screw instrumentation in the posterior treatment of adolescent idiopathic scoliosis. *J Pediatr Orthop*. 2012;32(5):490-499.
6. Ledonio CG, Polly DW, Jr., Vitale MG, Wang Q, Richards BS. Pediatric pedicle screws: comparative effectiveness and safety: a systematic literature review from the Scoliosis Research Society and the Pediatric Orthopaedic Society of North America task force. *J Bone Joint Surg Am*. 2011;93(13):1227-1234.
7. Auerbach JD, Weidner ZD, Milby AH, Diab M, Lonner BS. Musculoskeletal disorders among spine surgeons: results of a survey of the Scoliosis Research Society membership. *Spine (Phila Pa 1976)*. 2011;36(26):E1715-1721.
8. Alzahrani MM, Alqahtani SM, Tanzer M, Hamdy RC. Musculoskeletal disorders among orthopedic pediatric surgeons: an overlooked entity. *J Child Orthop*. 2016;10(5):461-466.
9. AlQahtani SM, Alzahrani MM, Harvey EJ. Prevalence of musculoskeletal disorders among orthopedic trauma surgeons: an OTA survey. *Can J Surg*. 2016;59(1):42-47.
10. Alqahtani SM, Alzahrani MM, Tanzer M. Adult Reconstructive Surgery: A High-Risk Profession for Work-Related Injuries. *J Arthroplasty*. 2016;31(6):1194-1198.
11. Skaggs DL, Schwab F, Cleason A, Ghandi A. Power-Assisted Pedicle Screw Insertion Reduces Muscle Exertion. *Congress of Neurological Surgeons Annual Meeting*. 2019.
12. Skaggs DL, Schwab F, Cleason A, Ghandi A. Increased Efficiency of Power-Assisted Pedicle Screw Placement. *Congress of Neurological Surgeons Annual Meeting*. 2019.
13. Seehausen DA, Skaggs DL, Andras LM, Javidan Y. Safety and Efficacy of Power-Assisted Pedicle Tract Preparation and Screw Placement. *Spine Deform*. 2015;3(2):159-165.
14. Kojima A, Fujii A, Morioka S, Torii Y, Arai K, Sasao Y. Safety and Efficacy of Percutaneous Pedicle Screw Placement Using a Power Tool. *Spine Surg Relat Res*. 2018;2(1):60-64.
15. Bartley CE, Bastrom TP, Newton PO. Blood Loss Reduction During Surgical Correction of Adolescent Idiopathic Scoliosis Utilizing an Ultrasonic Bone Scalpel. *Spine Deform*. 2014;2(4):285-290.
16. Watanabe K, Lenke LG, Matsumoto M, et al. A novel pedicle channel classification describing osseous anatomy: how many thoracic scoliotic pedicles have cancellous channels? *Spine (Phila Pa 1976)*. 2010;35(20):1836-1842.