

# The Contemporary Role for Hip Arthrodesis and Hip Replacement in Adolescents

Radomir Dimovski, MD and Ira Zaltz, MD

Children's Hospital of Michigan, Detroit, MI

**Abstract:** Hip arthrodesis and arthroplasty are historically proven options for end-stage arthritis in the young patient. Currently, patient and surgeon related factors influence choice of treatment. Arthrodesis relieves arthritic pain and enables modified function with expected eventual transition to arthroplasty. Conversion arthroplasty following arthrodesis provides good outcome with significant functional gain. Primary total hip arthroplasty for young patients is increasingly accepted due to improvements and consistency of implantation and more patient-expected natural levels of function. Advances in arthroplasty implants have increased component survivorship, but studies are still needed to determine outcomes using modern implants. Data supporting arthrodesis or arthroplasty for young patients with end-stage hip arthritis requires further study. This article summarizes the dilemma, provides current data in order to help guide decision-making.

## Key Concepts:

- End-stage hip arthritis in the young patient is an extremely challenging problem and one where long-term treatment options are limited.
- Hip arthrodesis can provide decades of pain relief for adolescents with unilateral hip arthrosis who may be a poor candidate (obesity, medical or social co-morbidities) for hip replacement. Later back and knee pain limits long term outcome.
- Hip arthroplasty is a good option for patients with the bilateral hip arthritis (e.g., sickle cell disease, chemotherapy-induced necrosis, inflammatory arthropathies); the desire for initial near normal hip motion is tempered by the uncertainty of implant survival and the need for multiple joint revisions.

## The Modern Dilemma

Pediatric hip conditions resulting in end-stage hip arthritis have been surgically treated using either arthroplasty or arthrodesis in order to reduce pain and improve function. Decision-making between an arthrodesis or arthroplasty is complex and influenced by surgeon age, fellowship training and experience, and patient factors. In a recent survey of members of the Pediatric Orthopaedic Society of North America (POSNA) and the American

Association of Hip and Knee Surgeons (AAHKS) clinical scenarios assessed surgeon preference for surgical management of end-stage unilateral hip arthritis in 18-year-old patients while varying patient gender, weight, and future job requirements.<sup>1</sup> For each procedure, this survey stratified surgeons by age and consideration of the trade-offs between providing younger patients with more function as a young adult using a total hip arthroplasty with the possibility of hindering mobility later in

life due to a failed arthroplasty. Older surgeons preferred arthrodesis over arthroplasty, while 82% of those surveyed agreed with the proposition that successful arthrodesis is technically more difficult than arthroplasty. Surgeons who believed that revision of total hip arthroplasty (THA) later in life posed a significant problem were more likely to recommend arthrodesis, while those surgeons who valued function as a young adult leaned toward THA. Contemporary improvements in hip implants, as well as fellowship training in joint arthroplasty, appear to create bias toward total hip arthroplasty in young patients.<sup>1</sup> The purpose of this article is to summarize the background and outline contemporary thought in order to provide guidance when arthrodesis or arthroplasty are treatment considerations for managing end-stage arthritis in the young hip.

#### *Limits of Arthrodesis*

Since the early 1980s, when and how to perform hip arthrodesis in the young patient with end-stage hip arthritis have a few studies with long-term follow-up that analyze patient outcomes. Callaghan et al. reported at an average of 20-25 years following arthrodesis, 60% of patients complained of ipsilateral knee pain and/or back pain, and 25% of patients developed contralateral hip pain.<sup>2</sup> The average age of these patients was 25.3 years at the time of fusion, and the etiology of these patients' hip arthritis was primarily caused by infection.

Sponseller et al., in a separate follow-up study averaging 39 years post-arthrodesis (range 31-55), also reported that in patients less than 35 years old at the time of hip arthrodesis, 57% of these patients developed low back pain, while 45% had knee pain though only 13% had been converted to total hip arthroplasty.<sup>3</sup> Patients treated by hip arthrodesis were found to have average overall activity levels comparable to their age group, well preserved walking ability, and no severe limitations in sexual function. Of note, the etiology of many of these patients' hip arthritis was linked to tuberculosis, which is less prevalent today. It is well accepted that hip arthrodesis is contraindicated in patients with the potential for early arthrosis of both hips such as bilateral AVN from systemic chemotherapy or blood dyscrasias such as

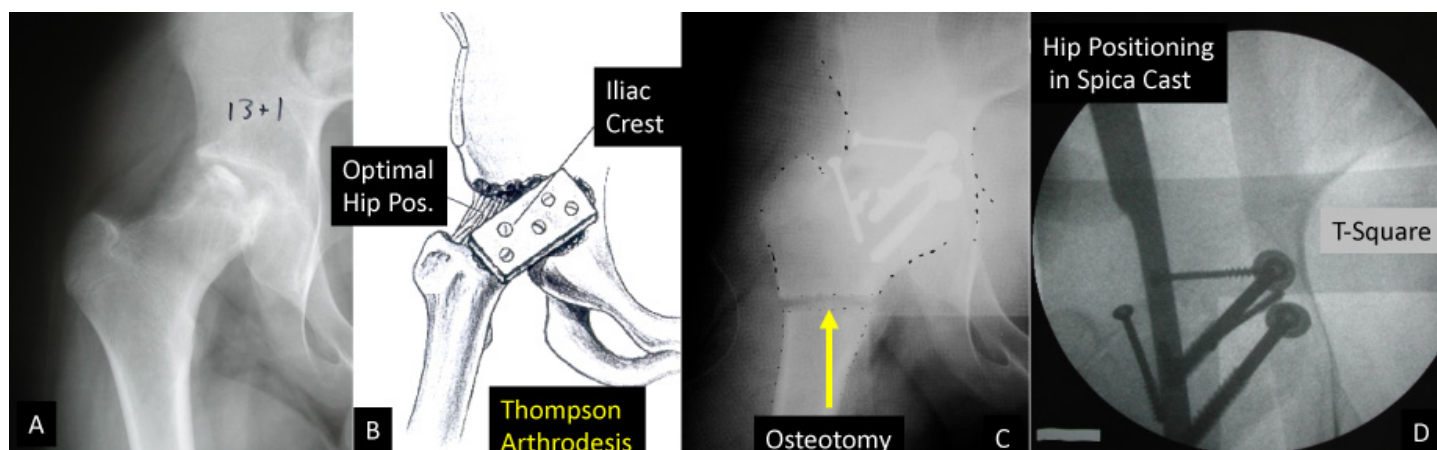


**Figure 1.** Professional athlete Bo Jackson acknowledges the crowd following a home run after his primary THR for post-traumatic avascular necrosis. He has had at least two revision surgeries since then.

sickle cell or Thalassemia. While hip arthrodesis still has a place in modern orthopaedics; it is generally understood that surgeon experience and patient expectations have evolved considerably, especially as technology has also evolved. It is hard for the young surgeon with extensive hip replacement training and who may have limited experience in arthrodesis to counsel a family for hip arthrodesis, especially when the parents remember Bo Jackson and his ability to return (for a few years) to professional athletics after a THR (Figure 1).

#### *Immediate and Long-Term Limitations of THR*

Though historical reports following arthrodesis suggest improvement in pain and function, the concept of



**Figure 2.** A. 13-year-old boy with end-stage Perthes Disease, B. Planning for a Thompson Arthrodesis, C. Intraoperative radiograph prior to cast application, D. Assessing hip position in a spica cast. Note the T-Square used to ensure neutral abduction.

providing a young patient with a total hip arthroplasty as an alternative to arthrodesis is appealing and increasingly accepted. However, the idealized goal of relieving pain, restoring function while preserving movement with THA is associated with specific risks and known complications. Factors related to previous hip surgery such as abductor deficiency, acetabular deformity following pelvic osteotomy, and proximal femoral deformity following osteotomy may lead to complications during and following THA.<sup>4,5</sup> Relative contraindications to THA in youth include history of septic arthritis or ongoing infection, severe obesity, repetitive impact loading, strenuous manual labor employment, inability to follow instructions, and general irresponsibility.

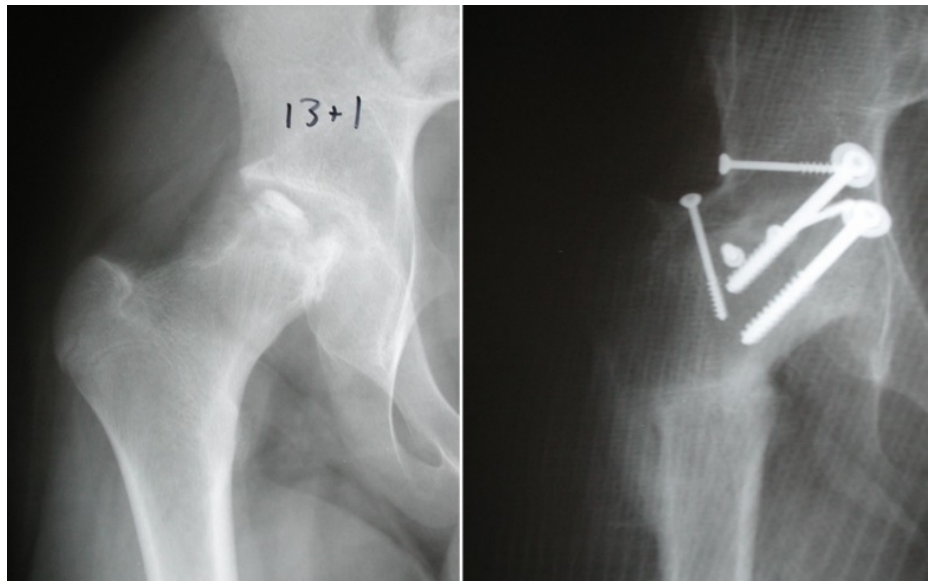
Although early reports of long-term follow-up of hip arthrodesis patients showed promising results, complete immobilization of the hip joint increases strain on adjacent articulations such that knee and back pain are the most frequent reason for conversion of the fused hip to an arthroplasty. The negative consequences of arthrodesis can be both functional and biomechanical causing deterioration of adjacent joints as the movement of the kinetic chain is altered. The primary complaints following hip arthrodesis include back pain affecting both sedentary and active patients, and the eventual development of ipsilateral knee ligamentous laxity in the anteroposterior or mediolateral planes.<sup>2,3</sup> Conversion of an

arthrodesis to a THA can improve movement and function, but results may be affected by the arthrodesis technique. Most common sequelae affecting results of THA are persistent abductor insufficiency causing a Trendelenberg gait pattern and upper femoral deformity increasing complexity and longevity of THA.<sup>2</sup> Despite functional limitations and structural consequences associated with a hip fusion, arthrodesis is still safe and effective for specific patients who are considered to be at increased risk for complications following THA.

#### *Indications for Arthrodesis*

Hip arthrodesis remains useful in young patients with unilateral end-stage hip arthritis in whom hip preservation methods may have failed or no longer provide promising prognosis.<sup>6</sup> In children who have bone defects or soft tissue defects that may compromise insertion and stability of THA implants or those with neuromuscular conditions, arthrodesis may be the single best option to produce a functional, stable, and pain-free hip with less risk than an arthroplasty.<sup>7</sup> Patients younger than 30 years old with previous hip surgeries resulting in excessive scar tissue or damage to abductor musculature, post-traumatic arthritis with bony defects, or post-infectious etiology appear to be strong candidates for hip arthrodesis versus arthroplasty.<sup>8</sup> Those who have preexisting low back pain, contralateral hip osteoarthritis or deformity that may predispose to arthritis, or ipsilateral knee pain

are at risk for progression of symptoms following hip arthrodesis, and, therefore, may not be suitable arthrodesis candidates. Despite general bias against performing an arthrodesis in a female, outcomes of hip arthrodesis have not been shown to be gender-dependent as male and female patients report similar outcomes, neither reported difficulties in sexual function, and females do not report problems during childbirth.<sup>2,8</sup> Nevertheless, there is current bias against arthrodesis due to the aforementioned structural and functional consequences, especially in females.



**Figure 3.** Six months after Thompson Arthrodesis

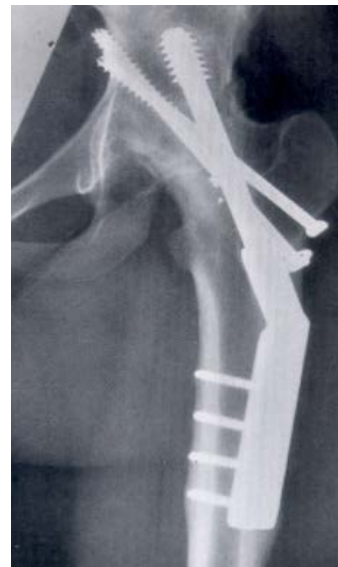### *Technical Considerations for Arthrodesis*

A functionally successful hip arthrodesis is highly correlated with precise limb alignment and position of fusion. Positioning of hip arthrodesis has shown superior outcomes in those patients who are fused between 15-30 degrees flexion, 0 degree of abduction and 10-15 degrees external rotation.<sup>8-13</sup> Hip flexion may be tailored individually for patient-specific level of function with patients who spend more time in a seated position benefiting from greater flexion near 25-30 degrees while those who will be walking or standing more benefiting from being near 15 to 20 degrees of flexion.<sup>8,10,11</sup> The angle of abduction or adduction is assessed by the anatomic axis of the femur relative to the horizontal axis of the pelvis.

*Tip: Consider a trip to your local hardware store for a steel 16-inch x 2-foot T-square that can be sterilized and used intraoperatively to ensure appropriate abduction.*

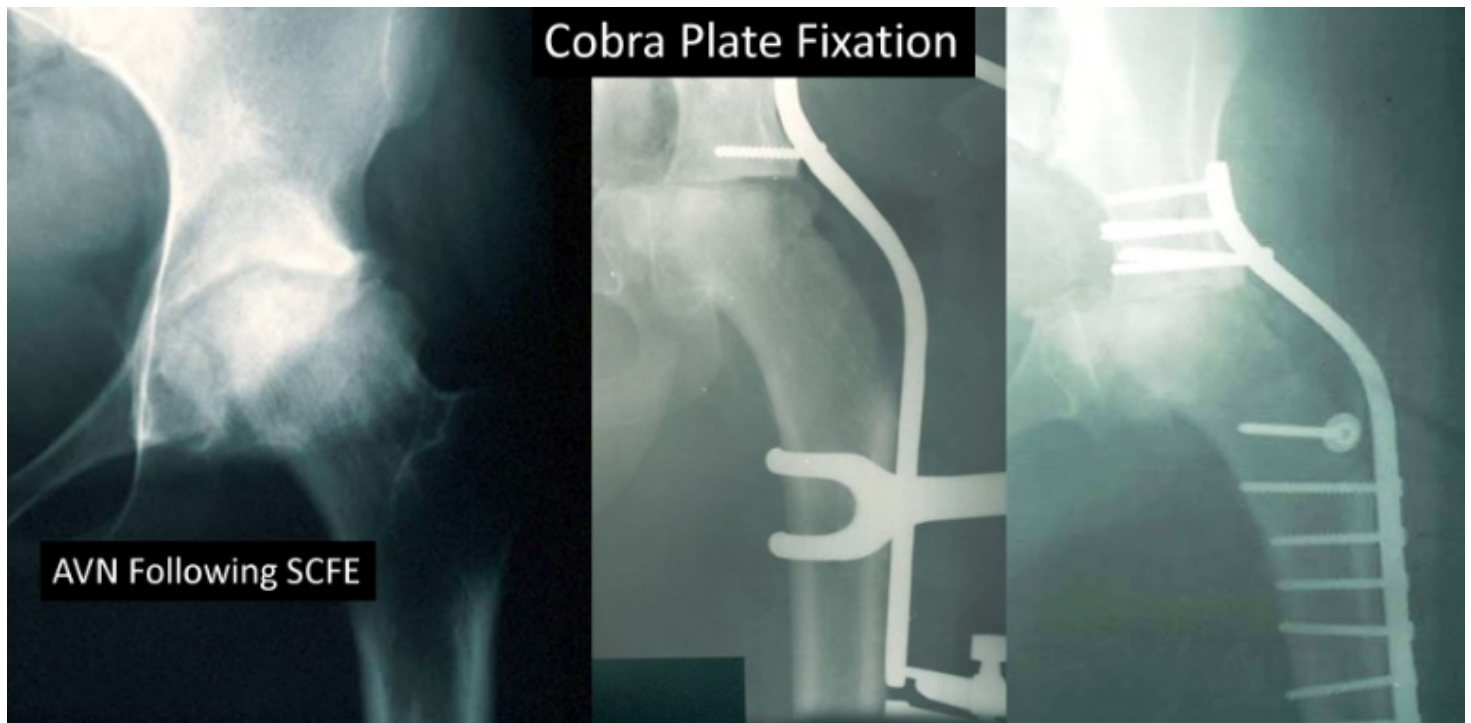
For patients with leg length discrepancy greater than 4cm, limb lengthening after hip fusion or timed epiphysiodesis of the contralateral limb are treatment options. Fusing a hip in slight abduction (10 degrees) can compensate for minor ipsilateral limb shortness.<sup>14</sup>

Multiple hip arthrodesis techniques have been described. The Thompson Arthrodesis technique should be considered in younger or smaller stature patients (Figure 2). In this procedure, the femoral head and the acetabulum are



**Figure 4.** Hip arthrodesis with a dynamic hip screw and supplementary screw fixation has the advantage of preserving the hip abductors, but fixation is not as secure in the acetabulum.

decorticated, and the femur is fixed to the acetabulum with screws and iliac crest. The femur is positioned in the best position to optimize femoral acetabular fusion. A subtrochanteric osteotomy allows the limb to angled to optimal hip fusion position and decreased risk of fusion failure. *Tip: It is important that while the femoral shaft is angled for optimal position that it doesn't translate to a great degree and thus make a later THR more challenging. After osteotomy, the surgeon can drill a hole on each side of the osteotomy and use a 5-0 Ethibond suture to maintain rough alignment while the*



**Figure 5.** Hip arthrodesis with a Cobra Plate. Through a trans-trochanteric osteotomy, the abductors are lifted, hip cartilage is denuded, and a Chiari osteotomy is performed. The hip is medially displaced and stabilized with the plate. The trochanter is reattached to the proximal femur. While this approach has a high fusion rate, later conversion to a THR will challenge the most skilled hip replacement surgeon. As such, this procedure is ill-advised in patients with normal hip abductor function prior to fusion or in patients when an anterior approach is feasible.

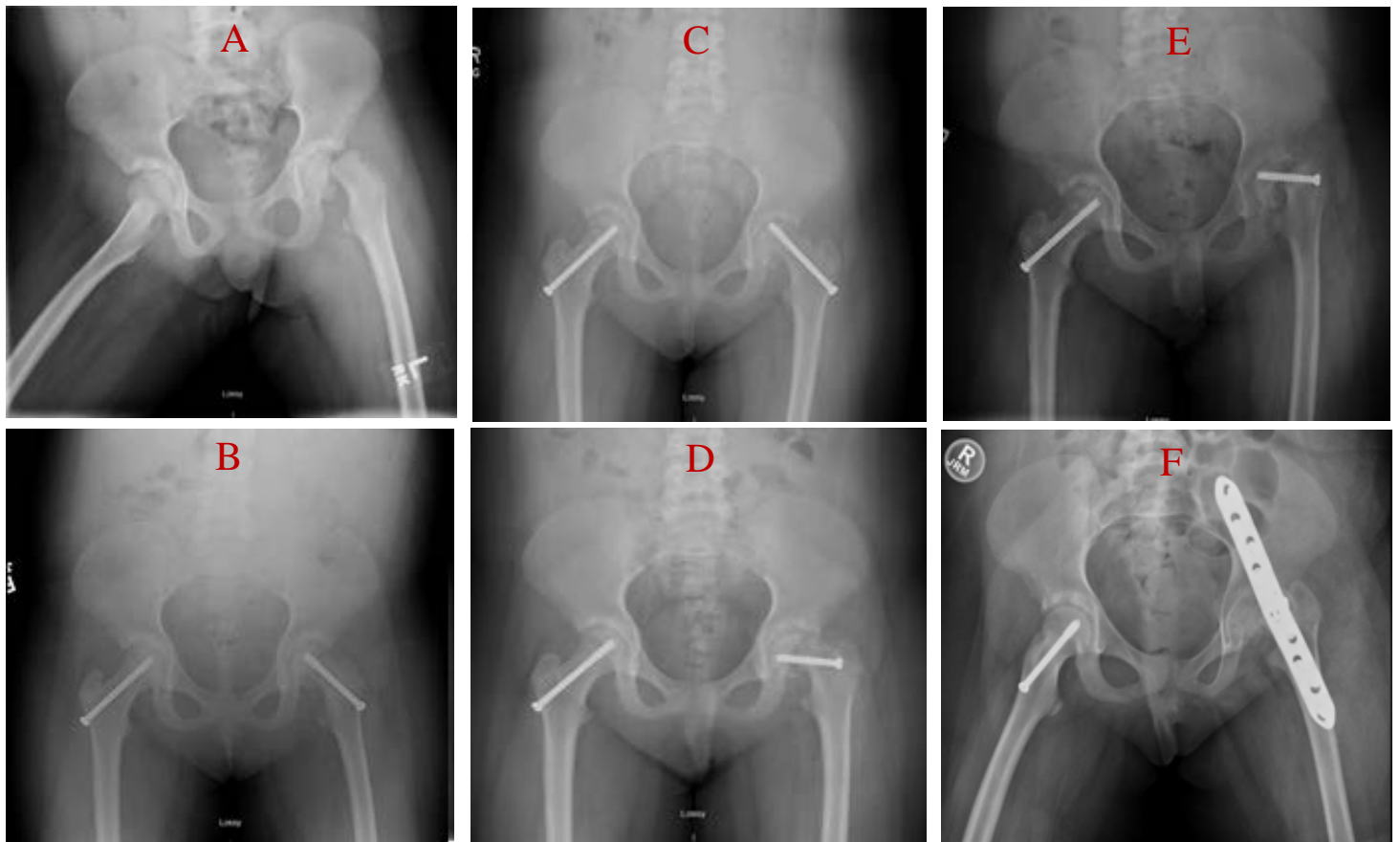
limb is held in a spica cast until both the fusion and the osteotomy heal (Figure 3).

Instrumented hip arthrodesis techniques include both trans-articular and a combination of trans- and extra-articular methods. Trans-articular methods include compression arthrodesis with muscle pedicle bone graft, dynamic hip screw (which preserves hip abductor unit) (Figure 4), and surgical dislocation of the hip with trochanteric flip osteotomy.<sup>15-18</sup>

Combined trans- with extra-articular methods include the Vancouver technique involving a lateral approach with cobra plate (Figure 5), and anterior plating through a modified Smith Peterson approach.<sup>12,19-22</sup> Today, it is an accepted principle that the abductor musculature should be treated gently and preserved to protect function when the arthrodesis is converted to a hip arthroplasty. Most contemporary hip fusions are performed via an abductor-sparing anterior approach.

#### *Authors Preferred Method: Anterior Approach*

The goal of hip arthrodesis is to establish a functionally positioned hip, to preserve hip abductor musculature, and to protect the greater trochanter anatomy. In such a manner, when future conversion to THA becomes necessary to manage the biomechanical consequences of a fused hip, it can be accomplished in a more straightforward fashion. Suboptimal fusion positioning can cause gait disturbance and functional leg length discrepancy.<sup>13,23-25</sup> The contemporary technique used for hip arthrodesis must protect hip abductor function and preserve trochanter anatomy as disruption during the arthrodesis may lead to increased rates of prosthetic dislocation related to component positioning or chronic limp related to abductor dysfunction. The anterior approach for arthrodesis works best with the highest reported union rate and acceptable patient functional outcome.<sup>5</sup> As reported by Matta et al., at 2-year follow-up fusion rates



**Figure 6.** The above images show the progression of a now 16-year-old female with a history of Downs syndrome who presented with left knee pain since January 2015 and was found to have a traumatic slipped capital femoral epiphysis (A shows preoperative slip and B shows postoperative fixation) in February of 2015 at the age of 10 after sustaining a fall in school. She went on to have screw fixation at that time for bilateral hips with screw exchange for the left hip 2 months later in April 2015 due to a prominent screw and fracture collapse (C shows preoperative image, D shows postoperative image from screw exchange). The patient subsequently developed avascular necrosis of her left femoral head (E) and underwent elective left hip arthrodesis due to her debilitating pain in January 2016 (F). She then had removal of her left hip anterior compression plate in August 2020 with a successful hip arthrodesis.

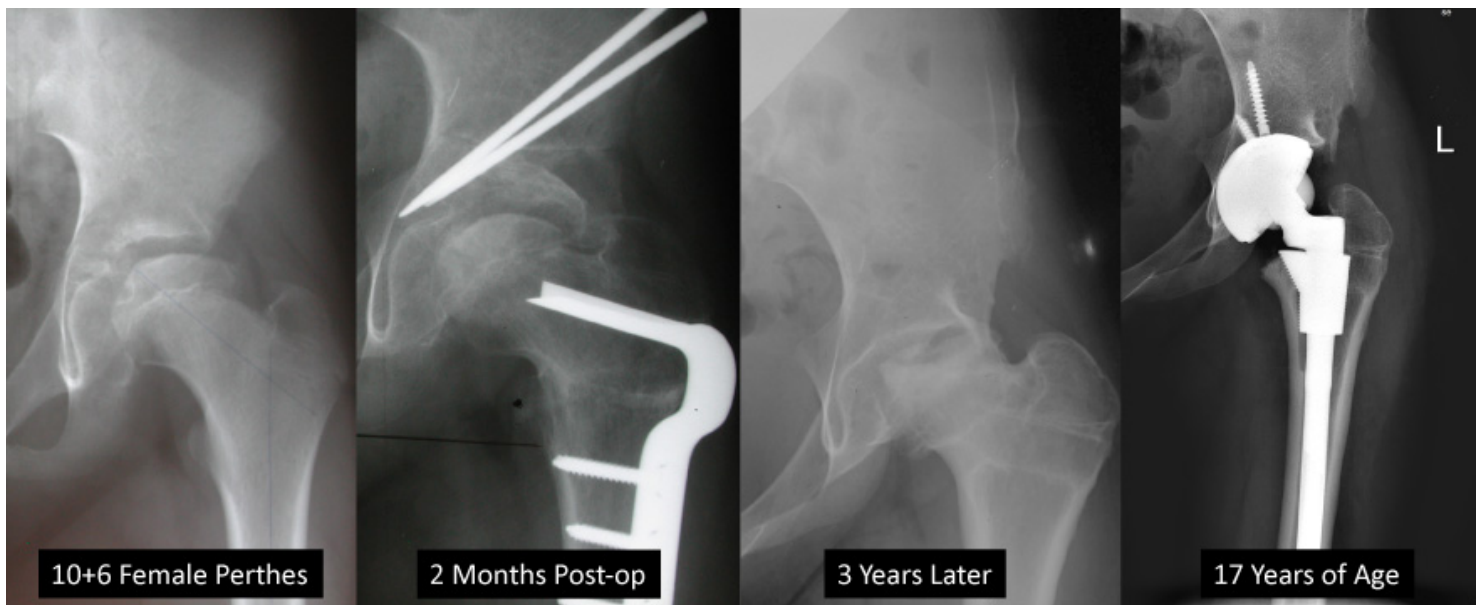
of 83% can be achieved without external fixation or casting while allowing patients to ambulate partial weight-bearing with crutches.<sup>12</sup> In our institution, we prefer the anterior approach with ventral plating as it facilitates accurate limb positioning, enables compression fixation and results in high fusion rates while preserving proximal femoral blood supply and avoiding damage to abductor muscles and trochanter anatomy (Figure 6).

#### *Technical Considerations for Arthroplasty*

Similar to arthrodesis, the indication for an arthroplasty include pain and dysfunction associated with end-stage hip arthritis that cannot be successfully managed

nonsurgically. THA may provide pain relief and restore function without significant short-term complications (Figure 7).<sup>26,27</sup> When a patient is deemed to benefit from THA, the choice of implants is vast, and unfortunately long-term implant-specific follow-up is not available.

Recently, Van de Velde et al. reported cementless total hip arthroplasty in 18 patients younger than 16 years of age at a mean follow up of 3.8 years. They found that modified Merle d'Aubigne et Postel scores for pain, movement, and walking were all significantly improved following THA, and no revisions had been performed at



**Figure 7.** A 10-year-old with Perthes disease undergoes hyper-containment to improve outcome. At 3 years postoperative, the hip is moderately painful and stiff. Her pain progressed, and at age 17 she underwent uncemented THR.

most recent follow-up with fixation and alignment maintained on radiographic evaluation.<sup>28</sup> In this study, some patients who were wheelchair-bound prior to arthroplasty transitioned to unrestricted gait. Of note, in the 24 THAs performed in this study, four of the patients required bone grafting during THA for bone deficiency from developmental dysplasia and juvenile rheumatoid arthritis. Also, three of the 24 hips had a Trendelenburg gait at follow-up. Longer-term evaluation of these patients, specifically to address component survivorship, is not available. Although these outcomes are promising, total hip arthroplasty in the pediatric patient has been incompletely studied.

Recent advances in cementless THA seem to be promising, with further research needed to elucidate the best bearing surface choice for pediatric patients. A major concern in THA for young patients is the survivorship of implants, as these patients are expected to have high physical demands and long-life expectancies.

Implant bearing surfaces have changed drastically in the last few decades, with metal on metal falling out of favor as revision rates have been shown to exceed 57% at 5

years in patients under 30 years old.<sup>29</sup> In a review of ideal bearing surfaces for young patients, Kamath et al. suggest that patients less than 30 years would have the best survivorship with decreased particle wear using ceramic-on-ceramic implants, but they do note that this must be investigated in longer-term studies.<sup>30</sup> Liner fractures and squeaking may occur with ceramic-on-ceramic implants, and thus, some surgeons prefer the use of ceramic on highly crosslinked polyethylene. This combination has been shown to have lower revision rates in patients younger than 25 years compared to conventional polyethylene with a mean time to revision of 64 months.<sup>31</sup> In their analysis of the Nordic Arthroplasty Registry Association (NARA) of 747 patients less than 21 years old undergoing total hip arthroplasty from 1995-2016, Halvorsen et al. found that the 15-year unadjusted survival rate for THA was 73% with aseptic loosening being the most common reason for revision. He also reported no significant difference in survival comparing cemented and cementless implants.<sup>32</sup> The utilization of cementless implants with highly crosslinked polyethylene liners appears to hold promise for improving survivorship of THA in young patients.

**Table 1: Considerations for Hip Fusion and Hip Replacement**

	<b>Hip Fusion</b>	<b>Hip Replacement</b>
<b>Relative Indications</b>	Heavy Active Patient Poor Social Situations Deficient Bony and Muscular Anatomy	Smaller Patient Low Demand Compliance with Hip Precautions Bilateral Hip Disease
<b>Contraindications</b>	Bilateral Hip Disease Ipsilateral Knee Pathology History of Back Pain/Pathology	History of Infection Deficient Bony and Muscular Anatomy

### Current Recommendations

The combination of improvements in THA components and bearing surfaces and improvement and consistency of surgical technique due to increased fellowship training have influenced preferential utilization of total hip arthroplasty for young patients with end-stage hip arthritis. Although long-term studies following arthrodesis report favorable outcomes and longevity despite the eventual need for conversion, the use of hip arthrodesis in the pediatric and young adult population is decreasing. When evaluating a young patient with end-stage arthritis, important factors for consideration include level of function, body habitus and weight, neuromuscular status and abductor muscle quality, bony loss, etiology of arthritis and ability to responsibly comply with the limitation of a prosthetic joint (Table 1). Unfortunately, the surgeon's dilemma persists. While properly performed and well-positioned hip arthrodesis provides consistent and reproducible outcomes, THA performed in young patients preserves movement and natural function but may require revision much earlier in life than an arthrodesis that will likely require conversion to THA. In the future, improved prosthesis survivorship data will be combined with patient expectation and demand data to refine the appropriate use of both arthrodesis and arthroplasty for the young arthritic patient.

### References

1. Kelman MG, Studdert DM, Callaghan JJ, et al. (2016) The Choice Between Total Hip Arthroplasty and Arthrodesis in Adolescent Patients: A Survey of Orthopedic Surgeons. *J Arthroplasty* 31:70–75.
2. Callaghan JJ, Brand RA, Pedersen DR (1985) Hip arthrodesis. A long-term follow-up. *J Bone Jt Surg - Ser A* 67:1328–1335.
3. Sponseller PD, McBeath AA, Perpich M (1984) Hip arthrodesis in young patients. A long-term follow-up study. *J Bone Jt Surg - Ser A* 66:853–859.
4. Polkowski GG, Callaghan JJ, Mont MA, Clohisy JC (2012) Total hip arthroplasty in the very young patient. *J. Am. Acad. Orthop. Surg.* 20:487–497
5. Kung PL, Ries MD (2007) Effect of femoral head size and abductors on dislocation after revision THA. In: *Clinical Orthopaedics and Related Research*. Lippincott Williams and Wilkins, pp 170–174
6. Clohisy JC, Beaulé PE, O'Malley A, et al. (2008) Hip disease in the young adult: Current concepts of etiology and surgical treatment. *J Bone Jt Surg - Ser A* 90:2267–2281.
7. Eichinger S, Forst R, Kindervater M (2007) Indikationen und alternativen der endoprothetischen versorgung beim jüngeren patienten. *Orthopade* 36:311–324.
8. Beaulé PE, Matta JM, Mast JW (2002) Hip arthrodesis: current indications and techniques. *J. Am. Acad. Orthop. Surg.* 10:249–258

9. Ahlbäck SO, Lindahl O (1966) Hip arthrodesis: the connection between function and position. *Acta Orthop* 37:77–87.
10. Gore DR, Murray MP, Sepic SB, Gardner GM (1975) Walking patterns of men with unilateral surgical hip fusion. *J Bone Jt Surg - Ser A* 57:759–765.
11. Karol LA, Halliday SE, Gourineni P (2000) Gait and function after intra-articular arthrodesis of the hip in adolescents. *J Bone Jt Surg - Ser A* 82:561–569.
12. Matta JM, Siebenrock KA, Gautier E, et al. (1997) Hip fusion through an anterior approach with the use of a ventral plate. *Clin Orthop Relat Res* 129–139.
13. Stover MD, Beaulé PE, Matta JM, Mast JW (2004) Hip Arthrodesis: A Procedure for the New Millennium? In: *Clinical Orthopaedics and Related Research*. Lippincott Williams and Wilkins, pp 126–133
14. Bittersohl B, Zaps D, Bomar JD, Hosalkar HS (2011) Hip arthrodesis in the pediatric population: where do we stand? *Orthop Rev (Pavia)* 3:13.
15. Davis JB (1954) The muscle-pedicle bone graft in hip fusion. *J Bone Joint Surg Am* 36 A:790–799.
16. Ranawat CS, Jordan LR, Wilson PD (1971) A technique of muscle-pedicle bone graft in hip arthrodesis. A report of its use in ten cases. *J Bone Joint Surg Am* 53:925–934.
17. Bankes MJK, Simmons JMH, Catterall A (2002) Hip arthrodesis with the dynamic hip screw. *J Pediatr Orthop* 22:101–104.
18. Ganz R, Gill TJ, Gautier E, et al. (2001) Surgical dislocation of the adult hip. *J Bone Jt Surg - Ser B* 83:1119–1124.
19. Barmada R, Abraham E, Ray RD (1976) Hip fusion utilizing the cobra head plate. *J Bone Jt Surg - Ser A* 58:541–544.
20. Murrell GAC, Fitch RD (1994) Hip fusion in young adults: Using a medial displacement osteotomy and cobra plate. *Clin Orthop Relat Res* 300:147–154.
21. Duncan CP, Spangehl M, Beauchamp C, McGraw R (1995) Hip arthrodesis: an important option for advanced disease in the young adult. *Can J Surg* 38 Suppl 1:
22. Smith-Petersen MN (1949) Approach to and exposure of the hip joint for mold arthroplasty. *J Bone Joint Surg Am* 31 A:40–46.
23. Bonin SJ, Eltoukhy MA, Hodge WA, Asfour SS (2012) Conversion of Fused Hip to Total Hip Arthroplasty With Presurgical and Postsurgical Gait Studies. *J Arthroplasty* 27:493.e9-493.e12.
24. Peterson ED, Nemanich JP, Altenburg A, Cabanela ME (2009) Hip arthroplasty after previous arthrodesis. *Clin Orthop Relat Res* 467:2880–2885.
25. Richards CJ, Duncan CP (2011) Conversion of Hip Arthrodesis to Total Hip Arthroplasty: Survivorship and Clinical Outcome. *J Arthroplasty* 26:409–413.
26. Boos N, Krushell R, Ganz R, Müller ME (1997) Total hip arthroplasty after previous proximal femoral osteotomy. *J Bone Jt Surg - Ser B* 79:247–253.
27. Parvizi J, Burmeister H, Ganz R (2004) Previous Bernese periacetabular osteotomy does not compromise the results of total hip arthroplasty. *Clin Orthop Relat Res* 118–122.
28. Van De Velde SK, Loh B, Donnan L (2017) Total hip arthroplasty in patients 16 years of age or younger. *J Child Orthop* 11:428–433.
29. Gililland JM, Anderson LA, Erickson J, et al. (2013) Mean 5-year clinical and radiographic outcomes of cementless total hip arthroplasty in patients under the age of 30. *Biomed Res Int* 2013:.
30. Kamath AF, Prieto H, Lewallen DG (2013) Alternative bearings in total hip arthroplasty in the young patient. *Orthop Clin North Am* 44:451–462.
31. Clohisy JC, Oryhon JM, Seyler TM, et al. (2010) Function and fixation of total hip arthroplasty in patients 25 years of age or younger. In: *Clinical Orthopaedics and Related Research*. Springer New York LLC, pp 3207–3213
32. Halvorsen V, Fenstad AM, Engesaeter LB, et al. (2019) Outcome of 881 total hip arthroplasties in 747 patients 21 years or younger: data from the Nordic Arthroplasty Register Association (NARA) 1995–2016. *Acta Orthop* 90:331–337.