

Is a CT Scan Needed for Pedicle Screws Crossing the Midline?

Jestin Williams, MD¹; Peter D'Amore, MD¹; Manaf H. Younis, MD, MPH²; Andrew King, MD, FACS²; Carter Clement, MD, MBA²

¹LSU Health New Orleans, New Orleans, LA; ²Children's Hospital New Orleans, New Orleans, LA

Abstract:

Pedicle screws are safe implants used for various spinal deformities in the pediatric population. Several studies have evaluated variations in pedicle anatomy, parameters to detect pedicle breach, and the need for postoperative computerized tomography (CT) scan to confirm screw placement. Some have opined that if the screws at one level cross on a posterior-anterior (PA) radiograph, there must be a medial pedicle breach. The purpose of this report is to review an example of spine fusion and instrumentation in a male patient with Scheuermann's Kyphosis. Relatively long pedicle screws were used, and postoperative radiographs showed screws crossing the midline at several levels. We ordered a CT scan that demonstrated several screw tips crossing midline without breaching the medial cortex. In conclusion, long pedicle screws are not necessarily mal-positioned if they cross the midline, especially if a far-lateral entry site has been used.

Key Concepts:

- Crossing-midline pedicle screws do not always indicate a medial wall breach.
- CT scan is not mandatory to check pedicle screws that cross midline in the setting of normal neuromonitoring, intact neurologic exam, and solid medial walls during intraoperative probing.
- Large patient anatomy facilitates medialization of pedicle screw tips.
- A relatively lateral pedicle screw starting point allows higher maximal insertional arc and increased medialization of screw tips.

Introduction

Posterior spine fusion (PSF) with pedicle screws (PS) allows fixation through all three columns of the spine and has become a mainstay of surgical treatment.^{4,7,9,14,22,24} Mal-positioned screws, with an incidence of 3-44%, is one of the main risks of PS placement as it may cause neurovascular injury.^{2,5,6,21,24} The risk of injury from medial pedicle wall breach increases in deformed vertebrae when placed at the apex of the curve and in the thoracic spine.³⁰

When assessing pedicle screw position intraoperatively, there are different modalities employed: pedicle wall palpation, fluoroscopy, intraoperative neuromonitoring (IONM), pedicle screw stimulation, and intraoperative CT scan.^{8,15,18-20,25} During surgery, the appearance of midline-crossing screws on a PA image raises concern for screws breaching the medial cortex. In such instances, the screw is usually removed, and the pedicle is probed for a breach. If there is no evidence of a breach,

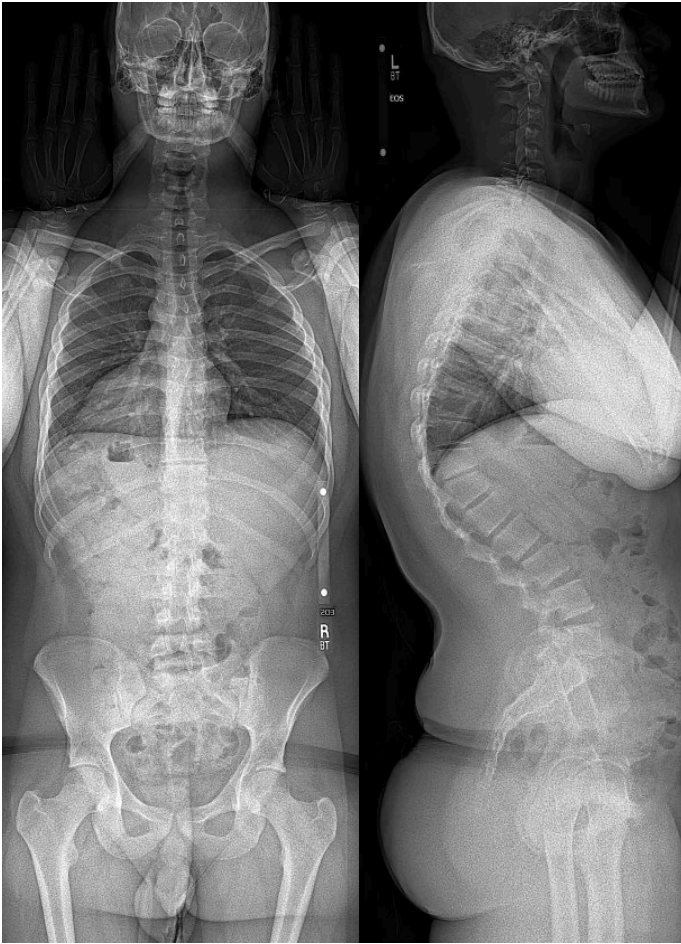


Figure 1. Standing scoliosis radiographs using EOS imaging system A) PA view B) Lateral view

the screw may be reinserted or repositioned. If there is definitive evidence of a medial breach, the screw should be repositioned, left out, or another modality of fixation can be employed (e.g., cables, wires, or hooks). On postoperative radiographs, some advocate that if a pedicle screw crosses the midline or if the two screw tips at one level appear to touch, a CT should be obtained to determine whether a breach is present. CT scans expose patients to radiation and are expensive, so it is optimal to avoid this test when possible.

We present a case of a heavy-built male with Scheuermann's Kyphosis who underwent PSF. Pedicle screws were noted to cross the midline on the postoperative radiographs, and a CT scan was performed to evaluate for medial wall breaches. Based on this experience, this

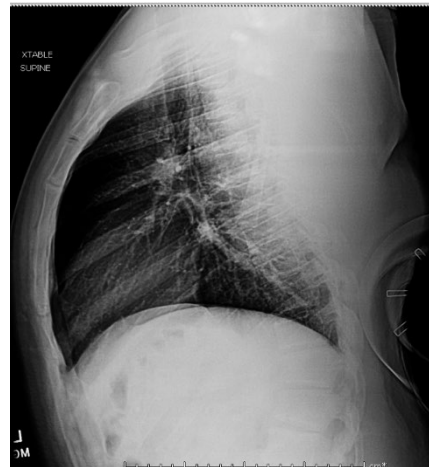


Figure 2. Lateral extension radiograph taken while supine resting over a posterior bolster

paper aims to outline parameters that should dissuade one from ordering a postoperative CT scan regardless of plain imaging.

Case

A 16-year-old healthy male presented for evaluation of worsening kyphosis over the past 2 years. He reported intermittent mid-back pain, but it did not limit his activities, including high school football. He denied radicular symptoms. Physical exam was benign except for exaggerated kyphosis with Adams forward bending test. Radiographic workup consisted of a PA, Lateral, and bending scoliosis x-rays which demonstrated an 88 degrees lower thoracic kyphotic angle that corrected to 40 degrees on bending films, with the apex at T10 and anterior wedging at three consecutive thoracic vertebrae of more than 5 degrees (Figures 1-2). He was diagnosed with Type II Scheuermann's Kyphosis.

PSF with apical Ponte osteotomies was indicated from T4-L3 to prevent progression. After standard approach including facetectomies, pedicle screws were placed in the following manner: burr to mark the entry point on the cortex, awl to create pedicle screw path, path checked for wall integrity with a ballpoint probe, then appropriate size screw was inserted. Medtronic brand instrumentation was employed (Medtronic, Dublin, Ireland). After all screws had been inserted, their positions were checked with PA and lateral fluoroscopy and triggered electromyography (EMG) thresholds were

measured. Threshold levels >6mA and >10mA were used to ensure appropriate placement of thoracic and lumbar PS, respectively. There was no concern for breach with probing and no screws demonstrated concerning thresholds with triggered EMG. Radiographs demonstrated that screws crossed the midline at T6-T9 and were in very close proximity at T4 and T5; the right T9 screw was most notable. This screw was taken out, and the path was reprobated, demonstrating a solid medial wall. The screw was then reinserted and restimulated; the threshold remained within normal limits. Width and size of screws used at their corresponding levels are shown in Table 1.

Rods were contoured and inserted, final reduction maneuvers were applied, and final tightening was performed. Final IONM demonstrated no abnormalities. The spine was decorticated using a burr, allogenic and autologous bone graft placed, and the wound was closed in standard layered fashion. The patient was extubated and transferred to the PACU without any adverse events.

Standard postoperative radiographs redemonstrated pedicle screws crossing midline at several levels, most prominently at T9 (Figure 3). To assess screw position, we elected to perform a CT scan (See Video), which demonstrated all screws traversing the paths of the pedicles. Due to metal artifact, minor medial breach could not be definitively ruled out nor confirmed for two screws (right T7 and T9; Figures 4 and 5, respectively). However, suspicion for breaches at these levels was low because the most medially directed implant (right T9) was removed and reprobated intraoperatively with a very reassuring medial wall. Most likely, the screws abutted the medial wall which was obscured by artifact, though penetration or, more likely, expansion of the wall is possible. Breach was ruled out at all other levels on the CT, including several screws with tips crossing the midline (left T4, T6, and T7 and right T6; **See Video**). The remainder of his course was uneventful. He followed our standard PSF postoperative protocol with the goals of minimizing narcotic pain medication and early ambulation (postoperative day (POD) 1). He progressed well,

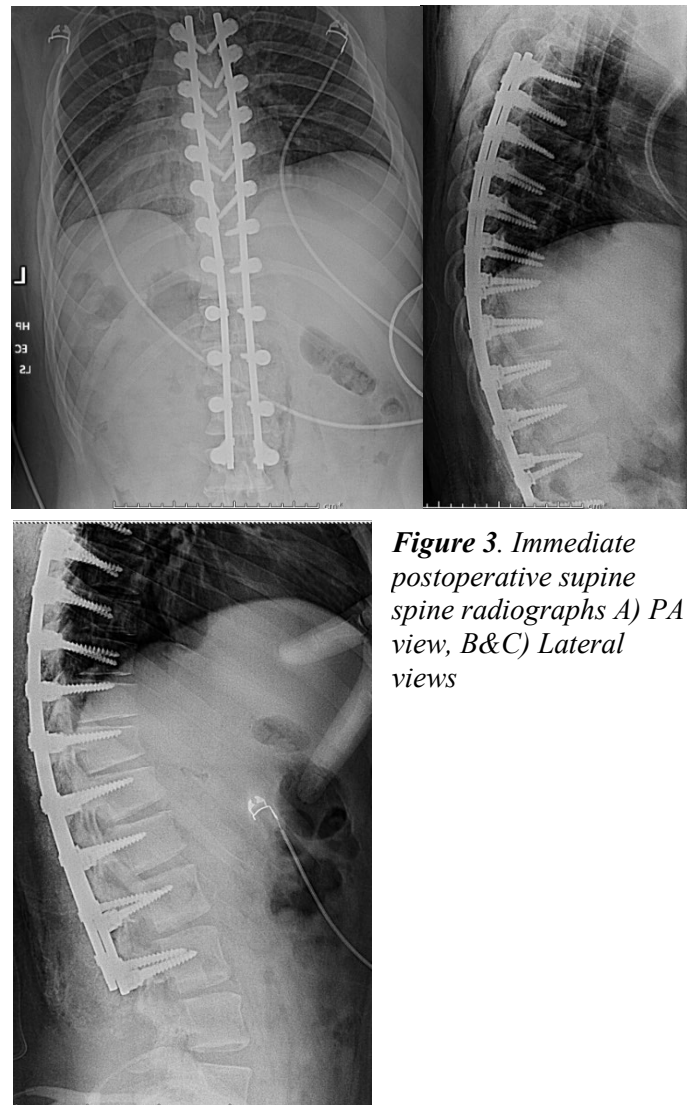


Figure 3. Immediate postoperative supine spine radiographs A) PA view, B&C) Lateral views

Vertebral Level	Left (mm x mm)	Right (mm x mm)
T4	5.5 x 35	5.5 x 35
T5-L1	5.5 x 40	5.5 x 40
L2	5.5 x 45	5.5 x 45
L3	6.5 x 40	6.5 x 40

remained neurologically intact, and did not have any complaints of radicular or myelopathic symptoms. He was discharged on POD 4 in stable condition, ambulating without assistance, tolerating oral (PO) diet, and with pain adequately controlled on PO medication.

Discussion

Assessment of pedicle screw placement, both intra and postoperatively, is of high importance due to the risk of damaging important neurovascular structures. Pedicle probing, IONM, threshold EMG testing, and intraoperative fluoroscopy have proven useful in detecting screw malposition and breach.^{8,15,18-20,25} If all the above parameters are normal, but a screw crosses the midline on radiographs, is a CT scan still warranted? The case presented here suggests the answer is no.

Our patient weighed 269 pounds and was 6 feet tall (BMI 28.1kg/m²). He was above the 97th percentile in weight and roughly 90th percentile in height. Studies have shown that males and relatively tall and heavy individuals have larger vertebral anatomy including pedicles.^{27,29} This anatomy allows a higher standard deviation in pedicle screw trajectory and longer screws which makes it more likely for screw tips to cross the midline without a medial breach. Thoracic pedicles also have a medialized trajectory compared to the lumbar segments,¹³ making this radiographic finding more likely in the thoracic spine. Anatomical studies have also shown that the thoracic spine has thicker medial cortices.^{5,12} The patient presented here had particularly dense bone and probing of the pedicle tracts was more definitive than usual. This type of reassuring tactile feedback should discourage the use of postoperative CT in the absence of other concerning findings. Additionally, as seen in this case, CT scan can be limited by metal artifact which may make it impossible to definitively confirm or deny a breach (though a clinically significant breach is more likely to be visible, even in the setting of metal artifact).

Far-lateral or ventral starting position (VSP) for PS placement allows an increase in maximal insertional arc (MIA), which is the screw angle from the most lateral to

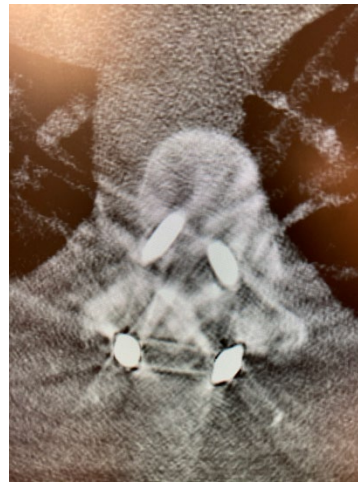


Figure 4. Axial CT slice through T7 demonstrating close proximity of the right pedicle screw to the medial wall where a minor medial breach cannot be definitively confirmed nor ruled out. Please re-view video of the CT scan to examine the entire CT.

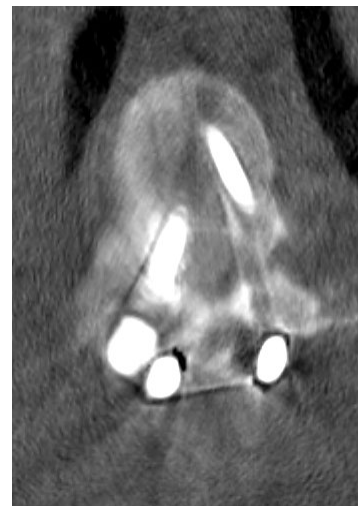

Figure 5. Axial CT slice through T9 demonstrating close proximity of the right pedicle screw to the medial wall where a minor medial breach cannot be definitively confirmed nor ruled out. There is low suspicion for a breach as this screw was removed intraoperatively based on fluoroscopy and repeat probing of the pedicle tract revealed an intact medial wall.

medial trajectory in the axial plane without causing a pedicle breach.¹⁶ In the case presented here, pedicle screw starting points throughout the levels with crossing screw tips were somewhat lateral, particularly on the right. This positioning allowed relative medialization of the screw tips. When utilizing a VSP, there should be less concern about screw tips that cross the midline in the absence of other issues.

Pedicle screw placement should always be critically evaluated by multiple modalities. Understanding how to weigh these modalities allows informed decisions about the need for further workup. Our case demonstrates that with a large patient and relatively lateral starting points, there can be low suspicion of a medial wall breach if a screw crosses the midline but there are no other concerning findings perioperatively (e.g., probing pedicle walls,

IONM, postoperative neurologic exam, cardiovascular status, etc.). Thus, a CT scan in this circumstance may be of low utility.

References

1. Augusto Gonzalvo, Gregory Fitt, Susan Liew, David de la Harpe, Nikitas Vrodos, Matthew McDonald, Myron A. Rogers & Peter H. Wilde (2015) Correlation between pedicle size and the rate of pedicle screw misplacement in the treatment of thoracic fractures: Can we predict how difficult the task will be?, *British Journal of Neurosurgery*, 29:4, 508-512, DOI: 10.3109/02688697.2015.1019414
2. Brown CA, Lenke LG, Bridwell KH, Geideman WM, Hasan SA, Blanke K. Complications of pediatric thoracolumbar and lumbar pedicle screws. *Spine (Phila Pa 1976)*. 1998 Jul 15;23(14):1566-71. doi: 10.1097/00007632-199807150-00012. PMID: 9682313.
3. Burton DC, Carlson BB, Place HM, Fuller JE, Blanke K, Cho R, Fu KM, Ganju A, Heary R, Herrera-Soto JA, Larson AN, Lavelle WF, Nelson IW, Vernengo-Lezica A, Verska JM. Results of the Scoliosis Research Society Morbidity and Mortality Database 2009-2012: A Report From the Morbidity and Mortality Committee. *Spine Deform*. 2016 Sep;4(5):338-343. doi: 10.1016/j.jspd.2016.05.003. Epub 2016 Aug 21. PMID: 27927490.
4. Daniel J. Hedequist, *Operative Techniques in Orthopaedics*, Vol. 15 (2005), pp.331-337.
5. Gertzbein SD, Robbins SE. Accuracy of pedicular screw placement in vivo. *Spine (Phila Pa 1976)*. 1990 Jan;15(1):11-4. doi: 10.1097/00007632-199001000-00004. PMID: 2326693.
6. Jin M, Liu Z, Qiu Y, Yan H, Han X, Zhu Z. Incidence and risk factors for the misplacement of pedicle screws in scoliosis surgery assisted by O-arm navigation-analysis of a large series of one thousand, one hundred and forty five screws. *Int Orthop*. 2017 Apr;41(4):773-780. doi: 10.1007/s00264-016-3353-6. Epub 2016 Dec 21. PMID: 27999927.
7. Kim YJ, Lenke LG, Bridwell KH, Cho YS, Riew KD. Free hand pedicle screw placement in the thoracic spine: is it safe? *Spine (Phila Pa 1976)*. 2004 Feb 1;29(3):333-42; discussion 342. doi: 10.1097/01.brs.0000109983.12113.9b. PMID: 14752359.
8. Kim YJ, Lenke LG, Cheh G, Riew KD. Evaluation of pedicle screw placement in the deformed spine using intraoperative plain radiographs: a comparison with computerized tomography. *Spine (Phila Pa 1976)*. 2005 Sep 15;30(18):2084-8. doi: 10.1097/01.brs.0000178818.92105.ec. PMID: 16166900.
9. Kim YJ, Lenke LG, Cho SK, Bridwell KH, Sides B, Blanke K. Comparative analysis of pedicle screw versus hook instrumentation in posterior spinal fusion of adolescent idiopathic scoliosis. *Spine (Phila Pa 1976)*. 2004 Sep 15;29(18):2040-8. doi: 10.1097/01.brs.0000138268.12324.1a. PMID: 15371706.
10. Kim YJ, Lenke LG. Thoracic pedicle screw placement: free-hand technique. *Neurology India*. 2005;53(4):512-519.
11. Kokushin DN, Vissarionov SV, Baidurashvili AG, Bart VA. Analysis of anatomical and anthropometric parameters of vertebrae in children with thoracic idiopathic scoliosis using 3D-CT-navigation. *Hir. Pozvonoc*. 2016;13(1):27-36. In Russian. DOI: <http://dx.doi.org/10.14531/ss2016.1.27-36>.
12. Kothe R, O'Holleran JD, Liu W, Panjabi MM. Internal architecture of the thoracic pedicle. An anatomic study. *Spine (Phila Pa 1976)*. 1996 Feb 1;21(3):264-70. doi: 10.1097/00007632-199602010-00002. PMID: 8742200.
13. Kretzer RM, Chaput C, Sciubba DM, et al. A computed tomography-based morphometric study of thoracic pedicle anatomy in a random United States trauma population. *Journal of Neurosurgery: Spine*. 2011;14(2):235-243. doi:10.3171/2010.9.SPINE1043
14. Kwan MK, Chiu CK, Gani SM, Wei CC. Accuracy and Safety of Pedicle Screw Placement in Adolescent Idiopathic Scoliosis Patients: A Review of 2020 Screws Using Computed Tomography Assessment. *Spine (Phila Pa 1976)*. 2017 Mar;42(5):326-335. doi: 10.1097/BRS.0000000000001738. PMID: 27310021.
15. Lehman RA, Potter BK, Kuklo TR, Chang AS, Polly DW, Shawen SB, Orchowski JR. Probing for thoracic pedicle screw tract violation(s): is it valid? *J Spinal Disord Tech*. 2004 Aug;17(4):277-83. doi: 10.1097/01.bsd.0000095399.27687.c5. PMID: 15280755.
16. Lin JD, Wei C, Shillingford JN, et al. Evaluation of a more ventral starting point for thoracic pedicle screws: higher maximal insertional arc and more medial and safer

screw angulation. *Journal of Neurosurgery: Spine*. December 2018;1-7. doi:10.3171/2018.8.SPINE18175

17. Panjabi MM, O'Holleran JD, Crisco JJ 3rd, Kothe R. Complexity of the thoracic spine pedicle anatomy. *European spine journal : official publication of the European Spine Society, the European Spinal Deformity Society, and the European Section of the Cervical Spine Research Society*. 1997;6(1):19-24. Accessed November 23, 2020.

<http://search.ebscohost.com/login.aspx?direct=true&db=cmedm&AN=9093823&site=eds-live&scope=site>

18. Piazzolla A, Montemurro V, Bizzoca D, Parato C, Carlucci S, Moretti B. Accuracy of plain radiographs to identify wrong positioned free hand pedicle screw in the deformed spine. *J Neurosurg Sci*. 2019 Aug;63(4):372-378. doi: 10.23736/S0390-5616.16.03670-5. Epub 2016 May 11. PMID: 27167472.

19. Raynor BL, Lenke LG, Kim Y, Hanson DS, Wilson-Holden TJ, Bridwell KH, Padberg AM. Can triggered electromyograph thresholds predict safe thoracic pedicle screw placement? *Spine (Phila Pa 1976)*. 2002 Sep 15;27(18):2030-5. doi: 10.1097/00007632-200209150-00012. PMID: 12634564.

20. Samdani AF, Tantorski M, Cahill PJ, Ranade A, Koch S, Clements DH, Betz RR, Asghar J. Triggered electromyography for placement of thoracic pedicle screws: is it reliable? *Eur Spine J*. 2011 Jun;20(6):869-74. doi: 10.1007/s00586-010-1653-x. Epub 2010 Dec 18. PMID: 21170665; PMCID: PMC3099169.

21. Sarwahi V, Wendolowski SF, Gecelter RC, Amaral T, Lo Y, Wollowick AL, Thornhill B. Are We Underestimating the Significance of Pedicle Screw Misplacement? *Spine (Phila Pa 1976)*. 2016 May;41(9):E548-55. doi: 10.1097/BRS.0000000000001318. PMID: 26630430.

22. Smorgick Y, Millgram MA, Anekstein Y, Floman Y, Mirovsky Y. Accuracy and safety of thoracic pedicle screw placement in spinal deformities. *J Spinal Disord Tech*. 2005 Dec;18(6):522-6. doi: 10.1097/01.bsd.0000154448.90707.a8. PMID: 16306843.

23. Su AW, McIntosh AL, Schueler BA, Milbrandt TA, Winkler JA, Stans AA, Larson AN. How Does Patient Radiation Exposure Compare With Low-dose O-arm Versus Fluoroscopy for Pedicle Screw Placement in Idiopathic

Scoliosis? *J Pediatr Orthop*. 2017 Apr/May;37(3):171-177. doi: 10.1097/BPO.0000000000000608. PMID: 27453221.

24. Suk SI, Kim WJ, Lee SM, Kim JH, Chung ER. Thoracic pedicle screw fixation in spinal deformities: are they really safe? *Spine (Phila Pa 1976)*. 2001 Sep 15;26(18):2049-57. doi: 10.1097/00007632-200109150-00022. PMID: 11547207.

25. Sutter M, Eggspuehler A, Jeszenszky D, Kleinstueck F, Fekete TF, Haschtmann D, Porchet F, Dvorak J. The impact and value of uni- and multimodal intraoperative neurophysiological monitoring (IONM) on neurological complications during spine surgery: a prospective study of 2728 patients. *Eur Spine J*. 2019 Mar;28(3):599-610. doi: 10.1007/s00586-018-5861-0. Epub 2018 Dec 17. PMID: 30560453.

26. Vaccaro AR, Rizzolo SJ, Allardyce TJ, Ramsey M, Salvo J, Balderston RA, Cotler JM. Placement of pedicle screws in the thoracic spine. Part I: Morphometric analysis of the thoracic vertebrae. *J Bone Joint Surg Am*. 1995 Aug;77(8):1193-9. doi: 10.2106/00004623-199508000-00008. PMID: 7642664.

27. Yu CC, Bajwa NS, Toy JO, Ahn UM, Ahn NU. Pedicle morphometry of upper thoracic vertebrae: an anatomic study of 503 cadaveric specimens. *Spine (Phila Pa 1976)*. 2014 Sep 15;39(20):E1201-9. doi: 10.1097/BRS.0000000000000505. PMID: 24983934.

28. Yu, Charles C. BA; Yuh, Roger T. BS; Bajwa, Navkirat S. MD; Toy, Jason O. MD; Ahn, Uri M. MD; Ahn, Nicholas U. MD Lower Thoracic Pedicle Morphometry, *Spine*: March 15, 2015 - Volume 40 - Issue 6 - p E323-E331 doi: 10.1097/BRS.0000000000000760

29. Yu, Charles C. BA; Yuh, Roger T. BS; Bajwa, Navkirat S. MD; Toy, Jason O. MD; Ahn, Uri M. MD; Ahn, Nicholas U. MD Pedicle Morphometry of Lumbar Vertebrae, *Spine*: November 2015 - Volume 40 - Issue 21 - p 1639-16 doi: 10.1097/BRS.0000000000001086

30. Zhu, Feng MD; Sun, Xu MD; Qiao, Jun PhD; Ding, Yitao MD; Zhang, Bing MD; Qiu, Yong MD Misplacement Pattern of Pedicle Screws in Pediatric Patients With Spinal Deformity, *Journal of Spinal Disorders and Techniques*: December 2014 - Volume 27 - Issue 8 - p 431-435 doi: 10.1097/BSD.0b013e31828d6a1b