

# The Evolution of EDF Casting

Michelle C. Welborn, MD<sup>1</sup>; James O. Sanders, MD<sup>2</sup>; Jacques D'Astous, MD<sup>3</sup>

<sup>1</sup>Department of Orthopaedic Surgery, Shriners' Hospital for Children Portland, Portland, OR; <sup>2</sup>Department of Orthopaedic Surgery, University of North Carolina Chapel Hill, Chapel Hill, NC; <sup>3</sup>Department of Orthopaedic Surgery, Shriners' Hospital for Children Salt Lake City, Salt Lake City, UT

## Abstract:

Casting for scoliosis has evolved significantly since it was first reported 150 years ago. Earlier techniques focused on temporizing scoliosis, loosening up curves prior to surgery, and facilitating fusions after surgery. Modern techniques have evolved to address the three-dimensional nature of the deformity and to harness the power of growth in younger children to provide a lasting correction. Its current iteration, elongation derotation flexion casting, has been successfully applied in multiple patient populations. It has been shown to cure anywhere from 35-69% of patients with infantile idiopathic scoliosis and will palliate many more. It can delay surgical intervention two or more years in patients with congenital, syndromic, or neuromuscular scoliosis. It is not without its limitations including rashes, pressure sores, rib deformity, and the potential long-term impact of repetitive anesthesia. Additionally, there continues to be variable outcomes in part due to the heterogeneous patient population and variability in casting techniques. However, the technique continues to improve as it evolves and it is the only treatment that can potentially cure scoliosis. Here we aim to discuss the evolution of casting, its application in different patient populations, and the tips and tricks of our preferred casting technique.

## Key Concepts:

- Serial casting is an effective treatment for early onset scoliosis.
- Modern casting techniques have evolved over the past 150 years and continue to evolve to better address the three-dimensional nature of scoliosis.
- Modern casting techniques can cure scoliosis in some patients, improve it in others, and delay surgical intervention in many more.

## Introduction

Casting for scoliosis has evolved significantly since it was first reported 150 years ago. Earlier techniques focused on temporizing scoliosis, loosening up curves prior to surgery, and facilitating fusions after surgery. These casts often required bed rest and had high rates of morbidity and even mortality in some cases. Modern techniques have evolved to address the three-dimensional nature of the deformity and to harness the power

of growth in younger children to provide a lasting correction. There has been significant improvement in outcomes as the technique has evolved and it has been applied successfully in multiple patient populations including infantile idiopathic scoliosis, congenital scoliosis, and neuromuscular scoliosis. As a result of this evolution, serial casting is now primarily applied in the early onset scoliosis population. Here we aim to discuss the

evolution of casting, outcomes in different patient populations, and our preferred casting technique. The goal of this paper is to help improve expectations and outcomes in what can be a challenging and heterogeneous patient population.

### *Why do serial casting for early onset scoliosis?*

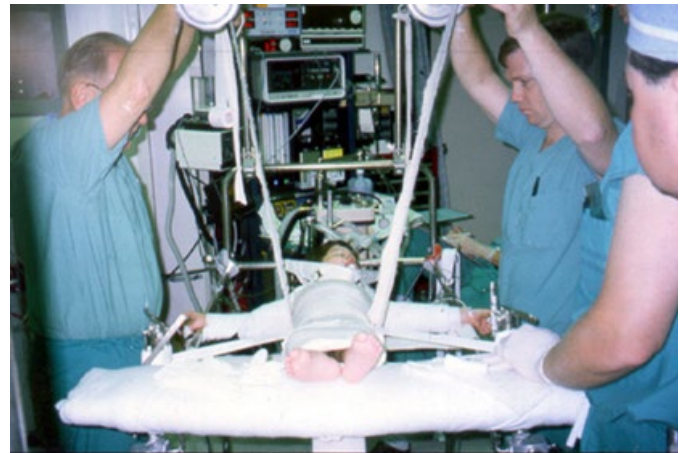
Early onset scoliosis (EOS) is defined as scoliosis with an onset of < 10 years of age.<sup>1,2</sup> Young age coupled with chest and spinal deformity can make the management of EOS challenging. This is because the spine grows most rapidly in the first 5 years of life achieving approximately 50% of its total length by age 5.<sup>3</sup> As rapid growth correlates with increased risk of progression, deformity progression can be rapid and relentless in this population. The progression of scoliosis is particularly impactful on lung development as the number of alveoli and lung volume increase most rapidly in the first two years of life, then more slowly up to age 8, with only a small increase during adolescence and adulthood.<sup>4,6</sup> In the most severe cases, this can result in thoracic insufficiency syndrome, which is the inability of the thorax to support normal lung function. This can be due to the underlying disease process, the impact of the scoliosis on the lungs, or due to the treatment of the scoliosis itself.<sup>7,8</sup> Karol et al. showed us the importance of preserving spine growth and that early fusion limits thoracic growth potential, lung development, and can be a cause of thoracic insufficiency syndrome.<sup>9</sup>

However, it is important to understand that growth is not always a bad thing. In her 2005 article, Mehta described the ability to correct scoliosis by harnessing the power of growth thru serial casting.<sup>10</sup> This concept represented a dramatic change in the utilization of casting as historically it was primarily done in adults with scoliosis.

### *The evolution of casting for scoliosis*

Sayre first reported casting for scoliosis in 1877, where he would partially suspend patients and then use a plaster jacket to hold the correction.<sup>11</sup> Despite Sayre's initial casting to correct scoliosis, the first extensive use of

casting to our knowledge was Hibbs applying turnbuckle casts preoperatively to correct and hold the curves corrected after uninstrumented fusion where he would split the spinous processes and place a tibial crest autograft to achieve fusion. The patients could not walk in these and were on bed rest for several months and then would have to wear a removable plaster jacket for years.<sup>12</sup> This procedure was associated with high risk but also high reward and revolutionized the treatment of scoliosis, opening the door for many of the surgeons who followed him.



**Figure 1.** Drs. Albert Sanders and James Sanders apply a Cotel-style cast in 1966.

Subsequently, Risser in the 1950s, who had worked under Hibbs, developed a technique and table for a corset cast allowing patients to walk. His goals were similar to Hibbs, and casts were applied for surgical cases, but these were better tolerated by patients. This technique was further adapted by Morel and Cotrel who introduced the derotation and flexion technique in the 1960s using straps to facilitate molding the cast.<sup>13</sup> They specifically theorized that their extension, derotation, flexion (EDF) technique could be used in infantile scoliosis. John Moe then brought this technique to the U.S. He and Cotrel taught Albert E. Sanders who later taught his son James Sanders who helped to popularize casting in the U.S. (Figure 1). At this point, the technique continued to primarily be used after Harrington rods and to temporize scoliosis. The technique was further refined when

Dubousset added the use of turnbuckle elongation cast emphasizing the importance of traction in scoliosis correction (Figure 2). Dubousset primarily applied casts to loosen up kyphosis and scoliosis prior to resuming more standard treatment. In 1978, Jacques D'Astous spent 3 months with Dubousset as a McLaughlin Travelling Fellow where he learned the technique, which he then brought to the U.S. (Figure 3).

### Modern casting techniques

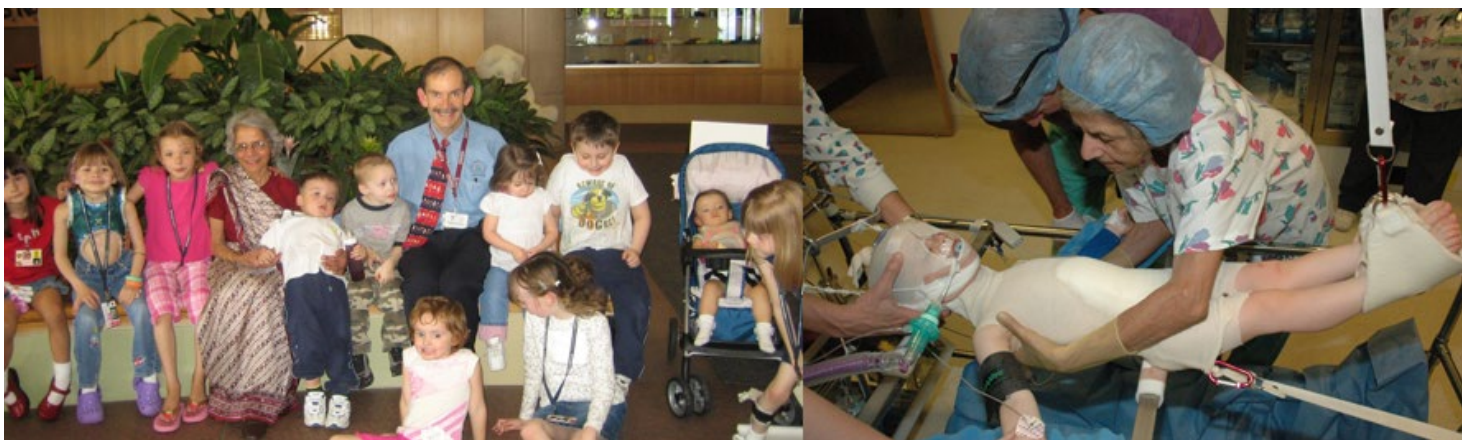Concurrently, Mehta was further refining her EDF casting technique. She first described this technique in 1979, and one of the big changes was that she did not use straps to achieve correction. Instead, she performed direct molding<sup>10,14</sup> Her first casting course in the U.S. occurred in Salt Lake City in 2003 and was sponsored by the Infantile Scoliosis Outreach Program (ISOP) where D'Astous, Johnston, and Sanders were present and who then spread the approach in the U.S. (Figure 4A, B).

Two years later, Mehta et al. reported the largest series of patients treated with EDF style casting and found that up to 100% of patients treated < 20 months resolved.<sup>10</sup> She was able to palliate patients who were referred late and 69% of patients in her series were able to avoid surgery. Other authors have shown good results, though none have been able to reproduce Dr. Mehta's work. When specifically looking at results in infantile idiopathic scoliosis, Fedorak et al. showed a cure rate of



**Figure 2.** Patient in turnbuckle cast and halo gravity traction. **Figure 3.** Drs. D'Astous and Dubousset.

49% at > 5-year follow-up<sup>15</sup> and Welborn et al. reported 45% were cured, 55% were palliated, and at the time of their study, none of the patients have progressed to surgery.<sup>16</sup> This is an improvement over the 35% rate of cure that Sanders et al. reported in an earlier study, but the previous paper included patients of all diagnoses.<sup>17</sup> Baulesh et al. reported that only 26% of the infantile idiopathic scoliosis patients had resolution of their curvature.<sup>18</sup> Multiple studies have looked at their outcomes in a more heterogenous population. Iorio et al. had a cure rate of 19%, but only 9.5% of their patients worsened during the course of treatment and the rest were palliated.<sup>19</sup> Hassanzadeh et al. did not indicate a cure rate but 29% had completed treatment without requiring surgery, 62% had transitioned to bracing and only 9% had



**Figures 4A, B.** Min Mehta, Dr. D'Astous, and their EDF casting patients at the ISOP casting course in Salt Lake City, UT, in 2003. **B.** Min Mehta demonstrates her EDF casting technique.

progressed.<sup>20</sup> Dhawale et al. reported that none of their patients were cured at final follow-up.<sup>21</sup>

### *Serial casting in nonidiopathic scoliosis*

While EDF casting success has been highest in the infantile idiopathic population, its use has been applied in other populations as well. Regarding congenital scoliosis, Demirkiran et al. reported they were able to effectively delay surgical intervention an average of 26.5 months. Cao et al. similarly reviewed their congenital scoliosis patients and showed they were able to prevent the equivalent of 70 growing rod-lengthening procedures in 23 patients.<sup>22,23</sup>

Its impact has been studied in neuromuscular and syndromic scoliosis patients. Lavalva et al. reported that 55% of patients had curve progression in their cast, 43% ultimately required surgery, and 30% had improvement of their curve > 10 degrees. But they were able to successfully delay surgical intervention an average of 3 years.<sup>24</sup> Ballhause et al. had similar results in the syndromic scoliosis population with a 44% decrease in curve magnitude after serial cast treatment.<sup>25</sup>

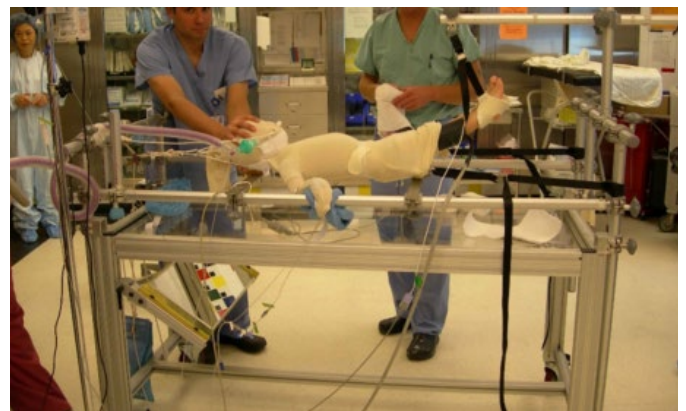Ultimately, there continues to be significant variability in the cure rates between different patients and centers. Numerous predictors of success have been delineated including younger age at initiation of treatment<sup>10,19</sup> as well as correction in the initial cast,<sup>15,17,19</sup> and lastly, curve magnitude at cessation of casting. Welborn et al. showed that even when adjusted for age, if the Cobb angle was > 10° in the last cast, the odds of falling into the palliated group was 7.3 times greater than if the Cobb was < 10 degrees.<sup>16</sup> Overall, the best results continue to be in idiopathic patients where up to 49% are cured, significant improvement is seen in up to 71% of patients, and many more are palliated.<sup>15,19,26</sup>

### *Downsides of casting*

While EDF style casting has been shown to have a number of benefits for early onset scoliosis, it is not without its downsides. Rashes and skin irritation are common


challenges and it is important to educate families on cast care to minimize them, though they rarely delay casting. Pressure sores can occur, particularly in patients with limited ability to communicate. It is important to make sure the cast is well padded and that parents monitor them closely. In the authors' experience, rib deformity is less common in patients that are casted for a short duration, but it is common in patients where there is prolonged casting. It can occur iatrogenically if the pelvic mold is too high and presses on the floating ribs or if the surgeon rests their hand against the lateral chest wall instead of using an anteriorly directed force when they are doing their derotation maneuver.

Rare complications include DVT and brachial plexopathy. Badlani et al. reported on a subclavian venous thrombosis in a patient where there was mild dynamic compression in the axilla.<sup>27</sup> The authors are aware of one patient who experienced a transient brachial plexopathy due to compression of the brachial plexus at the level of the axilla. This resolved after cast removal.



**Figure 5.** Specially designed Risser table used for EDF casting.

The most concerning downside is the potential long-term impact of anesthesia. While animal models have shown neurotoxicity associated with anesthetic exposure, clinical studies have not shown a difference in neurocognitive behavior or IQ when patients younger than 3 years of age have short exposures to anesthesia.<sup>28-30</sup> While it appears the benefits of casting outweigh the risks of anesthesia, we need to continue to be mindful about the



**Figure 6.** Left thoracolumbar curve correction.

potential negative impact of continued exposure and try to minimize this as much as possible.

#### *Authors preferred technique (See video)*

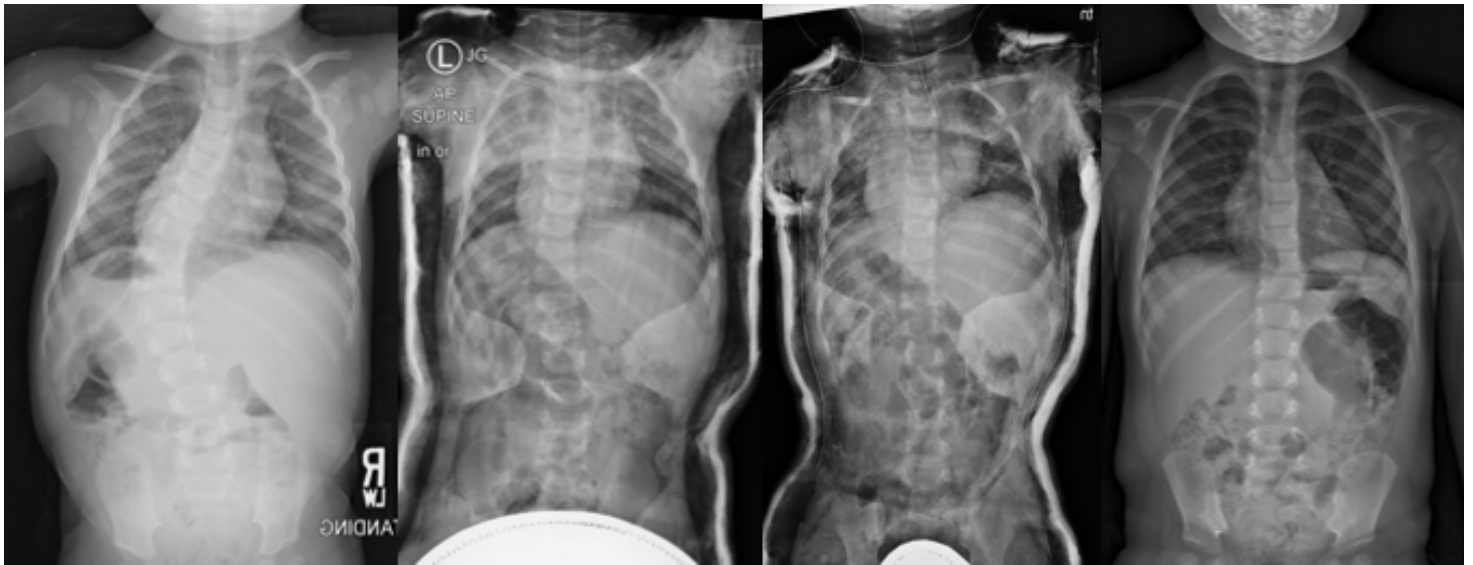
Whenever possible we delay casting until > 12 months unless the curve is very severe. We obtain an MRI in all patients prior to initiating casting to identify any potentially treatable etiologies of scoliosis.

We use a specially designed custom casting table (Figure 5). A 4-way stretch silver impregnated shirt is applied in the preoperative holding area. A 6-inch stockinette with holes cut out for the arms is applied over the shirt. After general anesthesia is administered the stomach is suctioned and a bite block is placed. Traction is applied through the occiput and jaw cranially and through two straps tied around the waist distally. Forty percent of the patient's body weight is applied thru the halter traction proximally. Distally the straps are pulled taut until they are able to support the patient's body weight and the

pelvis is level. Extra padding is applied over the iliac crests anteriorly and the rib prominence posteriorly.

When performing the molding, we prefer to have the surgeon stand on the concave side of the curve. For a left-sided curve, the surgeon's left hand is placed under the patient's right axilla and flexes the patient over with a cranial and medially directed force. With their right hand, they apply a derotation force by lifting upwards on the apical rib prominence just next to the spine. Take care not to allow the palm of the hand to rest on the lateral chest wall as this can cause iatrogenic rib deformity (Figure 6).

Two assistants are needed. Both will stand on the opposite side of the surgeon. One will apply a posteriorly directed force to the patient's left shoulder during the derotation maneuver; this will prevent the patient's whole body from rotating on the table and enabling that force to only derotate the spine. The second assistant will apply the pelvic mold. The pelvic mold is the



**Figures 6A-D.** PA x-ray 12-month-old female with infantile idiopathic scoliosis IIS, 55 degrees left thoracolumbar curve, RVAD 42 degrees; B. AP supine radiograph in first cast; C. AP supine radiograph in last cast; D. Standing PA radiograph now 5 years old, out of brace for 2 years demonstrating complete resolution of scoliosis and disc wedging.

foundation of the cast and they need to take care to apply the mold directly over iliac crests. They also prevent the patient from rotating on the bed during the derotation maneuver. Take care not to let their hands ride up as they can press on the floating ribs and cause an iatrogenic funnel chest deformity. Alternatively, if like Mehta you do not have a second assistant, you can alternate between doing the derotation and the pelvic mold as the plaster hardens.

After the plaster has hardened, we overwrap the cast with fiberglass to help make it more durable. We work promptly to perform the belly cut out as the patient's peak inspiratory pressures rise during this time.<sup>21</sup> Then the remaining cutouts are performed after the belly cut out. Posteriorly a large window is cut out on the concave side for the curve to derotate into and to facilitate hygiene. Trim the axilla so the patient can perform hygiene and reach their mouth. Trim distally so that the patient can flex their hips to 100 degrees so they can sit in their car seat.

Fedorak et al. showed no difference in outcomes when patients were casted over the shoulder versus those that

were not over the shoulder.<sup>31</sup> We prefer to go over the shoulder in patients where the apex is above T8, in patients with thoracic kyphosis, and in very young patients as it reinforces the top of the cast when the patients are small.

We obtain standing PA and lateral radiographs in the first cast to confirm appropriate in-cast correction, then subsequently monitor correction via clinical pictures obtained upon removal of every cast. One should consider the approach of Khoury et al. whereby radiographs should be obtained without a grid which decreases radiation exposure by 80% (*JPOSNA Vol. 2, No. 2*). The interval for casting varies based upon the age of the child. The goal is to place a form-fitting cast that guides the growth of the spine. This means that the cast must be changed based on how quickly the child is growing. We typically change the first cast after approximately 4-6 weeks. This is because the patients often go through a growth spurt after the application of the first cast and often the first cast gets soiled as the parents learn how to care for a child in a cast. Subsequent casts are applied every 6 weeks (in young children) to 3 months (in older children) with the caveat that it can be changed earlier if

it becomes too tight. Families are instructed on signs the cast is getting too tight such as increasing discomfort or early satiety.

We continue casting until the curve has resolved clinically at which point we obtain a radiograph to confirm the curvature is  $< 10$  degrees. At this point we mold for a brace which is available when we remove the cast. We then brace full time for 6 months to 1 year depending on the degree of disc wedging and if there is any residual curvature. If there is no residual curvature, then we will transition to nighttime and naps for 1 more year. We only discontinue bracing if after 1 year of nighttime and nap wear, there is no evidence of curve (Figure 6). All patients are followed until skeletal maturity with clinical exam as the curve may recur later. For those patients that are palliated, we continue to cast until the patient is no longer tolerating casting or the curve begins to progress despite casting.

## Summary

Casting for scoliosis was introduced 150 years ago and continues to be refined. Historically, the technique was used to stretch curves before surgery, to slow progression, or to stabilize the spine to facilitate fusion after surgery. However, the technique for casting scoliosis has evolved much like casting for clubfeet to better address the three-dimensional nature of the deformity. As it has evolved, the outcomes have improved, and its application has expanded. Its current iteration, EDF casting, theoretically harnesses the power of growth, reversing the abnormal tensile or compressive loading described by the Hueter Volkmann principle,<sup>20,32</sup> and subsequent maintenance of correction may in part be due to the vertebral body growth in response to force equalization. There are limitations of the technique. There continues to be significant variability in outcomes, which may be due to the heterogenous patient population, subtle differences in technique, or simply reflect the evolution of the technique. There continues to be no good way to assess pulmonary function in very young children; thus, we do not know if applying a rigid cast to the thorax during the critical period of lung development negatively impacts

lung development. Lastly, we do not know what the long-term consequences are of repetitive early anesthetic exposure. Despite these limitations, it is the only treatment option that has the potential to cure scoliosis. For those it does not cure, it can delay surgical intervention for several years or even prevent it altogether.

## Additional links

See Author's Casting Video

## References

1. Skaggs DL GT, El-Hawary R, et al. Early onset scoliosis consensus statement. *Spine Deformity*. 2015;3(2):107.
2. Williams BA, Matsumoto H, McCalla DJ, et al. Development and initial validation of the Classification of Early-Onset Scoliosis (C-EOS). *J Bone Joint Surg Am*. 2014 Aug 20;96(16):1359-67.
3. Dimeglio A BF, Canavese F. Normal growth of the spine and thorax. In: Akbarnia B. YM, Thompson G., editor. *The Growing Spine*. Berlin, Heidelberg: Springer; 2016. p. 47-82.
4. Herring MJ, Putney LF, Wyatt G, Finkbeiner WE, Hyde DM. Growth of alveoli during postnatal development in humans based on stereological estimation. *American journal of physiology Lung cellular and molecular physiology*. 2014 Aug 15;307(4):L338-44.
5. MS D. Postnatal growth of the lung. *Thorax*. 1962;17(4):329-33.
6. Thurlbeck WM. Postnatal human lung growth. *Thorax*. 1982 Aug;37(8):564-71.
7. Campbell RM, Jr., Smith MD, Mayes TC, et al. The characteristics of thoracic insufficiency syndrome associated with fused ribs and congenital scoliosis. *J Bone Joint Surg Am*. 2003 Mar;85(3):399-408.
8. Karol LA, Johnston C, Mladenov K, Schochet P, Walters P, Browne RH. Pulmonary function following early thoracic fusion in non-neuromuscular scoliosis. *J Bone Joint Surg Am*. 2008 Jun;90(6):1272-81.
9. Waldhausen JH, Redding GJ, Song KM. Vertical expandable prosthetic titanium rib for thoracic insufficiency syndrome: a new method to treat an old problem. *J Pediatr Surg*. 2007 Jan;42(1):76-80.

10. Mehta MH. Growth as a corrective force in the early treatment of progressive infantile scoliosis. *J Bone Joint Surg Br.* 2005 Sep;87(9):1237-47.
11. Zampini JM, Sherk HH, Lewis A. Sayre: the first Professor of Orthopaedic Surgery in America. *Clin Orthop Relat Res.* 2008 Sep;466(9):2263-7.
12. Falcone D. Available from: <https://www.srs.org/professionals/meetings/the-hibbs-society>.
13. Cotrel Y, Morel G. [the Elongation-Derotation-Flexion Technic in the Correction of Scoliosis]. *Revue de chirurgie orthopedique et reparatrice de l'appareil moteur.* 1964 Jan-Feb;50:59-75.
14. Mehta MH MG. The non-operative treatment of infantile idiopathic scoliosis. In: Zorab PA SD, editor. *Scoliosis.* London: Academic Press; 1980. p. 71-84.
15. Fedorak GT, D'Astous JL, Nielson AN, MacWilliams BA, Heflin JA. Minimum 5-Year Follow-up of Mehta Casting to Treat Idiopathic Early-Onset Scoliosis. *J Bone Joint Surg Am.* 2019 Sep 4;101(17):1530-8.
16. Welborn MC, D'Astous J, Bratton S, Heflin J. Infantile Idiopathic Scoliosis: Factors Affecting EDF Casting Success. *Spine Deform.* 2018 Sep - Oct;6(5):614-20.
17. Sanders JO, D'Astous J, Fitzgerald M, Khoury JG, Kishan S, Sturm PF. Derotational casting for progressive infantile scoliosis. *J Pediatr Orthop.* 2009 Sep;29(6):581-7.
18. Baulesh DM, Huh J, Judkins T, Garg S, Miller NH, Erickson MA. The role of serial casting in early-onset scoliosis (EOS). *J Pediatr Orthop.* 2012 Oct-Nov;32(7):658-63.
19. Iorio J, Orlando G, Diefenbach C, et al. Serial Casting for Infantile Idiopathic Scoliosis: Radiographic Outcomes and Factors Associated With Response to Treatment. *J Pediatr Orthop.* 2015 Sep 22.
20. Hassanzadeh H, Nandyala SV, Puvanesarajah V, Manning BT, Jain A, Hammerberg KW. Serial Mehta Cast Utilization in Infantile Idiopathic Scoliosis: Evaluation of Radiographic Predictors. *J Pediatr Orthop.* 2015 Nov 17.
21. Dhawale AA, Shah SA, Reichard S, et al. Casting for infantile scoliosis: the pitfall of increased peak inspiratory pressure. *J Pediatr Orthop.* 2013 Jan;33(1):63-7.
22. Demirkiran HG, Bekmez S, Celilov R, Ayvaz M, Dede O, Yazici M. Serial derotational casting in congenital scoliosis as a time-buying strategy. *J Pediatr Orthop.* 2015 Jan;35(1):43-9.
23. Cao J, Zhang XJ, Sun N, et al. The therapeutic characteristics of serial casting on congenital scoliosis: a comparison with non-congenital cases from a single-center experience. *Journal of orthopaedic surgery and research.* 2017 Apr 4;12(1):56.
24. LaValva S AA, MacAlpine E, Gupta P, Hammerberg K, Thompson GH, Sturm P, Garg S, Anari J, Sponseller P, Flynn J, Cahill PJ; Pediatric Spine Study Group. Serial Casting in Neuromuscular and Syndromic Early-onset Scoliosis (EOS) Can Delay Surgery Over 2 Years. *J Pediatr Orthop.* 2020;40(8):e772-e9.
25. Ballhause TM, Moritz M, Hättich A, Stücker R, Mladenov K. Serial casting in early onset scoliosis: syndromic scoliosis is no contraindication. *BMC musculoskeletal disorders.* 2019 Nov 20;20(1):554.
26. Gomez JA, Grzywna A, Miller PE, et al. Initial Cast Correction as a Predictor of Treatment Outcome Success for Infantile Idiopathic Scoliosis. *J Pediatr Orthop.* 2017 Dec;37(8):e625-e30.
27. Badlani N, Korenblit A, Hammerberg K. Subclavian vein thrombosis after application of body cast. *J Pediatr Orthop.* 2013 Jan;33(1):e1-3.
28. McCann ME, Soriano SG. Does general anesthesia affect neurodevelopment in infants and children? *BMJ (Clinical research ed).* 2019 Dec 9;367:l6459.
29. Cavuoto KM, Javitt M, Chang TC. Neurodevelopmental Effect of General Anesthesia on the Pediatric Patient. *Journal of pediatric ophthalmology and strabismus.* 2019 Nov 1;56(6):349-53.
30. Graham MR. Clinical update regarding general anesthesia-associated neurotoxicity in infants and children. *Current opinion in anaesthesiology.* 2017 Dec;30(6):682-7.
31. Fedorak GT, Stasikelis PJ, Carpenter AM, Nielson AN, D'Astous JL. Optimization of Casting in Early-onset Scoliosis. *J Pediatr Orthop.* 2019 Apr;39(4):e303-e7.
32. Castro FP, Jr. Adolescent idiopathic scoliosis, bracing, and the Hueter-Volkman principle. *Spine J.* 2003 May-Jun;3(3):180-5.