

Osteochondral Allograft Transplantation of the Femoral Head Through an Open Surgical Hip Dislocation

William T. Baumgartner, MD¹; Trevor J. Shelton, MD, MS²; Carter R. White, MS¹; Brian M. Haus, MD, FAAOS¹

¹Department of Orthopaedic Surgery, University of California at Davis, Sacramento, CA; ²Department of Orthopaedic Surgery, Southern California Orthopedic Institute, Van Nuys, CA

Abstract:

Young patients with avascular necrosis (AVN) of the femoral head have limited options for the management of their severe pain. The most common treatments include activity modification, core decompression, proximal femoral osteotomies, non-vascularized or vascularized bone grafting, and total hip arthroplasty. Although osteochondral allograft transplantation (OAT) is commonly used to treat cartilage defects in the knee, few studies report osteochondral allograft transplantation in the hip. OAT of the femoral head is an emerging technique that may be an effective option to preserve the hip in young patients with AVN. The manuscript and video review the indications and describe the technique of OAT of the femoral head through an open surgical hip dislocation.

Key Concepts:

- Perform open surgical hip dislocation to protect blood supply to femoral neck
- Identify osteochondral lesion by removing defective cartilage until healthy edges obtained
- Carefully prepare host bone and donor graft for implantation
- Gently insert osteochondral plug into position until flush with host articular cartilage and secure with headless compression screws if needed
- Secure the greater trochanter and confirm blood flow with Doppler ultrasound

Introduction

Avascular necrosis (AVN) of the femoral head in young patients is a challenging problem for orthopaedic surgeons. If left untreated, adverse outcomes include femoral head collapse and hip joint destruction.¹ In cases of advanced collapse or joint destruction, the only viable option is a total hip arthroplasty (THA) which is not ideal in a young, active patient as they will likely need additional revisions throughout their lifetime which results in decreased patient outcomes.² In those patients without joint destruction, nonoperative management or a

joint preservation procedure would be indicated to try and prevent the need for THA.

Nonsurgical management of AVN of the femoral head would include observation of an asymptomatic lesion until it becomes symptomatic or protected weight bearing.^{3,4} Joint preserving procedures would include core decompression, proximal femoral osteotomies, nonvascularized and vascularized bone grafting, or osteochondral allograft transplantation (OAT). The goal of core decompression is to reduce intraosseous pressure in the

Table 1. Summary of Studies Involving Osteochondral Allograft Transport of the Femoral Head

Authors	Year	N	Age Group	Findings
Meyers ⁷	1985	25 hips (21 patients)	Age at surgery: 16-60 years Follow-up: 9-63 months	- Most failures were receiving systemic steroid therapy - 80% success rate in non-steroid treated patients
Kosashvili et al. ⁵	2013	8 patients	Age at surgery: 23.7 (17-42) years Follow-up: 41 (24-54) months	- Improved HHS (57.7 to 83.9; $p < 0.02^{\S}$) - 63% of patients had good to excellent clinical outcomes
Khanna et al. ⁴	2014	17 patients*	Age at surgery: 25.9 (17-44) years Follow-up: 41.6 (3-74) months	- Improved HHS (52.6 to 72.9; $p < 0.01$) - 41% of patients had good to excellent clinical outcomes
Okadeji et al. ⁸	2018	10 patients	Age at surgery: 24.8 (16-32) years Follow-up: 17.2 (7-36) months	- 60% also had a concomitant procedure for intraarticular pathology - 70% had successful functional outcomes, 30% converted to THA
Mei et al. ⁶	2018	22 patients*	Age at surgery: 24.9 (14-44) years Follow-up: 68.8 (26-113) months	- Improved mHHS (48.9 to 77.4; $p < 0.01$) - 50% of patients had good to excellent clinical outcomes - Graft survivorship 86% at 2 years, 79% at 5 years, and 67% at 9 years

HHS – Harris Hip Score, mHHS – modified Harris Hip Score

[§] Calculated with a Wilcoxon Signed Rank test

* Patients from Khanna, et al. were also used in the study by Mei, et al.

femoral head while restoring vascular flow. Better outcomes with core decompression have been seen in pre-collapse stages with small lesions (< 15% of the femoral head) than those with intermediate (15-30% of the femoral head) or large lesions (30% of the femoral head).⁵ Adjuncts have been added to core decompression including nonvascularized grafts (to provide mechanical support), stem cells, or other biologic adjuncts (to try and promote new bone formation in the repair process) but research has not found one treatment as superior.¹ The goal of proximal femoral osteotomies (transtrochanteric rotational osteotomy or intertrochanteric osteotomy) is to move the osteonecrotic area from a weightbearing to a nonweightbearing area of the hip joint. The role of osteotomy depends on the size and location of the lesion and requires, is technically demanding, and conversion of a

failed osteotomy to THA is more difficult with worse outcomes than a primary THA.¹ The goal of bone grafting is to provide support to the subchondral bone with the graft and to restore blood flow to the damaged area of the femoral head. Studies have shown that vascularized fibula grafting improved survival of precollapse hips compared to nonvascularized grafts.⁶ However, survival rate at 14 years has been reported as being 60% and an approximately 20% donor site morbidity has been reported.^{1,7}

Although OAT is well established in improving outcomes and preserving joint disease in the knee, it is not frequently utilized in the hip. The procedure is used to replace unrepairable cartilage defects with a cartilage plug taken from an osteochondral allograft. While there

is much promise for its use in unsalvageable cartilage defects of the femoral head, its indications and success are not well established in the clinical literature. There are five studies in the literature, with a total of 61 patients (65 hips), which document OAT success of the femoral head (Table 1).⁸⁻¹² These studies show a significant short-term improvement in pain and function with an 86% graft survival at 2 years and 78% survival at 5 years. We have performed the procedure on 10 young patients, using the steps outlined in this paper, with similar success rates.

Surgical Method

Indications & Contraindications

The current indications for OAT for AVN of the femoral head include patients under 50 years of age with failure of nonoperative management, cartilage defect diameter ≤ 4 cm but > 2 cm², AVN involving $< 50\%$ of the femoral head, MRI with no bone edema to indicate quiescence of the AVN, and idiopathic AVN or AVN resulting from a vascular insult that is unlikely to reoccur.^{10,12} Conversely, the contraindications would include preservable hip cartilage during evaluation by hip arthroscopy, existing joint deformity or global hip osteoarthritis, inflammatory joint disease, inability to follow postoperative rehabilitation, previous surgical treatment, and no current smoking or alcohol abuse.^{10,12} Chronic systemic corticosteroids is a relative contraindication.¹²

Preoperative Radiographic Evaluation

Before undergoing this procedure, each patient has a radiographic workup including anteroposterior of the pelvis, a false profile, Dunn view, and lateral of the hip to fully evaluate the hip joint arthritic changes of any other pathology. An MRI is also obtained on each patient to evaluate the size and location of the lesion. A CT scan is also useful to better understand the three-dimensional anatomy of associated deformities associated with AVN, including slipped capital femoral epiphysis (SCFE) and Perthes disease.

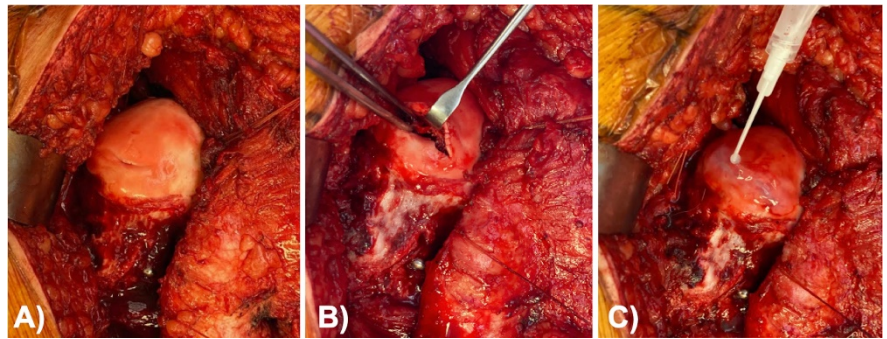


Figure 1A, 1B, 1C. In patients with a salvageable but unstable cartilage flap: (A) Curettage and bone grafting with repair of the cartilage can be performed instead of OAT. (B) Elevation of the stable cartilage flap with curettage, core decompression/drilling, and placement of bone graft taken from the femoral shaft. (C) Repair of the cartilage flap with 6-0 Vicryl and circumferential placement of fibrin glue.

A preoperative diagnostic hip arthroscopy can be helpful in determining the viability of the femoral head cartilage and therefore if the patient is a suitable candidate for OAT. In patients with AVN who otherwise have relatively normal appearing surface cartilage as evaluated by hip arthroscopy, it is preferable to perform an open surgical hip dislocation, elevation of the cartilage flap, core decompression/drilling, bone grafting, and cartilage repair (Figure 1A, 1B, and 1C). In the setting of a collapsed femoral head with pathologic, unsalvageable cartilage, an OATs procedure is indicated.

Required Equipment & Surgical Instruments

Either an MRI or a CT scan is submitted to an allograft company (Allosource, Centennial, CO; LifeNetHealth, Virginia Beach, VA) to find a size-matched donor fresh femoral head. Once an appropriately sized fresh donor graft is identified, it must be used within 1 week. There are several commercially available OAT workstations (Arthrex, Naples, FL; ConMed, Largo, FL) that allow preparation of the allograft.

The stages of OAT include 1) accessing the femoral head, 2) performing the osteochondral allograft transplantation, 3) postoperative protocol. Each stage is in detail outlined below.

Accessing the Femoral Head Via Open Surgical Hip Dislocation^{13,14}

Osteochondral allograft transplantation is performed through a standard open surgical hip dislocation that was originally described by Ganz et al. in 2001.¹³ To do this, the patient is positioned in the lateral decubitus position on a radiolucent operating table. Using a standard Kocher-Langenbeck or straight Gibson-type incision is used to approach and split the gluteus maximus. One advantage of this exposure is that the deep branch of the medial femoral circumflex artery (the main blood supply to the femoral head) is preserved throughout the surgery and protected by the intact obturator externus muscle. A second advantage of this approach is that once the hip has been dislocated, 360-degree access to the femoral head and acetabulum can be achieved.

Once this is done, place three retractors to aid in inspection of the acetabulum. Impact a retractor above the acetabulum, hook a second retractor on the anterior rim, and place a third retractor to lever the calcar of the neck against the incisura acetabuli. Lower the knee for good visualization of head/neck junction without use of a retractor. The blood supply can then be documented through Doppler flowmetry or through a 2.0-mm drill hole made in the dislocated femoral head. Once the hip is dislocated, the osteochondral defect is clearly accessible.

Osteochondral Allograft Transplantation

Once the humeral head has been inspected, identify the edges of the defect and measure the size of the defect (Figure 2A). Next, use the cylindrical sizers available to help map the location of the transplantation (Osteochondral Allograft Transfer System, Arthrex, Naples, FL). Center the sizer over the defect and place a guide pin through the defect to act as a central guide for the osteochondral reamer (Figure 2B). The osteochondral reamer is slid down over the guide pin and carefully used to debride back the diseased cartilage and bone, giving clean edges. Any remaining debris in the femoral head defect should be removed to ensure the graft will sit flush once prepared. Once the osteochondral defect is

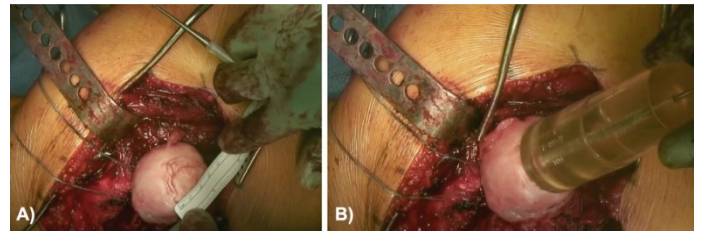


Figure 2A and 2B. Once dislocated, the femoral head should be thoroughly inspected and the borders of the osteochondral lesion identified. (A) After the borders have been clearly identified, the dimensions of the defect are measured. (B) Cylindrical sizers are then used to determine the size of the allograft to be used. Once the defect is sufficiently covered by a cylindrical sizer, it is held in place by a central guide pin which is used to ream over.

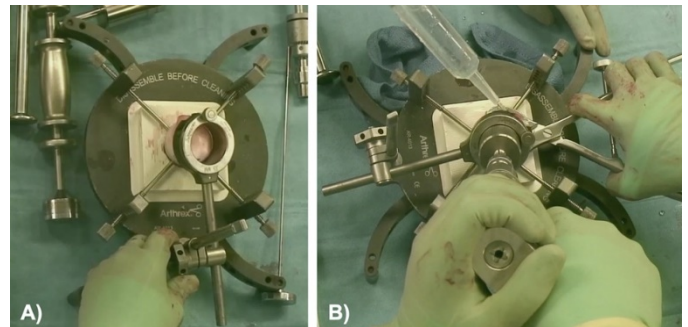


Figure 3A and 3B. (A) The allograft is prepared carefully by adjusting the osteochondral allograft workstation. (B) Once the workstation is set to the appropriate size and position, the graft is reamed out of the allograft femoral head.

removed and the recipient site is prepared, the next step is to prepare the osteochondral allograft donor.

The goal is to match the location and size of the defect. To do this, the donor head is placed next to the patient's femoral head and using the cylindrical sizer as a template, a marking pen is used to template out the recipient site on the donor head. Measure the host bed depth at the 12, 3, 6, and 9 o'clock positions to help map out the defect. Once mapped out, prepare the donor on osteochondral allograft workstation and anchor the donor in place with pins. Adjust the workstation using the same size of the recipient defect and place on the workstation over the marking placed on the femoral head (Figure 3A). The size-match-donor harvester is then placed into the

bushing and the donor head is carefully reamed through the donor graft while keeping the graft irrigated to ensure minimal damage to the graft (Figure 3B). It is very important to ensure that the graft is secure when doing this step as it could slip and then the graft could become damaged or become unsterile. The depth of the graft is fine-tuned to match the depth of the recipient site at the 12, 3, 6, and 9 o'clock positions. Because of the curvature of the femoral head, the depth of the graft may be thinner or thicker circumferentially. Fine oscillating saws and rasps are used to achieve the correct depth. Once the graft is properly sized, it is ready for transplantation.

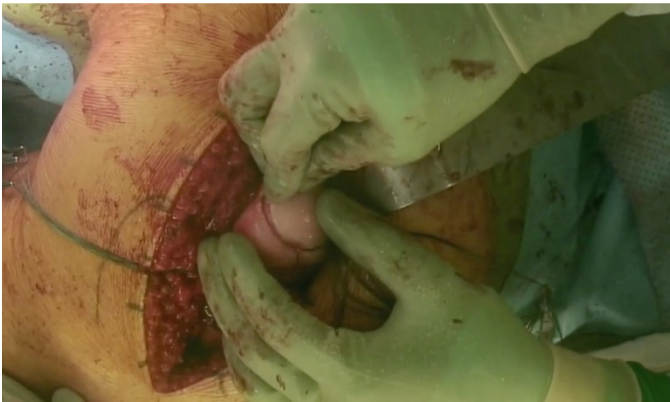


Figure 4. After the allograft has been sufficiently prepared, it is lined up carefully with the host and pushed into place. Once in place, the edges should be thoroughly inspected to ensure the graft is not prominent.

Because the graft and recipient site must match exactly, it is often necessary to try several times to get it perfectly matched to prevent graft and joint collapse or step off. Be sure to match the height of the graft to the measured position on the host bed dimensions (Figure 4). Dilators are used to dilate the recipient site before transplantation which can help with fitting the graft into place. Just before final transplantation, a small drill is used to drill several holes into the recipient site to facilitate healing. Small amounts of autologous bone graft from the trochanteric osteotomy site are packed under the graft to help with healing. Once the graft is finally transplanted, it can be tested for a pressed fit. If there is any concern about its stability, headless screws can be used to fix it in place. After a good fit is obtained, fibrin

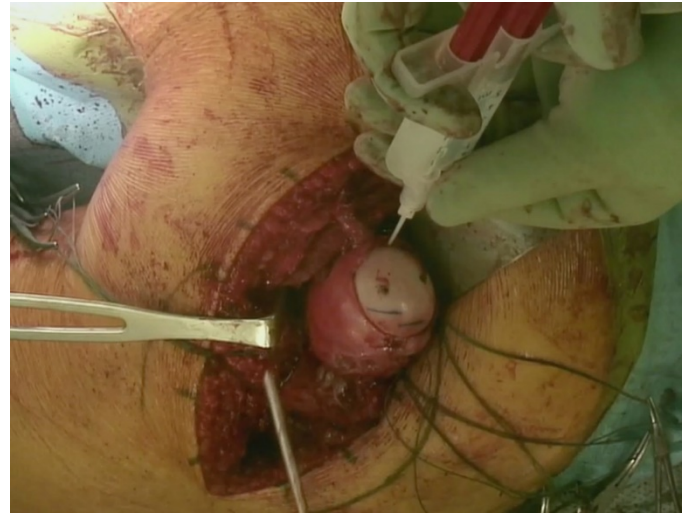


Figure 5. Once the graft is in place and noted to be appropriately positioned, additional fixation can be achieved with either the press-fit technique or with the addition of headless compression screws. Fibrin glue can then be used circumferentially around the graft-host interface.

glue is placed circumferentially around the edge (Figure 5). Once the graft is adequately secured, and the joint has been thoroughly irrigated to remove any debris from the joint, the hip is carefully reduced into the acetabulum. Care is taken to identify the tagged edges of the capsule and retract them out of the way to prevent soft tissue interposition in the joint upon reduction. After the hip is reduced, it is ranged and any femoacetabular impingement at the head-neck junction can be contoured at this time. The capsule is then closed and repaired under minimal tension to prevent limiting blood flow from the retinacular vessels. Confirm with Doppler ultrasound. The trochanteric osteotomy is then secured with two or three 3.5-mm cortical screws.

Postoperative Protocol

For the postoperative protocol, we recommend an abduction hip brace to maintain 20 degrees of hip abduction and 0-90 degrees of flexion for 6 weeks and non-weightbearing for 3 months. Deep vein thrombosis prophylaxis should be used for 6 weeks. Naproxen can be given for heterotopic ossification. Patients are admitted to the hospital postoperatively for pain control and to work with physical therapy on mobility training. Upon

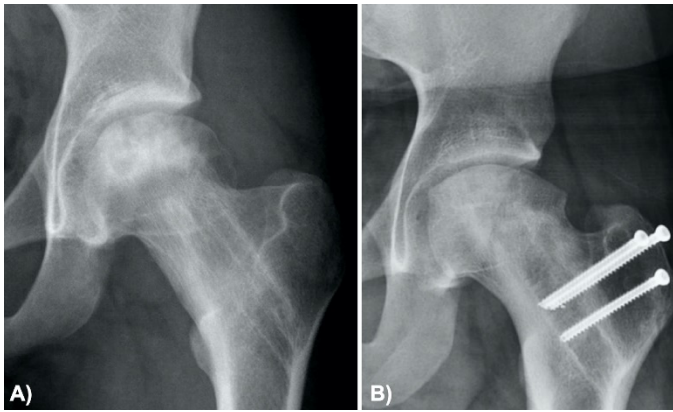


Figure 6A and 6B. (A) Preoperative AP of a 15-year-old patient with painful AVN after sustaining a femoral neck fracture. The screws were removed to prevent penetration into the joint. (B) Five-year follow-up after OAT to the femoral head. There is maintenance of the graft height and overall congruency. The patient does not complain of pain or a limp.

discharge, no further physical therapy is initiated until 6 weeks postoperatively when patients come out of their brace to start working on range of motion. A CT scan is obtained at 3 months to determine healing and integration of the graft. If healed, the patient is approved to subsequently progress to weight-bearing. Plain film radiographs are obtained every 3 months for the first year to assess for graft collapse. Patients are informed of no running or jumping for one year.

Suggestions for Success

As with any hip preservation procedure, it is important to maximize the congruency of the femoral-acetabular joint. Structural deformities associated with concomitant conditions such as SCFE or Perthes Disease should also be corrected at the same time as the OAT. The open surgical hip dislocation allows the ability to also perform femoralplasty, labral repair/reconstruction, relative head neck lengthening and trochanteric distalization, as needed. In severe cases of SCFE, a proximal femoral flexion/valgus/derotational osteotomy can also be performed, although it should be considered how any future THA may be negatively affected by changing the proximal femoral anatomy. The press-fit technique is often sufficient to stabilize the donor graft in the femoral head,

although headless compression screws can be used when there are not stable shoulders around the graft or if stability is of concern. Using the press-fit technique alone prevents any future concerns about graft collapse and potentially prominent hardware.

Review of Outcomes with Best and Worst Case

Patients with relatively normal structural anatomy and congruency of the femoral-acetabular joint are more likely to have the best radiographic outcomes. It is unclear whether or not poor congruency in the setting of femoral head OAT leads to worse clinical outcomes. In patients with femoral heads with limited collapse, it is technically easier to restore the spherical anatomy of the femoral head. Accordingly, patients with AVN from femoral neck fractures without femoral head deformity have more predictable radiographic outcomes than patients with femoral head collapse with concomitant deformities from SCFE or Perthes (Figure 6A and 6B).

It is a vexing surgical problem to manage a young patient with femoral head collapse from AVN that also has a concomitant structural deformity. These patients have limited options, but performing the OAT along with correcting associated structural problems is a promising treatment relative to nonoperative management or THA.

In such patients, it is important to try to restore sphericity/congruency as much as possible with femoralplasty or additional concomitant procedures such as relative head neck lengthening and trochanteric distalization. In cases of Perthes disease or SCFE, it is important to limit posterior femoralplasty so as to not disrupt the vascularity to the femoral head (Figure 7).

OAT should be considered a salvage procedure, and if it fails, options for further treatment in young patients include hip fusion or THA.

Comparison to Other Methods

Traditional treatment options for AVN of the femoral head includes nonoperative treatment (i.e., activity modification), core decompression, proximal femoral

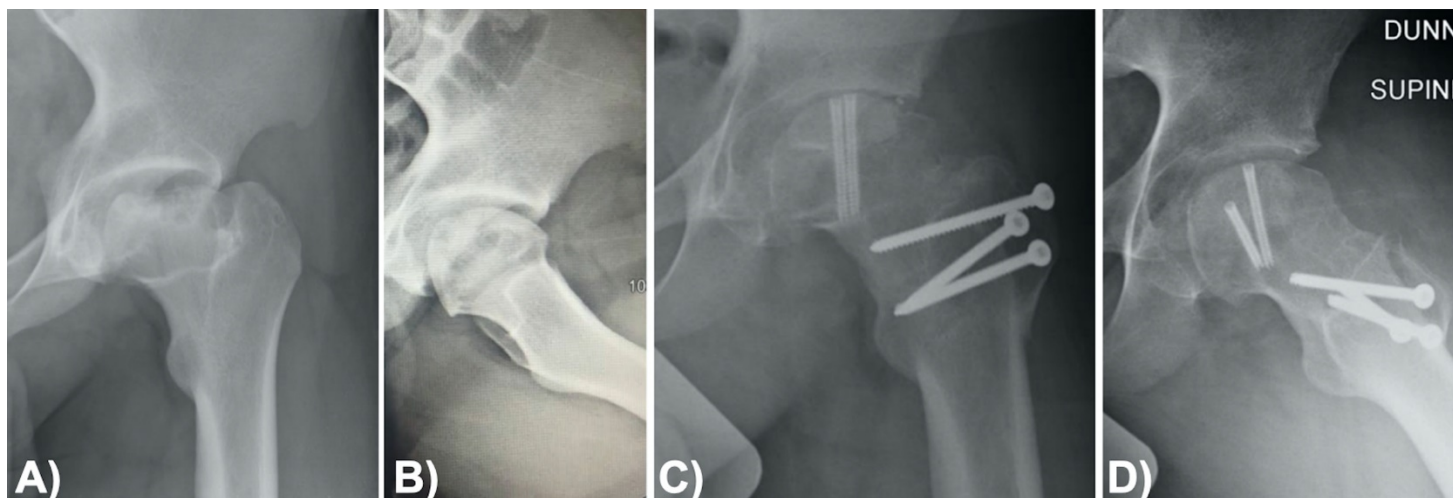


Figure 7A, 7B, 7C, and 7D. (A) AP and (B) lateral views of a 15-year old male patient with hip pain associated with central collapse of the femoral head in Perthes Disease. (C) AP and (D) lateral views 5-year follow-up after OAT to the femoral head. The patient also underwent open labral repair and reconstruction, femoralplasty, relative head neck lengthening, and a distalization. There is maintenance of the graft height and overall congruency, although there is some apparent joint space narrowing. The patient does not complain of pain or a limp.

osteotomies, nonvascularized or vascularized bone graft, and total hip arthroplasty (THA).¹ While all these options are possible in adult patients, they are not ideal in young patients, especially in pediatric and adolescent patients. Nonoperative management is generally reserved to precollapse stages of AVN and involves non-weightbearing and medications such as bisphosphonates to encourage bone healing. However, even with non-weightbearing in an asymptomatic hip, the progression to collapse is 59% within seven years.¹⁵

Core decompression is the most commonly performed surgery for early, precollapse AVN and is intended to decrease the intraosseous pressure within the femoral head and allow increased blood flow to the necrotic area.¹⁶ Historically, the core decompression was made with a large drill hole raising concern for postoperative femoral neck fractures. Newer methods involving multiple smaller drill holes have helped to alleviate that concern.¹⁷ Although the survivorship within the first few years has been reported to be 70-80%, this decreases to about 40% by 10 years.¹⁸⁻²⁰ Worse outcomes have also been seen in lesions that involve more than 50% of the femoral head.^{5,18}

Corrective osteotomies are performed in order to off-load the necrotic area of the femoral head. This also reduces the intraosseous pressure leading to improved vascularity as well.¹⁶ There are two types of osteotomies that are generally used, a trans-trochanteric rotational osteotomy and an intertrochanteric varus or valgus osteotomy (combined with flexion or extension). Trans-trochanteric osteotomy has a reported survivorship of 90% at four years postoperative,²¹ while varus or valgus intertrochanteric osteotomies have a reported 71% survivorship at two years but decreases to 58% by eight years.²² However, when this procedure is combined with other procedures addressed at the necrotic area, results may be improved. For instance, Scher et al. reported a 10-year survivorship of 87% when a flexion valgus osteotomy was combined with autogenous-bone grafting.²³ The role of osteotomy depends on the size and location of the lesion, and requires, is technically demanding, and conversion of a failed osteotomy to THA is more difficult.¹

Nonvascularized bone graft procedures are aimed at replacing the necrotic bone and giving structural support to the hip. This could be achieved with autograft or with allograft. One procedure used for this is a trapdoor proce-

ture in which the hip is approached through an open surgical hip dislocation and a trapdoor is made in the cartilage. The necrotic bone is then removed with a curette and a combination of cancellous chips and cortical struts typically taken from the iliac crest are placed in the defect before the trapdoor is closed. At 56-month follow-up, good-to-excellent outcomes were achieved in 83% of Ficat stage-III hips and 33% of Ficat stage-IV hips indicating that this may be a good procedure for patients with a small- to medium-size lesion with early stages of collapse.²⁴ Similarly, the lightbulb procedure involves making a cortical window at the femoral head-neck junction and the necrotic area is debrided through the window to preserve the articular cartilage. The results of this procedure show 78-85% survivorship for precollapse stages in smaller lesions and 60% survivorship in Ficat stage-III hips or large lesions.²⁵⁻²⁷

Vascularized bone graft is generally performed in precollapse or early collapse of the femoral head. The advantage of this procedure is to provide a vascularized structural support to prevent collapse. Generally, the vascularized graft is either from the iliac crest or fibula. In one meta-analysis, Fang et al., examined the outcomes of six studies and compared the results of vascularized fibular graft to core decompression, nonvascularized fibular autograft, and vascularized iliac graft and found that vascularized fibular graft had a lower conversion to THA (16.5% versus 42.6%) at early to mid-term follow-up.²⁸ However, at 14-years, the survivorship of vascularized fibular graft is only 60%.⁷ In addition, vascularized bone grafting is a technically demanding surgery requiring microsurgery and is associated with donor site morbidity including sensory abnormalities in approximately 20% of patients and is reserved for patients without collapse of the femoral head.¹

The technique of OAT transplantation presented in the present paper provides a unique bone graft procedure as it includes bone-cartilage graft. To date, there are only five studies in the literature with a total of 65 hips in 61 patients who have had OAT for AVN of the femoral head.⁸⁻¹² The first study reporting the outcomes of OAT reported

an 80% success rate (defined as functioning with minimal pain, without support, and with the use of non-narcotic analgesic occasionally for relief) in non-steroid treated patients at a follow-up ranging from 9-63 months.¹¹ Kosashvili et al. and Khanna et al. reported their results at approximately 3.5 years of follow-up and reported 41-63% of patients had a good to excellent clinical outcome.^{8,9} The largest and longest study to date reports the outcomes of 22 patients reported a graft survivorship of 86% at 2 years, 79% at 5 years, and 67% at 9 years.¹⁰

When these other options fail, or in stages of advanced collapse, the only other surgical option is total hip arthroplasty (THA). In young individuals this is challenging due to the increased likelihood of needing additional surgeries. Swarup et al. reported results of patients under 35 years of age who underwent THA for osteonecrosis and found a 10-year survivorship of 86%; however, this decreased to 66% at 20 years. They also expectedly reported that patients who underwent revision THA had lower outcome scores.²⁹ In another study, patients under 50 years of age who underwent THA for osteonecrosis of the femoral head had a high 10-year revision rate (50%) and a higher dislocation rate than age-matched patients who underwent THA for osteoarthritis.³⁰

AVN of the femoral head is a challenging problem in young patients. There are various potential treatment options for these patients but results of those procedures are mixed. OAT of the femoral head is a newer surgical procedure with limited studies to date. Although OAT have been extensively studied for the knee, there are few studies that report the outcomes for their use in the hip as it is a newer surgical procedure. Currently, there are no studies which compare the outcomes of OAT to other methods aimed at preserving the hip from collapse; however, OAT is a promising option to help patients maintain function and activity, avoid long-term complications, and retain healthy aspects of their bone. Future studies are still needed to assess the long-term outcomes of these surgeries as well as compare the outcomes between OAT, core decompression, and vascularized bone grafts.

Summary

OAT is regularly used to preserve osteochondral joint function in the knee. However, OAT at the hip is an emerging technique with little documentation in the literature. OAT is advantageous to traditional treatment methods because it allows preservation of joint function and anatomy while preventing donor site morbidity for grafts. Disadvantages include lengthy weight-bearing and postoperative activity restrictions.

Additional Links

Osteochondral Allograft with Open Surgical Hip Dislocation

http://www.posnacademy.org/media/Video+Abstract+16A+Osteochondral+Allograft+with+Open+Surgical+Hip+Dislocation/1_9g1ct4h3/162962082

Osteochondral Allograft with Open Surgical Hip Dislocation (with focus on osteochondral allograft)

<https://drive.google.com/file/d/19iO-pO-AZl8S4doQ6pMyUi-QOFdST3uv4/view>

References

- Zalavras CG, Lieberman JR. Osteonecrosis of the femoral head: evaluation and treatment. *J Am Acad Orthop Surg.* 2014 Jul;22(7):455-64.
- Adelani MA, Crook K, Barrack RL, Maloney WJ, Clohisey JC. What is the prognosis of revision total hip arthroplasty in patients 55 years and younger? *Clin Orthop Relat Res.* 2014 May;472(5):1518-25.
- Hernigou P, Poignard A, Nogier A, Manicom O. Fate of very small asymptomatic stage-I osteonecrotic lesions of the hip. *J Bone Joint Surg Am.* 2004 Dec;86(12):2589-93.
- Nam KW, Kim YL, Yoo JJ, Koo KH, Yoon KS, Kim HJ. Fate of untreated asymptomatic osteonecrosis of the femoral head. *J Bone Joint Surg Am.* 2008 Mar;90(3):477-84.
- Israelite C, Nelson CL, Ziarani CF, Abboud JA, Landa J, Steinberg ME. Bilateral core decompression for osteonecrosis of the femoral head. *Clin Orthop Relat Res.* 2005 Dec;441:285-90.
- Plakseychuk AY, Kim SY, Park BC, Varitimidis SE, Rubash HE, Sotereanos DG. Vascularized compared with nonvascularized fibular grafting for the treatment of osteonecrosis of the femoral head. *J Bone Joint Surg Am.* 2003 Apr;85(4):589-96.
- Eward WC, Rineer CA, Urbaniak JR, Richard MJ, Ruch DS. The vascularized fibular graft in precollapse osteonecrosis: is long-term hip preservation possible? *Clin Orthop Relat Res.* 2012 Oct;470(10):2819-26.
- Khanna V, Tushinski DM, Drexler M, et al. Cartilage restoration of the hip using fresh osteochondral allograft: resurfacing the potholes. *Bone Joint J.* 2014 Nov;96-B(11 Supple A):11-6.
- Kosashvili Y, Raz G, Backstein D, Lulu OB, Gross AE, Safir O. Fresh-stored osteochondral allografts for the treatment of femoral head defects: surgical technique and preliminary results. *Int Orthop.* 2013 Jun;37(6):1001-6.
- Mei XY, Alshaygy IS, Safir OA, Gross AE, Kuzyk PR. Fresh Osteochondral Allograft Transplantation for Treatment of Large Cartilage Defects of the Femoral Head: A Minimum Two-Year Follow-Up Study of Twenty-Two Patients. *J Arthroplasty.* 2018 Jul;33(7):2050-6.
- Meyers MH. Resurfacing of the femoral head with fresh osteochondral allografts. Long-term results. *Clin Orthop Relat Res.* 1985 Jul-Aug(197):111-4.
- Oladeji LO, Cook JL, Stannard JP, Crist BD. Large fresh osteochondral allografts for the hip: growing the evidence. *Hip Int.* 2018 May;28(3):284-90.
- Ganz R, Gill TJ, Gautier E, Ganz K, Krugel N, Berlemann U. Surgical dislocation of the adult hip a technique with full access to the femoral head and acetabulum without the risk of avascular necrosis. *J Bone Joint Surg Br.* 2001 Nov;83(8):1119-24.
- Leshikar HB, Haus BM. Open Surgical Dislocation. In: Chapman MW, James MA, editors. *Chapman's Comprehensive Orthopaedic Surgery.* 4th ed. New

Delhi, India: Jaypee Brothers Medical Publishers Ltd; 2019. p. 4957-60.

15. Mont MA, Zywielski MG, Marker DR, McGrath MS, Delanois RE. The natural history of untreated asymptomatic osteonecrosis of the femoral head: a systematic literature review. *J Bone Joint Surg Am.* 2010 Sep 15;92(12):2165-70.

16. Tripathy SK, Goyal T, Sen RK. Management of femoral head osteonecrosis: Current concepts. *Indian J Orthop.* 2015 Jan-Feb;49(1):28-45.

17. Song WS, Yoo JJ, Kim YM, Kim HJ. Results of multiple drilling compared with those of conventional methods of core decompression. *Clin Orthop Relat Res.* 2007 Jan;454:139-46.

18. Bozic KJ, Zurakowski D, Thornhill TS. Survivorship analysis of hips treated with core decompression for nontraumatic osteonecrosis of the femoral head. *J Bone Joint Surg Am.* 1999 Feb;81(2):200-9.

19. Marker DR, Seyler TM, Ulrich SD, Srivastava S, Mont MA. Do modern techniques improve core decompression outcomes for hip osteonecrosis? *Clin Orthop Relat Res.* 2008 May;466(5):1093-103.

20. Mont MA, Ragland PS, Etienne G. Core decompression of the femoral head for osteonecrosis using percutaneous multiple small-diameter drilling. *Clin Orthop Relat Res.* 2004 Dec(429):131-8.

21. Sakano S, Hasegawa Y, Torii Y, Kawasaki M, Ishiguro N. Curved intertrochanteric varus osteotomy for osteonecrosis of the femoral head. *J Bone Joint Surg Br.* 2004 Apr;86(3):359-65.

22. Maistrelli G, Fusco U, Avai A, Bombelli R. Osteonecrosis of the hip treated by intertrochanteric osteotomy. A four- to 15-year follow-up. *J Bone Joint Surg Br.* 1988 Nov;70(5):761-6.

23. Scher MA, Jakim I. Intertrochanteric osteotomy and autogenous bone-grafting for avascular necrosis of the femoral head. *J Bone Joint Surg Am.* 1993 Aug;75(8):1119-33.

24. Mont MA, Einhorn TA, Sponseller PD, Hungerford DS. The trapdoor procedure using autogenous cortical and cancellous bone grafts for osteonecrosis of the femoral head. *J Bone Joint Surg Br.* 1998 Jan;80(1):56-62.

25. Banerjee S, Issa K, Pivec R, Kapadia BH, Khanuja HS, Mont MA. Osteonecrosis of the hip: treatment options and outcomes. *Orthop Clin North Am.* 2013 Oct;44(4):463-76.

26. Seyler TM, Marker DR, Ulrich SD, Fatscher T, Mont MA. Nonvascularized bone grafting defers joint arthroplasty in hip osteonecrosis. *Clin Orthop Relat Res.* 2008 May;466(5):1125-32.

27. Wang BL, Sun W, Shi ZC, et al. Treatment of nontraumatic osteonecrosis of the femoral head using bone impaction grafting through a femoral neck window. *Int Orthop.* 2010 Jun;34(5):635-9.

28. Fang T, Zhang EW, Sailes FC, McGuire RA, Lineaweaver WC, Zhang F. Vascularized fibular grafts in patients with avascular necrosis of femoral head: a systematic review and meta-analysis. *Arch Orthop Trauma Surg.* 2013 Jan;133(1):1-10.

29. Swarup I, Shields M, Mayer EN, Hendow CJ, Burket JC, Figgie MP. Outcomes after total hip arthroplasty in young patients with osteonecrosis of the hip. *Hip Int.* 2017 May 12;27(3):286-92.

30. Ortiguera CJ, Pulliam IT, Cabanela ME. Total hip arthroplasty for osteonecrosis: matched-pair analysis of 188 hips with long-term follow-up. *J Arthroplasty.* 1999 Jan;14(1):21-8.