

Postoperative Analgesia After Posterior Spinal Fusion for Adolescent Idiopathic Scoliosis

Aadit Shah, MD¹; Eduard Praiss Pey, BA²; Stephen Bowen, MD¹; James Barsi, MD¹

¹Stony Brook University Hospital, Department of Orthopaedics, Stony Brook, NY; ²Stony Brook University Renaissance School of Medicine, Stony Brook, NY

Abstract:

Many postoperative analgesic options exist after a posterior spinal fusion (PSF) for adolescent idiopathic scoliosis (AIS) with newer interventions gaining attention. It is unclear which provide the most benefit. The aim of this current concept review is to document the efficacy, safety, and the quality of evidence for different methods of pain management after PSF for AIS. Potent analgesia with IV opioids or epidural anesthesia remains the cornerstone of postoperative analgesia following PSF for AIS. A diverse set of analgesic adjuvants are under investigation with promising results, including GABA-analogues, intrathecal anesthesia, nonsteroidal anti-inflammatory drugs, acetaminophen, ketamine, spinal nerve block, alpha-2 agonists, glucocorticoids, and muscle relaxants. Psychiatric interventions and patient education are also proving to provide value.

Key Concepts:

- IV opioids or epidural infusion are the most widely preferred postoperative pain management strategies following PSF for AIS.
- Multimodal analgesic protocols are becoming increasingly common.
- Numerous analgesic adjuvants are currently under investigation.

Introduction

Adolescent idiopathic scoliosis (AIS) is defined by lateral curvature of the spine in the coronal plane more than 10 degrees.¹ Surgery is indicated for major curve magnitudes greater than 50 degrees. Most patients requiring operative treatment for AIS undergo posterior spinal fusion (PSF) which is considered the gold standard. PSF is associated with significant pain both because it necessitates extensive dissection of tissues, bones and ligaments that are innervated via the posterior rami of spinal nerves and because most of the patients that are treated with

PSF for AIS are young women who are particularly susceptible to pain.¹ Current postoperative pain management strategies are diverse and multimodal, with variation in analgesic efficacy as well as adverse events. The purpose of this current concept review is to synthesize all available data from randomized and observational studies to provide a comprehensive overview of the use and key advantages of different analgesic treatment modalities after posterior spinal fusion in patients with adolescent idiopathic scoliosis.

Methods

Comprehensive MEDLINE and Embase searches were performed for all English language articles published before March 2021 and meeting a search query designed to identify the key terms “postoperative,” “spinal fusion,” “adolescent idiopathic scoliosis,” and “analgesia” as well as common synonyms. The exact search query used on both MEDLINE and Embase used was:

((post-op) OR (post-operative) OR (postoperative) OR (following) OR (after)) AND ((spinal fusion) OR (scoliosis surgery) OR (scoliosis correction surgery)) AND ((ais) OR (adolescent idiopathic scoliosis) OR (adolescent)) AND ((Analgesia) OR (Pain Control)).

Additionally, a search for the two terms “analgesia” and “adolescent idiopathic scoliosis” was used on the Cochrane Library as well as the Clinicaltrials.gov database.

Inclusion criteria focused on studies of postoperative analgesia after posterior spinal fusion for adolescent idiopathic scoliosis. Studies published more than 20 years old and case reports were excluded. Results were screened using the machine learning software Rayyan QCRI (<https://rayyan.qcri.org>). Discussions on intraoperative anesthesia without focus on postoperative analgesia, reports on chronic analgesia, and analgesia studies that failed to segregate AIS were excluded.

Studies were grouped according to the analgesic techniques utilized. Groups included: patient-controlled analgesia (PCA) or non-PCA opioid, epidural, GABA analogues, intrathecal, anti-inflammatories, ketamine, psychiatric, nerve block, alpha-2 agonist, lidocaine or bupivacaine, glucocorticoids, muscle relaxants, and multimodal analgesia (MMA) pathways.

Outcomes assessed included length of stay, pain scores, and opioid dose reduction. Metrics for each outcome were days, numerical pain scale rating, and morphine milligram equivalents, respectively. Outcomes were synthesized by summarizing effect estimates.

Modality	References	Sub-Groups (references)
Intravenous opioids	14	IV morphine(10) Adjuvant opioid(3) Oral opioids(1)
Epidural	13	N/A
GABA-analogues	10	N/A
Intrathecal	7	N/A
Anti-inflammatory	7	N/A
Ketamine	6	N/A
Psychiatric	5	N/A
Nerve Block	1	N/A
Alpha 2 Agonist	5	Primary Analgesic(1) Adjuvant(4)
Continuous Wound Infiltration	4	N/A
Glucocorticoids	1	N/A
Muscle Relaxants	3	N/A

Table 1. Groups used to sort studies by analgesic modalities.

*The “PCA or non-PCA opioid” group only included studies evaluating PCA or non-PCA opioid use as a primary outcome as virtually all studies referenced in this review reference PCA with opioids as a control.

Results

Six hundred sixty-six results were retrieved from MEDLINE, and 490 were retrieved from Embase. Twenty-eight results were retrieved from the Cochrane Library and 16 from the Clinicaltrials.gov database. These sum to a total of 1200. After removing duplicates, 910 records were screened and 124 were included. Seven of these were excluded due to lack of sufficient evidence of the efficacy of the analgesic modality.

Discussion

Analgesic Modalities

Intravenous Opioids

IV Morphine

Historically, intravenous (IV) patient-controlled analgesia (PCA) or continuous infusion with opioids has been a mainstay of pain management in the immediate postoperative period after scoliosis surgery, with the most common side effects being postoperative nausea and vomiting (PONV).^{1,2} With appropriate pump settings, opioids are established as safe and efficacious in children.^{1,3,4} Because children are considered to have a lower risk of respiratory depression, a background infusion is widely used.¹ Typical administration involves a morphine 0.05-0.1mg/kg initial loading dose before the end of surgery followed by PCA bolus dose of 0.01-0.03mg/kg, a lockout interval of 6-10 min, and background infusion of 0.01-0.02mg/kg/h.¹ PCA has been found to be superior to intramuscular analgesia at reducing pain scores in adolescents receiving PSF for AIS ($p < 0.02$).⁵ This may be due to reported high variability in pain tolerance or threshold.⁶

A study comparing postoperative PCA alone and PCA with background infusion for patients receiving AIS repair found no difference between the two strategies with respect to postoperative morphine use, side effects, or patient satisfaction.⁷

The main adverse effects of IV PCA with morphine are postoperative nausea, vomiting (20-80%), and pruritis (11-47%), but clinically significant respiratory depression is rare. Of note, investigations using IV naloxone (0.5mcg/kg/hr) to mitigate opioid-related side effects of pruritis, nausea, vomiting, and respiratory depression have shown limited efficacy against pruritis and nausea, but other outcomes were nonsignificant.⁸⁻⁹ Considering the high incidence of PONV and pruritis, other techniques described later in this review have been investigated to supplement IV PCA to minimize morphine use.

Intraoperative Opioids

Four studies evaluated modalities of intraoperative opioid administration and their effects on PCA opioid requirements and opioid-related side effects.

Compared to continuous sufentanil infusion (0.25ug/kg/h), intraoperative bolus administration of methadone (0.2 mg/kg) was shown to reduce postoperative opioid requirements by approximately 50% at 48 and 72 hours ($p = 0.023$ and $p = 0.024$) as well as decrease pain scores by approximately 50% at 48 hours.¹⁰⁻¹¹ Despite increasing use, however, the intraoperative large bolus use of methadone is controversial due to inconsistent reductions in total opioid use and adverse effects such as respiratory depression, EKG abnormality such as QTc prolongation, and PONV.¹² A newer study reports novel multiple small perioperative methadone doses resulted in safe and lower blood methadone levels of $< 100\text{ng/mL}$.¹²

Intraoperative use of remifentanyl, an ultra-short acting opioid commonly used to supplement general anesthesia, is associated with the development of hyperalgesia manifesting clinically as an increase in postoperative analgesic requirements. A study comparing bolus morphine pre-treatment (150ug/kg) to saline placebo prior to intraoperative

remifentanyl use found no differences between groups for initial 24-hour morphine consumption.¹³ Further, a newer retrospective study found no relationship between remifentanyl dose and opioid consumption through 72 hours specifically in the setting of AIS surgery.¹⁴

Subcutaneous Morphine

Preemptive use of subcutaneous morphine infusion (20mg/day) was found to significantly decrease pain scores as assessed using verbal response score (VRS) and visual-analog scale (VAS) as well as decrease analgesic consumption when compared with control.¹⁵

Oral Opioids

In an attempt to improve pain control beyond the initial postoperative period, controlled release oxycodone-CR has been used safely and effectively in pediatric postoperative spinal fusion patients, converted from PCA to oxycodone-CR, used for an average of 13.3 days with average wean time of 6 days.¹⁶

Epidural

Epidural anesthesia consists of injection of local anesthetics and/or opioids into the spine outside the dura mater. It may be administered as a single injection or a loading dose followed by continuous infusion.¹⁷ Compared to intrathecal injection, single bolus extended-release epidural opioid is associated with longer duration of analgesia.¹⁸

In the pediatric population, it is not well characterized whether epidural analgesia improves pain control, accelerates return of gastrointestinal function, or reduces risk of respiratory depression, length of hospitalization, or costs of care. Compared with IV PCA, epidural anesthesia is complex to administer and is associated with rare side effects such as epidural hematoma or abscess. Therefore, it is important to justify epidural use with clear evidence of its superiority to IV PCA in this population. A recent meta-analysis comparing epidural versus systemic analgesia for thoracolumbar spine surgery in children concluded that moderate and low-quality evidence exists showing epidural

anesthesia may provide a small additional reduction in pain up to 72 hours, and two very small studies showed anesthesia with local epidural anesthetic alone may accelerate the return of gastrointestinal function.¹⁷ Findings were consistent with a similar meta-analysis published 9 years prior.¹⁹ That meta-analysis is to date the highest quality evidence comparing IV PCA versus epidural anesthesia for our target patient population; however, it notably excluded several observational studies that indicated equivalence or advantages with epidural anesthesia over IV PCA,²⁰⁻²⁵ some of which claimed significantly better pain scores for all time periods, less pain fluctuation, lower maximum pain levels during the postoperative period,²² lower pain scores, decreased total opioid use,²¹ decreased time to feeding, and decreased vomiting.²³ Further, a meta-analysis comparing IV analgesia with epidural analgesia that was not limited to the pediatric population found significantly superior analgesia, patient satisfaction, and decreased overall opioid consumption associated with epidural analgesia.²⁶ Therefore, large randomized trials comparing epidural analgesia with systemic analgesia specifically in the pediatric population may sufficiently elucidate advantages of this modality to justify its more complex administration.

Comparison of Different Epidural Analgesia Adjuvants and Techniques

A 2017 randomized study with 48 participants compared patient-controlled intermittent epidural analgesia (PCIEA) versus continuous epidural analgesia (PCCEA) and concluded that nausea, vomiting, and pruritis were considerably higher in the PCCEA group with no significant difference in pain scores.²⁷ Another 2017 randomized study with 71 participants comparing intrathecal morphine and extended-release epidural morphine (EREM) found longer duration of analgesia with EREM versus intrathecal morphine.¹⁸ A 2013 randomized trial involving 66 participants comparing the use of continuous infusion of bupivacaine and fentanyl with two epidural catheters versus one catheter versus IV morphine PCA found dual

catheter epidural analgesia significantly superior to the other modalities in terms of pain control, whereas the single catheter method trended towards the fewest side effects.²⁸

Intrathecal Morphine

Intrathecal morphine is given with a spinal needle into the spinal subarachnoid space as a one-time bolus. A 2015 study concluded that pediatric patients undergoing posterior spinal fusion for AIS experienced improved analgesia from intrathecal morphine for at least 12 hours following administration.²⁹ A retrospective study explored the dosing regimen of intrathecal morphine and found through analyzing 407 consecutive patients that a moderate dose range of 9 to 19 ug/kg (mean 14ug/kg) provided safe and effective analgesia in the immediate postoperative setting, and that higher doses did not provide better analgesia and only increased frequency of respiratory depression.³⁰ Data from a retrospective cohort study of 138 cases comparing PCA alone or PCA with intrathecal injection or PCA with epidural infusion concluded that intrathecal morphine injection controls the pain equally for the first 24 hours with less pruritus and less adverse events.²⁵ A randomized trial of 46 children receiving either no intrathecal injection, low dose intrathecal (morphine 5ug/kg sufentanil 1ug/kg), or high dose intrathecal (morphine 15ug/kg sufentanil 1ug/kg) concluded that low dose intrathecal opioid usage significantly reduced postoperative opioid demand and high dose did not further improve efficacy.³¹ A retrospective study of 20 patients receiving intrathecal morphine matched with 20 receiving epidural hydromorphone found that the intrathecal group reported significantly lower pain scores in the post anesthesia care unit and first 8 hours after surgery but higher pain scores on the second postoperative day. Documented time to ambulation and time of foley catheter removal were statistically earlier in the intrathecal group, and the hospital length of stay was significantly shorter, with no significant difference in adverse events.³² A retrospective case comparison study compared combined intrathecal morphine and epidural anesthesia to

conventional IV-PCA and found that the intrathecal and epidural group reported significantly lower pain scores and total opioid use.²¹

Gabapentin/Pregabalin

Gabapentinoids have been widely used for neuropathic pain, although a recent systematic review of the efficacy and safety of gabapentin and pregabalin for pain in children and adolescents found a paucity of evidence for the analgesic effect and safety.³³ A 2017 database study using ICD9 codes for scoliosis and PSF procedure involving 7349 subjects at 38 children's hospitals found that gabapentinoid use was significantly associated with decreased odds of prolonged IV opioid use (OR 0.63, 95% CI 0.53-0.75) and called for further trials.³⁴ A recent randomized controlled trial involving 50 patients aged 10–19 found that pre and postoperative administration of gabapentin as an adjuvant to multimodal narcotic and NSAID analgesia significantly decreased both opioid use and visual analog pain scales in the first two postoperative days and suggested that gabapentin be considered as a standard medication for perioperative pain control in this population.³⁵ Another randomized study found decreased initial pain scores but no change in opioid related side effects with adjuvant gabapentin use.³⁶ A similar randomized study with 63 participants using pregabalin found no difference with respect to postoperative opioid consumption or pain scores.³⁷ A randomized study involving a single preoperative dose of gabapentin did not significantly change postoperative opioid consumption or pain scores.³⁸ A retrospective study found that addition of gabapentin or gabapentin and clonidine regimens to IV morphine PCA reduced opioid use and decreased length of hospital stay.³⁹ Another retrospective chart review found addition of gabapentin adjuvant therapy was associated with improved pain scores and decreased opioid use in the first 48 to 72 hours postoperatively.⁴⁰ A retrospective chart review of 101 patients found that the use of perioperative gabapentin is associated with a significant decrease in time to completing physical therapy goals.⁴¹

NSAIDs or Acetaminophen as Adjuvants

NSAIDs and acetaminophen (APAP) have been well known to augment the analgesic effects of oral opioids and minimize opioid usage requirements. A randomized cohort study of 114 adolescents found that IV APAP and PCA was significantly superior to PCA alone in terms of decreasing length of hospital stay.⁴² However, a double-blinded randomized controlled trial with 36 patients explored acetaminophen as an alternative to NSAIDs, claiming NSAIDs may inhibit bone healing through COX inhibition. This study found that IV APAP did improve analgesia but did not diminish oxycodone consumption during the 24 hours following spine surgery.⁴³ A chart review of 7349 patient records from 38 children's hospitals found that postoperative ketorolac use was associated with decreased likelihood of prolonged IV opioid exposure.³⁴ A prospective, randomized, double-blinded, placebo-controlled trial with 36 adolescents assessing analgesic effects of low-dose ketorolac in conjunction with PCA found that compared to PCA alone, the ketorolac group had significantly lower pain scores on POD 1 and 2 and tolerated activity better on POD 1 with no differences in incidence of pruritus, nausea, vomiting, or constipation and no difference in incidence of curve progression, hardware failure, or back pain in the 2 years following spinal fusion.⁴⁴

Ketamine

Ketamine is an NMDA receptor antagonist with well-documented use in children as an anesthetic and analgesic.⁴⁵ The use of intravenous ketamine as an adjuvant alongside morphine to reduce postoperative pain has been explored in several different surgery subtypes with conflicting results. Ketamine has shown promise to be opioid sparing and analgesic by itself. Most recent Level I evidence from a prospective, randomized, double-blinded, placebo-controlled trial with 50 adolescent patients comparing the standard morphine equivalent therapy to the standard therapy plus ketamine found significant reductions in postoperative morphine equivalent consumption, pain scores, and incidence of nausea and vomiting.⁴⁶

Notably, earlier research has shown conflicting results. Two 2017 studies,^{45,47} one observational and one randomized controlled trial, found no statistically or clinically significant benefits of ketamine as a postoperative adjunct analgesic for AIS surgery.⁴⁵ A 2014 randomized controlled trial did not find evidence to support the use of perioperative low-dose ketamine to decrease opioid use in this patient population.⁴⁸

Studies that supported the use of ketamine adjuvant therapy include a randomized controlled trial that found significant reductions in morphine consumption up to 48 hours postoperatively and significantly smaller antiemetic consumption in the experimental group receiving intra- and postoperative low dose ketamine infusion.⁴⁹ In 2014, another randomized controlled trial of 50 patients found that combined ketamine and magnesium adjuvant therapy reduced postoperative morphine consumption and seemed to provide better sleep quality and patient satisfaction.⁵⁰ In that trial, magnesium was added for its noncompetitive NMDA receptor antagonist properties, and it is also known to inhibit intracellular influx of calcium.⁵⁰

Psychiatric Intervention

A study descriptively examining the effectiveness of PCA in children and adolescents following spinal fusion posited that pain stimuli produces psychological and emotional responses and therefore relief of the pain may need multidimensional non pharmacologic along with precisely titrated pharmacologic therapies.⁵¹ To this end, some studies have attempted to effect pain scores through psychological interventions.

A randomized controlled study compared cognitive-behavioral interventions' effects on self-reported postoperative pain for adolescents following surgery for AIS. The first intervention was cognitive—presenting objective information about the surgery. The second was behavioral—teaching coping strategies for managing postoperative pain. The third was a combination of these. These three strategies were compared to a control group which was given no instruction. Of these, the behavioral instruction was the only intervention effective for

reducing pain on the second postoperative day, and it remained significantly effective on the fourth postoperative day at which time the combined cognitive and behavioral approach was associated with the most pain reduction.⁵² The same group also found that for adolescents under about age 13, the behavioral coping intervention was associated with more pain reduction than interventions that did not include coping.⁵³

A study investigating a 12-minute music therapy video teaching music-assisted relaxation with controlled breathing and imagery found significantly reduced pain immediately post-therapy versus pre-therapy.⁵⁴ A trial evaluating a video teaching guided imagery and relaxation exercises found significantly less pain in the intervention group at time of discharge, 2 weeks post discharge, and 1 month postoperatively.⁵⁵

A prospective study with 58 adolescents found that patients with parental anxiety of greater than 1 standard deviation above the mean was associated with a two-fold higher risk (47% vs. 20%) that the patient was still taking narcotics at their first postoperative visit at about 2 weeks postoperatively.⁵⁶

Nerve Block

A recent technical report described a novel regional anesthesia technique in which local anesthetic is deposited around the thoracolumbar dorsal rami nerves via four multi-orifice pain catheters to obtain analgesia for posterior spinal fusion surgery on scoliosis patients. The approach was used in three patients, all of whom reported very low pain scores, low doses of opioid consumption, and satisfaction with their pain control throughout the hospitalization.⁵⁷

Alpha-2 Agonists

Dexmedetomidine and clonidine, which exert antinociceptive and sedative effects by stimulating alpha-2 receptors, have been trialed as adjuvants to reduce opioid consumption following PSF. A recent prospective randomized study compared 24h postoperative infusion of either IV morphine (10ug/kg/h) or dexmedetomidine (0.4ug/kg/h), both in addition to

multimodal analgesia with preemptive 10mg/kg gabapentin, postoperative 1g paracetamol, and 30mg ketorolac IV every 8h for 48hrs postsurgical. No difference in pain scores or breakthrough analgesia requirement was observed between the two groups during the infusion period or during the first postoperative week, but the dexmedetomidine group had significantly lower incidence of ileus ($p=0.014$), lower incidence of postoperative nausea and vomiting (PONV) ($P<0.001$), and lower mean time to bowel opening ($p<0.001$).⁵⁸

A retrospective trial evaluating PCA with or without oral gabapentin and/or clonidine found that patients receiving gabapentin alone or gabapentin and clonidine had reduced opioid use and reduced hospital stay, and the patients receiving both gabapentin and clonidine had the fewest attempts to obtain morphine over the first 10-hour postoperative period.³⁹

A study comparing fentanyl PCA with fentanyl plus dexmedetomidine PCA found that in the combined dexmedetomidine group, fentanyl requirement was decreased and concluded that side effects of fentanyl may have been reduced and that dexmedetomidine inclusion may bring early postoperative recovery.⁵⁹ In contrast, a retrospective review of 163 cases over 10 years found no difference in opioid use related to dexmedetomidine on any postoperative day.⁶⁰ A similar earlier chart review of 131 patients concluded that a morphine sparing effect might be possible.⁶¹

Continuous Wound Infiltration (CWI)

CWI with local anesthetics via catheters placed in the surgical wound before closure prevents nociceptive impulses, relieves postoperative pain,⁶² and can have significant opioid sparing effect.⁶⁰ A recent retrospective chart review of 81 patients found that in addition to IV PCA and oral opioids, CWI bupivacaine provided via elastomeric pumps was associated with clinically and statistically significant improvements in postoperative course, and that the addition of multimodal pain management with gabapentin and methocarbamol was associated with trends toward

further improvements.⁶³ An earlier randomized, prospective, double blinded study with 30 participants investigating the use of CWI and epidural anesthesia in addition to IV PCA concluded that this combination was an “effective and simple method” for postoperative analgesia with significant reductions in postoperative morphine consumption and VAS pain scores versus a control group receiving IV PCA alone.⁶² A retrospective chart review of 107 patients in 2011 found that compared to narcotic and non-narcotic PCA, postoperative wound irrigation with 0.1-0.2% ropivacaine in combination with NSAIDs was more effective in that it provided for earlier feeding and reduced incidence of vomiting.²³

Glucocorticoids

Literature has supported the use of postoperative steroids in other areas of orthopaedics on the basis of more rapid recovery and improved postoperative pain control, but surgeons have hesitated to use steroids in patients undergoing posterior spinal fusion because of the risk of wound complications—glucocorticoids suppress the body’s immune response and increase serum blood glucose, both of which are risk factors for wound healing complications and acute infection.⁶⁴ A recent records review of 118 patients undergoing PSF for AIS between 2015 and 2018 concluded that three doses of postoperative dexamethasone (mean dose 8mg) was associated with a 39.6% decrease in total opioid usage ($p < 0.001$) with no significant difference in incidence of infection or wound dehiscence.⁶⁴

Muscle Relaxants

Three studies were identified that made use of methocarbamol, a muscle relaxant with proven efficacy providing symptomatic relief in acute back pain.⁶⁵ In the first, the addition of 500mg oral methocarbamol and gabapentin to an opioid administration strategy utilizing elastomeric pain pumps showed nonsignificant improving trends across three outcomes: infection, postoperative gastrointestinal retention, and length of stay.⁶³ A second study evaluated the implementation of a Perioperative Surgical Home

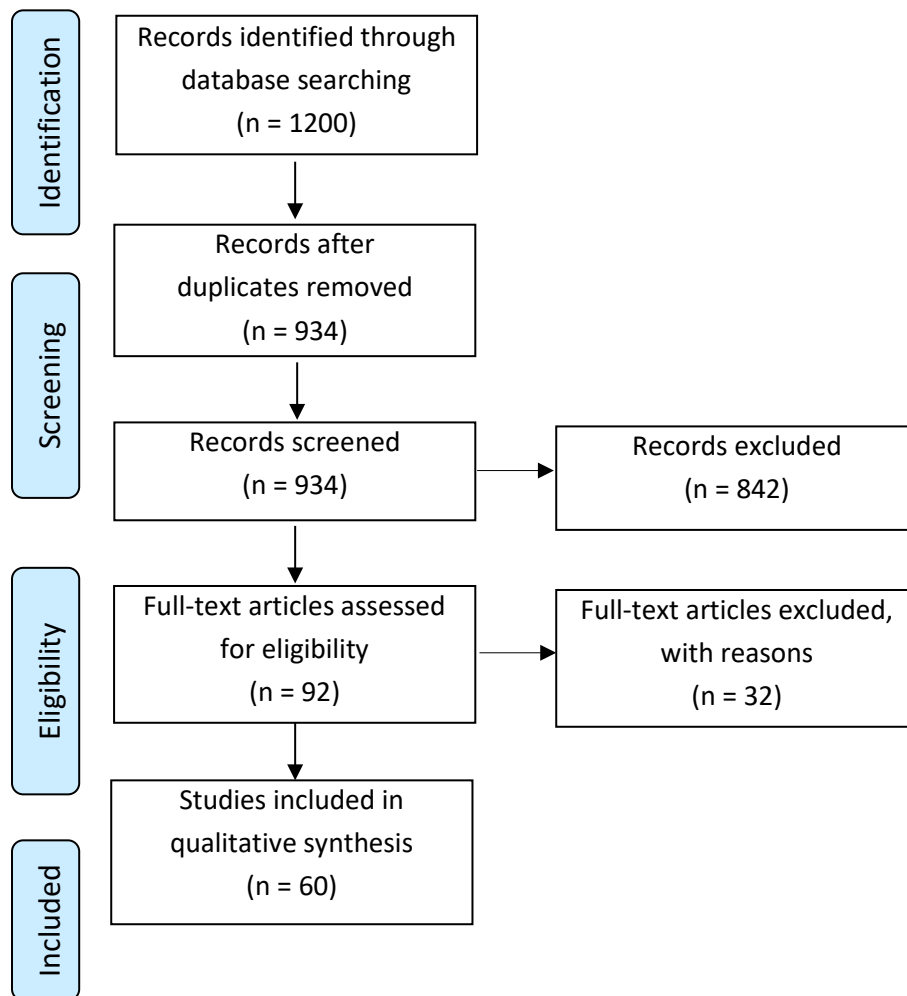
(PSH) model of standardization of care for AIS including postoperative methocarbamol, ketorolac and pre- and postoperative gabapentin all augmenting intravenous hydromorphone and oral oxycodone. Findings in the PSH group were significant decreases in opioid use, PICU utilization, and allogenic blood transfusion as well as increased non-opioid pain medications.⁶⁶ The third study also included methocarbamol in a care standardization protocol with scheduled methadone, methocarbamol, ketorolac or ibuprofen, acetaminophen and oxycodone with intravenous opioids as needed. Pain scores were higher in the protocol group on day 0, similar on POD 1, and lower on POD 2 with additional significant improvements in total morphine consumption, length of stay, median time to first bowel movement, and number of post discharge pain-related phone calls.⁶⁷

These three studies did not isolate methocarbamol to assess its efficacy in this patient population, but trending data in the first study that isolated the combination of methocarbamol and gabapentin illustrate that it may have some role. Positive results from the latter two studies suggest further research is indicated isolating the efficacy of methocarbamol as an analgesic adjuvant.

Summary

IV patient-controlled anesthesia (PCA) with morphine is the preferred primary method of analgesia with multimodal analgesic protocols becoming increasingly common. IV PCA may be supplemented with a continuous morphine infusion. The other primary methods of analgesia currently under investigation are epidural administration of opioids, IV dexmedetomidine infusion, and case reports of dorsal rami nerve blocks with local anesthetics.

Numerous adjuvant approaches exist to modulate the primary analgesic modality. Common objectives are to decrease total opioid use, decrease opioid-related side effects such as postoperative nausea and vomiting (PONV), and decrease time to recovery. These

Figure 1. Current Literature Review Diagram

adjuvant approaches include intraoperative methadone bolus administration instead of continuous sufentanil infusion, subcutaneous morphine injection, intrathecal opioid injection, perioperative or standing gabapentin, NSAIDs, acetaminophen, ketamine, psychiatric interventions, alpha-2 agonists, continuous wound infiltration with local anesthetics, glucocorticoids, and muscle relaxants.

Authors Preferred Strategy

After careful review of this extensive literature search, the authors currently recommend the following protocol for our patients. Preoperatively, during a family conference discussing the risks and benefits of surgery, we spend time discussing pain control following

surgery. We believe that managing expectations and making patients aware of the protocol reduces their overall anxiety and can therefore manage the psychological aspects of pain. We also prescribe preoperative gabapentin that is begun 2 days prior to surgery. Intraoperatively, we recommend low-dose intrathecal morphine. Postoperatively, we recommend gabapentin, ketorolac for 48 hours followed by ibuprofen, methocarbamol, and an opioid consisting of a demand dose IV PCA for the first 24 hours followed by oral medicine. Patients are monitored carefully postoperatively to watch for respiratory depression which may occur when intrathecal morphine is combined with a postoperative opioid; however, using low dose (5 ug/kg) intrathecal morphine we have not had any instances of this.

Additional Links

- POSNAcademy: *Intrathecal Morphine for Pediatric Spine Surgery*
https://www.posnacademy.org/media/Intrathecal+Morphine+for+Pediatric+Spine+Surgery/0_u3fzguv2/19140032
- POSNAcademy: *Posterior Spinal Instrumentation and Fusion for Treatment of Adolescent Idiopathic Scoliosis*
https://www.posnacademy.org/media/Posterior+Spinal+Instrumentation+and+Fusion+for+Treatment+of+Adolescent+Idiopathic+Scoliosis/0_kpkklion/19140032

References

1. Seki H, Ideno S, Ishihara T, Watanabe K, Matsumoto M, Morisaki H. Postoperative pain management in patients undergoing posterior spinal fusion for adolescent idiopathic scoliosis: a narrative review. *Scoliosis Spinal Disord*. 2018;13:17. Published 2018 Sep 12.
2. Poe-Kochert C, Tripi PA, Potzman J, Son-Hing JP, Thompson GH. Continuous intravenous morphine infusion for postoperative analgesia following posterior spinal fusion for idiopathic scoliosis. *Spine (Phila Pa 1976)*. 2010;35(7):754-757.
3. Garstka J, Mikołajczak G. [Patient-controlled analgesia (PCA) in postop pain management in scoliosis surgery]. *Chir Narzadow Ruchu Ortop Pol*. 1998;63(3):281-286.
4. Beaulieu P, Cyrenne L, Mathews S, Villeneuve E, Vischoff D. Patient-controlled analgesia after spinal fusion for idiopathic scoliosis. *Int Orthop*. 1996;20(5):295-299.
5. Walson PD, Graves PS, Mortensen ME, Kern RA, Torch MA. Patient-controlled versus conventional analgesia for postsurgical pain relief in adolescents. *Dev Pharmacol Ther*. 1992;19(1):32-39.
6. Tyler DC, Pomietto M, Womack W. Variation in opioid use during PCA in adolescents. *Paediatr Anaesth*. 1996;6(1):33-38.
7. Weldon BC, Connor M, White PF. Pediatric PCA: the role of concurrent opioid infusions and nurse-controlled analgesia. *Clin J Pain*. 1993;9(1):26-33.
8. Anderson JT, Pieters B, Schwend RM, Price N. Comparison of low versus medium dose naloxone infusion combined with patient-controlled analgesia after posterior spinal fusion and instrumentation for adolescent idiopathic scoliosis: A randomized controlled trial. *Pediatrics*. 2018;141(1).
9. Pieters BJ, Anderson JT, Price N, Anson LM, Schwend RM. Low-Dose Versus High-Dose Postoperative Naloxone Infusion Combined with Patient-Controlled Analgesia for Adolescent Idiopathic Scoliosis Surgery: A Randomized Controlled Trial. *Spine Deform*. 2018;6(4):430-434.
10. Gottschalk A, Durieux ME, Nemergut EC. Intraoperative methadone improves postoperative pain control in patients undergoing complex spine surgery. *Anesth Analg*. 2011;112(1):218-223.
11. Gottschalk A, Durieux ME, Nemergut EC. . Intraoperative Methadone Improves Postoperative Pain Control in Patients Undergoing Complex Spine Surgery. *Survey of Anesthesiology*. 2011;55(6):308–309.
12. Sadhasivam S, Aruldas BW, Paekiasabapathy S, et al. A Novel Perioperative Multidose Methadone-Based Multimodal Analgesic Strategy in Children Achieved Safe and Low Analgesic Blood Methadone Levels Enabling Opioid-Sparing Sustained Analgesia With Minimal Adverse Effects [published online ahead of print, 2021 Jan 21]. *Anesth Analg*. 2021;10.1213
13. McDonnell C, Zaarour C, Hull R, et al. Pre-treatment with morphine does not prevent the development of remifentanyl-induced hyperalgesia. *Can J Anaesth*. 2008;55(12):813-818.
14. Lo C, Schwindt S, Sharma R, et al. Association Between Intraoperative Remifentanyl Dosage and Postoperative Opioid Consumption in Adolescent Idiopathic Spine Surgery: A Retrospective Cohort Study [published online ahead of print, 2021 Feb 5]. *Anesth Analg*. 2021;10.1213
15. Machida M, Imamura Y, Usui T, Asai T. Effects of preemptive analgesia using continuous subcutaneous morphine for postoperative pain in scoliosis surgery: a randomized study. *J Pediatr Orthop*. 2004;24(5):576-580.
16. Czarnecki ML, Jandrisevits MD, Theiler SC, Huth MM, Weisman SJ. Controlled-release oxycodone for the

management of pediatric postoperative pain. *J Pain Symptom Manage*. 2004;27(4):379-386.

17. Guay J, Suresh S, Kopp S, Johnson RL. Postoperative epidural analgesia versus systemic analgesia for thoracolumbar spine surgery in children. *Cochrane Database Syst Rev*. 2019;1(1):CD012819. Published 2019 Jan 16.

18. Cohen M, Zuk J, McKay N, Erickson M, Pan Z, Galinkin J. Intrathecal Morphine Versus Extended-Release Epidural Morphine for Postoperative Pain Control in Pediatric Patients Undergoing Posterior Spinal Fusion. *Anesth Analg*. 2017;124(6):2030-2037.

19. Taenzer AH, Clark C. Efficacy of postoperative epidural analgesia in adolescent scoliosis surgery: a meta-analysis. *Paediatr Anaesth*. 2010;20(2):135-143.

20. Hong R, Gauger V, Caird MS, Burke C. Narcotic-only Epidural Infusion for Posterior Spinal Fusion Patients: A Single-Center, Retrospective Review. *J Pediatr Orthop*. 2016;36(5):526-529.

21. Ravish M, Muldowney B, Becker A, et al. Pain management in patients with adolescent idiopathic scoliosis undergoing posterior spinal fusion: combined intrathecal morphine and continuous epidural versus PCA. *J Pediatr Orthop*. 2012;32(8):799-804.

22. Sucato DJ, Duey-Holtz A, Elerson E, Safavi F. Postoperative analgesia following surgical correction for adolescent idiopathic scoliosis: a comparison of continuous epidural analgesia and patient-controlled analgesia. *Spine (Phila Pa 1976)*. 2005;30(2):211-217.

23. Aizenberg V, Ul'rikh G, Klu U, Zabolotskiĭ D, Ivanov M, Malashenko N. Methods of analgesia in children after surgical correction of the scoliotic spinal deformities. *Anesteziologiya i reanimatologiya*. 2011(1):59-62

24. Lavelle ED, Lavelle WF, Goodwin R, et al. Epidural analgesia for postoperative pain control after adolescent spinal fusion procedures which violated the epidural space. *J Spinal Disord Tech*. 2010;23(5):347-350.

25. Milbrandt TA, Singhal M, Minter C, et al. A comparison of three methods of pain control for posterior spinal fusions in adolescent idiopathic scoliosis. *Spine (Phila Pa 1976)*. 2009;34(14):1499-1503.

26. Meng Y, Jiang H, Zhang C, et al. A comparison of the postoperative analgesic efficacy between epidural and

intravenous analgesia in major spine surgery: a meta-analysis. *J Pain Res*. 2017;10:405-415. Published 2017 Feb 14.

27. Erdogan MA, Ozgul U, Ucar M, et al. Patient-controlled Intermittent Epidural Bolus Versus Epidural Infusion for Posterior Spinal Fusion After Adolescent Idiopathic Scoliosis: Prospective, Randomized, Double-blinded Study. *Spine (Phila Pa 1976)*. 2017;42(12):882-886.

28. Klatt JW, Mickelson J, Hung M, Durcan S, Miller C, Smith JT. A randomized prospective evaluation of 3 techniques of postoperative pain management after posterior spinal instrumentation and fusion. *Spine (Phila Pa 1976)*. 2013;38(19):1626-1631.

29. Ibach BW, Loeber C, Shukry M, Hagemann TM, Harrison D, Johnson PN. Duration of intrathecal morphine effect in children with idiopathic scoliosis undergoing posterior spinal fusion. *J Opioid Manag*. 2015;11(4):295-303.

30. Tripi PA, Poe-Kochert C, Potzman J, Son-Hing JP, Thompson GH. Intrathecal morphine for postoperative analgesia in patients with idiopathic scoliosis undergoing posterior spinal fusion. *Spine (Phila Pa 1976)*. 2008;33(20):2248-2251.

31. Eschertzhuber S, Hohlrieder M, Keller C, Oswald E, Kuehbacher G, Innerhofer P. Comparison of high- and low-dose intrathecal morphine for spinal fusion in children. *Br J Anaesth*. 2008;100(4):538-543.

32. Hong RA, Gibbons KM, Li GY, Holman A, Voepel-Lewis T. A retrospective comparison of intrathecal morphine and epidural hydromorphone for analgesia following posterior spinal fusion in adolescents with idiopathic scoliosis. *Paediatr Anaesth*. 2017;27(1):91-97.

33. Egunsola O, Wylie CE, Chitty KM, Buckley NA. Systematic Review of the Efficacy and Safety of Gabapentin and Pregabalin for Pain in Children and Adolescents. *Anesth Analg*. 2019;128(4):811-819.

34. Rosenberg RE, Trzcinski S, Cohen M, Erickson M, Errico T, McLeod L. The Association Between Adjuvant Pain Medication Use and Outcomes Following Pediatric Spinal Fusion. *Spine (Phila Pa 1976)*. 2017;42(10):E602-E608.

35. Anderson DE, Duletzke NT, Pedigo EB, Halsey MF. Multimodal pain control in adolescent posterior spinal fusion patients: a double-blind, randomized controlled trial to

validate the effect of gabapentin on postoperative pain control, opioid use, and patient satisfaction. *Spine Deform.* 2020;8(2):177-185.

36. Rusy LM, Hainsworth KR, Nelson TJ, et al. Gabapentin use in pediatric spinal fusion patients: a randomized, double-blind, controlled trial. *Anesth Analg.* 2010;110(5):1393-1398.

37. Helenius LL, Oksanen H, Lastikka M, et al. Preemptive Pregabalin in Children and Adolescents Undergoing Posterior Instrumented Spinal Fusion: A Double-Blinded, Placebo-Controlled, Randomized Clinical Trial. *J Bone Joint Surg Am.* 2020;102(3):205-212.

38. Mayell A, Srinivasan I, Campbell F, Peliowski A. Analgesic effects of gabapentin after scoliosis surgery in children: a randomized controlled trial. *Paediatr Anaesth.* 2014;24(12):1239-1244.

39. Choudhry DK, Brenn BR, Sacks K, Shah S. Evaluation of Gabapentin and Clonidine Use in Children Following Spinal Fusion Surgery for Idiopathic Scoliosis: A Retrospective Review. *J Pediatr Orthop.* 2019;39(9):e687-e693.

40. Trzcinski S, Rosenberg RE, Vasquez Montes D, et al. Use of Gabapentin in Posterior Spinal Fusion is Associated With Decreased Postoperative Pain and Opioid Use in Children and Adolescents. *Clin Spine Surg.* 2019;32(5):210-214.

41. Thomas JJ, Levek C, Quick HD, Brinton JT, Garg S, Cohen MN. Utility of gabapentin in meeting physical therapy goals following posterior spinal fusion in adolescent patients with idiopathic scoliosis. *Paediatr Anaesth.* 2018;28(6):558-563.

42. Olbrecht VA, Ding L, Spruance K, Hossain M, Sadhasivam S, Chidambaran V. Intravenous Acetaminophen Reduces Length of Stay Via Mediation of Postoperative Opioid Consumption After Posterior Spinal Fusion in a Pediatric Cohort. *Clin J Pain.* 2018;34(7):593-599.

43. Hiller A, Helenius I, Nurmi E, et al. Acetaminophen improves analgesia but does not reduce opioid requirement after major spine surgery in children and adolescents. *Spine (Phila Pa 1976).* 2012;37(20):E1225-E1231.

44. Munro HM, Walton SR, Malviya S, et al. Low-dose ketorolac improves analgesia and reduces morphine requirements following posterior spinal fusion in adolescents. *Can J Anaesth.* 2002;49(5):461-466.

45. Southon S, Lukenchuk L, Kerslake M, Huynh G, Chorney J, Tsui B. Low dose postoperative ketamine as an adjuvant analgesic: A review of 50 pediatric patients with adolescent idiopathic scoliosis (AIS). *Scoliosis Spin Disord.* 2017;12.

46. Ricciardelli RM, Walters NM, Pomerantz M, et al. The efficacy of ketamine for postoperative pain control in adolescent patients undergoing spinal fusion surgery for idiopathic scoliosis. *Spine Deform.* 2020;8(3):433-440.

47. Perelló M, Artés D, Pascuets C, Esteban E, Ey Batlle AM. Prolonged Perioperative Low-Dose Ketamine Does Not Improve Short and Long-term Outcomes After Pediatric Idiopathic Scoliosis Surgery. *Spine (Phila Pa 1976).* 2017;42(5):E304-E312.

48. Pestieau SR, Finkel JC, Junqueira MM, et al. Prolonged perioperative infusion of low-dose ketamine does not alter opioid use after pediatric scoliosis surgery. *Paediatr Anaesth.* 2014;24(6):582-590.

49. Minoshima R, Kosugi S, Nishimura D, et al. Intra- and postoperative low-dose ketamine for adolescent idiopathic scoliosis surgery: a randomized controlled trial. *Acta Anaesthesiol Scand.* 2015;59(10):1260-1268.

50. Jabbour HJ, Naccache NM, Jawish RJ, et al. Ketamine and magnesium association reduces morphine consumption after scoliosis surgery: prospective randomised double-blind study. *Acta Anaesthesiol Scand.* 2014;58(5):572-579.

51. Kotzer AM, Foster R. Children's use of PCA following spinal fusion. *Orthop Nurs.* 2000;19(5):19-30.

52. LaMontagne L, Hepworth JT, Salisbury MH, Cohen F. Effects of coping instruction in reducing young adolescents' pain after major spinal surgery. *Orthop Nurs.* 2003;22(6):398-403.

53. LaMontagne LL, Hepworth JT, Cohen F, Salisbury MH. Cognitive-behavioral intervention effects on adolescents' anxiety and pain following spinal fusion surgery. *Nurs Res.* 2003;52(3):183-190.

54. Nelson K, Adamek M, Kleiber C. Relaxation Training and Postoperative Music Therapy for Adolescents Undergoing Spinal Fusion Surgery. *Pain Manag Nurs.* 2017;18(1):16-23.

55. Charette S, Fiola JL, Charest MC, et al. Guided Imaging for Adolescent Post-spinal Fusion Pain Management: A Pilot Study. *Pain Manag Nurs*. 2015;16(3):211-220.
56. Sarkisova N, Andras LM, Yang J, Tolo VT, Skaggs DL. High Parental Anxiety Increases Narcotic Use in Adolescent Patients Following Spinal Fusion. *J Pediatr Orthop*. 2020;40(9):e794-e797.
57. Xu JL, Tseng V, Delbello D, Pravetz MA. Thoracolumbar Dorsal Ramus Nerve Block Using Continuous Multiorifice Infusion Catheters: A Novel Technique for Postoperative Analgesia After Scoliosis Surgery. *Int J Spine Surg*. 2020;14(2):222-225. Published 2020 Apr 30.
58. Naduvanahalli Vivekanandaswamy A, Prasad Shetty A, Mughesh Kanna R, Shanmuganathan R. An analysis of the safety and efficacy of dexmedetomidine in posterior spinal fusion surgery for adolescent idiopathic scoliosis: a prospective randomized study. *Eur Spine J*. 2021;30(3):698-705.
59. Yamazaki K, Kaneda T, Suzuki T. Usefulness of additional dexmedetomidine administration in postoperative pain management after the scoliosis surgery. *Masui The Japanese journal of anesthesiology*. 2014;63(7):783-788.
60. Jones JS, Cotugno RE, Singhal NR, et al. Evaluation of dexmedetomidine and postoperative pain management in patients with adolescent idiopathic scoliosis: conclusions based on a retrospective study at a tertiary pediatric hospital. *Pediatr Crit Care Med*. 2014;15(6):e247-e252.
61. Sadhasivam S, Boat A, Mahmoud M. Comparison of patient-controlled analgesia with and without dexmedetomidine following spine surgery in children. *J Clin Anesth*. 2009;21(7):493-501.
62. Cakar Turhan KS, Ozgencil E, Ozturk Mamik F, et al. Postoperative preemptive segmental epidural analgesia and wound infiltration following the posterior fusion surgery in adolescent patients with scoliosis. *Reg Anesth Pain Med*. 2011;36(5):E166.
63. Kriel HH, Yngve D. Elastomeric Pain Pumps for Scoliosis Surgery. *Cureus*. 2019;11(2):e4042. Published 2019 Feb 11.
64. Fletcher ND, Ruska T, Austin TM, Guisse NF, Murphy JS, Bruce RW Jr. Postoperative Dexamethasone Following Posterior Spinal Fusion for Adolescent Idiopathic Scoliosis. *J Bone Joint Surg Am*. 2020;102(20):1807-1813.
65. Abdel Shaheed C, Maher CG, Williams KA, McLachlan AJ. Efficacy and tolerability of muscle relaxants for low back pain: Systematic review and meta-analysis. *Eur J Pain*. 2017;21(2):228-237.
66. Kelly BA, Saito J, Cullen J, Welch T, Luhmann S. Adoption of a Perioperative Surgical Home for Adolescent Idiopathic Scoliosis Surgery Decreases Postoperative Opioid Usage. *Pediatrics*. 2020;146(1):94-96.
67. Ye J, Myung K, Packiasabapathy S, et al. Methadone-based Multimodal Analgesia Provides the Best-in-class Acute Surgical Pain Control and Functional Outcomes with Lower Opioid Use Following Major Posterior Fusion Surgery in Adolescents With Idiopathic Scoliosis. *Pediatr Qual Saf*. 2020;5(4):e336. Published 2020 Jul 27.