

Angulated Innominate Osteotomy (AIO): A Salter Osteotomy Without a Bone Graft

Makoto Kamegaya, PhD; Takashi Saisu, PhD; Youhei Tomaru, PhD

Chiba Child & Adult Orthopaedic Clinic, Chiba, Japan

Abstract:

The angulated innominate osteotomy (AIO) was first presented as an innominate osteotomy using no bone graft in 2014. Since then, 52 hips in 48 patients with developmental dysplasia of the hip (DDH) have undergone the AIO. The AIO has several advantages over previously described single innominate osteotomy. This technique avoids deformity of iliac crest that occurs secondary to sacrificing the normal contour of the anterior superior iliac spine (ASIS) that can occur in a Salter type osteotomy. It avoids postoperative lengthening of the ilium. There is also less postoperative displacement secondary to direct contact between both iliac fragments. In addition, there is a shorter time for bone union and therefore earlier full weight-bearing. This technique has been performed for 7 years, and there have been no complications seen with this technique. This paper describes the surgical technique for AIO.

Key Concepts:

- The angulated innominate osteotomy is a useful osteotomy in the treatment of childhood developmental dysplasia of the hip.
- The AIO has several advantages over previously described single innominate osteotomies.
- The AIO demonstrates reliable healing and a shorter time to full weight-bearing.

Introduction

There are several advantages to the angulated innominate osteotomy (AIO) technique for correction of acetabular dysplasia. AIO does not lead to sacrifice of the ASIS and resultant asymmetry of the pelvis from iliac crest deformity that occurs with Salter innominate osteotomy (SIO). While the AIO is just as effective as the SIO, it is less invasive and does not require the use of bone grafts.¹ In addition, traditional Salter osteotomies can cause growth disturbance of the pelvic ring secondary to the surgical splitting of the apophysis. This AIO technique also avoids postoperative lengthening of the ilium, which can lead to pelvic obliquity. With the AIO technique, there is less postoperative displacement

secondary to direct contact between both fragments. In addition, this technique has a shorter time for bone union, allowing for earlier full weight-bearing in contrast with our previous pelvic osteotomy using the original Salter method. SIO patients were usually allowed to bear full weight after the implant removal about 3 months postoperatively.

Since our first report of this method, we have continued to have excellent outcomes with this technique. The goal of this paper is to provide a more detailed description of the surgical technique and provide pearls and pitfalls for a successful outcome.

Surgical Technique

1) Skin incision

A 5–6 cm bikini skin incision is made, approximately one finger width below and parallel to the iliac crest (Figure 1).

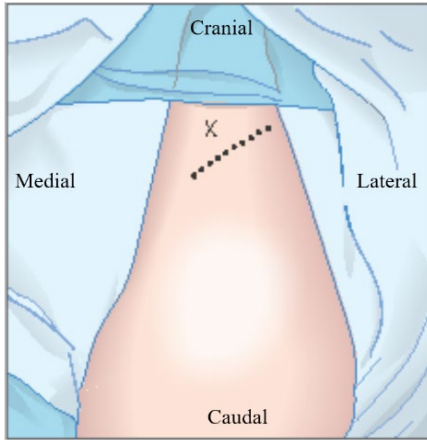


Figure 1. Planning the surgical incision. The “x” indicates the anterior superior iliac spine (ASIS) and the dotted line represents the planned surgical incision.

2) Approach to the iliac crest

The muscle interval between the sartorius and tensor fasciae lata is identified and developed from the ASIS proximally and continues distally along inner and outer margins of the iliac crest (Figure 2).

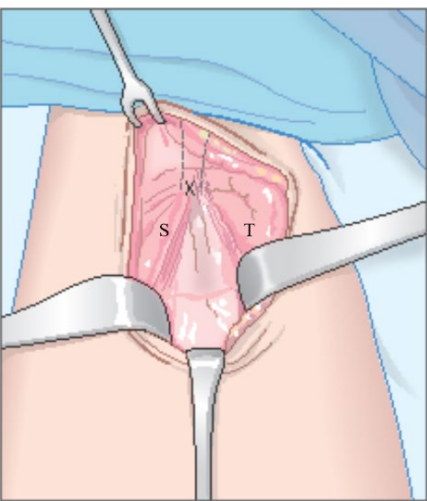


Figure 2. The superficial dissection. The “x” denotes that ASIS, “S” depicts the location of the sartorius, and “T” describes the location of the tensor fasciae lata.

3) Separation of the inner iliac wall

Without vertically dividing the iliac crest apophysis, the inner iliac margin is dissected with an electrosurgical knife. In this process, care is taken to identify and protect branches of the lateral femoral cutaneous nerve. The iliacus muscle on the inner wall is extraperiosteally separated with gentle sweeping of the finger along the periosteum of the inner wall as far as the greater sciatic notch (Figure 3). Using an extra-periosteal technique prevents damage to the subperiosteal bridging veins, thereby reducing blood loss.

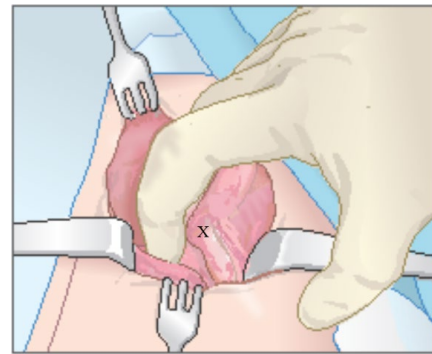


Figure 3. The dissection of the inner table. The “x” denotes the location of the ASIS.

4) Separation of the outer iliac wall

After dissecting the outer iliac margin, the gluteus medius and minimus muscles on the outer wall are extraperiosteally separated with an electrosurgical knife and the use of gauze sponge as far as the greater sciatic notch (Figure 4). Finger sweeping as performed on the inner wall side is not effective because of the adhesiveness to the periosteum in those muscles.

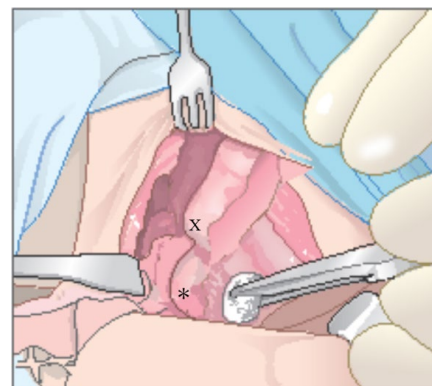


Figure 4. The dissection of the outer table. The “x” depicts the location of the ASIS and “*” describes the location of the anterior inferior iliac spine (AIIS).

5) Approach to the sciatic notch and insertion of forceps

After confirming the location of the sciatic notch from both sides, an acutely curved forceps is passed through the notch from either the inner wall side to the outer wall side or vice versa based on surgeon preference (Figure 5). The forceps is a customized instrument designed with a specific curve for this particular case (Figure 6).

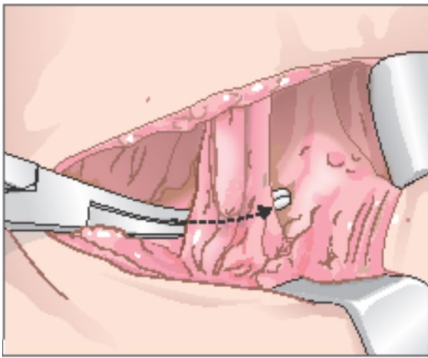


Figure 5. Passage of the curved forceps through the sciatic notch.

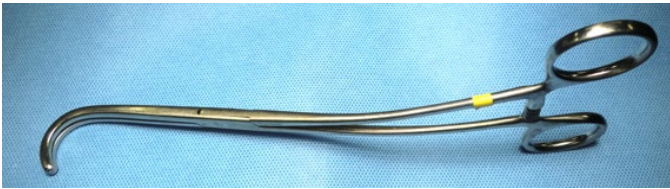


Figure 6. Our customized curved forceps.

6) A suture under the sciatic notch

A suture is placed in the tips of the forceps and is pulled through under the sciatic notch (Figure 7).

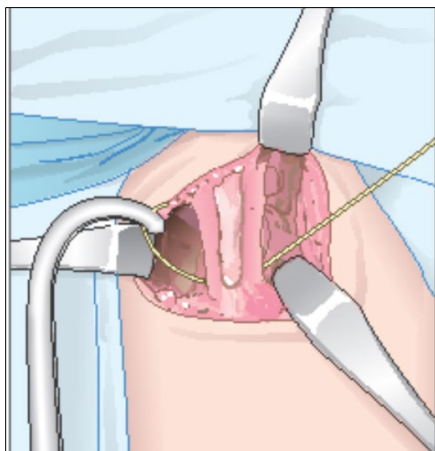


Figure 7. Passage of a suture through the sciatic notch.

Measurement of the distance between the sciatic notch and the upper end of AIIS

Both suture ends are then pulled up along both iliac walls and overlapped on a straight line between the sciatic notch and the upper end of the anterior inferior iliac spine (AIIS). A mark is indicated on each side of the suture at the level of the upper end of AIIS with a skin marker pen to determine the distance between the Sciatic notch and the upper end of the AIIS. Half of the distance between the two marks on the suture indicates the distance (Figure 8).

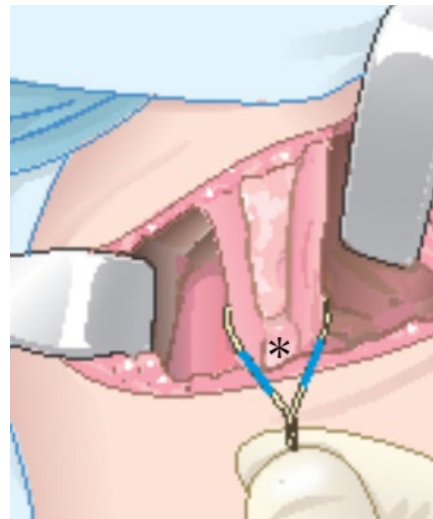


Figure 8. The measurement of the distance between the sciatic notch and the upper end of the AIIS. The "x" depicts the AIIS.

7) Geometric analysis of the triangle for the osteotomy

This angle was chosen based on the results of a biomechanical analysis of the Salter osteotomy,² which produced correction with an angle of approximately 30 degrees. In reality, when performing the osteotomy, it is vital to first identify the vertex on the inner wall. It is on a perpendicular line proximal to the midpoint of the baseline with a distance calculated with the following formula: $A/2 \times \tan 30 \text{ degrees}$ with "A" being the distance between the Sciatic notch and the upper end of AIIS.

An isosceles triangle was determined to be the optimum shape for this type of osteotomy according to the geometric analysis of the three kinds of triangles. The other two triangles did not demonstrate ideal conditions for

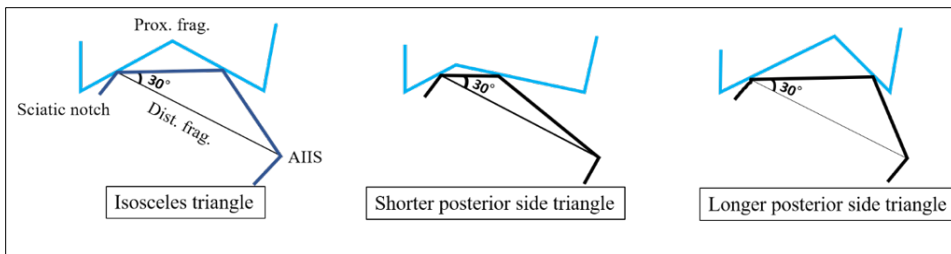


Figure 9. The geometric analysis used to determine the angles for the osteotomy.

stable postoperative fixation. This is because a shorter posterior side triangle results in too shallow a cutting notch and too close each contact point. On the other hand, a longer posterior side triangle shows too deep a cutting notch and too far apart each contact point (Figure 9). Both these conditions hinder optimum bone union.

8) Osteotomy line on the inner wall

A diamond T-saw (MANI, Inc., Takenzawa, Japan) is passed through the sciatic notch with the suture. A T-saw is less likely to damage the surrounding soft tissue during the osteotomy and is extremely smooth to operate. The angulated osteotomy line is performed along two sides of an isosceles triangle having a baseline of the original Salter osteotomy line and two 30-degree base angles (Figure 10).

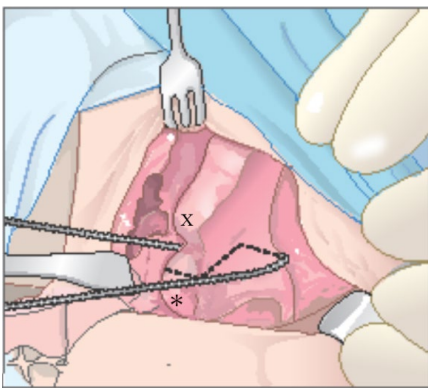


Figure 10. The osteotomy along the inner wall. The “x” describes the location of the ASIS and “*” marks the AIIS.

9) Osteotomy line on the outer wall

The vertex on the outer wall is also marked at the same location as the inner wall. The osteotomy with a T-saw starts towards the vertex along the posterior side of the isosceles triangle from the sciatic notch. With this upward osteotomy, the skin edge is protected from injury by the T-saw (Figure 11). Once approaching the vertex, a downward motion is made to the upper end of the AIIS (the anterior side). Each osteotomy line on both inner and outer walls must be carefully monitored due to the different shape of each iliac wall—concave in the inner wall and convex in the outer wall.

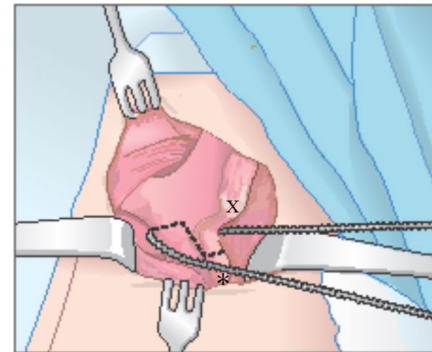


Figure 11. The osteotomy along the outer wall. The “x” describes the location of the ASIS and “*” marks the AIIS.

10) Displacement of the distal fragment and its fixation

After osteotomy, the distal bone is maneuvered anterolaterally to ensure that the outer wall of the proximal bone fragment is in contact with the inner wall of the distal bone fragment with a displacement equal to the thickness of the iliac wall on the anterior side. After confirming the acetabular coverage of the femoral head under image intensifier, a first K-wire (2 mm diameter) is inserted from the inner wall in the proximal fragment to the outer wall in the distal fragment via the laterally displaced osteotomy site on the anterior side (Figure 12).

Additional second (threaded 3 mm diameter) and third (smooth 2 mm diameter) K-wires are inserted from the iliac crest to the posterior column of the distal fragment. The proximal tip of the first K-wire is bent toward the other two K-wire tips for ease of removal. This creates two points of contact between the proximal and distal bone fragments, thereby enabling stable fixation and good bone healing without the use of a bone graft.

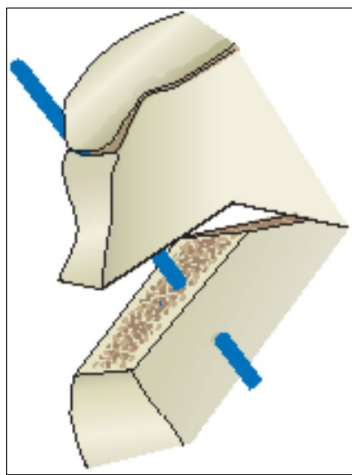


Figure 12. Displacement of the distal fragment. The blue line indicates the initial K-wire placement.

11) Postoperative management

Postoperatively, the patient is placed in a 1.5 leg spica cast for 6 weeks after which full weight is permitted. The wires are buried and subsequently removed in the operating room when bone union is confirmed on a radiograph (usually postop 8~10 weeks).

Case Presentation

This patient was a 7-year-6-month-old Chinese girl at her first visit to our clinic. According to a letter of introduction from the Chinese doctor, she had been diagnosed with a left DDH at the age of 6 months and successfully treated with Pavlik harness. Her initial radiograph demonstrated residual left sided acetabular dysplasia (Figure 13A). She underwent AIO at 8-year-3-months of age. At 6 weeks postop, her spica cast was removed. A radiograph taken at that time demonstrated a well stabilized osteotomy site (Figure 13B) and she was allowed to bear full weight as tolerated. Her hardware

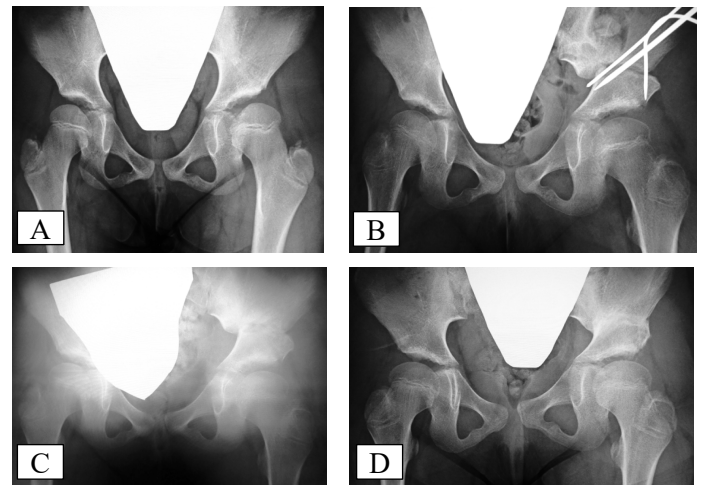


Figure 13. A case presentation: preoperative radiograph (13A), radiograph taken at 6 weeks postoperatively after a spica cast removal (13B), radiograph taken 9 weeks postoperatively after removal of hardware (13C), radiographs taken at 12 weeks postoperatively after final union (13D).

was removed in the operating room 9 weeks after the operation, and a radiograph taken at the same time demonstrated near complete bony union (Figure 13C). At most recent follow-up 12 weeks postop, a radiograph demonstrated complete bony union (Figure 13D), and she could walk normally with normal hip range of motion.

Summary

In conclusion, we have found the AIO to be an efficacious alteration of the original Salter pelvic osteotomy for residual dysplasia. The angulated nature of this cut allows for good anterior coverage while maintaining bony contact and without having increased OR time and potential morbidity when utilizing a bone graft wedge as originally described by Salter. It appears that healing is quicker with the AIO as we are not dependent on complete incorporation of the bone wedge before starting ambulation.

References

1. Morita M, Kamegaya M, Takahashi D, et al. Proposal of a new type of innominate osteotomy without the use of bone graft in children. A preliminary study. *J Bone Joint Surg Open Access*. 2019 Sep 16;4(3), e0016.1-7.
2. Rab GT. Biomechanical aspects of Salter osteotomy. *Clin Orthop Relat Res*. 1978 May;(132):82-7.